

# A rare case of mandibular dentinogenic ghost cell tumor: Histopathological, clinical and surgical management

Daniela Novembre, Elio Giofrè, Ida Barca, Francesco Ferragina, Maria Giulia Cristofaro

Department of Experimental and Clinical Medicine, Maxillo-Facial Surgery Unit, Magna Graecia University, Catanzaro, Italy

## Abstract

Dentinogenic ghost cell tumor (DGCT) is a rare benign tumorous form of calcifying odontogenic cyst (COC) characterized by the presence of ghost cells but it seems to have more aggressive behavior. It represents 11.5% of COCs. In this work, we report a case of a 60-year-old male patient with DGCT in the posterior region of the right mandible treated with surgical enucleation.

**Keywords:** Calcifying odontogenic cyst, dentinogenic ghost cell tumors, ghost cells

**Address for correspondence:** Dr. Ida Barca, Department of Experimental and Clinical Medicine, Maxillo-Facial Surgery Unit, Magna Graecia University, Viale Europa, 88100 Catanzaro, Italy.  
E-mail: barca.ida@gmail.com

**Submitted:** 04-May-2020, **Revised:** 30-Nov-2020, **Accepted:** 19-Jan-2021, **Published:** 14-May-2021

## INTRODUCTION

Calcifying odontogenic cysts (COCs) are developmental odontogenic lesions that occasionally go into recurrence. Dentinogenic ghost cell tumor (DGCT) is a rare tumor form of COC, regarded as variant and seems to have more aggressive behavior. The COC was first described by Gorlin *et al.* in 1962.<sup>[1]</sup> Formerly, the solid variant of COC was called calcifying ghost cell odontogenic tumor. Primary form has the features of cyst, but since it also has several prominent characteristics of a solid neoplasm, it was renamed as dentinogenic ghost cell tumor (DGCT) by Praetorius *et al.*<sup>[2]</sup> In 2005, the WHO classified them into three groups: Calcifying cystic odontogenic tumors (CCOTs), described as benign cystic neoplasms of odontogenic origin; dentinogenic ghost cell tumors (DGCTs), described as locally invasive neoplasms characterized by ghost cell formation; and Ghost cell odontogenic carcinomas (GCOCs), described as malignant and aggressive neoplasms containing groups of ghost

epithelial cells, with metastatic potential.<sup>[3]</sup> The purpose of this article is a case of dentinogenic ghost cell tumor presented at maxillo-facial surgery Department of Magna Graecia University of Catanzaro in a 60-year-old male in the posterior region of the mandible, that is at a comparatively infrequent site.

## CASE REPORT

A 60-year-old male showed up to the Maxillofacial Unit of “Magna Graecia” University of Catanzaro with a swelling in the right posterior region of the lower jaw, since 2 months. The patient complained about the presence of purulent secretion in the absence of pain. No signs of illness were highlighted for extraoral examination. Intraoral examination revealed the presence of a bony hard swelling, extending from 47 to the retromolar region. The lower right second molar also showed motility. The color of the lesional area was the same as that of the adjacent mucosa. There was no

This is an open access journal, and articles are distributed under the terms of the Creative Commons Attribution-NonCommercial-ShareAlike 4.0 License, which allows others to remix, tweak, and build upon the work non-commercially, as long as appropriate credit is given and the new creations are licensed under the identical terms.

**For reprints contact:** WKHLRPMedknow\_reprints@wolterskluwer.com

**How to cite this article:** Novembre D, Giofrè E, Barca I, Ferragina F, Cristofaro MG. A rare case of mandibular dentinogenic ghost cell tumor: Histopathological, clinical and surgical management. *J Oral Maxillofac Pathol* 2021;25:206.

### Access this article online

#### Quick Response Code:



#### Website:

www.jomfp.in

#### DOI:

10.4103/jomfp.JOMFP\_185\_20

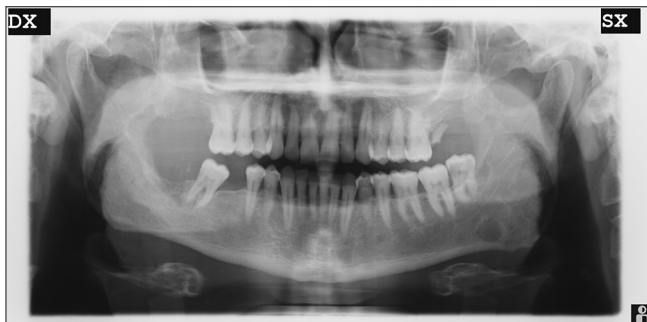limitation of mouth opening and no paresthesia. Clinically, a provisional diagnosis of odontogenic cysts was made. The patient was subjected to various radiographic investigations which included orthopantomograph and computed tomography (CT) scan. The panoramic radiograph showed distal osteorarefaction at the second right lower molar [Figure 1]. Three-dimensional cone beam CT of mandible showed an interesting osteolytic lesion [Figure 2]. Coronal sections on contrast-enhanced CT revealed a heterogeneous, soft-tissue expansile mass in the right jaw from the region of 47, the upright branch up to the subcoronoid region causing destruction of the inner and outer cortical plates. Multiple discrete hyperdense calcified mass were noted in the lingual cortex in the anterior part of the lesion [Figure 3]. Radiographic differential diagnosis included COC, dentigerous cyst, ameloblastoma and central giant cell granuloma were considered. The incisional biopsy and extraction of the right mandibular second molar were performed. Histopathological examination revealed similar findings to those of the initial tumor of the mandible, and there was no evidence of malignant transformation. All the hematological parameters were within the normal

range. Patient consent was obtained prior to the surgery. The lesion was surgically removed [Figure 4] and the tissue was sent to a histological examination: Fibrous wall of cysts covered by multi-layered squamous epithelium in which partially calcified oval structures are found. The presence of widespread chronic inflammatory lymphoplasmacellular infiltrate, dysplastic dentin and large amount of ghost cells based on histopathologic findings, the present lesion was finally diagnosed as DGCT [Figure 5]. Clinical and radiographic control with OPT, after 6 months and after 1 year, showed no signs of recurrence [Figure 6].

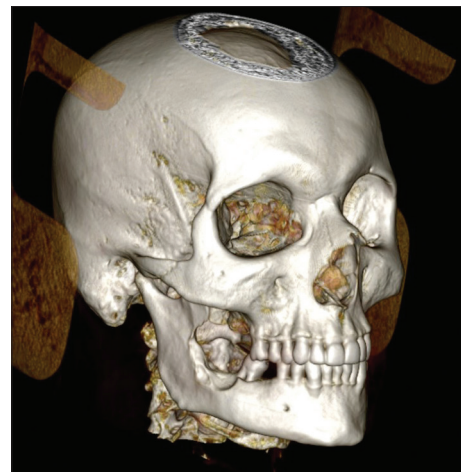## DISCUSSION

Dentinogenic ghost cell tumor (DGCT) is very rare and benign neoplasia of odontogenic epithelium predominantly consisting of ameloblastomatous proliferations.

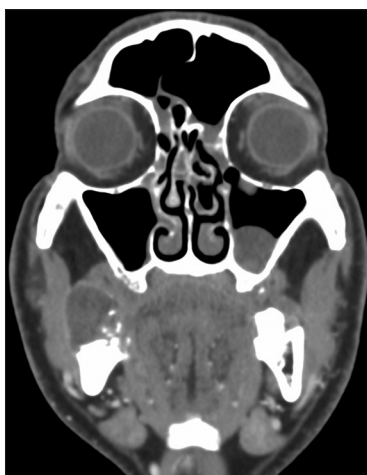It is characterized by islands of odontogenic epithelial cells immersed in a mature connective tissue. Typical is



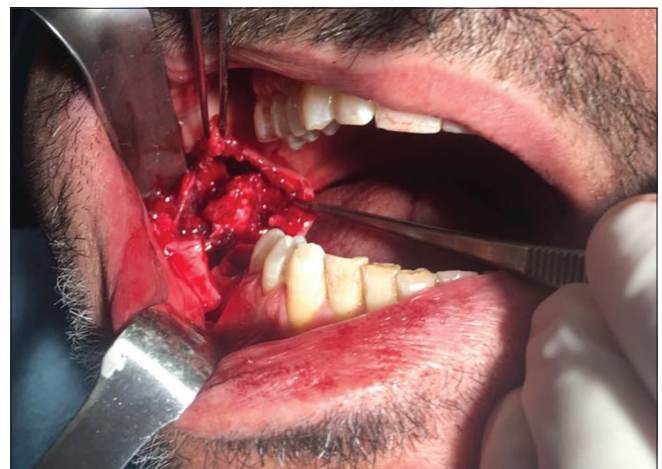**Figure 1:** Preoperative panoramic radiograph showed distal osteorarefaction at the second right lower molar



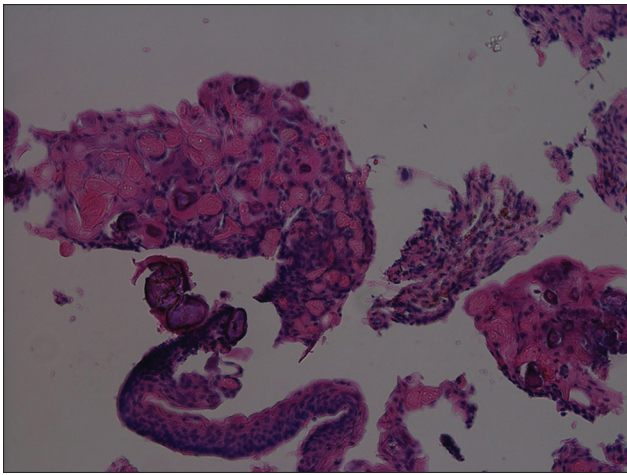
**Figure 2:** Preoperative three-dimensional cone beam computed tomography of mandible showing destructive lesion



**Figure 3:** Preoperative coronal sections on contrast enhanced computed tomography revealed a heterogeneous, soft tissue expansile mass with hyperdense calcification in the right jaw



**Figure 4:** Surgical enucleation of the lesion

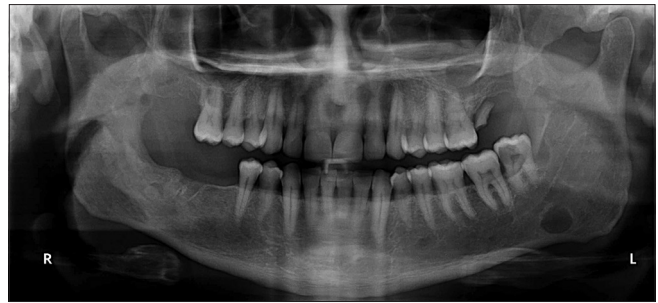

**Figure 5:** Histological image shows fibrous wall of cysts covered by multi-layered squamous epithelium in which partially calcified oval structures are found. The presence of aggregates of eosinophilic ghost cells with large areas of dysplastic dentin

the presence of ghost cells, that are nucleus-free epithelial cells; but it must be emphasized that the mere presence of these is not sufficient to diagnose DGCT. Ghost cells are thought to transform into odontogenic epithelial cells, the mechanism of this transformation remains unknown.

At first, DGCT indicated the solid variant of COC. More recently it has been seen that this variant has several important characteristics of a solid neoplasia, and for this reason, it has been renamed dentinogenic phantom cell tumor (DGCT). According to the latest WHO guidelines, COCs can be classified into three groups: calcifying cystic odontogenic tumors (CCOT), dentinogenic phantom cell tumors (DGCT) and odontogenic phantom cell carcinomas (GCOC). COCs represent about 1%–2% of all odontogenic tumors; of these, 88.5% is represented by the cystic type and the remaining 11.5% is made up of solid tumors, especially the DGCT.<sup>[4]</sup> There are two types of the latter tumor: A peripheral or extraosseous form and a central or intraosseous form. Intraosseous DGCT are more aggressive, have an infiltrative growth pattern and a high recurrence rate after resection; whereas, extraosseous lesions are less common, arise in the gingiva or alveolar mucosa, exhibit limited growth potential and usually occurs in sixth decades. Both intraosseous and extraosseous variants of DGCTs exhibit similar histopathological features.

The average age for the presentation of this lesion is 50 years, (range 17–72 years) with slight male predilection. Tumor occurs in the maxilla and the mandible with equal frequency, with canine to first molar region the most often affected site.<sup>[5]</sup> Patients are usually asymptomatic, although some complain of pain or discomfort.



**Figure 6:** Postoperative panoramic radiograph evaluation after 1 year

Histologically this kind of tumor is characterized by a population of solid basaloid cells, hyperchromatic and isomorphous, displayed as sheets and rounded islands.<sup>[6]</sup> In general, the cystic lumen is lined by odontogenic epithelium (dysplastic dentin-like or osteodentin-like material) of variable thickness with a prominent well-defined basal layer consisting of palisaded columnar cells (ameloblast-like cells) and hyperchromatic nuclei polarized away from the basement membrane.<sup>[7]</sup> The nuclei are moderately enlarged and contain prominent nucleoli; there are increased mitoses number including atypical forms, as well as areas of comedo-type necrosis. Components of oral mucosa, of cutaneous structures or bone are not present.<sup>[8]</sup> The cell that gives its name to this type of tumor is the “ghost cell” or “shadow cell” or “matrical,” which is eosinophilic epithelial cell with no nucleus.

This cell population involves a small part of the neoplasia and can be found in the surface layers; are characterized by eosinophilic cytoplasmic homogenization with loss of nuclei, obviously representing a major component of ghost cell.<sup>[9]</sup> Some of the ghost cell areas are associated with foreign body reaction and psammoma body-type calcification or are accompanied by multicellular giant cell reaction.<sup>[8,9]</sup> The malignant epithelial cells exhibit pleomorphism, hyperchromatism, mitosis, necrosis, an infiltrative growth pattern associated with ghost cell keratinization and a dentinoid formation.<sup>[10]</sup>

Applying an immune-histological staining, the cell component showed strong nuclear reactivity for p63 and p53, cytoplasmic reactivity for CK5/6 and a dominant nuclear, less intense cytoplasmic reactivity for  $\beta$ -catenin. The expression of Ki-67 is low and is between 10% and 20%. Negative reactions were seen for CK14, CK7, CK18, SOX10, smooth muscle actin, S100, GATA3 androgen receptor, DOG-1 and adipophyllin.<sup>[8]</sup> Furthermore, the cells were positive for CK19 and negative for SMA.<sup>[11]</sup>

The COC bears a striking histological resemblance to the calcifying epithelioma of Malherbe. Microscopically, it consists

of ameloblastomatous odontogenic epithelium and varying amount of dentinoid material. The typical feature is the presence of so-called ghost cell keratinization, characterized by the less of nuclei and preservation of basic cellular outlines. They both contain characteristics ghost epithelium and frequently demonstrate a foreign body inflammatory reaction surrounding this epithelial transformation.

Digital dental radiography and dental panoramic tomography are initial imaging modalities for detection of odontogenic tumors. Thanks to the use of these tests it is possible to appreciate an area of osteo-rarefaction. Radiographically, the presence of radiolucency associated with scattered radio-opaque calcifications is typical. Useful second level examinations are CT either the cone-beam CT. These are capable to detect the relationship of odontogenic tumors with the teeth and the mandibular canal, the possible resorption of the roots. They also allow us to study the internal structure of the tumor, its cortical expansion and possible erosion. The DGCT, in most cases, appears as an osteolytic lesion; but it can be radiolucent, radiopaque or mixed appearance.<sup>[12]</sup> The literature also mentions advanced methods, such as CT perfusion or dual-energy CT, or computerized tomographic angiography, useful for the prevascular mapping and the detection of the vascular supply of the odontogenic tumor.<sup>[13]</sup> T1- and T2-weighted magnetic resonance imaging (MRI) may also be recommended. Routine T2-weighted images help in the evaluation of cystic tumors, and contrast study helps to distinguish the solid from the cystic component of the tumor and its extension into the soft tissue. Diffusion-weighted or perfusion-weighted MRI is used for the evaluation of odontogenic tumors. Diffusion-weighted MRI help in characterization of cystic tumors and may help in differentiation of malignant from benign tumors of the head and neck. Perfusion-weighted MRI can help in a prediction of malignancy of head and neck and odontogenic tumors.<sup>[14]</sup>

The differential diagnosis must be made between the DGCT and the odontogenic myxoma. Odontogenic myxomas are locally aggressive benign infiltrating tumors that are most commonly found in the jaw, where they can cause root resorption and displacement of dental elements. They also appear to be OPT as osteolytic lesions that can cause tooth displacement and resorption; at TC, however, they have a typical “tennis racket” or “honeycomb” appearance; moreover, the bark appears perforated and the edge of the bark expands into the soft tissues.<sup>[15]</sup>

Early diagnosis is essential for a better patient prognosis. The treatment depends on the form of DGCT, both

the frequency of recurrence and the malignant potential change.

Intraosseous lesions generally require block excision or segmental resection associated with adequate safety margins which depend on the size and anatomical extent of the neoplasm. They exhibit a high local recurrence rate after limited local resection or conservative therapy on the contrary, extra-osseous lesions are generally treated with local conservative excision. The malignant transformation of a DGCT into odontogenic phantom cell carcinoma is rare.

## CONCLUSION

Although DGCT is an uncommon odontogenic neoplasm, a maxillofacial surgeon should not rule out the possibility of meeting it in daily clinical practice.

It must be underlined how an accurate clinical examination and an appropriate radiographic examination can prevent the under-diagnosis of this specific entity. It is also essential to carry out a close follow-up, in order to early identify a possible recurrence and improve the prognosis.

## Declaration of patient consent

The authors certify that they have obtained all appropriate patient consent forms. In the form the patient(s) has/have given his/her/their consent for his/her/their images and other clinical information to be reported in the journal. The patients understand that their names and initials will not be published and due efforts will be made to conceal their identity, but anonymity cannot be guaranteed.

## Acknowledgments

The authors would like to thank medical staff of the Anatomopathology Department of Magna Graecia University for providing us with detailed histological images and reports used in this study.

## Financial support and sponsorship

Nil.

## Conflicts of interest

There are no conflicts of interest.

## REFERENCES

1. Gorlin RJ, Pindborg JJ, Clausen FP, Vickers RA. The calcifying odontogenic cyst – A possible analogue of the cutaneous calcifying epithelioma of Malherbe. An analysis of fifteen cases. *Oral Surg Oral Med Oral Pathol* 1962;15:1235-43.
2. Praetorius F, Hjorting-Hansen E, Gorlin RJ, Vickers RA. Calcifying odontogenic cyst. Range, variations and neoplastic potential. *Acta Odontol Scand* 1981;39:227-40.
3. Ito A, Ichikawa H, Shiomi S, Matsuzaki H, Tanaka J, Ohata A case of

- calcifying cystic odontogenic tumor associated with odontoma of the maxillary sinus. *Jpn J Oral Maxillofac Surg* 2006;52:532-6.
4. Bafna SS, Joy T, Tupkari JV, Landge JS. Dentinogenic ghost cell tumor. *J Oral Maxillofac Pathol* 2016;20:163.
  5. Agrawal Y, Naidu GS, Makkad RS, Nagi R, Jain S, Gadewar DR, *et al.* Dentinogenic ghost cell tumor-a rare case report with review of literature. *Quant Imaging Med Surg* 2017;7:598-604.
  6. Mori M, Kasai T, Nakai M, Sato K, Takeuchi H, Takai Y, *et al.* Dentinogenic ghost cell tumor: Histologic aspects, immunohistochemistry, lectin binding profiles, and biophysical studies. *Oral Oncol* 2000;36:134-43.
  7. Walia C, Kashyap B, Roy S. Disorganized histomorphology: Dentinogenic ghost cell tumor. *J Oral Maxillofac Pathol* 2017;21:154-7.
  8. Ihrler S, Mollenhauer M, Weitmayr B, Haas CJ. Salivary ghost cell carcinoma: Case report and proposal of a new entity. *Virchows Arch* 2020;476:465-8.
  9. Remya K, Sudha S, Nair RG, Jyothi H. An unusual presentation of ghost cell odontogenic carcinoma: A case report with review of literature. *Indian J Dent Res* 2018;29:238-43.
  10. Del Corso G, Tardio ML, Gissi DB, Marchetti C, Montebugnoli L, Tarsitano A. Ki-67 and p53 expression in ghost cell odontogenic carcinoma: A case report and literature review. *Oral Maxillofac Surg* 2015;19:85-9.
  11. Jia MQ, Jia J, Wang L, Zou HX. Ghost cell odontogenic carcinoma of the jaws: Report of two cases and a literature review. *World J Clin Cases* 2019;7:357-65.
  12. Almazrooa S, Binmadi NO, Khalifa HM, Jadu FM, Jan AM, Meisha DE. The agreement rate between radiographic interpretation and histopathologic diagnosis of jaw lesions. *Radiol Res Pract* 2019;40:56359.
  13. Razeq AA, Tawfik AM, Elsorogy LG, Soliman NY. Perfusion CT of head and neck cancer. *Eur J Radiol* 2014;83:537-44.
  14. Abdel Razeq AA, Samir S, Ashmalla GA. Characterization of parotid tumors with dynamic susceptibility contrast perfusion-weighted magnetic resonance imaging and diffusion-weighted MR imaging. *J Comput Assist Tomogr* 2017;41:131-6.
  15. Albanese M, Nocini PF, Fior A, Rizzato A, Cristofaro MG, Sancassani G, *et al.* Mandibular reconstruction using fresh frozen bone allograft after conservative enucleation of a mandibular odontogenic myxoma. *J Craniofac Surg* 2012;23:831-5.