


HOW I DO IT

Modified side overlap esophagogastronomy after laparoscopic proximal gastrectomy

Yoshito Yamashita¹  | Taichi Tatsubayashi¹ | Koichi Okumura¹ | Takumi Miyamoto¹ | Kohei Ueno²

¹Department of Gastroenterological Surgery, Japanese Red Cross Wakayama Medical Center and Cancer Center, Wakayama, Japan

²Department of Surgery, Graduate School of Medicine, Kyoto University, Kyoto, Japan

Correspondence

Yoshito Yamashita, Department of Gastroenterological Surgery, Japanese Red Cross Wakayama Medical Center and Cancer Center, 4-20, Komatsubara-dori, Wakayama-city, Wakayama 640-8558, Japan.

Email: helji3852@yahoo.co.jp

Abstract

We report a new method of esophagogastronomy after proximal gastrectomy, side overlap with fundoplication by Yamashita (SOFY) in 2017. Recently, even better treatment results can be obtained by modifying the SOFY method. We describe the technical details of the modified SOFY (mSOFY) after laparoscopic proximal gastrectomy. The stomach was dissected in the short axis direction and the esophagus was dissected in the left and right direction. After the proximal gastrectomy, the bilateral diaphragmatic crus were dissected to enhance gastric elevation. After confirming that the esophagus overlapped more than 5 cm at the center of the remnant stomach (we call it SOFY check), the remnant stomach was suture-fixed to the dissected diaphragmatic crus. The right wall of the esophageal stump and the remnant stomach were anastomosed using the full length of a 45 mm-linear stapler. The entry hole was closed in a direction that did not widen the anastomotic hole. Both sides of the esophagus, remnant stomach, and diaphragmatic crus were suture-fixed on the cranial side 1–2 cm away from the anastomosis. Moreover, the left wall and lower end of the esophagus was suture-fixed to the remnant stomach. The preserved dorsal esophageal wall is pressed and flattened by pressure from the pseudofornix, which is the reflux prevention mechanism. The mSOFY method had favorable treatment outcomes. In conclusion, mSOFY can be one of the safe and feasible reconstruction methods after laparoscopic proximal gastrectomy.

KEYWORDS

esophagogastronomy, laparoscopic gastrectomy, mSOFY, proximal gastrectomy

1 | INTRODUCTION

Proximal gastrectomy is more suitable than total gastrectomy for early-stage gastric cancer in the upper third of the stomach from the viewpoint of lymphadenectomy.¹ However, esophagogastronomy, which is the simplest reconstruction method used after proximal gastrectomy, can cause severe reflux esophagitis occasionally. Thus,

various esophagogastronomy methods with an additional antireflux procedure have been reported to date.^{2–6} However, there is no optimal anastomotic method due to problems such as reflux, anastomotic stricture, and technical difficulties.

Thus, we developed side overlap with fundoplication by Yamashita (SOFY) in 2014, which is a novel esophagogastronomy method that can prevent reflux after proximal gastrectomy. Then

This is an open access article under the terms of the Creative Commons Attribution-NonCommercial License, which permits use, distribution and reproduction in any medium, provided the original work is properly cited and is not used for commercial purposes.

© 2022 The Authors. *Annals of Gastroenterological Surgery* published by John Wiley & Sons Australia, Ltd on behalf of The Japanese Society of Gastroenterological Surgery.

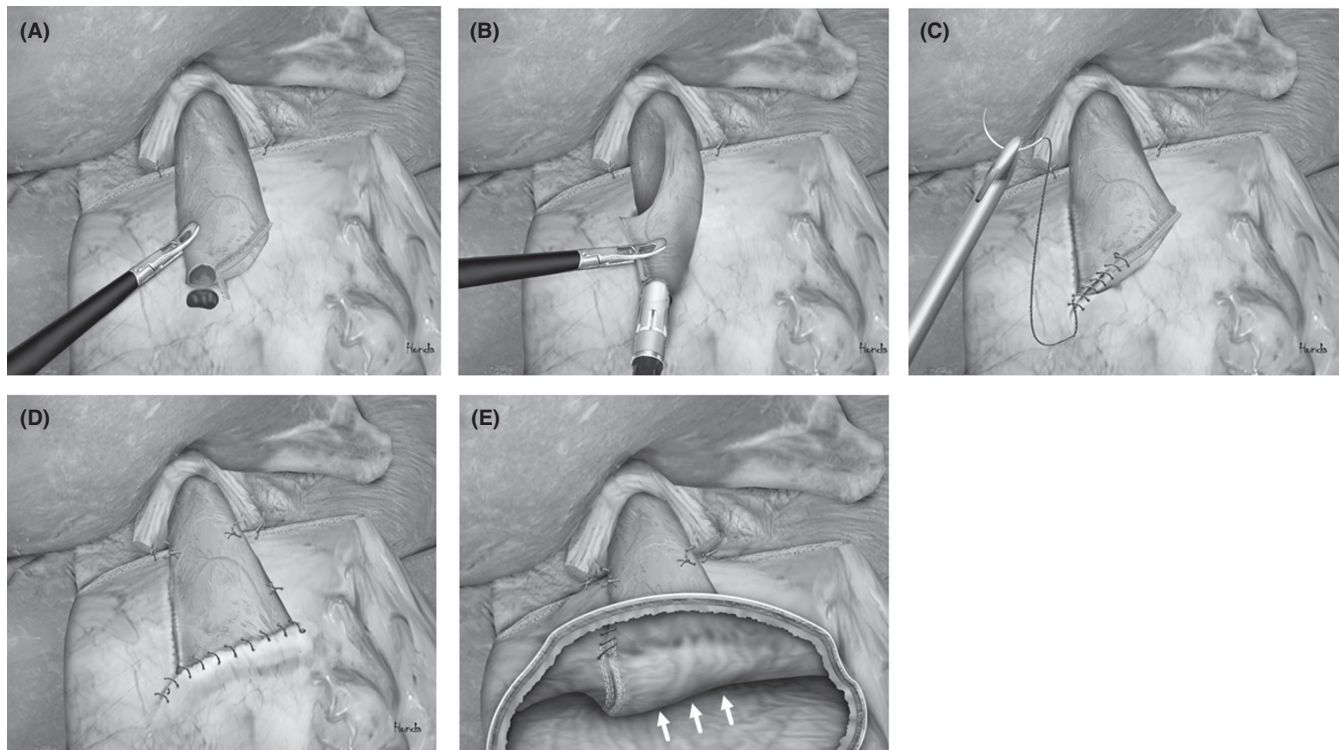


FIGURE 1 mSOFY method. A, Small incisions were made in the right side of the esophageal stump and the anterior gastric wall, which coincided with it. B, Forks of a 45-mm linear stapler were inserted into the esophagus and stomach. The esophagus was rotated counterclockwise on its axis, thereby suturing the gastric wall to the left side of the esophagus. C, The entry hole was closed with an absorbable barbed suture in a direction that did not widen it. D, The left and lower side of the esophagus was sutured to the remnant stomach, so that the esophagus was stuck flat to the gastric wall. E, The preserved dorsal esophageal wall was pressed and flattened into a valvate shape due to pressure from the pseudofornix

it was introduced in 2017.⁷ However, as the number of cases increased, we experienced cases in which the antireflux mechanism could not be technically well created. Thus, we recently modified the SOFY on several points to achieve more stable treatment outcomes. The modified SOFY (mSOFY) method is relatively easy to perform laparoscopically, and it has recently been used in many institutions.

Herein, we present the technical details of the mSOFY method after laparoscopic proximal gastrectomy.

2 | MATERIALS AND METHODS

2.1 | Patients

From March 2018 to March 2021, 36 patients were diagnosed with gastric cancer without esophageal invasion localized in the upper stomach who underwent laparoscopic proximal gastrectomy with mSOFY reconstruction at Japanese Red Cross Wakayama Medical Center and Cancer Center. Cases in which at least two-thirds of the stomach can be preserved after proximal gastrectomy were selected. The maximum length of esophagectomy was 1.5 cm. The characteristics of patients are detailed in Table S1. In the elderly, proximal gastrectomy was also performed in some cases for advanced cancer in order to maintain the postoperative condition.

2.2 | Surgical technique

The surgeon performed the whole process of laparoscopic proximal gastrectomy and reconstruction on the right side of the patient. The stomach was dissected with a line perpendicular to the long axis of the stomach to preserve it as large as possible. The esophagus was dissected by inserting a 45-mm-linear stapler from the right side to the left side of the esophagus. After the esophagus was fully exposed to a length of 5 cm, the bilateral diaphragmatic crus were dissected to enhance gastric elevation, being careful not to open the thoracic cavity. Then a small incision was made in the right side of the esophageal stump and a full-thickness suture was added to prevent mucosal shedding. After confirming that the esophagus overlapped more than 5 cm at the center of the remnant stomach (we call it SOFY check), a small incision was made in the anterior gastric wall, which coincided with the right side of the esophageal stump (the procedure is demonstrated in Video S1). The upper edge of the remnant stomach was fixed to the dissected left and right diaphragmatic crus with two stitches. The abdominal esophagus was pulled sufficiently to the caudal side, and the most proximal dorsal side of the esophagus was sutured to the center of the upper edge of the remnant stomach. Thus, the esophagus and the remnant stomach overlapped by at least 5 cm (Figure 1A; the procedure is demonstrated in Video S2). A 45-mm linear stapler was inserted via the patient's lower right

port and was bent slightly to the left to fit the axis of the esophagus. The forks of the linear stapler were inserted into the esophagus and stomach, and the right-side wall of the esophagus and the remnant stomach were anastomosed by lifting the left side of the esophagus and by rotating it 90° counterclockwise (Figure 1B; the procedure is demonstrated in Video S3). Concurrently, we ensured that the esophagus and the remnant stomach were anastomosed with a total length of 45 mm without shifting. The entry hole was closed with an absorbable barbed suture in a direction that did not widen the anastomotic hole (Figure 1C; the procedure is demonstrated in Video S4). This closure formed a slit-shaped anastomotic hole. The right side of the esophagus, remnant stomach, and right diaphragmatic crus were suture-fixed on the cranial side 1–2 cm away from the anastomosis. Moreover, the left side of the esophagus, remnant stomach, and left diaphragmatic crus were also suture-fixed at a position as high as that at the right side. Three stitches of an absorbable barbed suture were used to fix the left side of the esophagus and the remnant stomach. Hence, the esophagus was stuck flat to the gastric wall (the procedure is demonstrated in Video S5). The staple line of the esophageal stump was then buried sutured with an absorbable barbed suture to complete the reconstruction (Figure 1D; the procedure is demonstrated in Video S6). Reflux is prevented because the preserved posterior wall of the lower esophagus is pressed by the pseudofornix and flattened into a valve shape (Figure 1E).

2.3 | Ethical considerations

This study was conducted in accordance with the Declaration of Helsinki with approval of the Ethics Committee of Japanese Red Cross Wakayama Medical Center (approval no. 872). Informed consent was obtained from all patients.

3 | RESULTS

The surgical outcomes and postoperative complications are summarized in Table 1. The median operation time was 302 (range: 192–467) min and the median reconstruction time was 54 (range: 43–86) min. The volume of estimated blood loss was 10 (range: 10–431) g. The number of retrieved lymph nodes were 30 (range: 8–67). None of the patients had intraoperative complications, and conversion to open surgery was not required. Moreover, 5 (13.9%) of 36 patients presented with grade II or higher postoperative complications based on the Clavien–Dindo classification. However, none of the patients had short-term complications related to intraabdominal infections such as anastomotic leakage and abscess. Patients started drinking water on postoperative d 1 and ate meals on postoperative d 4. The median length of the postoperative hospital stay was 9 d (range: 7–23). Figure 2 shows the findings of gastrographin-enhanced examination performed 4 d after the operation. The anastomotic hole was observed at the right side of the lower esophagus (arrowhead), and inflow of gastrographin from the esophagus to the remnant stomach

TABLE 1 Surgical outcomes and postoperative complications

Surgical outcomes	mSOFY (n = 36)
Operation time (min)	
Median (range)	302 (192–467)
Time for reconstruction (min)	
Median (range)	54 (43–86)
Estimated blood loss (g)	
Median (range)	10 (10–431)
Harvested lymph nodes	
Median (range)	30 (8–67)
Short-term complications	
CD grade II	5 (13.9%)
Intraabdominal abscess	0
Anastomotic leakage	0
Pneumonia	2 (5.6%)
Delirium	1 (2.8%)
Elevation of CRP	1 (2.8%)
Delayed gastric emptying	1 (2.8%)
CD grade IIIa or higher	0
Postoperative hospital stay (d)	
Median (range)	9 (7–23)
Postoperative endoscopic findings (n=28 cases)	
Esophagitis	
LA grade A	2 (7.1%)
LA grade B	2 (7.1%)
LA grade C	1 (3.6%)
LA grade D	0
Reflux symptom	1 (2.8%)
Anastomotic stricture	1 (2.8%)

Abbreviations: CD, Clavien–Dindo classification; LA grade, Los Angeles grade; mSOFY, modified side overlap with fundoplication method.

was extremely good. There was no reflux of gastrographin into the esophagus even when patients were in the head-down tilt position. Twenty-eight patients underwent endoscopy 3–6 mo after surgery, 22 of whom were followed up for more than 1 y after surgery (maximum 3 y). Endoscopic findings showed that the lumen of the abdominal esophagus was flatly closed due to pressure from the remnant stomach on the dorsal side but was easily expanded by air supply. Anastomosis was observed on the right side of the esophageal wall, and the gastroscop was smoothly inserted via the anastomosis. Observation from the stomach confirmed the artificial angle of His and pseudofornix formation (Figure 3A–D). In total, 5 (17.9%) of 28 patients had reflux esophagitis on endoscopy. However, the extent of inflammation in four of five patients was limited to small redness and erosions very close to the anastomotic site (Figure 4) and who did not complain of symptoms. The remaining one patient did not have symptoms of reflux or stenosis for 3 mo after surgery. However, an endoscopist misunderstood that the slit-shaped anastomotic hole

was stenotic and performed endoscopic balloon dilatation. It subsequently caused grade C reflux esophagitis based on the Los Angeles classification,⁸ whose cause was unknown. Endoscopic findings of the patients with good mSOFY did not change during the follow-up period. Twenty-nine of 36 (80.6%) patients were taking some antiulcer drug after surgery.

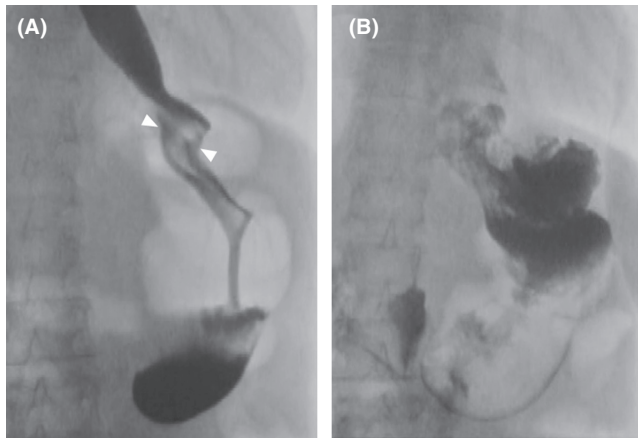


FIGURE 2 Findings of gastrografin-enhanced examination after proximal gastrectomy with mSOFY. A, The anastomotic hole was observed at the right side of the lower esophagus (arrowhead), and the inflow of gastrographin from the esophagus to the remnant stomach was extremely good. B, There was no reflux of contrast medium into the esophagus even when patients were in the head-down tilt position

4 | DISCUSSION

Side overlap with fundoplication by Yamashita (SOFY), which is a novel esophagogastrostomy method after proximal gastrectomy, was developed in 2014 and was introduced in 2017.⁷ This method is relatively easy to perform laparoscopically and may overcome problems such as postoperative reflux and anastomotic stricture. The important points in the SOFY method are that the posterior wall of the esophagus is preserved by anastomosing the left side of the esophagus with the remnant stomach, and that the esophagus is suture-fixed at the center of the remnant stomach. The preserved posterior wall of the esophagus is pressed by the pressure from the pseudofornix, causing the esophagus to be closed flat. This mechanism could then prevent reflux. However, one of the 27 patients who underwent proximal gastrectomy with SOFY reconstruction complained of severe reflux symptom (LA grade D). The cause was a shift of the anastomotic site to the lesser curvature side of the remnant stomach, which caused the esophagus to not be pressed by the pressure of the pseudofornix due to insufficient overlap with the esophagus and the remnant stomach. In the SOFY method, it was considered that the mismatch between the long axis of the stomach and the axis of the linear stapler from the left side of the patient and the axis rotation of the linear stapler caused unstable results.

Thus, the SOFY method has been modified based on several points to achieve more stable treatment outcomes. In the mSOFY method, a linear stapler was inserted from the patient's right side with a slight left flexion without axial rotation, which allows the linear stapler to always be parallel to the long axis of the remnant stomach. Along with this, the anastomotic site was changed from the left side to the right side of the esophagus for simplicity, the esophagus

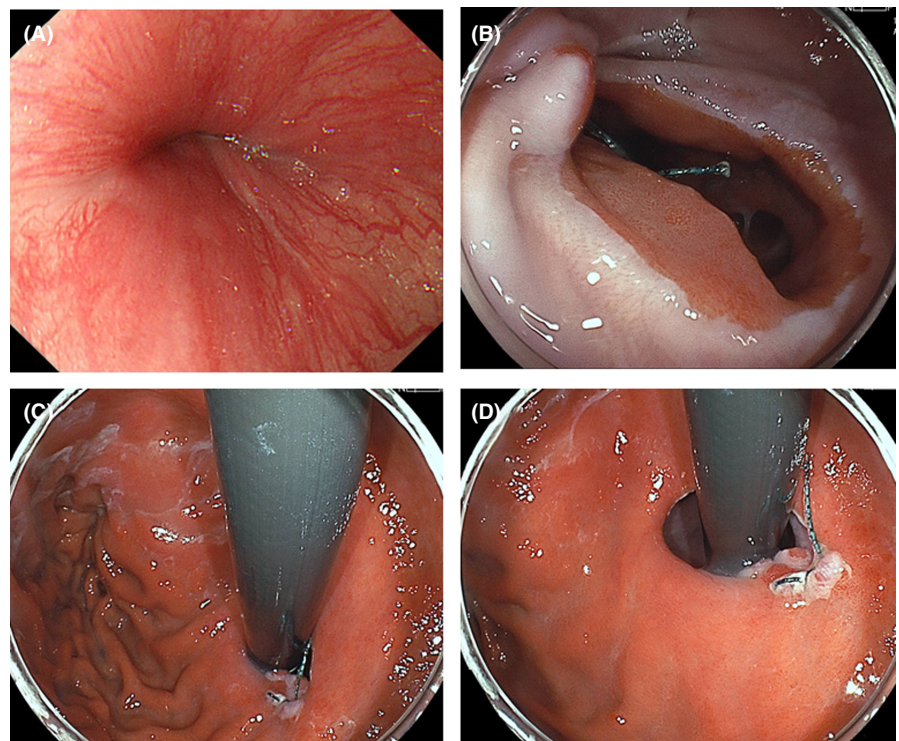


FIGURE 3 Endoscopic findings after proximal gastrectomy with mSOFY reconstruction. A, The lumen of the abdominal esophagus was closed flat due to pressure from the remnant stomach on the dorsal side. B, The abdominal esophagus was easily expanded by air supply, and the anastomosis was observed on the right side of the esophageal wall. C, Endoscopic examination of the stomach revealed the angle of His and formation of a pseudofornix. D, A wide anastomotic hole was found

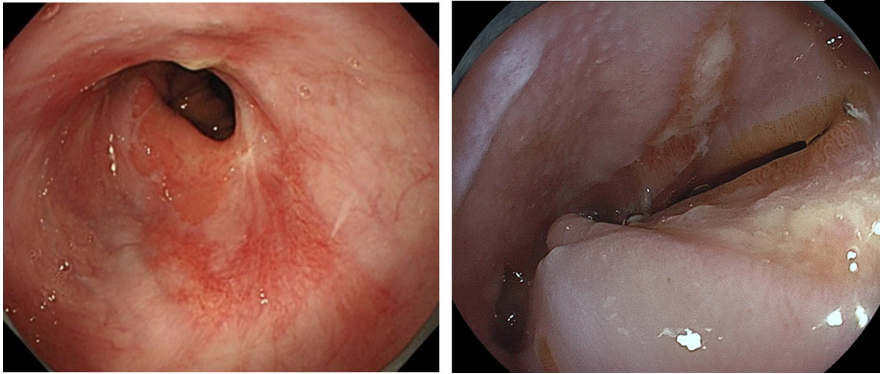


FIGURE 4 Reflux esophagitis after proximal gastrectomy with mSOFY reconstruction. Small erosions or redness are sometimes observed very close to the anastomotic site.

was rotated 90° counterclockwise, and thereby anastomosing the right side of the esophagus to the gastric wall. With this change, the anastomosis can be performed on the planned line, and the esophagus can be always fixed at the center line of the remnant stomach. Next, the left and right diaphragmatic crus were dissected without thoracotomy to enhance stomach elevation. The remnant stomach is further pulled up by 2–3 cm via this process, so intraabdominal mSOFY reconstruction could be performed if the esophageal resection length is within 2–3 cm. The dissected abdominal esophagus is often pulled into the thoracic cavity. However, after its surrounding structures are dissected, it can be slowly stretched back into the abdominal cavity. The final modification was that both sides of the esophagus, 1–2 cm cranial away from the anastomosis, were sutured to the remnant stomach and diaphragmatic crus, which improved the mechanism of reflux prevention.

The mSOFY method has favorable treatment outcomes. In total, 36 patients did not present with intraabdominal infections, such as anastomotic leakage and abscess. Endoscopic findings occasionally revealed small erosions and redness only near the anastomotic site. Nevertheless, all but one patient did not complain of reflux symptoms. The oral rate of proton pump inhibitors was as high as 80.6% because it was continuously prescribed by family doctors, not for improving reflux symptoms.

Precautions should be observed when performing an anastomosis using a linear stapler. That is, the esophagus and remnant stomach must be anastomosed with a total length of 45 mm without shifting. In addition, a slit-shaped anastomotic hole must be made. When the anastomosis is conducted well with a length of 45 mm and the entry hole is sutured closed with a 5-mm-wide seam allowance, the size of the slit-shaped anastomosis will be slightly larger than that of the anastomosis when using a 25-mm circular stapler. Therefore, this method shows a lower incidence of anastomotic stricture than other reports.^{9,10} However, if the anastomosis between the esophagus and the remnant stomach is shifted by 10 mm or more, anastomotic stricture may occur. In such a case, the entry hole must be closed in a direction that can widen it to prevent stricture, which may reduce the ability to prevent reflux. Also, endoscopists may misunderstand that the slit-shaped anastomotic hole is narrow, so it is necessary to inform them about the slit-shaped anastomotic hole in the mSOFY in advance.

Previous reports of laparoscopic esophagogastronomies with an additional antireflux procedures have described the incidence

of reflux esophagitis of 10.0%–42.9% for all LA grades and 6.0%–28.6% for grade B or higher.^{2,11–13} Among the various methods, the incidence of reflux esophagitis in the double-flap technique is lower than that in mSOFY (10.6% vs 17.9% for all grades, 6.0% vs 10.7% for grade B or higher). However, the spread of esophagitis in the mSOFY was limited very close to the anastomotic site, and few patients had reflux symptom. Theoretically, the double-flap technique is considered to have a strong ability of reflux prevention, but anastomotic stricture, which required some balloon dilation, was observed in 4.7%–25.0%.^{5,14–16}

In conclusion, mSOFY can be relatively easily performed laparoscopically and may overcome the problems of postoperative reflux and anastomotic stricture. It can be one of the safe and feasible reconstruction methods after laparoscopic proximal gastrectomy.

However, examination of more cases and longer follow-up are required to further determine the usefulness of mSOFY.

DISCLOSURE

Funding: None.

Conflict of Interest: The authors declare no conflicts of interest for this article.

Author Contributions: Study conception and design: Yamashita, Tatsubayashi, Okumura, Miyamoto, Ueno. Drafting of the article: Yamashita. Critical revision: Tatsubayashi. Final approval for publication: Yamashita, Tatsubayashi, Okumura, Miyamoto, Ueno.

ORCID

Yoshito Yamashita  <https://orcid.org/0000-0002-5291-0765>

REFERENCES

1. Katai H, Sano T, Fukagawa T, Shinohara H, Sasako M. Prospective study of proximal gastrectomy for early gastric cancer in the upper third of the stomach. *Br J Surg*. 2003;90(7):850–3.
2. Sakuramoto S, Yamashita K, Kikuchi S, Futawatari N, Katada N, Moriya H, et al. Clinical experience of laparoscopy-assisted proximal gastrectomy with toupet-like partial fundoplication in early gastric cancer for preventing reflux esophagitis. *J Am Coll Surg*. 2009;209(3):344–51.
3. Ishigami S, Uenosono Y, Arigami T, Kurahara H, Okumura H, Natsugoe S, et al. Novel fundoplication for esophagogastronomy after proximal gastrectomy. *Hepatogastroenterology*. 2013;60(127):1814–6.

4. Okabe H, Obama K, Tanaka E, Tsunoda S, Akagami M, Sakai Y. Laparoscopic proximal gastrectomy with a hand-sewn esophago-gastric anastomosis using a knifeless endoscopic linear stapler. *Gastric Cancer*. 2013;16(2):268–74.
5. Kuroda S, Nishizaki M, Kikuchi S, Noma K, Tanabe S, Fujiwara T, et al. Double-flap technique as an antireflux procedure in esophagogastrostomy after proximal gastrectomy. *J Am Coll Surg*. 2016;223(2):e7–13.
6. Omori T, Moon JH, Yanagimoto Y, Sugimura K, Miyata H, Yano M. Pure single-port laparoscopic proximal gastrectomy using a novel double-flap technique. *Ann Laparosc Endosc Surg*. 2017;2(8):123.
7. Yamashita Y, Yamamoto A, Tamamori Y, Yoshii M, Nishiguchi Y. Side overlap esophagogastrostomy to prevent reflux after proximal gastrectomy. *Gastric Cancer*. 2017;20(4):728–35.
8. Lundell LR, Dent J, Bennett JR, Blum AR, Armstrong D, Wallin L, et al. Endoscopic assessment of oesophagitis: clinical and functional correlates and further validation of the Los Angeles classification. *Gut*. 1999;45(2):172–80.
9. Hosoda K, Washio M, Mieno H, Moriya H, Ema A, Yamashita K, et al. Comparison of double-flap and OrVil techniques of laparoscopy-assisted proximal gastrectomy in preventing gastroesophageal reflux: a retrospective cohort study. *Langenbecks Arch Surg*. 2019;404(1):81–91.
10. Shoji Y, Nunobe S, Ida S, Kumagai K, Ohashi M, Hiki N, et al. Surgical outcomes and risk assessment for anastomotic complications after laparoscopic proximal gastrectomy with double-flap technique for upper-third gastric cancer. *Gastric Cancer*. 2019;22(5):1036–43.
11. Kuroda S, Choda Y, Otsuka S, Ueyama S, Tanaka M, Muraoka A, et al. Multicenter retrospective study to evaluate the efficacy and safety of the double-flap technique as antireflux esophagogastrostomy after proximal gastrectomy (rD-FLAP Study). *Ann Gastroenterol Surg*. 2018;3:96–103.
12. Okabe H, Obama K, Tanaka E, Tsunoda S, Akagami M, Sakai Y. Laparoscopic proximal gastrectomy with a hand-sewn esophago-gastric anastomosis using a knifeless endoscopic linear stapler. *Gastric Cancer*. 2013;16:268–74.
13. Yasuda A, Yasuda T, Imamoto H, Kato H, Nishiki K, Shiozaki H, et al. A newly modified esophagogastrostomy with a reliable angle of His by placing a gastric tube in the lower mediastinum in laparoscopy-assisted proximal gastrectomy. *Gastric Cancer*. 2015;18:850–8.
14. Muraoka A, Kobayashi M, Kokudo Y. Laparoscopy-assisted proximal gastrectomy with the hinged double flap method. *World J Surg*. 2016;40:2419–24.
15. Hayami M, Hiki N, Nunobe S, Mine S, Ohashi M, Yamaguchi T, et al. Clinical outcomes and evaluation of laparoscopic proximal gastrectomy with double-flap technique for early gastric cancer in the upper third of the stomach. *Ann Surg Oncol*. 2017;24:1635–42.
16. Shibasaki S, Suda K, Nakauchi M, Kikuchi K, Kadoya S, Uyama I, et al. Robotic valvuloplastic esophagogastrostomy using double flap technique following proximal gastrectomy: technical aspects and short-term outcomes. *Surg Endosc*. 2017;31:4283–97.

SUPPORTING INFORMATION

Additional supporting information may be found in the online version of the article at the publisher's website.

How to cite this article: Yamashita Y, Tatsubayashi T, Okumura K, Miyamoto T, Ueno K. Modified side overlap esophagogastrostomy after laparoscopic proximal gastrectomy. *Ann Gastroenterol Surg*. 2022;6:594–599. <https://doi.org/10.1002/ags3.12549>