

Unicyclic ameloblastoma of mural variant crossing the midline

ABSTRACT

Unicyclic ameloblastoma (UCA) refers to cystic lesions that show gross features of a jaw cyst but on histologic examination show a typical ameloblastomatous epithelium lining part of the cyst cavity, with or without luminal and/or mural tumor growth. Even though the lesion is not as aggressive as the solid ameloblastoma, an accurate histopathologic diagnosis is essential for the treatment and prognosis. This case report illustrates a case of UCA of mural variant in the anterior region of the mandible crossing the midline, which is usually an unusual site of occurrence.

Keywords: Cyst, expansion, luminal, multilocular, odontogenic

INTRODUCTION

Unicyclic ameloblastoma (UCA) is a less encountered variant of the second most common odontogenic tumor, ameloblastoma. It refers to those cystic lesions that show clinical and radiographic characteristics of an odontogenic cyst but on histologic examination show a typical ameloblastomatous epithelium lining part of the cyst cavity, with or without luminal and/or mural tumor proliferation.^[1] Unicyclic ameloblastoma deserves separate consideration due to its clinical radiographic and pathologic features. This case report illustrates a case of UCA of mural variant in the anterior region of the mandible crossing the midline in a 20-year-old Nigerian female, which is usually an unusual site of occurrence.

CASE REPORT

A 20-year-old Nigerian female reported to the department of oral medicine and radiology with a chief complaint of mobility in the lower front tooth for 3 months, without pain. No history of systemic comorbidities and no extraoral swelling were detected [Figure 1]. On inspection, no intraoral swelling was seen, and on palpation, slight buccal cortical expansion was felt in relation to 41, 31, 32 and retained 73. 33 was missing and Grade II mobility of 31, 32, 41,

and 73 was seen, no paresthesia of the lower lip present indicating noninvolvement of terminal branches of inferior alveolar nerve; orthopantomogram revealed a well-defined multilocular mixed radiolucent radiopaque lesion extending from the left parasymphiseal region of the mandible in relation to the apices of 35 crossing the midline to the right parasymphiseal region in relation to apices of 42, measuring about 4 cm × 2 cm causing displacement of the 33 toward the base of the mandible with scalloped superior border associated with root resorption with respect to 35, 34, 73, 32, and 31. Septations were seen in the inferior border [Figure 2]. Radiopaque mass was seen 4 mm below the apices of 73, giving an impression of odontome. Cone-beam computed tomography revealed expansion of the buccal and lingual cortical bones with severe thinning which had breached the labial cortex [Figure 3]. On the basis of clinical

LEENA JAMES, ADIL SHAFATH, TEJAVATHI NAGARAJ, ARUNDHATI BISWAS

Department of Oral Medicine and Radiology, Sri Rajiv Gandhi College of Dental Sciences, Bengaluru, Karnataka, India

Address for correspondence: Dr. Arundhati Biswas, Department of Oral Medicine and Radiology, Sri Rajiv Gandhi College of Dental Sciences, Bengaluru - 560 032, Karnataka, India. E-mail: arundhatibds@gmail.com

Received: 31 March 2019, **Revised:** 30 June 2019, **Accepted:** 15 September 2019, **Published:** 26 May 2022

Access this article online

Website:
www.njms.in

DOI:
10.4103/njms.NJMS_21_19

Quick Response Code



This is an open access journal, and articles are distributed under the terms of the Creative Commons Attribution-NonCommercial-ShareAlike 4.0 License, which allows others to remix, tweak, and build upon the work non-commercially, as long as appropriate credit is given and the new creations are licensed under the identical terms.

For reprints contact: WKHLRPMedknow_reprints@wolterskluwer.com

How to cite this article: James L, Shafath A, Nagaraj T, Biswas A. Unicyclic ameloblastoma of mural variant crossing the midline. *Natl J Maxillofac Surg* 2022;13:S199-202.

and radiographic characteristics, provisional diagnosis of UCA with differential diagnoses of odontogenic myxoma and dentigerous cyst was given. After routine investigations, aspiration biopsy was performed to evaluate the contents of the swelling, mainly to exclude the possibility of a vascular lesion. Following this an incisional biopsy was performed under local anesthesia, and the specimen was sent for histological evaluation. Histopathological report confirmed the provisional diagnosis of a UCA, which was a mural variant. The patient was advised a surgical line of management with informed consent and a preanesthetic evaluation, which included buccal decortication with enucleation of the cyst, followed by application of Carnoy's solution and a peripheral osteotomy, which was performed under nasotracheal intubation with the extraction of impacted canine along with 31,32,73 under general anesthesia to

reduce the risk of recurrence [Figures 4 and 5]. The specimen was sent for histopathological evaluation, which confirmed the diagnosis of UCA. The patient has been followed up for 6 months, with no clinical or radiographic evidence of recurrence [Figures 6 and 7].

DISCUSSION

Ameloblastoma is the second most common odontogenic tumor,^[2] and 80% of all cases occur in the molar-ramus region. The term ameloblastoma was coined by Churchill in 1934. Almost up to 15 variants of this tumor are recorded till date.^[3] UCA is one of the variants.

UCA was first defined by Robinson and Martinez in 1977.^[4] The frequency of these tumors is reported to be between 5% and 22% of all types of ameloblastomas.^[5] An age-old debate for the pathogenesis of this lesion still prevails. The following three mechanisms have been proposed for the development of the UCA:^[6]

1. The reduced enamel epithelium of a developing tooth undergoes ameloblastic transformation with subsequent cystic development
2. Ameloblastomas arise in dentigerous or other types of odontogenic cysts
3. Solid ameloblastoma undergoes cystic degeneration.

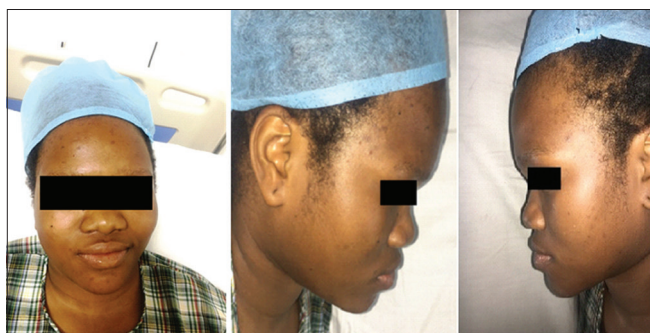


Figure 1: Preoperative extraoral photograph

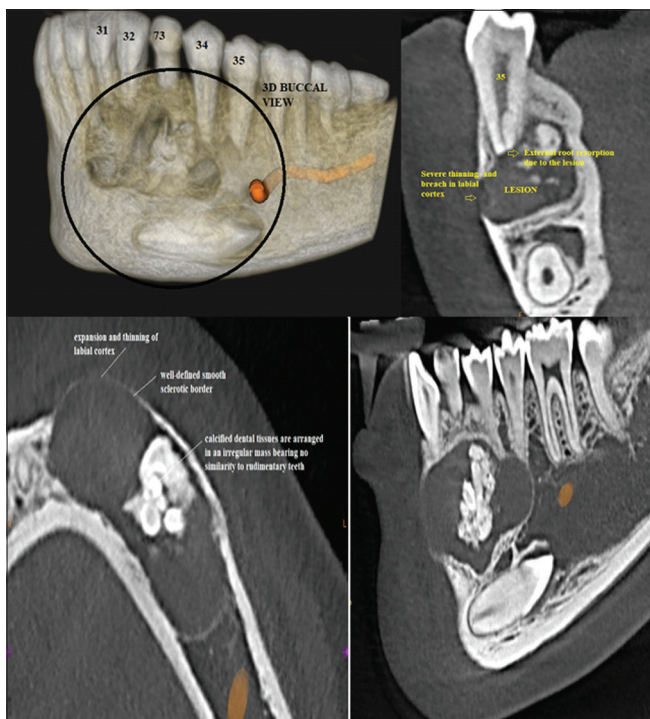


Figure 3: Computed tomography scan with three-dimensional reconstruction, coronal, axial, and sagittal view

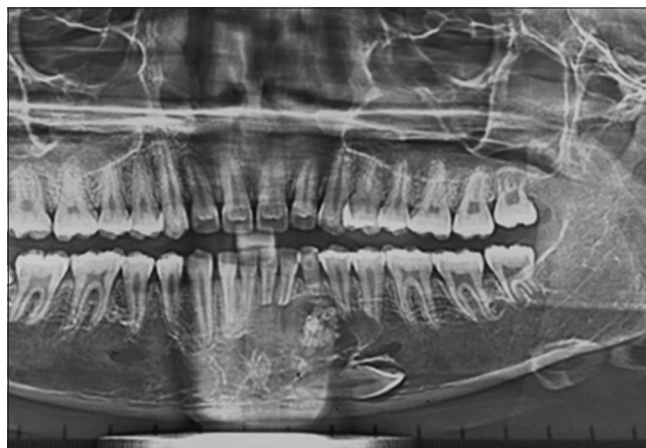

Figure 2: Cropped orthopantomograph radiograph

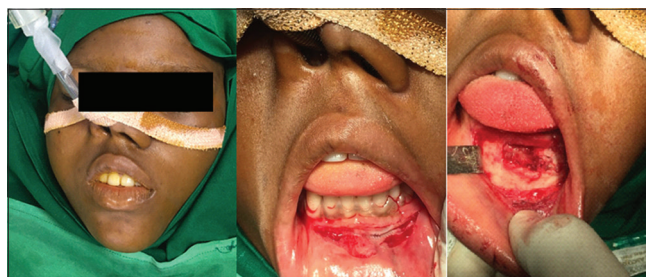

Figure 4: Intraoperative photograph: Nasotracheal intubation, incision, and periosteal flap elevation

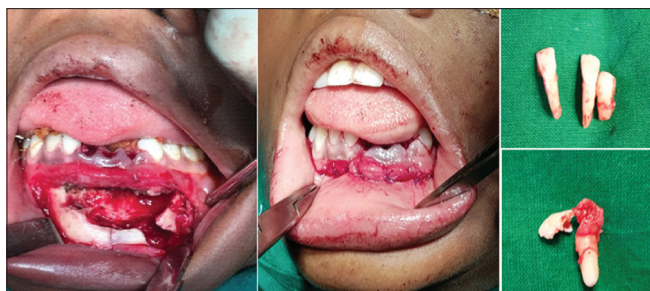

Figure 5: Intraoperative photograph: Buccal decortication with enucleation, extraction of 31, 32, 73, and impacted 33

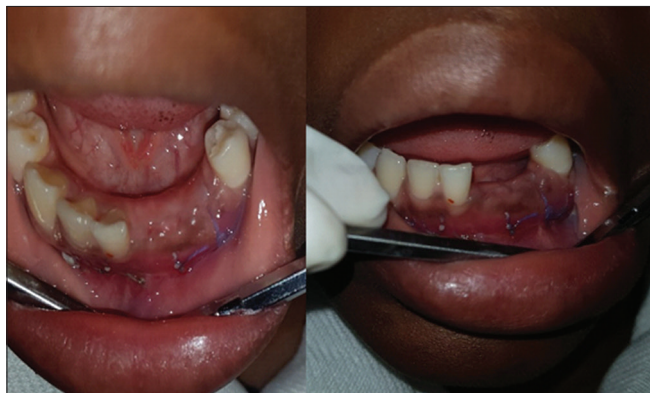

Figure 6: Postoperative photograph

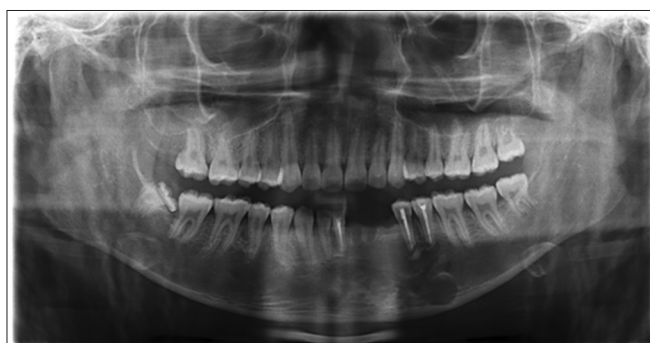

Figure 7: Postoperative orthopantomogram

UCA is a slow-growing, persistent, and locally invasive lesions, which may lead to bone deformation.^[7] These expansile lesions exhibit well-defined radiolucent areas, which are surrounded by corticated borders, mainly in the posterior region of the mandible.^[8] In this report, a multilocular mixed radiolucent lesion was seen in the mandibular anterior region causing root resorption, which deviates from the usual descriptions for this type of lesions in the literature. UCA may present three histological variants, where the luminal subtype of the tumor is confined to the luminal surface of the cyst and the cystic wall is totally or partially lined by ameloblastic epithelium; the intraluminal variant presents ameloblastoma nodules protruding into the lumen of the cyst, and finally, in the third variant, known as mural, wherein the cystic wall is infiltrated by ameloblastomatous epithelium in the connective

tissue wall without involving the entire epithelium.^[8,9] The histologic criteria for diagnosing a UCA include a cyst lined by ameloblastic epithelium with a tall columnar basal layer, subnuclear vacuoles, reverse polarity of the hyperchromatic nucleus, and a thin layer of edematous, degenerating, stellate reticulum-like cells on the surface.^[10] Histological characteristics described on the excised specimen of the present case are compatible with the mural variant. Despite there being a consensus to treat ameloblastomas radically to prevent recurrence,^[7] still it is worth-mentioning enucleation, marsupialization followed by chemical cauterization, also cryotherapy, decompression, peripheral osteotomy, and rare cases block resection regarding its management.^[7] Treatment approach was selected for the presented case herein, where enucleation of the cyst was followed by an application of Carnoy's solution and peripheral osteotomy, to minimize the risk of recurrence. The patient has been followed up for 6 months without evidence of relapse.

CONCLUSION

UCA should be differentially diagnosed from odontogenic cysts as the former has a high rate of recurrence. Timely intervention for ameloblastoma with conservative surgery combined with local adjuvants such as Carnoy's solution, peripheral osteotomy, and extraction of the associated teeth should be the foremost treatment option for ameloblastoma in young patients. This kind of approach is associated with positive outcomes esthetically, psychologically, and functionally when compared to major resections.

Declaration of patient consent

The authors certify that they have obtained all appropriate patient consent forms. In the form the patient(s) has/have given his/her/their consent for his/her/their images and other clinical information to be reported in the journal. The patients understand that their names and initials will not be published and due efforts will be made to conceal their identity, but anonymity cannot be guaranteed.

Financial support and sponsorship

Nil.

Conflicts of interest

There are no conflicts of interest.

REFERENCES

1. Li TJ, Wu YT, Yu SF, Yu GY. Unicystic ameloblastoma: A clinicopathologic study of 33 Chinese patients. *Am J Surg Pathol* 2000;24:1385-92.
2. Rajendran R, Sivapathasundharam B. *Shafer's Textbook of Oral Pathology*. 5th ed. New Delhi: Elsevier; 2007. p. 381-90.

3. Reichart PA, Philipsen HP. Odontogenic Tumours and Allied Lesions. 1st ed. New Delhi: Quintessence Publishing; 2004. p. 77-86.
4. Robinson L, Martinez MG. Unicystic ameloblastoma: A prognostically distinct entity. *Cancer* 1977;40:2278-85.
5. Reichart PA, Philipsen HP, Sonner S. Ameloblastoma: Biological profile of 3677 cases. *Eur J Cancer B Oral Oncol* 1995;31B: 86-99.
6. Leider AS, Eversole LR, Barkin ME. Cystic ameloblastoma. A clinicopathologic analysis. *Oral Surg Oral Med Oral Pathol* 1985;60:624-30.
7. Meshram M, Sagarka L, Dhuvad J, Anchlia S, Vyas S, Shah H, *et al.* Conservative management of unicystic ameloblastoma in young patients: A prospective single-center trial and review of literature. *J Maxillofac Oral Surg* 2017;16:333-41.
8. Filizzola AI, Bartholomeu-dos-Santos TC, Pires FR. Ameloblastomas: Clinicopathological features from 70 cases diagnosed in a single oral pathology service in an 8-year period. *Med Oral Patol Oral Cir Bucal* 2014;19:e556-61.
9. Ghattamaneni S, Nallamala S, Guttikonda VR. Unicystic ameloblastoma in conjunction with peripheral ameloblastoma: A unique case report presenting with diverse histological patterns. *J Oral Maxillofac Pathol* 2017;21:267-72.
10. Braunshtein E, Vered M, Taicher S, Buchner A. Clear cell odontogenic carcinoma and clear cell ameloblastoma: A single clinicopathologic entity? A new case and comparative analysis of the literature. *J Oral Maxillofac Surg* 2003;61:1004-10.