



# The usefulness of ultrasound-guided coarse needle aspiration in carotid arteries for diagnosis of carotid arteritis: probing of the vascular margin

Ling Zhao<sup>1,2#</sup>, Yong Zhou<sup>3#</sup>, Qian Yu<sup>4</sup>, Yue Can<sup>2</sup>, Buyun Ma<sup>2^</sup>

<sup>1</sup>Department of Ultrasound, Chinese People's Liberation Army 63820 Hospital, Mianyang, China; <sup>2</sup>Department of Ultrasound, West China Hospital of Sichuan University, Chengdu, China; <sup>3</sup>Department of Ultrasound, The Third Hospital of Changsha, Changsha, China; <sup>4</sup>Department of Ultrasound, Leshan Hospital of Traditional Chinese Medicine, Leshan, China

#These authors contributed equally to this work.

*Correspondence to:* Buyun Ma, PhD. Department of Ultrasound, West China Hospital of Sichuan University, 37 Guoxue Alley, Wuhou District, Chengdu 610041, China. Email: ws\_mby@163.com.

Submitted Mar 19, 2023. Accepted for publication Sep 11, 2023. Published online Oct 20, 2023.

doi: 10.21037/qims-23-350

**View this article at:** <https://dx.doi.org/10.21037/qims-23-350>

## Introduction

We report a case of ultrasound-guided coarse needle (using a Bard magnum with an 18-G needle; C. R. Bard, Inc., Murray Hill, NJ, USA) aspiration of the carotid arteries in the diagnosis of carotid arteritis, presenting a challenge to existing imaging diagnosis. There are currently only a few reports on its use as a diagnostic tool. Both contrast-enhanced magnetic resonance imaging (CE-MRI) and contrast-enhanced ultrasound (CEUS) showed wall enhancement in the right common carotid artery. Pathological diagnosis revealed chronic inflammation with fibrous tissue proliferation. Finally, with the medical history and pathological findings considered, the cervical mass was consistent with the diagnosis of carotid arteritis. Therefore, ultrasound-guided coarse needle aspiration may be a useful complementary tool for diagnosing carotid arteritis, especially in cases of atypical arteritis in the carotid arteries.

Carotid arteritis is a sterile inflammatory reaction of the common carotid artery and its branches. It is a carotid syndrome dominated by vascular pain. It is a systemic vasculitis of unknown cause, resulting in aneurysmal changes, lumen stenosis or occlusion, and other problems in the diseased vessels. Since multiple vessels are often

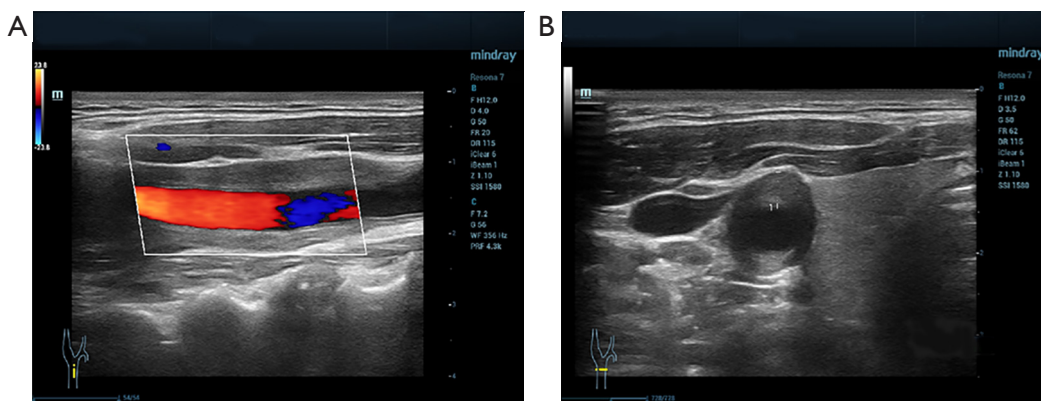
involved, its clinical manifestations are different, and it is difficult to diagnose clinically at the initial stage (1,2). The clinical manifestations of carotid arteritis are complex and diverse, mainly including neck pain, tenderness upon slight pressure, and aggravation when swallowing, which can radiate to the back of the ear. A non-specialized sonographer lacks sufficient experience to diagnose carotid arteritis; the atypical laboratory indicators and clinical manifestations also contribute to easy misdiagnosis. Below we report a case of carotid artery inflammatory disease diagnosed by ultrasound-guided thick needle puncture in West China Hospital.

## Case presentation

All procedures performed in this study were in accordance with the ethical standards of the Ethics Committee of West China Hospital and with the Helsinki Declaration (as revised in 2013). Written informed consent was provided by the patient for the publication of this case report and accompanying images. A copy of the written consent is available for review by the editorial office of this journal.

The patient, a 53-year-old male, presented with

<sup>^</sup> ORCID: 0000-0002-6020-828X.



**Figure 1** Ultrasound. (A) Carotid artery tube cavity filled with blood. (B) Thickened wall of the right common carotid artery to be encased by weak echogenicity.

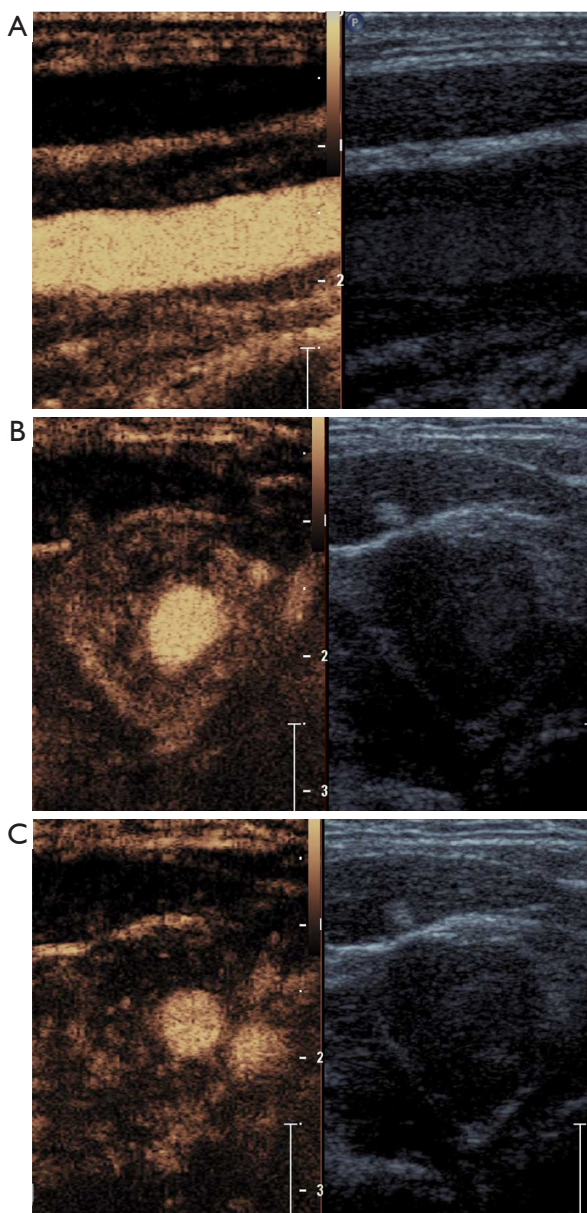
postauricular retraction pain with backward head pitch to the left without obvious incentive that had started 3 months ago, with no dizziness, no melena, and no dysphagia. Special physical examination: the patient had a right-sided curvature of the neck and a palpable 2 cm × 1 cm mass that was soft, mobile, had no obvious tenderness, no obvious prominent skin surface, skin without breakdown and color change, and good neck mobility. The notable results of laboratory tests were as follows (reference values in parentheses): adrenaline, 41 ng/L↓ (54–122 ng/L); noradrenaline, 169 ng/L↓ (272–559 ng/L); fibrinogen, 1.61 g/L↓ (2.0–4.0 g/L); serum cystatin C, 1.21 mg/L↑ (0.51–1.09 mg/L); lymphocyte absolute,  $3.48 \times 10^9/L \uparrow$  ( $1.1 \times 10^9/L$ – $3.2 \times 10^9/L$ ). The remaining laboratory tests, such as erythrocyte sedimentation rate (ESR) and C-reactive protein (CRP), were within normal ranges. Carotid ultrasound revealed a hypoechoic mass approximately 84 mm × 18 mm × 14 mm in size within the sheath of the right common carotid artery, which wrapped the common carotid artery and the proximal segment of the internal and external carotid arteries, and punctate blood flow signal was observed within it (*Figure 1*); CEUS showed heterogeneous hyperenhancement (*Figure 2*). The ultrasound-based diagnosis of the right carotid sheath lesion was xanthoma. Contrast-enhanced computed tomography (CECT) of the head and neck vessels revealed soft tissue density surrounding the right common carotid artery with shadow wrapping, light-to-moderate enhancement, inflammatory changes in the vessel wall, or fibrosis (*Figure 3*). Computed tomography angiography (CTA) of the carotid artery showed that the surrounding soft tissue density around the right common carotid artery had surrounded the vessel, resulting in mild stenosis of its lumen (*Figure 4*). CE-MRI revealed isointense

T1 and isointense slightly longer T2 signal circularity was seen around the terminal bifurcation of the right common carotid artery; the enhancement scan showed annular enhancement of the right common carotid artery lesion, which made the presence neoplastic lesions (carotid body aneurysms) more likely, or common carotid artery intimal hyperplasia (*Figure 5*). The findings of echocardiography were indicative of micro regurgitation of the aortic valve, with no obvious abnormalities in the proximal segment of descending part of the aortic arch.

Based on the CE-MRI and CEUS findings, a biopsy can provide more information to assist diagnostic decisions. We communicated with the patient about the advantages, risks, and management of complications of puncture. The patient actively requested an ultrasound-guided puncture biopsy, so we chose an ultrasound-guided puncture biopsy in the principle of maximizing the interests of the patient.

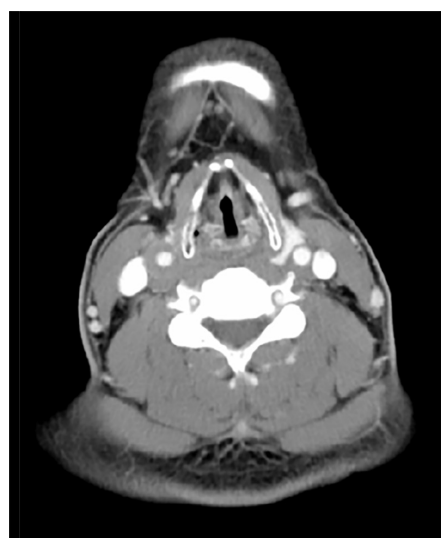
Before performing a carotid puncture, we considered associated risks such as carotid pseudoaneurysm, carotid rupture, dissection, intramural hematoma, hemorrhage, nerve palsy, or paralysis. We performed a comprehensive evaluation of the patient before surgery, including 2-dimensional ultrasound to evaluate the size and location of the lesion, color Doppler ultrasound to evaluate the blood flow of the lesion, and CEUS to evaluate the perfusion of the lesion, and we found that ultrasound-guided carotid artery puncture biopsy was feasible for this patient. An experienced chief physician carried out the puncture.

Preparation before puncture included blood routine, coagulation function, electrocardiogram, a full set of auxiliary examinations before blood transfusion, ABO

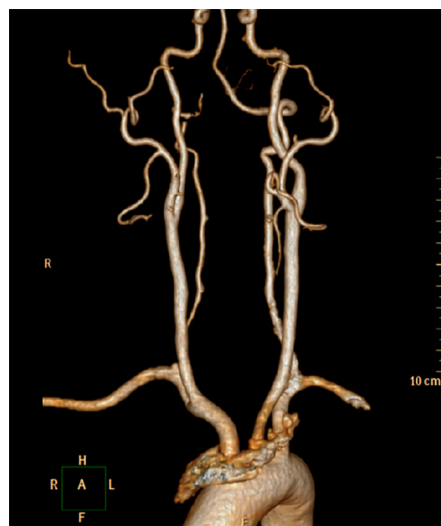

**Figure 2** Contrast-enhanced ultrasound. (A) Heterogeneously low enhancement at 5 s. (B) Heterogeneously low enhancement at 15 s. (C) Heterogeneously low enhancement at 30 s.

blood group + Rh blood group, patient counselling, signing consent, and the preparation of rescue equipment. The puncture process was as follows: on the right side of the neck, the puncture area was sterilized, a sterile towel was spread, and the ultrasound probe was wrapped in a sterile protective sleeve. For local anesthesia, 0.5 mL of 2% lidocaine was used. Under the guidance of ultrasound, the needle (18-G) was placed in front of the hypoechoic

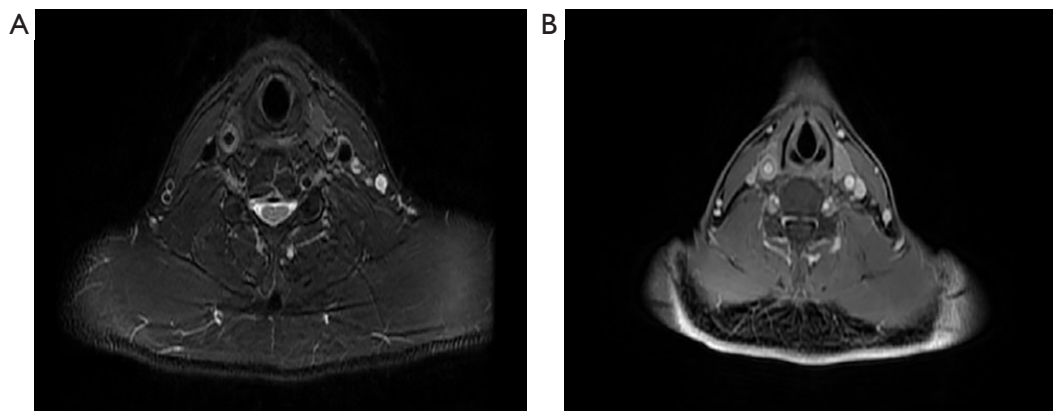


**Figure 3** On contrast-enhanced computed tomography, the wall of the right common carotid artery was thickened.

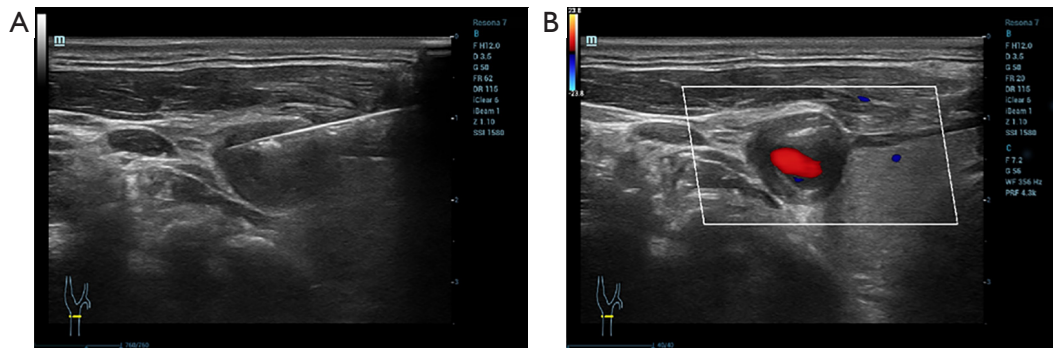


**Figure 4** Computed tomography angiography showed mild stenosis of the right common carotid artery lumen.

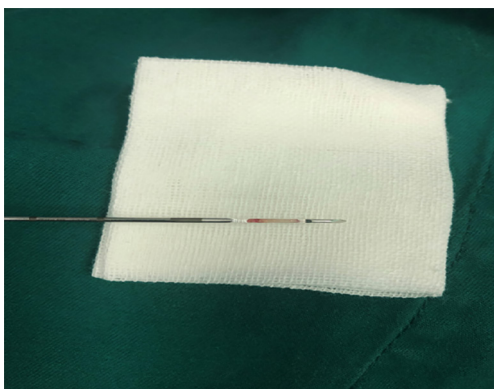
mass in the common carotid artery, and the needle tip was close to the lesion. Care was taken to avoid too small or parallel angles. The needle was not oriented toward the lumen of the carotid artery, and 3 tissues were obtained by 3 punctures under ultrasound monitoring. At the end of the puncture, the puncture area was observed, no obvious bleeding and surrounding tissue damage were observed, and the area was then sterilized, wrapped, and pressurized.



**Figure 5** Magnetic resonance imaging. (A) A fat suppression in magnetic resonance imaging showed thickening of the canal wall of the right common carotid artery. (B) Contrast-enhanced magnetic resonance imaging showed the right common carotid artery wall thickening and strengthening obviously.



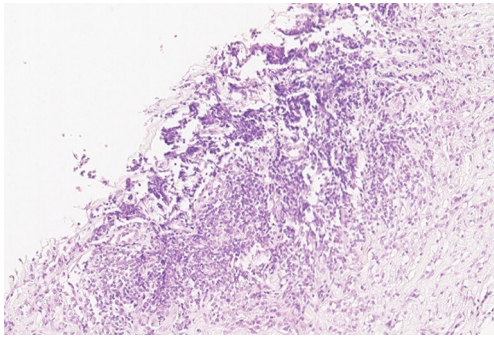
**Figure 6** Ultrasound-guided by the right common carotid artery mass biopsy. (A) During puncture. (B) After puncture.



**Figure 7** The tissue strips are perforated under ultrasound guidance.

Continuous ultrasound monitoring of the puncture site was conducted and recorded at 1-, 4-, 8-, and 24-hour to confirm that there was no pseudoaneurysm, hematoma, carotid artery dissection, and other complications, and that the patient did not experience any discomfort.

The patient underwent ultrasound-guided coarse-needle aspiration biopsy (*Figure 6*), and 2 pieces of gray and white tissue were removed by needle aspiration (*Figure 7*). Hematoxylin and eosin staining showed mainly lymphocytic infiltration, interspersed foreign body giant cells, plasma cells, and fibrous tissue hyperplasia. Pathological diagnosis suggested chronic inflammation with fibrous tissue proliferation (*Figure 8*). Finally, combined with the medical history and pathological findings, the cervical mass was consistent with the diagnosis of Carotid arteritis (a nonspecific inflammation that occurs temporarily in the carotid arteries), which changed the therapeutic prescription



**Figure 8** Pathological examination of the carotid sheath showed chronic inflammation with fibrous tissue proliferation (hematoxylin and eosin staining,  $\times 20$ ).

from surgery to medication. After being administered oral steroids, the patient's symptoms showed significant improvements over time. Upon 1-year follow-up, it was observed that the pain had decreased significantly and disappeared completely without any resulting neurological deficits.

## Discussion

The pathogenesis of carotid arteritis is not fully defined, and there may be some connection with the immune response *in vivo*, which has a long, slow course and shows progressive aggravation. Patients in the early stage of carotid arteritis mostly present with periarteritis, adventitia of the artery, and as the disease develops, it can progress to the tunica media and intima of the vessel, and a large number of lymphocytic infiltrates, plasma cell infiltrates, and diffuse fibrous tissue proliferation can be observed in all layers of the affected artery, resulting in different degrees of stenosis in the arterial vessel, which is highly susceptible to thrombosis, causing luminal occlusion and seriously endangering human health (3,4). The correct diagnosis of carotid arteritis is difficult, and it is prone to missed diagnosis and misdiagnosis.

Histopathology of the vasculopathy is usually obtained after surgical intervention (revascularization or temporal artery biopsy because of treatment), with disease studies even derived from autopsy. A few cases have been reported in which a percutaneous intravascular biopsy technique (5-7) was performed. At present, there are few reports on ultrasound-guided puncture of carotid endarterectomy in China and internationally, and there are certain difficulties and challenges. The size of the mass influences the decision

to perform a biopsy. If the mass is too small, it may cross the carotid artery, enter the lumen, or cut the intima of the carotid artery, causing massive bleeding, or the sample size may not be sufficient to meet the needs of pathological diagnosis.

Ustymowicz *et al.* reported a case of carotid artery dissection complications caused by blind puncture of lymph nodes near the carotid artery. They believed that a biopsy near the carotid artery should be performed under imaging monitoring (8). In consultation with the patient, we opted for an ultrasound-guided needle biopsy of the common carotid artery mass, drawing on nonvascular luminal biopsy techniques, to probe the vascular margins.

A plan had been developed to prevent and address common complications. If there is massive bleeding that injures the carotid artery, surgical treatment is needed; if minor bleeding occurs, local pressure is required to stop bleeding; when pain occurs, the range of local anesthesia is sufficient; it is necessary to control the tip of the puncture needle inside the lesion and not exit the lesion to avoid internal jugular vein injury and carotid artery dissection. The diameter of the puncture needle should be controlled to avoid excessive width of the puncture needle and repeated puncture at the same puncture point, which may cause a pseudoaneurysm. In this case, through the accurate operation, real-time ultrasound monitoring, cooperation of the medical staff involved in the puncture, and cooperation of the patient, the examination of the common carotid artery intima with an 18-G needle under ultrasound guidance was safe. We successfully obtained the pathological tissue and were able to diagnose the carotid artery intimal mass, which provided the basis for subsequent treatment.

Usually, the diagnosis of carotid arteritis is made on the consensus of clinical presentation, elevated inflammatory markers, and imaging studies suggestive of vasculitis involving large-to-medium-sized vessels (9). In this case, laboratory results showed that the ESR and CRP were within the normal range; Li (10) reported that vascular inflammation and injury may persist in carotid arteritis patients with normal inflammatory markers such as CRP and ESR. In this case report, the laboratory indicators and clinical manifestations were not typical, CE-MRI and CEUS revealed the wall enhancement in the right common carotid artery and these characteristics did not conform to the existing diagnostic criteria of vasculitis (11). Therefore, this may be atypical carotid arteritis, which is prone to missed diagnosis and misdiagnosis clinically. This case demonstrated that ultrasound-guided coarse needle

aspiration may be a useful complementary tool for the diagnosis of various manifestations of arteritis especially the atypical arteritis in carotid arteries.

The patient was admitted to the hospital with a right carotid body tumor and a local mass in the neck; a carotid intima-media needle biopsy was performed in this case, which ruled out xanthoma and space-occupying lesions, and the treatment plan was subsequently adjusted. Suljić *et al.* reported that in an era of genetic studies, the identification of microRNAs (miRNA) associated with arteritis can help to develop new therapies based on miRNA (12). We look forward to adding more cases to further investigate the association between gene detection and promote the development of disease treatment.

Ultrasound needle biopsy of arterial vessels is still in an exploratory stage, and there are no case reports. The location of the common carotid arteries is superficial, and ultrasound-guided needle biopsy is one method that can be attempted in cases with significant vessel wall thickening and poor blood flow. Precise ultrasound monitoring, which can obtain lesions close to the tunica adventitia in the vessel wall without damaging the intima, is less traumatic to the vessel, poses less risk of both embolus formation and bleeding, and safely and rapidly obtains histopathological diagnosis. As there is no evidence from a large number of cases, it cannot be ruled out that the technique may have the risk of forming intramural hematomas, and because of the choice of the puncture site, full vessel wall information cannot be obtained, so the pathologic value remains to be discussed.

In conclusion, ultrasound-guided carotid artery wall biopsy provides a new method for clinical diagnosis and treatment of arterial diseases, and its safety and effectiveness need further research.

## Acknowledgments

*Funding:* None.

## Footnote

*Conflicts of Interest:* All authors have completed the ICMJE uniform disclosure form (available at <https://qims.amegroups.com/article/view/10.21037/qims-23-350/coif>). The authors have no conflicts of interest to declare.

*Ethical Statement:* The authors are accountable for all aspects of the work in ensuring that questions related

to the accuracy or integrity of any part of the work are appropriately investigated and resolved. All procedures performed in this study were in accordance with the Ethics Committee of West China Hospital and with the Helsinki Declaration (as revised in 2013). Written informed consent was provided by the patient for the publication of this case report and accompanying images. A copy of the written consent is available for review by the editorial office of this journal.

*Open Access Statement:* This is an Open Access article distributed in accordance with the Creative Commons Attribution-NonCommercial-NoDerivs 4.0 International License (CC BY-NC-ND 4.0), which permits the non-commercial replication and distribution of the article with the strict proviso that no changes or edits are made and the original work is properly cited (including links to both the formal publication through the relevant DOI and the license). See: <https://creativecommons.org/licenses/by-nc-nd/4.0/>.

## References

1. Zhang X, Li H. Analysis of one case of carotid artery inflammation misdiagnosed as subacute thyroiditis. *Anhui Medical and Pharmaceutical Journal* 2017;21:1076-8.
2. Dong Y, Wang Y, Wang Y, Tian X, Li J, Yang Y, Ge Z, Zhang L, Zou M, Wang H, Li J. Ultrasonography and contrast-enhanced ultrasound for activity assessment in 115 patients with carotid involvement of Takayasu arteritis. *Mod Rheumatol* 2023;33:1007-15.
3. Gornik HL, Creager MA. Aortitis. *Circulation* 2008;117:3039-51.
4. Gao H. Clinical analysis of 120 cases of carotid arteritis. *Jilin Medical Journal* 2011;32:5762.
5. Singh V, Naik S, Robert J, Phadke RV, Agarwal V, Bhoi SK. Endovascular biopsy in Takayasu arteritis. *Eur J Rheumatol* 2019;6:155-7.
6. Morrissey NJ, Goldman J, Fallon JT, Faries PL, Marin ML, Hollier LH. Endovascular aortic biopsy in the diagnosis of takayasu arteritis. *J Endovasc Ther* 2003;10:136-40.
7. Lee SA, Plett SK, Luetkemeyer AF, Borgo GM, Ohliger MA, Conrad MB, Cookson BT, Sengupta DJ, Koehler JE. Bartonella quintana Aortitis in a Man with AIDS, Diagnosed by Needle Biopsy and 16S rRNA Gene Amplification. *J Clin Microbiol* 2015;53:2773-6.
8. Ustymowicz A, Guzińska-Ustymowicz K, Kordecki K, Lewszuk A, Krejza J. Carotid artery dissection - an

- important complication after fine-needle aspiration biopsy. *Med Sci Monit* 2004;10 Suppl 3:120-2.
9. Yadava S, Arafa F, Shepherd Z. Takayasu's Disease With Bilateral Carotid Arteritis in a Caucasian Female: A Rare Presentation and Diagnostic Dilemma. *Cureus* 2021;13:e19376.
  10. Li Z. Clinical characteristics and disease activity screening of Takayasu's arteritis. Air Force Military Medical University; 2019.
  11. Fukuma K, Kowa H, Nakayasu H, Nakashima K. Atypical Arteritis in Internal Carotid Arteries: A Novel Concept of Isolated Internal Carotid Arteritis. *Yonago Acta Med* 2016;59:248-54.
  12. Suljić A, Hočevár A, Jurčić V, Bolha L. Evaluation of Arterial Histopathology and microRNA Expression That Underlie Ultrasonography Findings in Temporal Arteries of Patients with Giant Cell Arteritis. *Int J Mol Sci* 2023;24:1572.

**Cite this article as:** Zhao L, Zhou Y, Yu Q, Can Y, Ma B. The usefulness of ultrasound-guided coarse needle aspiration in carotid arteries for diagnosis of carotid arteritis: probing of the vascular margin. *Quant Imaging Med Surg* 2023;13(12):8839-8845. doi: 10.21037/qims-23-350