



ELSEVIER

Contents lists available at ScienceDirect

JSES International

journal homepage: [www.jsesinternational.org](http://www.jsesinternational.org)

## Influence of glenoid wear pattern on glenoid component placement accuracy in shoulder arthroplasty



Kevin A. Hao, BS<sup>a</sup>, Christopher D. Sutton, MD<sup>b</sup>, Thomas W. Wright, MD<sup>b</sup>,  
Bradley S. Schoch, MD<sup>c</sup>, Jonathan O. Wright, MD<sup>b</sup>, Aimee M. Struk, MEd, ATC<sup>b</sup>,  
Edward T. Haupt, MD<sup>c</sup>, Thiago Leonor, BS<sup>d</sup>, Joseph J. King, MD<sup>b,\*</sup>

<sup>a</sup>College of Medicine, University of Florida, Gainesville, FL, USA

<sup>b</sup>Department of Orthopaedics & Rehabilitation, University of Florida, Gainesville, FL, USA

<sup>c</sup>Department of Orthopaedic Surgery, Mayo Clinic, Jacksonville, FL, USA

<sup>d</sup>Inverted TEA LLC, Gainesville, FL, USA

### ARTICLE INFO

#### Keywords:

Shoulder replacement  
Planning  
Inclination  
Navigation  
Walch classification  
Error  
Arthroplasty  
Outliers

Level of evidence: Level IV; Case Series;  
Treatment study

**Background:** Accurate glenoid component placement in shoulder arthroplasty is often difficult even with the use of preoperative planning. Computer navigation and patient-specific guides increase component placement accuracy, but which patients benefit most is unknown. Our purpose was to assess surgeons' accuracy in placing a glenoid component in vivo using 3-dimensional preoperative planning and standard instruments among various glenoid wear patterns.

**Methods:** We conducted a retrospective review of 170 primary anatomic total shoulder arthroplasty (aTSA) and reverse total shoulder arthroplasty (rTSA) performed at a single institution. Commercially available preoperative planning software was used in all arthroplasties with multiplanar 2-dimensional computed tomography and a 3-dimensional implant overlay. After registration of intraoperative bony landmarks to the navigation system, participating surgeons with knowledge of the preoperative plan were blinded to the computer screen and attempted to implement their preoperative plan by simulating placement of a central-axis glenoid guide pin. Two hundred thirty-three screenshots of surgeon's simulated guide pin placement were included. Glenoid displacement, error in version and inclination, and overall malposition from the preoperatively planned target point were stratified by posterior wear status (with [Walch B2 or B3] or without [A1, A2, or B1]) and Walch classification (A1, A2, B1, B2, or B3). The glenoid component was considered malpositioned when version or inclination errors exceeded 10° or the starting point displacement exceeded 4 mm.

**Results:** For rTSA, errors in version were greater for glenoids with posterior wear compared with those without (8.1° ± 5.6° vs. 4.7° ± 4.0°;  $P < .001$ ). On post hoc analysis, B2 glenoids had greater version error than A1, A2, and B1 glenoids. A greater proportion of glenoids undergoing rTSA that possessed posterior wear had an error in version >10° compared with those without (31% vs. 8%;  $P < .001$ ). Consequently, glenoids undergoing rTSA with posterior wear were malpositioned at a greater rate compared with those without (73% vs. 53%). In contrast, glenoids undergoing aTSA with and without posterior wear did not differ based on displacement error, version error, inclination error, or malposition occurrence.

**Conclusions:** Posterior glenoid bone loss more commonly resulted in glenoid version errors exceeding 10 degrees and component malposition in rTSA, but not for aTSA. Malposition was still relatively high in patients without significant posterior wear for both aTSA (36%) and rTSA (53%). Surgeons should consider alternate techniques beyond preoperative planning and standard instrumentation when performing shoulder arthroplasty in patients with posteriorly worn glenoids.

Published by Elsevier Inc. on behalf of American Shoulder and Elbow Surgeons. This is an open access article under the CC BY-NC-ND license (<http://creativecommons.org/licenses/by-nc-nd/4.0/>).

The University of Florida Institutional Review Board approved this study (IRB201901040).

\*Corresponding author: Joseph J. King, MD, Orthopaedics and Sports Medicine Institute, University of Florida, 3450 Hull Road, Gainesville, FL, 32611, USA.

E-mail address: [kingjj@ortho.ufl.edu](mailto:kingjj@ortho.ufl.edu) (J.J. King).

<https://doi.org/10.1016/j.jseint.2021.11.021>

2666-6383/Published by Elsevier Inc. on behalf of American Shoulder and Elbow Surgeons. This is an open access article under the CC BY-NC-ND license (<http://creativecommons.org/licenses/by-nc-nd/4.0/>).

Implant positioning is critical to successful total shoulder arthroplasty and remains a significant, surgeon-modifiable risk factor for decreased implant longevity. In anatomic total shoulder arthroplasty (aTSA), placement of the glenoid implant in neutral version leads to less chance of osteolysis and glenoid loosening.<sup>11</sup>

Conversely, retroverted glenoid implants (ie, those with retroversion  $>10^\circ$ ) have been associated with increased rates of component loosening.<sup>5,12,15,23</sup> Similarly, accurate glenoid placement in reverse total shoulder arthroplasty (rTSA) is important to prevent scapular notching, which is associated with poorer patient outcomes.<sup>6,18,22,26</sup>

Commercially available preoperative planning software has become widely adopted with the goal of improved glenoid implant placement in both aTSA and rTSA. Preoperative planning has improved glenoid implant placement even when standard instrumentation is used.<sup>8,14,16,29,36</sup> However, precise placement of glenoid implants *in vivo* remains difficult because of the limited visualization of anatomic landmarks of the scapula during shoulder arthroplasty.<sup>30</sup> To better replicate preoperative plans, 2 primary methods have gained popularity: computer navigation and patient-specific instrumentation. Both of these technologies have demonstrated improved accuracy of glenoid placement.<sup>4,7,10,30,35</sup> However, increased cost, low availability, and lack of proven clinical benefit to patients have remained impediments to uniform adoption. Identifying patient risk factors for implant malposition could enable more selective use of computer navigation and patient-specific instrumentation, thereby benefiting patients at greater risk for implant malposition without burdening patients that would not see significant benefit of additional costs.

In this study, we sought to determine if surgeons' ability to accurately execute their preoperative plan varied based on the native glenoid morphology. We hypothesized that glenoids with posterior wear would be associated with greater malposition of glenoid implants when only 3-dimensional preoperative planning was used *in vivo* during shoulder arthroplasty.

## Methods

A retrospective review of all primary shoulder arthroplasties performed between September 2017 and March 2020 was performed from a single institution. In 2017, 3-dimensional preoperative planning software and intraoperative computer navigation (Equinox Planning App and Exactech GPS; Exactech, Gainesville, FL, USA) were introduced to our practice; subsequently, nearly all primary shoulder arthroplasties, both aTSA and rTSA, performed at our institution used this technology both pre- and intraoperatively. After the introduction of this technology, 4 fellowship-trained shoulder arthroplasty surgeons began to measure and track their individual accuracy at placing the glenoid implant based on their preoperative plan. Procedures for which navigation was unable to be performed or screenshots were not available for analysis were excluded from this study.

### Preoperative planning

Preoperatively, participating surgeons reviewed 2D and 3D computed tomography (CT) scan reconstructions using the preoperative planning software. The software provides 2D multiplanar CT imaging with 3D implant overlay. Participating surgeons (always at least one attending, fellowship-trained shoulder surgeon, sometimes with one or more upper extremity fellows) collaborated to use the planning software to determine appropriate implant placement based on patient-specific glenoid morphology. In all cases, the final decision on implant placement was made by the attending surgeon. In some cases, full-wedge augments were planned for both in aTSA and rTSA based on surgeon discretion. The planned case was then saved and uploaded to the operating room computer navigation unit for use during surgery.

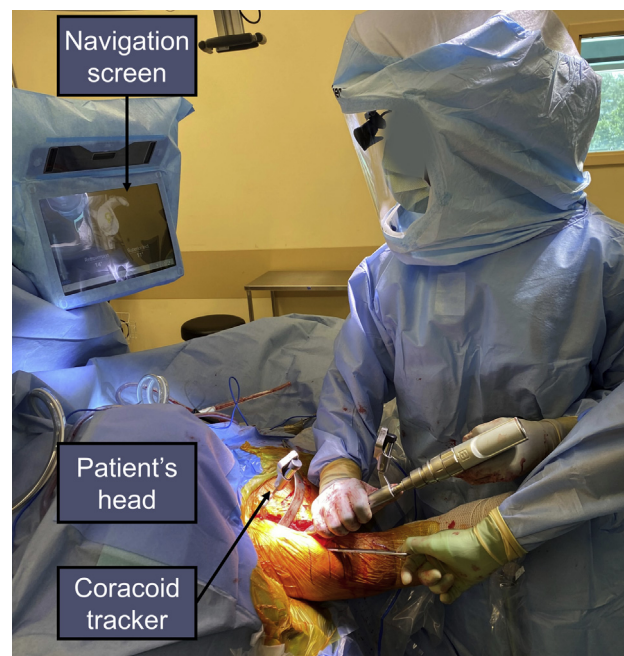

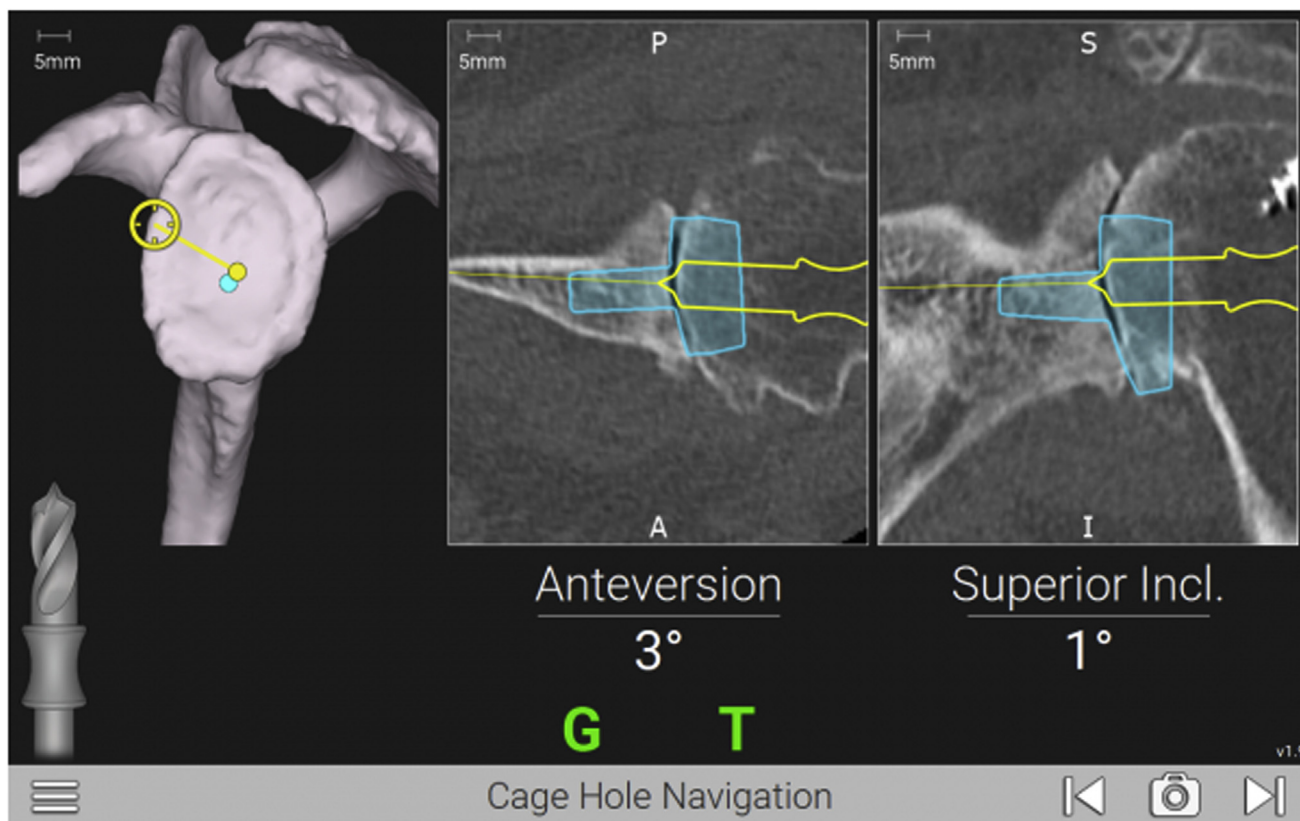
Figure 1 Unblinded navigation.

### Operative technique

All surgical procedures were performed through a deltopectoral approach. The incision was extended proximally approximately 1–2 cm past the coracoid tip to enable complete and adequate exposure for the placement of the coracoid tracker used for computer navigation. Management of the subscapularis was per surgeon preference, with either lesser tuberosity osteotomy or subscapularis peel for aTSA and subscapularis peel or tenotomy for rTSA. The humerus was exposed with extension and external rotation after an inferior capsular release. For aTSA, the head was cut in its native retroversion. For rTSA, the head underwent osteotomy in either  $20^\circ$  of retroversion or its native retroversion, per surgeon preference, using an extramedullary guide. The glenoid was then exposed in a routine fashion. The biceps if present was routinely tenodesed to the pectoralis major tendon, and the remaining proximal stump and labral tissue were removed. Any remaining cartilage was carefully removed using a Cobb elevator. Soft tissue was released off of the anterior glenoid neck. The base of the coracoid was exposed using electrocautery. The coracoacromial ligament was preserved, and the superior aspect of the coracoid was exposed. The tracker stand was then secured in place with 2 screws (eg, see Fig. 1). The glenoid bony surface was registered according to the manufacturer's protocol to link the patient's CT scan and preoperative plan to the visualized anatomy.

### Study protocol

At this point, all surgeons were blinded from viewing the navigation screen. Using standard instruments and visible anatomic landmarks, and with knowledge of the preoperative plan, surgeons attempted to identify the planned starting point for the central cage of the implant, similar to the placement of the central-axis pin used by many shoulder arthroplasty systems. Participating surgeons then aligned the guided drill in their perceived planned axis (version and inclination), and a screenshot was taken for



**Figure 2** Example of a computer navigation screenshot showing surgeon-blinded simulated placement of the central-axis guide pin (yellow outline), attempting to match the preoperative plan (blue outline, 3° of anteversion and 1° of superior inclination); the values for the starting point location, version, and inclination for the simulation were then compared with the preoperatively planned component position to determine displacement, version and inclination error, and malposition. P, posterior; A, anterior; S, superior; I, inferior.

retrospective comparison to the preoperative plan (eg, see Fig. 2). Participating surgeons were blinded from the images taken and other surgeons' positioning. Subsequently, participating surgeons were unblinded to the navigation screen and continued the procedure using computer navigation according to the preoperative plan (eg, see Fig. 1).

*Data analysis*

Eligible patients were identified, and screenshots were collected and blinded for analysis. An independent evaluator reviewed all screenshots and recorded the displacement from the planned starting point, the magnitude of version error, and the magnitude of inclination error. All values were determined based on the starting central-axis guide pin. Displacement between the preoperative (planned) starting point and the simulated starting point identified intraoperatively by blinded participating surgeons was measured on the screenshots using a validated computer screen measurement program (eg, see Fig. 3; ImageJ; National Institutes of Health, Washington, DC, USA). Intraoperative version and inclination were measured directly by the navigation system and compared with preoperative (planned) version and inclination. Differences in the preoperatively planned measurements and blinded intraoperative positioning from each participating surgeon were computed. Intraoperative blinded execution was considered malpositioned based on previously published criteria: version or inclination errors exceeding 10° or starting point displacement exceeding 4 mm.<sup>31</sup> Glenoid morphology was classified based on the Walch classification.<sup>2,34</sup> Measurements were stratified by posterior wear status

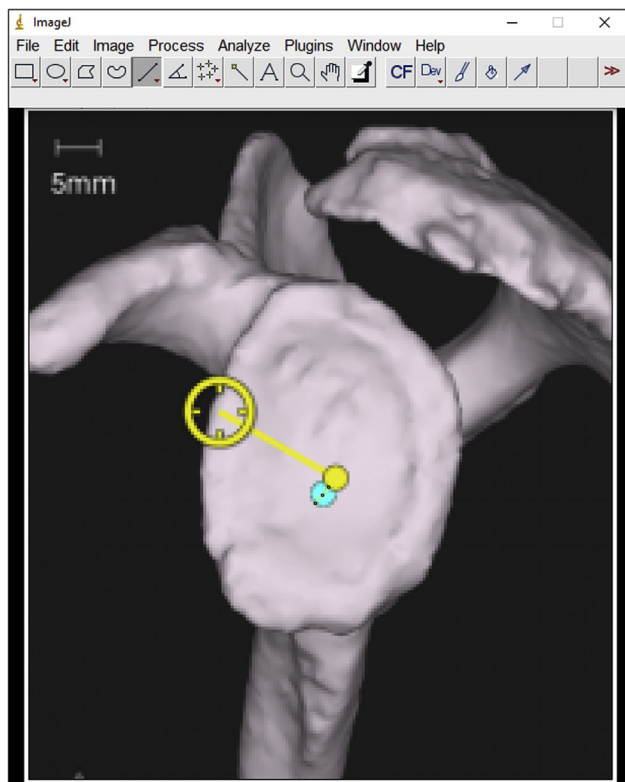
(with, Walch type B2 or B3; without, Walch type A1, B1, or A2) and specific Walch classification (A1, A2, B1, B2, or B3) and were compared based on error from the preoperative plan in displacement, version, and inclination. Only one glenoid was classified as Walch type C in our cohort and was excluded because of lack of statistical power.

*Statistical analysis*

Displacement, version error, and inclination error on a continuous scale were compared between glenoids with and without posterior wear using an unpaired 2-sided *t*-test. In addition, differences based on specific Walch classification (A1, A2, B1, B2, or B3) were compared using a one-way analysis of variance test. Version and inclination error were also grouped categorically (<5°, between 5° and 10°, and >10°) and compared based on posterior wear status and specific Walch classification using chi-square tests. Significant interactions were followed by a Tukey (continuous data) or Bonferroni (categorical data) post hoc test for pairwise comparisons where appropriate. All statistics were performed separately for aTSA and rTSA using R Software (version 3.6.3, R Core Team, Vienna, Austria), and the significance was set at a *P*-value of 0.05.

**Results**

From our institutional database, we initially identified 368 primary aTSA and rTSA performed during the study period. From these, 233 images from 170 shoulder arthroplasties were included. The mean age at surgery was 69.2 ± 9.2 years, and 53% were female.



**Figure 3** Example of the displacement between the preoperative (planned) starting point and the simulated starting point identified intraoperatively by a blinded surgeon being measured on a computer navigation screenshot using ImageJ.

Seventy percent of images were from rTSA cases. Glenoids were classified as posteriorly worn (Walch type B2 or B3) in 90 images and not posteriorly worn (A1, A2, or B1) in 143 images. Specifically, the Walch classification of included images are as follows: type A1 in 63 (27%), type A2 in 32 (14%), type B1 in 48 (21%), type B2 in 84 (36%), and type B3 in 6 (3%).

*Displacement error*

The mean displacement from the planned starting point was  $3.5 \pm 2.8$  mm, with 68 measurements (29%) exceeding 4 mm. Displacement error did not differ between glenoids with and without posterior wear for aTSA ( $2.7$  mm  $\pm$   $2.7$  mm vs.  $3.0$  mm  $\pm$   $2.0$  mm;  $P = .560$ ) nor rTSA ( $4.0$  mm  $\pm$   $3.8$  mm vs.  $3.7$  mm  $\pm$   $2.3$  mm;  $P = .518$ ; **Table I**). Similarly, glenoids with and without posterior wear were displaced from the starting point by over 4 mm at similar rates for aTSA (21% [8] vs. 16% [5];  $P = .874$ ) and rTSA (35% [18] vs. 33% [37];  $P = .917$ ).

*Version error*

The mean magnitude of version error was  $5.7^\circ \pm 4.7^\circ$  (range,  $0^\circ$  to  $21^\circ$ ). Forty-four percent of cases deviated more than  $5^\circ$  from the preoperative plan, and 16% deviated beyond  $10^\circ$ . The mean error in version was significantly greater for glenoids with posterior wear than those without for rTSA ( $8.1^\circ \pm 5.6^\circ$  vs.  $4.7^\circ \pm 4.0^\circ$ ;  $P < .001$ ), but not aTSA ( $5.7^\circ \pm 3.8^\circ$  vs.  $5.8^\circ \pm 5.0^\circ$ ,  $P = .875$ ; **Table I**). On post hoc pairwise comparison, the magnitude of version error in rTSAs was significantly greater for B2 glenoids compared with A1, A2, and B1 glenoids ( $P = .002$ ,  $P < .001$ , and  $P = .015$ , respectively; **Table II**). When classifying version error in  $5^\circ$  increments, glenoids

**Table I** Displacement, version error, inclination error, and malposition rates compared between glenoids with posterior wear (Walch B2 or B3) and without posterior wear (Walch A1, B1, or A2) stratified by procedure.

Walch classification	With posterior wear (B2 or B3) (N = 90)	Without posterior wear (A1, A2, or B1) (N = 143)	P value
aTSA, N	39	31	
Displacement, mm	$2.7 \pm 2.7$	$3.0 \pm 2.0$	.560
Version error, °	$5.7 \pm 3.8$	$5.8 \pm 5.0$	.875
Inclination error, °	$5.5 \pm 5.3$	$4.0 \pm 4.1$	.190
Malposition*, % (N)	41% (16)	36% (11)	.821
rTSA, N	51	112	
Displacement, mm	$4.0 \pm 3.8$	$3.7 \pm 2.3$	.518
Version error, °	$8.1 \pm 5.6$	$4.7 \pm 4.0$	<b>&lt;.001</b>
Inclination error, °	$8.7 \pm 5.8$	$7.8 \pm 5.6$	.327
Malposition*, % (N)	73% (37)	53% (59)	<b>.027</b>

aTSA, anatomic total shoulder arthroplasty; rTSA, reverse total shoulder arthroplasty.

Bold values indicate statistical significance.

\*As defined by Throckmorton et al.

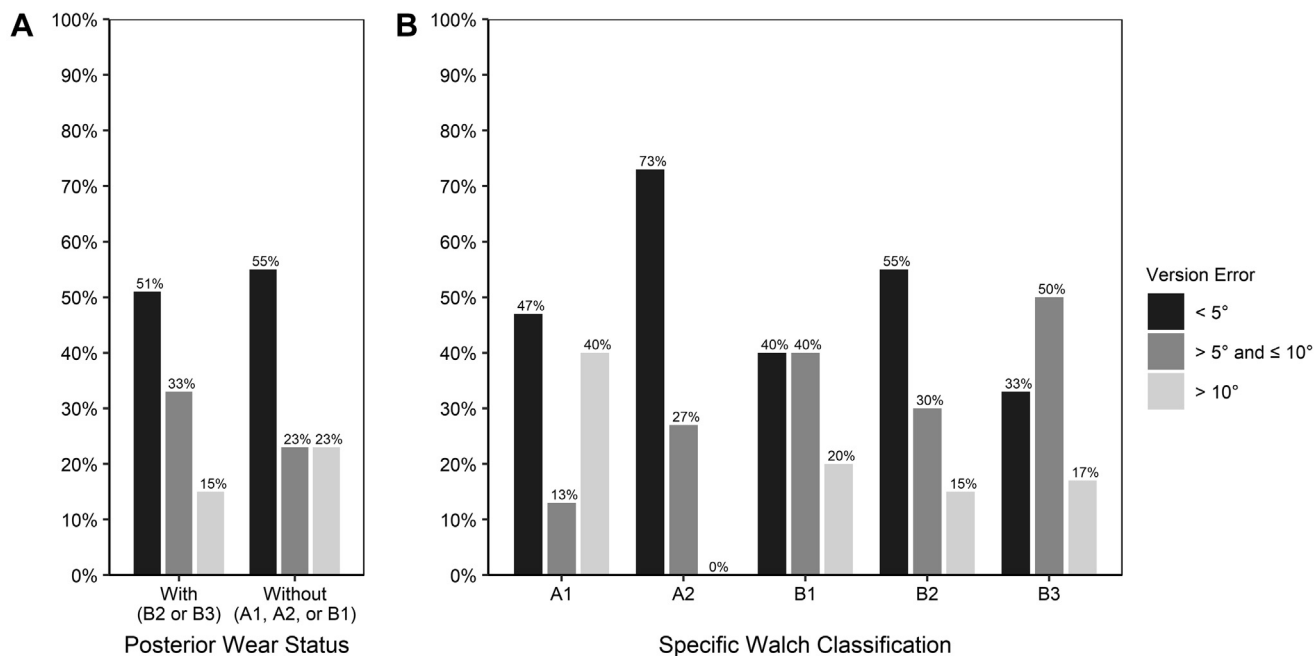
**Table II** Displacement, version error, inclination error, and malposition rates for glenoids classified based on the Walch classification and stratified by procedure.

Walch classification	A1	A2	B1	B2	B3	P value
aTSA, N	15	11	5	33	6	
Displacement, mm	$2.8 \pm 1.5$	$2.9 \pm 2.8$	$4.0 \pm 1.7$	$2.7 \pm 2.8$	$2.7 \pm 1.6$	.849
Version error, °	$7.1 \pm 5.8$	$3.6 \pm 2.6$	$6.8 \pm 5.8$	$5.5 \pm 3.9$	$6.8 \pm 3.6$	.300
Inclination error, °	$4.5 \pm 4.8$	$3.2 \pm 2.6$	$4.4 \pm 5.0$	$5.2 \pm 4.7$	$7.3 \pm 8.0$	.537
Malposition*, % (N)	47% (7)	18% (2)	40% (2)	36% (12)	67% (4)	.353
rTSA, N	48	21	43	51	0	
Displacement, mm	$3.8 \pm 2.4$	$4.7 \pm 3.1$	$3.0 \pm 1.6$	$4.0 \pm 3.8$	NA	.124
Version error, °	$4.7 \pm 3.8$	$3.3 \pm 2.9$	$5.3 \pm 4.5$	$8.1 \pm 5.6$	NA	<b>&lt;.001</b>
Inclination error, °	$7.4 \pm 6.4$	$6.5 \pm 4.3$	$8.7 \pm 5.1$	$8.7 \pm 5.8$	NA	.328
Malposition*, % (N)	50% (24)	57% (12)	54% (23)	73% (37)	NA	.110

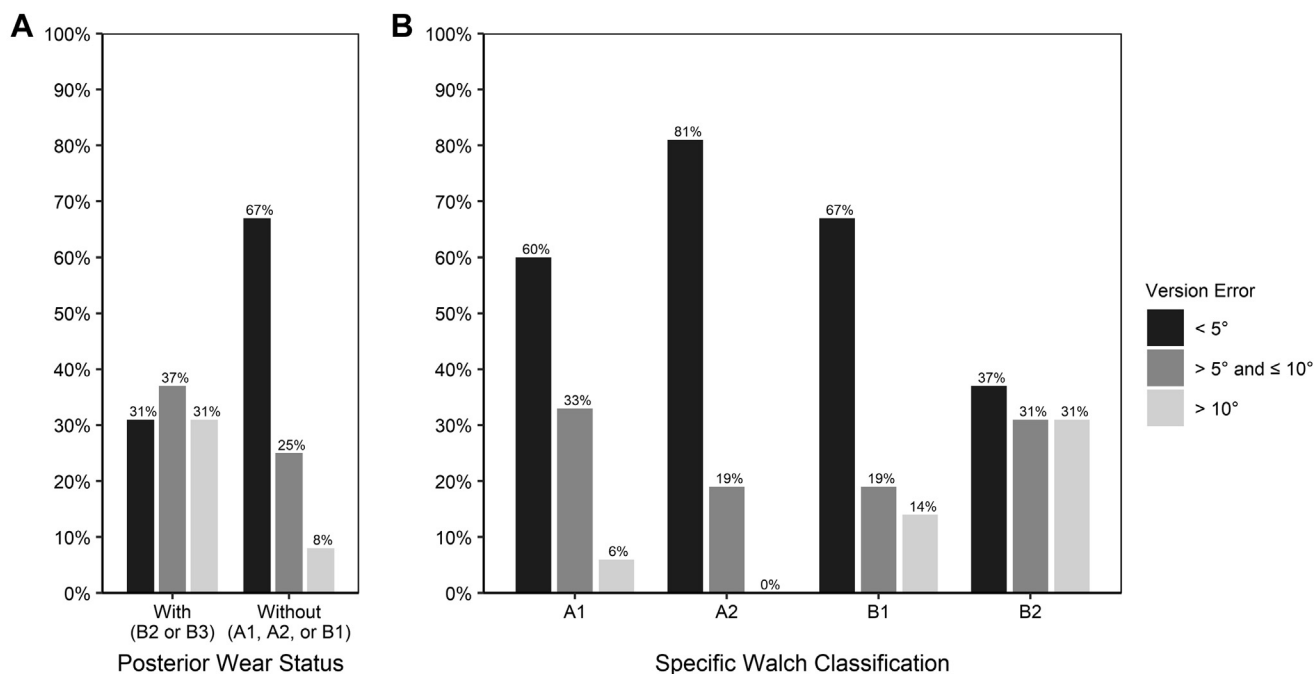
aTSA, anatomic total shoulder arthroplasty; NA, not applicable; rTSA, reverse total shoulder arthroplasty.

Bold values indicate statistical significance.

\*As defined by Throckmorton et al.



**Figure 4** Version error in aTSAs stratified by (A) posterior wear status and (B) Walch classification and grouped by <5°, between 5° and 10°, or >10°.



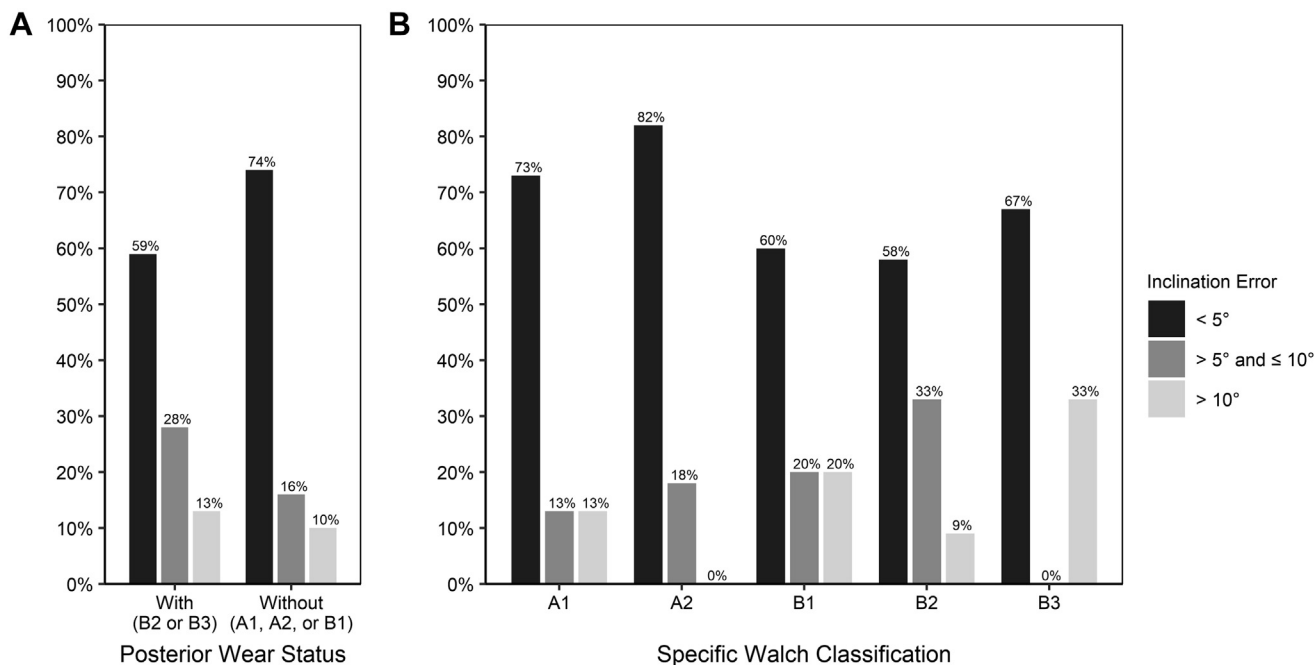
**Figure 5** Version error in rTSAs stratified by (A) posterior wear status and (B) Walch classification and grouped by <5°, between 5° and 10°, or >10°.

undergoing aTSA did not differ based on the degree of wear ( $P = .543$ ) nor the specific Walch classification ( $P = .267$ ; Fig. 4). In contrast, glenoids undergoing rTSA differed based on both degree of wear ( $P < .001$ ) or specific Walch classification ( $P < .001$ ) with increased error seen in glenoids with greater posterior wear (Fig. 5). Notably, a greater proportion of glenoids with posterior wear undergoing rTSA had an error in version >10° (31% [16] vs. 8% [9];  $P < .001$ ). Of the glenoids with >10° of version error (both aTSA and rTSA), glenoids with posterior wear were more commonly

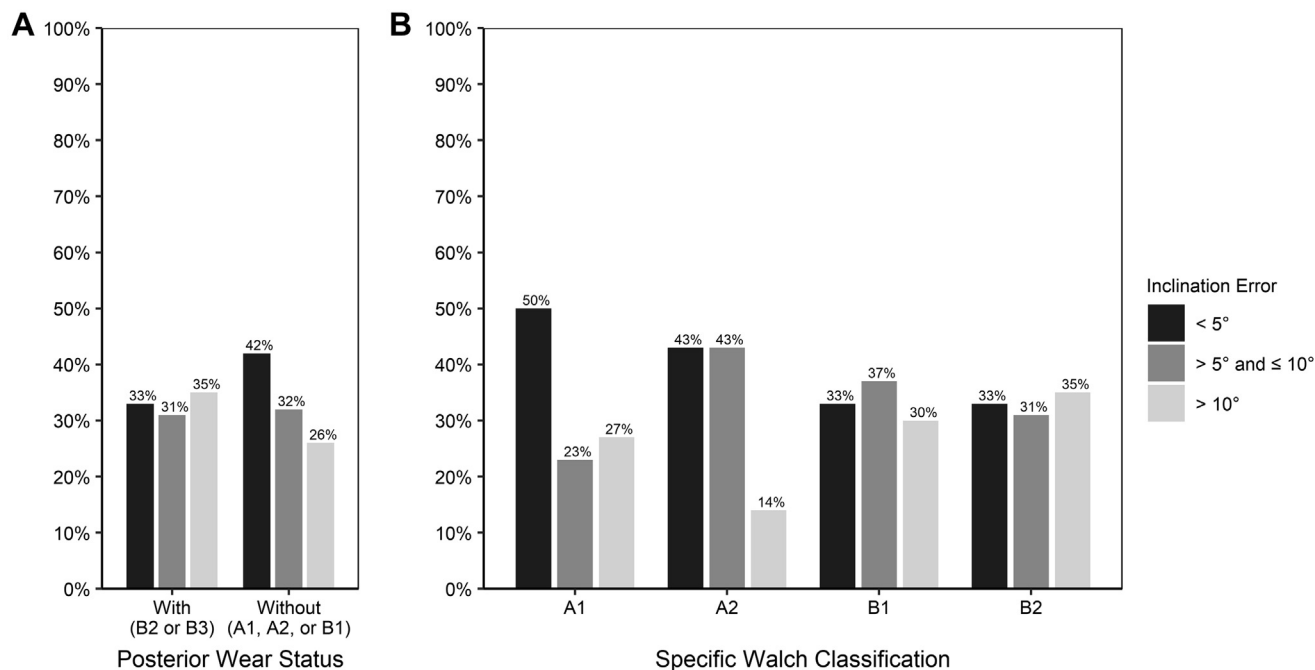
overretroverted intraoperatively compared with the preoperative plan compared with glenoids without posterior wear (55% vs. 31%), although this was not statistically significant ( $P = .273$ ).

*Inclination error*

The mean magnitude of inclination error was  $7.1 \pm 5.6^\circ$  (range,  $0^\circ$  to  $26^\circ$ ), with 53% of measurements exceeding the 5° error cutoff and 24% exceeding the 10° cutoff. The magnitude of inclination



**Figure 6** Inclination error in aTSAs stratified by (A) posterior wear status and (B) Walch classification grouped by <5°, between 5° and 10°, or >10°.



**Figure 7** Inclination error in rTSAs stratified by (A) posterior wear status and (B) Walch classification grouped by <5°, between 5° and 10°, or >10°.

error did not differ between glenoids with and without posterior wear for aTSA ( $5.5^\circ \pm 5.3^\circ$  vs.  $4.0^\circ \pm 4.1^\circ$ ;  $P = .190$ ) nor rTSA ( $8.7^\circ \pm 5.8^\circ$  vs.  $7.8^\circ \pm 5.6^\circ$ ;  $P = .327$ ; Table I). When classifying inclination error in 5° increments, glenoids did not differ based on either posterior wear status or specific Walch classification for aTSA ( $P = .395$  and  $P = .351$ , respectively) nor rTSA ( $P = .418$  and  $P = .305$ , respectively; Figs. 6 and 7, respectively).

*Glenoid malposition*

Without intraoperative navigation, 53% of glenoids would have been malpositioned based on the Throckmorton criteria (>4 mm of displacement or >10° error in version or inclination). Glenoids with posterior wear would have had a higher rate of malposition compared with glenoids without posterior wear without the use of

intraoperative navigation for rTSA (73% vs. 53%;  $P = .027$ ), but not aTSA (41% vs. 36%;  $P = .821$ ; Table 1).

## Discussion

Despite widespread adoption of preoperative planning software and evidence supporting the use of guided instrumentation intraoperatively to improve glenoid component placement accuracy, traditional instrumentation remains the most used method for glenoid placement in shoulder arthroplasty. In the present study, we found that simulated glenoid component placement had greater version error when compared with the preoperative plan for glenoids with posterior wear compared with those without in rTSA, but not aTSA. Without the use of intraoperative navigation, the rate of glenoid malposition would have been greater for glenoids with posterior wear undergoing rTSA, but not aTSA; nonetheless, the rate of malposition in aTSA would have been high (39%).

The ability of the surgeons in the present study to reproduce their preoperative plan is similar to previous studies. Displacement from the planned starting point in our study (3.5 mm) was comparable to previously published data (2.89–3.2 mm).<sup>17,30,31</sup> Our overall version error (5.7°), inclination error (7.1°), and malposition rate (53%) were within the range of previously published data (4.8°–8°, 4.2°–7°, and 38%–66%, respectively).<sup>17,30,31</sup> Similarly, a comparable proportion of glenoid components in the present study were within 5° as reported previously for version (56% vs. 48–51%) and inclination (47% vs. 22–50%).<sup>14,30</sup>

To our knowledge, this is the first study to report on glenoid morphology as a specific risk factor for imprecise glenoid component placement *in vivo* when preoperative planning is used without intraoperative navigation or patient-specific guides. Our finding that there was greater error in version for glenoids with posterior wear undergoing rTSA has potential clinical significance. Glenoids with eccentric wear preoperatively are associated with a greater than 2-fold increased rate of glenoid component loosening compared with glenoids with concentric wear in aTSA.<sup>13</sup> In our study, errors in version were significantly more common with posterior glenoid bone loss, compared with displacement and inclination, which did not appear to be affected by posterior glenoid bone loss. These findings highlight the difficulty for surgeons to accurately use intraoperative landmarks, which are altered with posterior glenoid bone loss and increasing glenoid retroversion. To reduce potential complications such as implant loosening, surgeons should consider using a patient-specific guide or computer navigation in shoulders with posterior glenoid bone loss, particularly when performing rTSA.

Preoperative planning software used with computer navigation or patient-specific guides provides more accurate and reproducible positioning and orientation of the glenoid component in aTSA and rTSA.<sup>7,19,33</sup> The results of our study demonstrate that glenoids with posterior wear reduce surgeons' ability to reproduce their preoperative plan when not using patient-specific guides or navigation during rTSA, but not aTSA. This is in agreement with some prior studies; glenoid morphology has been shown to have no significant influence on the accuracy of patient-specific guides during aTSA.<sup>7,9</sup> In contrast, Jacquot et al found that the use of patient-specific guides in aTSA especially improved the position of the central point when operating on severely retroverted (>10°) glenoids.<sup>17</sup> Regardless of glenoid morphology, routine use of computer navigation may improve component positioning; Nashikkar et al found that postoperative alignment of glenoid components for patients undergoing aTSA and rTSA with computer navigation was within 5° of the plan for 82% of cases for version and 76% of cases for inclination.<sup>25</sup> The use of computer navigation or patient-specific guides in addition to preoperative planning may substantially improve the

surgeons' accuracy when placing the glenoid component, especially in patients with severe posterior glenoid bone loss undergoing rTSA.

Previous authors have suggested that not all patients may benefit from computer navigation or patient-specific guides. Hendel et al found that glenoid component accuracy was significantly increased in patients undergoing primary aTSA with bone deformity and retroversion in excess of 16° when 3-dimensional preoperative planning software with patient-specific guides was used compared with conventional planning and surgical technique.<sup>9</sup> However, no difference in the accuracy of glenoid component placement was seen for patients with <7° of retroversion. In contrast, we report high simulated component malposition rates in glenoids without posterior wear for both aTSA and rTSA (36% and 53%, respectively). Similarly, Schoch et al who showed that glenoid components were malpositioned in more than 38% of cases despite the use of preoperative planning.<sup>30</sup> These results suggest that there may be a benefit of computer navigation and patient-specific guides for all patients, regardless of glenoid morphology.

There are several issues to consider when adopting patient-specific guides or computer navigation. Currently, it is unclear whether shoulder arthroplasty patients will benefit clinically from these technologies. Patient-specific guides and computer navigation are not new to orthopedics, and studies of these technologies in the knee have demonstrated no significant improvement in patient-reported outcomes or implant survival despite more anatomic positioning.<sup>28,32,37</sup> However, radiographic failure rates of glenoids remain significantly higher than primary hip and knee arthroplasty, suggesting that these technologies may have a greater role in shoulder arthroplasty.<sup>1,21,24</sup> A recent meta-analysis including 247 shoulders from 5 studies found that glenoid version was significantly more accurate according to the preoperative plan when computer navigation was used compared with standard instrumentation.<sup>27</sup> Furthermore, a difficult learning curve and increased surgery length may not be an issue for these technologies in shoulder arthroplasty: Wang et al showed surgeons could become proficient using intraoperative computer navigation after 8 cases, and surgical time is comparable to procedures performed using standard instrumentation (77.3 vs. 78.5 minutes).<sup>35</sup> Although further work is needed to prove their long-term benefit, patient-specific guides and computer navigation are promising solutions for improving surgeon accuracy, especially in patients with posterior glenoid bone loss.

This study has multiple limitations to consider. First, we included data from both attending surgeons as well as fellow trainees (both hand/upper extremity and shoulder/elbow fellows). This may have contributed to elevated malposition rates and increased version error; prior research has demonstrated a learning curve for both nonnavigated<sup>3,20</sup> and navigated<sup>35</sup> shoulder arthroplasty. However, our findings are largely consistent with previously reported malposition rates despite including both fellow trainees and attending surgeons.<sup>17,30,31</sup> Furthermore, it further represents generalized practice where shoulder arthroplasties are more commonly performed by nonfellowship trained surgeons. Second, our evaluation of a surgeon's ability to replicate their preoperative plan was based on their hand position held in space at the time of implant central-axis preparation (as measured by the affixed trackers and line-of-sight camera described in the methods), but not on final implant position. Although postoperative radiographs were obtained, cost, radiation exposure, and deviation from the accepted standard of care precluded our ability to obtain routine postoperative CT scans to evaluate final glenoid implant position more completely. However, prior studies have validated the accuracy of this guided technology, and thus, our findings are expected to appropriately predict final implant position.<sup>25</sup> Finally, this study

did not evaluate subjective or objective clinical outcomes; therefore, we remain unable to fully assess the clinical benefit of intraoperative guidance on either patient-reported outcomes or implant survival.

## Conclusion

Surgeons are less accurate at executing their preoperative plan regarding version in glenoids with posterior wear (Walch type B2 or B3) compared with those without (A1, A2, or B1) when performing rTSA, but not aTSA. Without the use of intraoperative navigation when performing rTSA, the rate of malposition would have been greater in glenoids with posterior wear. Although glenoid component displacement, inclination error, and overall malposition did not differ based on glenoid morphology for aTSA, substantial deviations in the preoperative plan were evident in all glenoid types. When performing shoulder arthroplasty with preoperative planning software but without intraoperative navigation or patient-specific guides, surgeons should take additional care to ensure accuracy of glenoid implant placement, especially with respect to version in patients with posterior glenoid bone loss. Furthermore, to improve accuracy of glenoid component placement, surgeons should consider routine use of computer navigation or patient-specific guides.

## Disclaimers:

Funding: This study received no outside funding.

Conflicts of interest: T.W.W. receives royalties and has a consultancy agreement with Exactech, Inc. B.S.S. receives royalties and has a consultancy agreement with Exactech, Inc. J.J.K. is a paid consultant with Exactech, Inc. and LinkBio Corp. The University of Florida Department of Orthopaedics and Rehabilitation receives research support from Exactech, Inc. The remaining authors, their immediate families, and any research foundations with which they are affiliated have not received any financial payments or other benefits from any commercial entity related to the subject of this article.

## References

- Ancelin D, Reina N, Cavaignac E, Delclaux S, Chiron P. Total hip arthroplasty survival in femoral head avascular necrosis versus primary hip osteoarthritis: case-control study with a mean 10-year follow-up after anatomical cementless metal-on-metal 28-mm replacement. *Orthop Traumatol Surg Res* 2016;102:1029–34. <https://doi.org/10.1016/j.otsr.2016.08.021>.
- Bercik MJ, Kruse K, Yalozis M, Gauci MO, Chaoui J, Walch G. A modification to the Walch classification of the glenoid in primary glenohumeral osteoarthritis using three-dimensional imaging. *J Shoulder Elbow Surg* 2016;25:1601–6. <https://doi.org/10.1016/j.jse.2016.03.010>.
- Cho CH, Song KS, Koo TW. Clinical outcomes and complications during the learning curve for reverse total shoulder arthroplasty: an analysis of the first 40 cases. *Clin Orthop Surg* 2017;9:213–7. <https://doi.org/10.4055/cios.2017.9.2.213>.
- Colasanti GB, Moreschini F, Cataldi C, Mondanelli N, Giannotti S. GPS guided reverse shoulder arthroplasty: an anatomic dissection study. *Acta Bio Med Atenei Parm* 2020;91:204. <https://doi.org/10.23750/ABM.V91I4-S.9377>.
- Farron A, Terrier A, B uchler P. Risks of loosening of a prosthetic glenoid implanted in retroversion. *J Shoulder Elbow Surg* 2006;15:521–6. <https://doi.org/10.1016/j.jse.2005.10.003>.
- Friedman RJ, Barcel DA, Eichinger JK. Scapular notching in reverse total shoulder arthroplasty. *J Am Acad Orthop Surg* 2019;27:200–9. <https://doi.org/10.5435/JAAOS-D-17-00026>.
- Gauci MO, Boileau P, Baba M, Chaoui J, Walch G. Patient-specific glenoid guides provide accuracy and reproducibility in total shoulder arthroplasty. *Bone Joint J* 2016;98-B:1080–5. <https://doi.org/10.1302/0301-620X.98B8.37257>.
- Hamilton MA, Polakovic S, Saadi P, Jones RB, Parsons IM, Cheung EV. Evaluation of preoperative implant placement in total shoulder arthroplasty. *Bull NYU Hosp Jt Dis* 2015;73:S47.
- Hendel MD, Bryan JA, Barsoum WK, Rodriguez EJ, Brems JJ, Evans PJ, et al. Comparison of patient-specific instruments with standard surgical instruments in determining glenoid component position: a randomized prospective clinical trial. *J Bone Joint Surg Am* 2012;94:2167–75. <https://doi.org/10.2106/JBJS.K.01209>.
- Heylen S, Van Haver A, Vuylsteke K, Declercq G, Verborgt O. Patient-specific instrument guidance of glenoid component implantation reduces inclination variability in total and reverse shoulder arthroplasty. *J Shoulder Elbow Surg* 2016;25:186–92. <https://doi.org/10.1016/j.jse.2015.07.024>.
- Ho JC, Sabesan VJ, Iannotti JP. Glenoid component retroversion is associated with osteolysis. *J Bone Joint Surg Am* 2013;95:e82. <https://doi.org/10.2106/JBJS.L.00336>.
- Hopkins CM, Azar FM, Mulligan RP, Hollins AM, Smith RA, Throckmorton TW. Computed tomography and magnetic resonance imaging are similarly reliable in the assessment of glenohumeral arthritis and glenoid version. *Arch Bone Joint Surg* 2021;9:64–9. <https://doi.org/10.22038/ABJS.2020.38922.2035>.
- Hussey MM, Steen BM, Cusick MC, Cox JL, Marberry ST, Simon P, et al. The effects of glenoid wear patterns on patients with osteoarthritis in total shoulder arthroplasty: an assessment of outcomes and value. *J Shoulder Elbow Surg* 2015;24:682–90. <https://doi.org/10.1016/j.jse.2014.09.043>.
- Iannotti J, Baker J, Rodriguez E, Brems J, Ricchetti E, Mesaha M, et al. Three-dimensional preoperative planning software and a novel information transfer technology improve glenoid component positioning. *J Bone Joint Surg Am* 2014;96:e71. <https://doi.org/10.2106/JBJS.L.01346>.
- Iannotti JP, Norris TR. Influence of preoperative factors on outcome of shoulder arthroplasty for glenohumeral osteoarthritis. *J Bone Joint Surg Am* 2003;85:251–8. <https://doi.org/10.2106/0004623-200302000-00011>.
- Iannotti JP, Weiner S, Rodriguez E, Subhas N, Patterson TE, Jun BJ, et al. Three-dimensional imaging and templating improve glenoid implant positioning. *J Bone Joint Surg Am* 2015;97:651–8. <https://doi.org/10.2106/JBJS.N.00493>.
- Jacquot A, Gauci MO, Chaoui J, Baba M, Deransart P, Boileau P, et al. Proper benefit of a three dimensional pre-operative planning software for glenoid component positioning in total shoulder arthroplasty. *Int Orthop* 2018;42:2897–906. <https://doi.org/10.1007/s00264-018-4037-1>.
- Jang YH, Lee JH, Kim SH. Effect of scapular notching on clinical outcomes after reverse total shoulder arthroplasty. *Bone Joint J* 2020;102-B:1438–45. <https://doi.org/10.1302/0301-620X.102B11.BJJ-2020-0449.R1>.
- Jones RB, Greene AT, Polakovic SV, Hamilton MA, Mohajer NJ, Youderian AR, et al. Accuracy and precision of placement of the glenoid baseplate in reverse total shoulder arthroplasty using a novel computer assisted navigation system combined with preoperative planning: a controlled cadaveric study. *Semin Arthroplast JSES* 2020;30:73–82. <https://doi.org/10.1053/j.sart.2020.05.004>.
- Kempton LB, Ankersen E, Michael Wiater J. A complication-based learning curve from 200 reverse shoulder arthroplasties. *Clin Orthop Relat Res* 2011;469:2496–504. <https://doi.org/10.1007/s11999-011-1811-4>.
- Kim YH, Park JW, Jang YS. 20-year minimum outcomes and survival rate of high-flexion versus standard total knee arthroplasty. *J Arthroplasty* 2021;36:560–5. <https://doi.org/10.1016/j.arth.2020.07.084>.
- Kolmodin J, Davidson IU, Jun BJ, Sodhi N, Subhas N, Patterson TE, et al. Scapular notching after reverse total shoulder arthroplasty: prediction using patient-specific osseous anatomy, implant location, and shoulder motion. *J Bone Joint Surg Am* 2018;100:1095–103. <https://doi.org/10.2106/JBJS.17.00242>.
- Mansat P, Briot J, Mansat M, Swider P. Evaluation of the glenoid implant survival using a biomechanical finite element analysis: influence of the implant design, bone properties, and loading location. *J Shoulder Elbow Surg* 2007;16(3 Suppl):S79–83. <https://doi.org/10.1016/j.jse.2005.11.010>.
- McLendon PB, Schoch BS, Sperling JW, Sanchez-Sotelo J, Schleck CD, Cofield RH. Survival of the pegged glenoid component in shoulder arthroplasty: part II. *J Shoulder Elbow Surg* 2017;26:1469–76. <https://doi.org/10.1016/j.jse.2016.12.068>.
- Nashikkar PS, Scholes CJ, Haber MD. Computer navigation re-creates planned glenoid placement and reduces correction variability in total shoulder arthroplasty: an in vivo case-control study. *J Shoulder Elbow Surg* 2019;28:e398–409. <https://doi.org/10.1016/j.jse.2019.04.037>.
- Patel M, Martin JR, Campbell DH, Fernandes RR, Amini MH. Inferior tilt of the glenoid leads to medialization and increases impingement on the scapular neck in reverse shoulder arthroplasty. *J Shoulder Elbow Surg* 2021;30:1273–81. <https://doi.org/10.1016/j.jse.2020.09.023>.
- Sadoghi P, Vavken J, Leithner A, Vavken P. Benefit of intraoperative navigation on glenoid component positioning during total shoulder arthroplasty. *Arch Orthop Trauma Surg* 2015;135:41–7. <https://doi.org/10.1007/s00402-014-2126-1>.
- Sassoon A, Nam D, Nunley R, Barrack R. Systematic review of patient-specific instrumentation in total knee arthroplasty: new but not improved. *Clin Orthop Relat Res* 2015;473:151–8. <https://doi.org/10.1007/s11999-014-3804-6>.
- Scalise JJ, Codsı MJ, Bryan J, Brems JJ, Iannotti JP. The influence of three-dimensional computed tomography images of the shoulder in preoperative planning for total shoulder arthroplasty. *J Bone Joint Surg Am* 2008;90:2438–45. <https://doi.org/10.2106/JBJS.G.01341>.
- Schoch BS, Haupt E, Leonor T, Farmer KW, Wright TW, King JJ. Computer navigation leads to more accurate glenoid targeting during total shoulder arthroplasty compared with 3-dimensional preoperative planning alone. *J Shoulder Elbow Surg* 2020;29:2257–63. <https://doi.org/10.1016/j.jse.2020.03.014>.
- Throckmorton TW, Gulotta LV, Bonnarens FO, Wright SA, Hartzell JL, Rozzi WB, et al. Patient-specific targeting guides compared with traditional instrumentation for glenoid component placement in shoulder arthroplasty: a multi-



- surgeon study in 70 arthritic cadaver specimens. *J Shoulder Elbow Surg* 2015;24:965-71. <https://doi.org/10.1016/j.jse.2014.10.013>.
32. Venkatesan M, Mahadevan D, Ashford RU. Computer-assisted navigation in knee arthroplasty: a critical appraisal. *J Knee Surg* 2013;26:357-61. <https://doi.org/10.1055/S-0033-1341581>.
  33. Verborgt O, De Smedt T, Vanhees M, Clockaerts S, Parizel PM, Van Glabbeek F. Accuracy of placement of the glenoid component in reversed shoulder arthroplasty with and without navigation. *J Shoulder Elbow Surg* 2011;20:21-6. <https://doi.org/10.1016/j.jse.2010.07.014>.
  34. Walch G, Badet R, Boulahia A, Khoury A. Morphologic study of the glenoid in primary glenohumeral osteoarthritis. *J Arthroplasty* 1999;14:756-60.
  35. Wang AW, Hayes A, Gibbons R, Mackie KE. Computer navigation of the glenoid component in reverse total shoulder arthroplasty: a clinical trial to evaluate the learning curve. *J Shoulder Elbow Surg* 2020;29:617-23. <https://doi.org/10.1016/j.jse.2019.08.012>.
  36. Werner BS, Hudek R, Burkhart KJ, Gohlke F. The influence of three-dimensional planning on decision-making in total shoulder arthroplasty. *J Shoulder Elbow Surg* 2017;26:1477-83. <https://doi.org/10.1016/j.jse.2017.01.006>.
  37. Wylie JD, Tashjian RZ. Planning software and patient-specific instruments in shoulder arthroplasty. *Curr Rev Musculoskelet Med* 2016;9:1-9. <https://doi.org/10.1007/s12178-016-9312-4>.