



# Technical Aspects of Combined Heart-Lung Transplantation

Min Ho Ju, M.D., Hyung Gon Je, M.D., Ph.D.

Department of Nursing and Cardiothoracic Surgery, Pusan National University Yangsan Hospital, Medical Research Institute of Pusan National University, Yangsan, Korea

## ARTICLE INFO

**Received** July 25, 2022

**Revised** July 29, 2022

**Accepted** August 1, 2022

## Corresponding author

Hyung Gon Je

**Tel** 82-55-360-2127

**Fax** 82-55-360-2157

**E-mail** jehg7332@gmail.com

**ORCID**

<https://orcid.org/0000-0003-4713-2898>

Although organ transplants have become quite common, combined heart-lung transplantation (CHLTx) is unfamiliar at most institutions. While the remarkable rate of development in treatment options, such as drugs and mechanical circulatory support, have reduced the need for CHLTx, it remains the sole treatment option for a subset of patients with end-stage cardiopulmonary failure. For many cardiothoracic surgeons, CHLTx is not technically new or difficult, but it does pose challenges due to its low frequency and relative complexity. Thus, this review aims to describe the CHLTx technique in technical detail using the existing literature.

**Keywords:** Organ transplantation, Heart-lung transplantation, Surgical technique

## Introduction

The first successful combined heart-lung transplantation (CHLTx) was performed in 1981 [1]. Since 1990, over 4,800 CHLTx procedures have been conducted; however, only approximately 50 cases are performed worldwide each year [2]. Thus, because CHLTx is performed intermittently and many surgeons may not be familiar with it, CHLTx can be conducted inefficiently. Moreover, technical problems are a primary cause of early deaths following CHLTx [3]. Thus, well-designed surgical plans and well-organized teamwork are required to reduce the risk of adverse outcomes. The aim of this report was to provide detailed and up-to-date technical information on CHLTx through a review of previously published papers. As this study only reviewed existing literature and did not include any human subjects, institutional review board approval and informed consent were not required.

## Donor procurement

In CHLTx, the heart and lungs are harvested as a “heart-lung bloc.” Procurement of the heart-lung bloc begins with median sternotomy for exposure of the thoracic organs, after which the suitability of the heart and lungs can be assessed. The pleurae are then opened bilaterally, and each

lobe of the lungs is evaluated for abnormalities and compliance. The pericardium is also opened, contractility and coronary anatomy are evaluated, and cardiac dissection begins. The ascending aorta is then dissected away from the main pulmonary artery (mPA), and the superior vena cava (SVC) is separated from the right pulmonary artery (PA). The dissected ascending aorta and SVC are then held with nylon tape for safe retraction (Fig. 1A). Next, at the discretion of the surgeon, the azygous vein may be identified and ligated twice with black silk. However, it does not need to be divided at this time. It is safe to divide the azygous vein after cardiac arrest to reduce the risk of bleeding if possible.

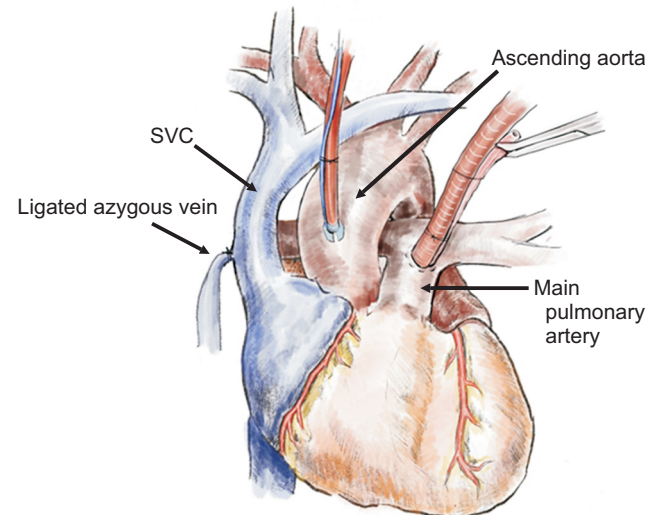
The trachea is then fully dissected circumferentially (Fig. 1B). This process may also be performed after cardiac arrest, depending on the surgeon's preference [3]. Circumferential dissection of the inferior vena cava (IVC) may also be performed, but is not essential. After the abdominal team's procedures are complete, an infusion of 400 U/kg heparin (typically 20,000–30,000 U) is administered. An antegrade cardioplegic cannula is then inserted into the aorta with purse-string sutures and a cardioplegic perfusion line is connected with de-airing. A lung perfusion cannula is also inserted into the mPA with purse-string sutures and connected to the perfusion line. Following the procurement team's cannula placement, 500 mg of prosta-



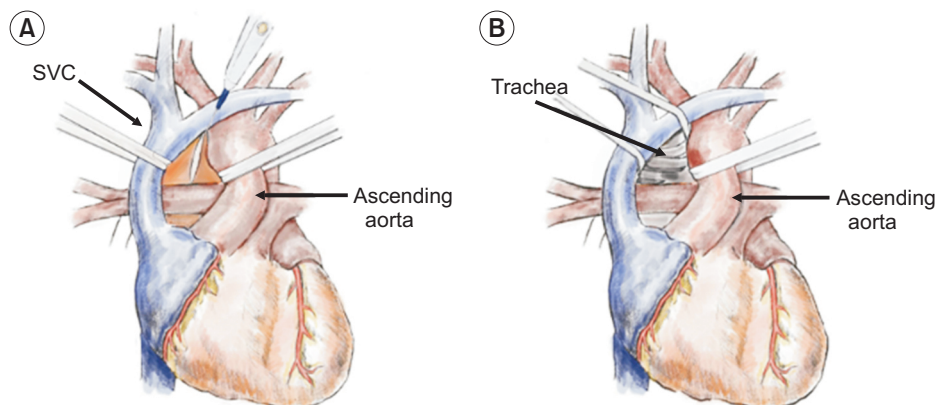
glandin E1 is injected into the mPA (Fig. 2), followed by venting of the left heart and partial division of the IVC. Traditionally, amputation of the left atrial auricle (LAA) has primarily been used for the venting of the left heart (Fig. 3A). However, more recently, left atriotomy via the interatrial groove (also known as Waterston's groove) has also been used according to the surgeon's preference (Fig. 3B). This method enables easier repair and can preserve LAA contractility. The SVC is then blocked with a vascular clamp or snare of pre-encircled nylon tape. After 5–10 seconds of cardiac venting, aortic cross-clamping is performed. Cardioplegia and surgical technique are then infused through each cannula, respectively, and the pericardial space and pleural cavity are filled with ice slush for topical cooling. As the plegic solutions are administered, it is necessary to continuously monitor for sufficient perfusion of solution, aortic pressure, cannula displacement, and cardiac venting. Additionally, mechanical ventilation at 10 breaths per minute must be maintained.

After the plegic infusions are complete, all clamps and cannulas are removed. The IVC is then transected completely, and the SVC is transected from the cephalad level to the azygous vein. The ascending aorta is then transected distally to the origin of the innominate artery, and the pericardium is cut down to the diaphragm and then posteriorly along the diaphragm on both sides. Next, both inferior pulmonary ligaments are divided up to the level of the inferior pulmonary veins. Each lung is flipped medially to expose the contents of the posterior mediastinum; these contents, such as the esophagus and descending aorta, are

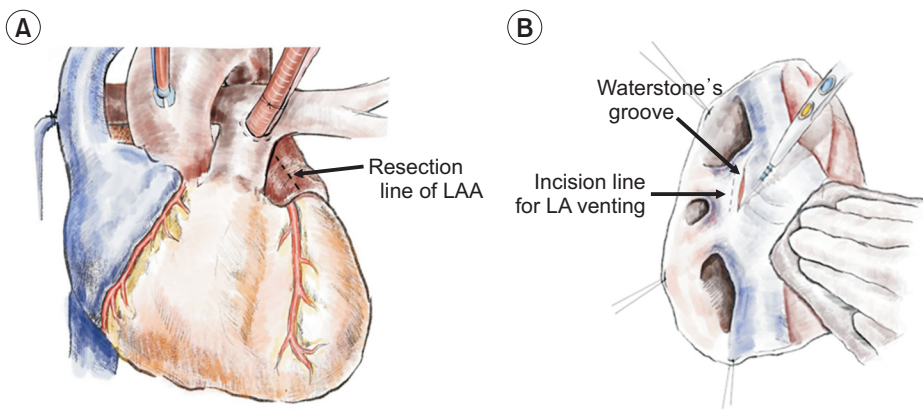
then bluntly dissected. Azygous vein division is also performed at this time. During this procedure, a sharp instrument can damage the tracheal posterior membrane by proximity. Additionally, care should be taken to avoid damage to the left PA and the right mainstem bronchus in the process of separating the bilateral lungs from the peri-



**Fig. 2.** Cannulation for cardioplegia and pulmoplegia in the donor heart. After systemic heparinization, a cannula for cardioplegia is inserted at the ascending aorta with a purse-string suture. Next, a cannula for pulmoplegia is placed at the main pulmonary artery with a purse-string suture. At this time, the surgeon should be careful that the tip of the cannula does not go deep to one side or bend to one side. SVC, superior vena cava.



**Fig. 1.** Preparation for procurement of the heart-lung bloc. (A) Dissection and snaring of the ascending aorta and the superior vena cava (SVC). (B) Dissection of the trachea. The ascending aorta is carefully dissected from the pulmonary artery, and the SVC is fully mobilized. Care must be taken not to damage the right pulmonary artery during the SVC dissection. Next, the ascending aorta and the SVC are held with umbilical tape. After carefully pulling the aorta and the SVC on both sides, the posterior pericardium between the aorta and the SVC is opened for dissection of the trachea. The trachea is dissected to the cephalad direction as much as possible (from the upper margin of the right pulmonary artery to the innominate vein).



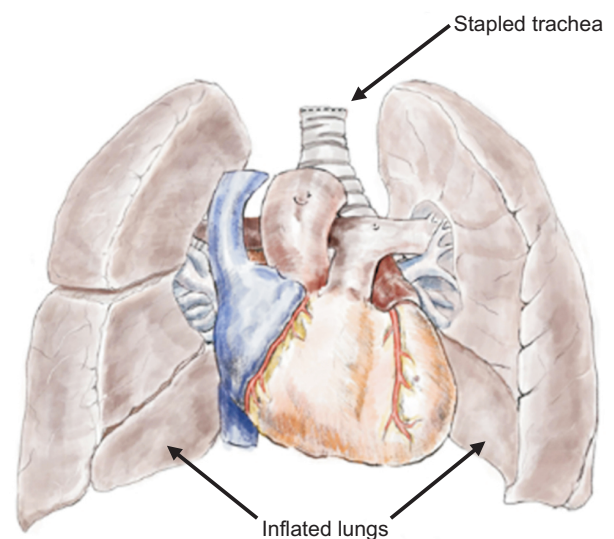
**Fig. 3.** Venting site of the left heart. (A) Amputation of the left atrial appendage (LAA). (B) Left atriotomy in the interatrial groove (Waterstone's groove). After infusion of prostaglandin E1 into the main pulmonary artery, cardiac venting is accomplished before aortic cross-clamping. A wide opening for inserting the suction cannula is made at the LAA or the interatrial groove near the right upper pulmonary vein. LA, left atrium.

cardium. Aggressive dissection can cause injury due to the acute caudal angles of the lungs. The trachea is then further mobilized and stapled off distally at least 1 cm above the carina. At this time, the lungs should be mildly inflated at low pressure. The heart-lung bloc is then extracted from the donor's thoracic cavity (Fig. 4), grossly examined for any abnormality, and placed into a cold preservative solution for transport.

In the recipient's operation room, the heart-lung bloc is removed from storage. Excess mediastinal tissue including the mediastinal portion of the esophagus, descending aorta, and pericardium is removed. However, the paratracheal tissue of the heart-lung bloc should be left intact to facilitate blood supply to the area of the tracheal anastomosis. The staple line of the trachea is then removed sharply, and the venting site (LAA or left atriotomy) is repaired. Then, the atrial septum is inspected through the IVC. If a patent foramen ovale is revealed, it is repaired at this time.

## Recipient preparation

Surgeons may select either a median sternotomy or bilateral thoracosternotomy (clamshell incision) for recipient incision. The midline of the pericardium is opened and both pleural spaces are opened widely. As much dissection as possible should be performed before beginning cardiopulmonary bypass (CPB). At the appropriate time, CPB is initiated, and the recipient heart is removed from the thorax. In general, cannulation is performed directly through the distal ascending aorta, SVC, and IVC. In patients with preoperative extracorporeal membrane oxygenation (ECMO) support, femoral cannulations of ECMO are changed to cannulations of CPB, and direct SVC cannulation is then added for bicaval drainage. In patients with a history of previous cardiac surgery, peripheral cannulation



**Fig. 4.** Procurement of the heart-lung bloc. The trachea is stapled as upwards as possible from the carina with moderately inflated lungs. All applied cannulas are removed and the purse-string suture of the main pulmonary artery is tied. The superior vena cava and inferior vena cava are harvested as long as possible, and the aorta is transected at a more distal level than the base of the innominate artery. The harvested heart-lung bloc is grossly examined for abnormalities and packaged in sterile bags with protective solutions.

through the femoral vessels and the right internal jugular vein may be helpful. Cardiectomy is then performed in the same manner as in isolated heart transplantation. At this point, it is recommended to leave sufficient cuffs of the SVC and IVC remaining. After aortic cross-clamping of the recipient, the proximal aorta is transected at the level of the commissure of the aortic valve. The mPA and LA cuff can then be excised comfortably (Fig. 5).

Traditionally, a pericardial phrenic pedicle is created on both sides to obtain adequate space for the implanted heart-lung block. An incision is made in the pericardium

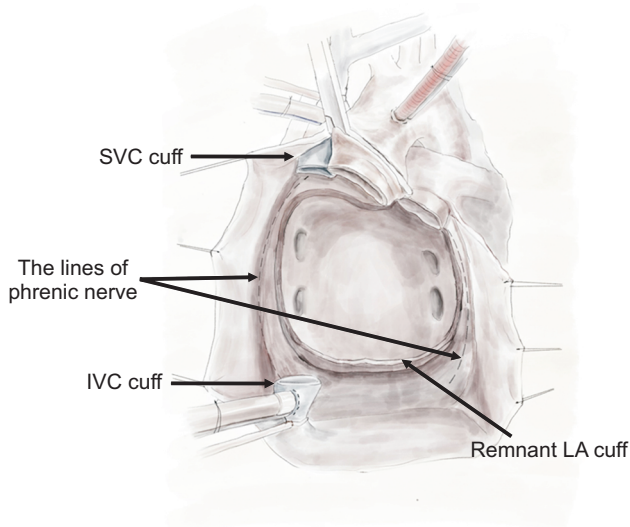
just anterior to the left pulmonary veins and with enough distance from the phrenic nerve. Extension of the incision is then made cranially and caudally by a few centimeters [4,5]. Generally, remnant recipient tissues, including the left atrium and pulmonary vein, are removed via posterior mediastinal dissection, and residual PA tissue is removed (Fig. 6A). During this procedure, some PA tissue on the ligamentum arteriosum is left behind to avoid potential damage to the recurrent laryngeal nerve (Fig. 6B). Alterna-

tively, some institutions leave the pulmonary hilum in place without aggressive dissection, a method that is useful in recipients with previous interventions or operations related to this area, especially in those with congenital heart disease [6]. Recently, a modified method called the non-in situ technique has been introduced, which leaves all residual tissues, including the left atrial cuff, pulmonary hilum, remnant tissue of the PA, and residual recipient bronchus, without any posterior mediastinal dissection. In this technique, a pericardial phrenic pedicle is not made, and the heart-lung bloc is placed above the pericardium [7]. Both bronchi are closed by stapling, and the bronchus is divided distally to the stapler line. Other details of the procedure follow those of a pneumonectomy.

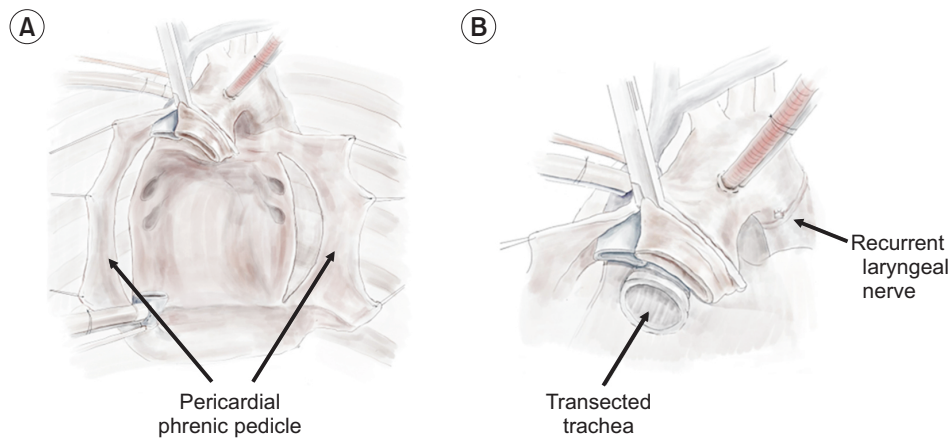
### Implantation technique

Once the recipient's heart and lungs are removed and remnant tissue is cleared, the heart-lung bloc can be implanted. Before the donor allograft is placed, meticulous hemostasis must be performed. As the posterior mediastinum is well-collateralized from the arterial vessels, visibility in this area is very difficult after heart-lung bloc implantation.

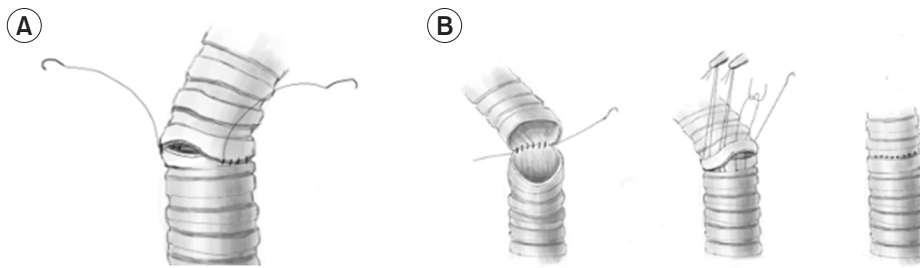
The lungs are then passed under the respective phrenic pedicle and placed into each pleural space. It does not matter which lung is inserted first. The heart should be placed in the midline, followed by performing airway anastomosis. There are 2 airway implantation techniques according to the level of anastomosis: tracheal anastomosis and bi-bronchial anastomosis [5,8]. The tracheal anastomosis



**Fig. 5.** Cardiectomy status of the recipient. Cardiectomy of the recipient is performed in the same way as in isolated heart transplantation. The superior vena cava (SVC), the inferior vena cava (IVC), and the aorta are used for anastomosis, so these vessels should be left with sufficient residual cuffs. LA, left atrium.



**Fig. 6.** Preparation of implantation. (A) The thoracic cavity of the recipient after pericardial phrenic formation and the removal of remnant tissues. (B) Trachea and aorta of the recipient after removal of the remnant pulmonary arterial tissue. Traditionally, the remnant tissues of the left atrium and vessels of both hilar areas are removed. Longitudinal pericardial phrenic pedicles are made to put the lungs into the pleural space. Remnant tissue of the pulmonary artery also is removed; at this point, care must be taken not to damage the recurrent laryngeal nerve. After the remnant tissues are removed, a meticulous hemostatic process is required.



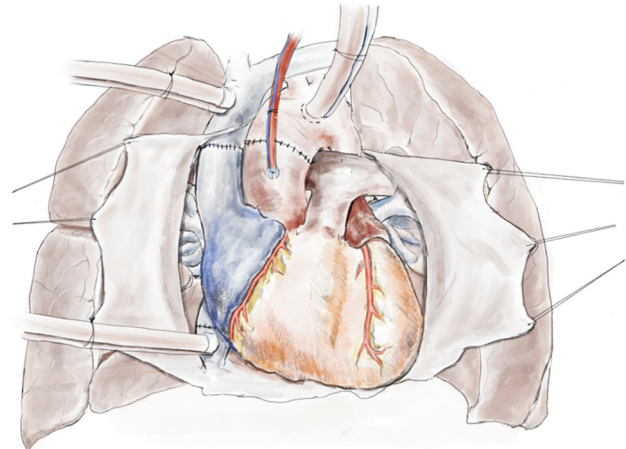
**Fig. 7.** Methods for tracheal anastomosis. (A) Continuous running suture along the entire circumference. (B) Running suture in the membranous portion and interrupted sutures in the cartilage portion.

technique can diminish the bypass and graft ischemic time by reducing the number of anastomoses. However, this technique requires peri-tracheal dissection, which increases the bleeding risk around the carina along with injury to the vagus nerve. Alternatively, the bi-bronchial technique can help avoid complications related to dissection around the carina, but may increase the risk of small airway narrowing [8].

Usually, tracheal or bronchial anastomosis is performed using a single-layer running suture with a 3-0 or 4-0 polypropylene monofilament (Fig. 7A) [5]. Some surgeons prefer running sutures for the membranous portion and interrupted sutures for the cartilaginous portion (Fig. 7B) [9].

Following anastomosis, insufflation to a pressure of 20–30 cmH<sub>2</sub>O is performed to examine air leakage. The anastomosis must be accurate without buckling [5]. Some case reports have described mycotic disruption of the aortic anastomosis when adjacent to the tracheal anastomosis [9]. Thus, this airway anastomosis should be wrapped by viable local tissue, such as pericardial or lymphatic tissue, separating them from the surrounding vascular structures. This may also provide additional protective effects against ischemia at the anastomosis site [3].

Cardiac anastomosis is then begun. Some institutions insert a small catheter into the LA chamber at this point via the LAA or right upper pulmonary vein with a purse-string suture [3,6]; this catheter is used to remove air from the left heart chamber [6], with some institutions infusing cold crystalloid solution through it to evacuate air [3]. Additionally, the order of cardiac vessel anastomosis varies among institutions. At Stanford University, both venae cavae are first anastomosed, followed by aortic anastomosis [5]. However, other institutions have explained that aortic anastomosis is performed first, followed by anastomosis of both venae cavae [3]. Generally, the sequence of vascular anastomosis of heart is as follows. The IVC is anastomosed first, followed by aortic anastomosis using the same maneuver as used in isolated heart transplantation. Next, the aortic cross-clamp is released by de-airing via the root



**Fig. 8.** Status after complete anastomosis of the heart-lung bloc.

vent. Finally, the SVC anastomosis is completed, with re-perfusion (Fig. 8). When all anastomoses are completed, careful hemostasis should be performed. Upon the confirmation of restoration of heart contraction and normal ventilation of both lungs, the patient is then weaned from CPB. After a protamine infusion, additional hemostasis is performed, and appropriate drains are placed in both pleural and pericardial spaces before the incision is closed.

## Conclusion

This review compiled published reports on CHLTx procedures to provide a complete and up-to-date picture of its process. Several institutions have created various modified CHLTx techniques to improve outcomes and reduce the difficulty of surgery. These efforts are constantly required to ensure sufficient skill and expertise.

CHLTx is not a technically new or difficult surgery; unlike isolated thoracic transplantation, the cardiopulmonary connection in this procedure is intact, so fewer anastomoses are required for graft implantation. Nevertheless, many previous reports have shown high incidences of complications and early death after CHLTx. The most important

factor that determines the outcomes of CHLTx is the condition of the patient before surgery. However, prolonged operation time, wasted ischemic time, intraoperative or postoperative bleeding, and technical complications such as nerve injuries or airway problems are also important factors for patients' prognosis. Therefore, a detailed and well-designed surgical plan is required for CHLTx procedures.

## ORCID

Min Ho Ju: <https://orcid.org/0000-0001-7839-8598>

Hyung Gon Je: <https://orcid.org/0000-0003-4713-2898>

## Author contributions

Conceptualization: MHJ, HGJ. Data curation: MHJ. Methodology: MHJ. Visualization: MHJ. Writing—original draft: MHJ. Writing—review & editing: MHJ, HGJ.

## Conflict of interest

No potential conflict of interest relevant to this article was reported.

## Funding

This research did not receive any specific grant from funding agencies in the public, commercial, or not-for-profit sectors.

## Acknowledgments

The authors would like to thank Sung Ho Son for his special illustrations.

## References

1. Reitz BA, Wallwork JL, Hunt SA, et al. *Heart-lung transplantation: successful therapy for patients with pulmonary vascular disease*. *N Engl J Med* 1982;306:557-64.
2. Chambers DC, Cherikh WS, Harhay MO, et al. *The International Thoracic Organ Transplant Registry of the International Society for Heart and Lung Transplantation: thirty-sixth adult lung and heart-lung transplantation report-2019; focus theme: donor and recipient size match*. *J Heart Lung Transplant* 2019;38:1042-55.
3. Huddleston CB, Richey SR. *Heart-lung transplantation*. *J Thorac Dis* 2014;6:1150-8.
4. Pasque MK. *Standardizing thoracic organ procurement for transplantation*. *J Thorac Cardiovasc Surg* 2010;139:13-7.
5. Nasirov T, Shudo Y, MacArthur JW, et al. *Heart-lung transplantation*. *Oper Tech Thorac Cardiovasc Surg* 2022 Jun 11 [Epub]. <https://doi.org/10.1053/j.optechstcvs.2022.06.001>.
6. Carvajal HG, Costello JP, Miller JR, Eghtesady P, Nath DS. *Pediatric heart-lung transplantation: technique and special considerations*. *J Heart Lung Transplant* 2022;41:271-8.
7. Xu X, Shi J, Peng G, et al. *Non-in situ technique of heart-lung transplantation: case series and technique description*. *Ann Thorac Surg* 2021;112:661-4.
8. Roselli EE, Smedira NG. *Surgical advances in heart and lung transplantation*. *Anesthesiol Clin North Am* 2004;22:789-807.
9. Griffith BP, Magliato KE. *Heart-lung transplantation*. *Oper Tech Thorac Cardiovasc Surg* 1999;4:124-41.