

Evaluating outcomes of combined bladder neck and supramontanal sparing ejaculatory preserving transurethral resection of the prostate: Results from a prospective, randomised study

Manasa T, Nishith Reddy, Sandeep Puvvada, Prasad Mylarappa

Department of Urology, MS Ramaiah Medical College, Bangalore, India

Citation: T Manasa, Reddy N, Puvvada S, Mylarappa P. Evaluating outcomes of combined bladder neck and supramontanal sparing ejaculatory preserving transurethral resection of the prostate: Results from a prospective, randomised study. Cent European J Urol. 2022; 75: 292-298.

Article history

Submitted: Jan. 3, 2022

Accepted: July 4, 2022

Published online: July 22, 2022

Corresponding author

Prasad Mylarappa
MS Ramaiah Medical
College
Msrit Post, Msr Nagar,
Mathikere,
560054 Bengaluru, India
phone: +91 9650 145 436
drpmuro3@gmail.com

Introduction Although conventional transurethral resection of the prostate (TURP) is highly successful in improving urinary symptoms and flow rates, a higher incidence of loss of antegrade ejaculation has been reported. Therefore, we aimed at prospectively comparing the efficacy and outcomes of a novel dual bladder neck and supramontanal sparing TURP to conventional TURP to improve voiding and ejaculation.

Material and methods Between January 2019 and November 2020, all patients with benign prostatic hyperplasia (BPH) satisfying the eligibility criteria underwent either conventional TURP (Group 1) or combined bladder neck and supramontanal sparing TURP (Group 2) after randomisation. The groups were compared for functional outcomes including International Prostate Symptom Score (IPSS), peak flow rates, post-void residual urine, perioperative variables and postoperative complications. Ejaculation was assessed with International Index of Erectile Function-Question 9 (IIEF-9) and Ejaculation Projection score (EPS).

Results A total of 90 patients were randomised, 45 each to Group 1 and 2 respectively. The demographic profiles across both groups were comparable. Retrograde ejaculation and bladder neck contracture were significantly higher in Group 1. Both groups demonstrated significant improvement in the IPSS (26.12 ± 2.88 to 4.69 ± 0.87 (Group 1) vs 26.60 ± 3.45 to 4.36 ± 1.74 in Group 2) and Qmax (7.03 ± 2.71 to 24.36 ± 3.82 mL/s in Group 1 vs 6.29 ± 2.64 to 25.28 ± 4.33 mL/s in Group 2) at 3 months. However, a significant difference in IPSS and Qmax were recorded at 6 months. IIEF-9 score in Group 2 remained similar to preoperative profile (4.18 ± 0.75) vs 2.58 ± 0.86 (Group 1). EPS significantly decreased in Group 1 but remained similar to preoperative EPS in Group 2. Antegrade ejaculation was preserved in 88.89% in Group 2 as compared to 22.22% in Group 1.

Conclusions Dual bladder neck and supramontanal ejaculation preserving TURP is superior to conventional TURP in preventing retrograde ejaculation and bladder neck contractures in prostates <50 cc with comparable functional results, perioperative and postoperative morbidity.

Key Words: ejaculation preservation ◊ bladder neck contracture
◊ transurethral resection of the prostate ◊ retrograde ejaculation

INTRODUCTION

Transurethral resection of the prostate (TURP) has stood the test of time and remains the standard of care for surgical indications of benign prostatic

hyperplasia (BPH) to date [1, 2]. Although highly successful in terms of improving urinary symptoms and flow rates [3, 4], a higher incidence of loss of antegrade ejaculation (~70%) has been reported with conventional TURP [5]. Various newer modalities

of resection of prostate such as holmium laser enucleation of the prostate/thulium laser vapoenucleation of the prostate (HoLEP/ ThuVEP) have attempted to address this problem, but to no avail [6].

Retrograde ejaculation has been traditionally attributed to the removal of smooth sphincter of bladder neck [7, 8]. This theory has often been challenged and more recently, preservation of paracollicular tissue is hypothesised as a significant determining factor for preserving forward ejaculation [9]. Modifications based on supramontanal sparing hypothesis have reported favourable outcomes to as high as 92% [10]. However, the combined technique of both bladder neck and supramontanal dual sparing TURP achieves superior results [11]. This novel dual sparing technique has been reported scarcely when compared to bladder neck or hood preserving technique alone. Therefore, we aimed at prospectively comparing the efficacy and outcomes of bladder neck and supramontanal sparing TURP to conventional TURP with regard to voiding and ejaculation.

MATERIAL AND METHODS

Between January 2019 and November 2020, all patients attending the Urology out-patient Department with benign prostatic enlargement and subsequently planned for TURP as per the American Urological Association (AUA) International BPH Guidelines were included in the study. This prospective, randomised study was conducted only after obtaining Institutional Ethics Committee clearance.

Inclusion criteria: prostate volume range: 20–50 mL; IPSS > 7; maximum urinary flow rate (Q_{max}) < 15 mL/s; serum prostate-specific antigen (PSA) < 4 ng/mL; biopsy proven BPH if serum PSA > 4 ng/mL; failure of medical management and; active and healthy sexual life with an ability to ejaculate. Exclusion criteria: history of prostate, bladder or urethral surgery; neurogenic bladder; untreated active urinary tract infection (UTI); presence of median lobe enlargement on cystoscopy, presence of bladder calculi; urethral stricture disease; and biopsy confirmed carcinoma of the prostate.

Initial assessment included clinical history with IPSS followed by physical examination including digital rectal examination (DRE) and focused neurological examination; complete hemogram; serum creatinine; serum electrolytes; urine analysis; serum PSA; ultrasonography of the kidney, ureter, and bladder (USG KUB) region to assess the prostate size, the upper tract, post-void residual urine volume (PVR) and for the presence of calculi; and Q_{max} measurement on uroflowmetry. Patients with urinary tract infection were treated with a course of antibiotics and

were included only if a repeat urine culture was sterile. Those with refractory UTI were eliminated from the study so as to undergo detailed evaluation. Patients suspected to have neurogenic bladder on history and physical examination proceeded to undergo urodynamic study to confirm the diagnosis. All eligible patients were admitted to the hospital one day prior to surgery. International Index of Erectile Function Score-Question 9 (IIEF-9) and Ejaculation Projection Score (EPS) were assessed. Informed written consent for both conventional TURP and supramontanal with bladder neck sparing TURP was taken.

Under anaesthesia, cystoscopy was performed with a 30° degree telescope with the patient in dorsal lithotomy position to rule out the presence of median lobe enlargement. Those with median lobe enlargement underwent conventional TURP but were excluded from the study to eliminate bias. Eligible patients were randomised into two groups in a 1:1 ratio using sealed envelope sequence after cystoscopy. Group 1 underwent conventional TURP and Group 2 underwent bladder neck and supramontanal sparing TURP.

All procedures were performed using a standard resectoscope (26 Fr) and a monopolar electro-surgical cautery. In Group 1, whole adenoma tissue was completely removed to the prostatic capsule including the tissue in front of the verumontanum (ejaculatory hood). In Group 2, lateral lobes were completely resected to the level of capsule. Apical lobe resection was performed by utilizing the colliculus seminalis as a distal resection border while maintaining a 1 cm safety margin. End result would be a to leave behind a strip of prostatic tissue from the bladder neck to the verumontanum at and around 6'o clock position with preservation of bladder neck (Figures 1A,1B).

Following complete haemostasis, a 20 Fr three-way catheter was inserted into the bladder, traction given, and postoperatively the bladder was irrigated with 0.9% saline until clear effluent was seen. Intraoperative factors assessed were operative time, requirement of blood transfusion and intraoperative complications, such as bleeding and capsular/venous sinus perforation and transurethral resection (TUR) syndrome. Postoperatively clot retention, decrease in haemoglobin and electrolyte imbalance were noted and dealt with accordingly. An oral antibiotic was given for 5 days after catheter removal. All patients were followed-up regularly at 3 and 6 months postoperatively with the IPSS, Q_{max}, PVR, IIEF-9Q and EPS.

Statistical analysis

The data analysis was done using the Statistical Package for the Social Sciences (SPSS® version

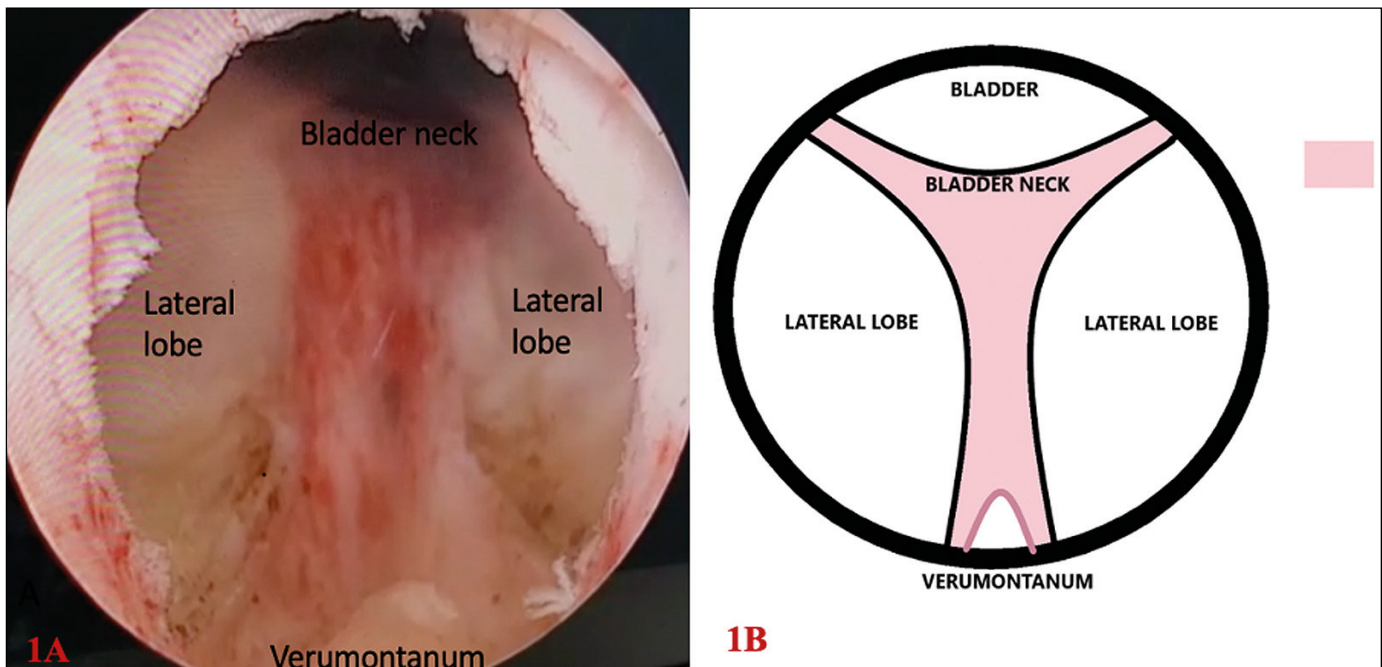


Figure 1A. Endoscopic view of bladder neck and supramontanal sparing TURP with the resected adenoma on lateral lobes. A bridge of tissue between the bladder neck and verumontanum is left unresected between 5'o clock and 7'o clock position.
1B. Diagrammatic representation of sparing of tissue at the bladder neck and verumontanum.

TURP – transurethral resection of the prostate

22.0, SPSS Inc., Armonk, NY, USA). The differences in patient characteristics, perioperative and postoperative parameters between the two groups were analysed using the Student's t-test. Success or failure of the ejaculation preservation in the two groups was analysed using an odds ratio and a chi-square test. A $P < 0.05$ was considered statistically significant.

RESULTS

A total of 90 patients were eligible and randomised; 45 patients each to conventional TURP (Group 1) and ejaculation preserving combined bladder neck and supramontanal sparing TURP (Ep-TURP) (Group 2) groups, respectively. Mean age of the study population was 66.21 ± 9.25 years. The mean preoperative serum creatinine level was 1.13 ± 0.38 mg/dL vs 1.11 ± 0.36 mg/dL and the mean serum PSA level was 1.46 ± 0.78 ng/mL vs 1.27 ± 0.67 ng/mL for Group 1 and 2 respectively. Mean prostate volume was 43.49 ± 4.77 cc in Group 1 and 43.67 ± 4.54 cc in Group 2 respectively. The demographic profiles of the study population across both groups were comparable, as depicted in Table 1. Pretreatment IPSS, Qmax, PVR, IIEF-9 and EPS were comparable, as shown in Table 1.

Operative time was longer in Group 1 (46.16 minutes) when compared to Group 2 (43.84 minutes),

Table 1. Distribution of preoperative parameters across the study population ($n = 90$)

Variable	Group 1 ($n = 45$) (mean \pm SD)	Group 2 ($n = 45$) (mean \pm SD)	P value
Serum PSA (ng/mL)	1.46 ± 0.78	1.27 ± 0.67	0.20
Hemoglobin (g/dL)	12.57 ± 1.11	12.77 ± 1.57	0.47
Serum sodium (meq/L)	139.42 ± 2.55	138.96 ± 4.04	0.51
Serum creatinine (mg/dL)	1.13 ± 0.38	1.11 ± 0.36	0.75
Prostate volume (cc)	43.49 ± 4.77	43.67 ± 4.54	0.85
IPSS	26.12 ± 2.88	26.60 ± 3.45	0.50
Qmax (mL/s)	7.03 ± 2.71	6.29 ± 2.64	0.19
PVR (mL)	135.12 ± 80.90	$145.25 \pm$	0.59
IIEF-9	4.42 ± 0.69	4.33 ± 0.64	0.52
EPS	3.64 ± 0.48	3.67 ± 0.47	0.82

n – number of patients; PSA – prostate-specific antigen; SD – standard deviation; IPSS – International Prostate Symptom Score; PVR – post-void residual urine volume; IIEF-9 – International Index of Erectile Function- Question 9; EPS – Ejaculation Projection Score

but not statistically significant. The mean duration of hospital stay and the mean duration of postoperative catheterisation time was similar across both the treatment groups. Intraoperative and postoperative complications recorded in both the treatment groups

Table 2. Postoperative surgical complications in the two treatment groups (n = 90)

Variable	Group 1 (n = 45)	Group 2 (n = 45)	P value
Perforation of capsule/venous sinus	2	0	0.15
TUR syndrome	–	–	–
Blood transfusion	–	–	–
Clot retention	–	–	–
Urethral stricture	–	–	–
Bladder neck contracture	–	6	0.011
Hematuria	–	–	–
UTI	3	2	0.64
Recatheterisation	–	–	–
Urinary incontinence	2	0	0.15
Retrograde ejaculation	35	5	0.00

n – number of patients; TUR – transurethral resection; UTI – urinary tract infection

are depicted in Table 2. Of the postoperative complications noted, retrograde ejaculation and bladder neck contracture were significantly higher in Group 1 as compared to Group 2, respectively.

Both the treatment groups demonstrated significant improvement in the IPSS score (from a preoperative mean of 26.12 ± 2.88 to 4.69 ± 0.87 at 3 months in Group 1 and from 26.60 ± 3.45 to 4.36 ± 1.74 at 3 months in Group 2) and Qmax (from a mean of 7.03 ± 2.71 mL/s to 24.36 ± 3.82 mL/s in Group 1 and from 6.29 ± 2.64 mL/s to 25.28 ± 4.33 mL/s in Group 2) at 3 months postoperatively (Figure 2). However a significant difference in IPSS (6.67 ± 3.72 in Group 1 vs 4.49 ± 1.42 in Group 2; $p = 0.00$) and Qmax (21.64 ± 6.42 mL/s in Group 1 vs 24.07 ± 4.85 mL/s in Group 2; $p = 0.047$) were recorded at 6 months between both the treatment groups (Table 3).

IIEF-9 score in Group 2 remained similar to preoperative profile (4.18 ± 0.75) vs 2.58 ± 0.86 in Group 1 at 3 months; $p < 0.05$ (Table 3). EPS assessment showed significant decrease in Group 1 (from a mean preoperative value of 3.64 ± 0.48 to 2.31 ± 0.84 at 3 months) while it remained similar to the preoperative EPS score in Group 2 (from a mean preoperative value of 3.67 ± 0.47 to 3.36 ± 0.74) at 3 months. The difference in EPS was significant between both the treatment groups; $p = 0.00$). The EPS and IIEF 9 remained stable at 6 months in the Ep-TURP group (Group 2) (Table 3) with no improvement in Group 1.

DISCUSSION

Transurethral resection of the prostate (TURP) is one of the most frequently performed procedures

Table 3. Postoperative comparison of objective and subjective functional measures across the treatment groups (n = 90)

Variable	Group 1 (n = 45)	Group 2 (n = 45)	P value
IPSS			
3 months	4.69 ± 0.87	4.36 ± 1.74	0.25
6 months	6.67 ± 3.723	4.49 ± 1.42	0.00
Qmax (mL/s)			
3 months	24.36 ± 3.82	25.28 ± 4.33	0.29
6 months	21.64 ± 6.42	24.07 ± 4.85	0.047
PVR (ml)			
3 months	4.38 ± 3.93	4.29 ± 5.56	0.93
6 months	16.20 ± 19.88	3.64 ± 5.40	0.00
IIEF-9			
3 months	2.58 ± 0.86	4.18 ± 0.75	0.00
6 months	2.53 ± 0.84	4.18 ± 0.75	0.00
EPS			
3 months	2.44 ± 0.84	3.49 ± 0.69	0.00
6 months	2.31 ± 0.84	3.36 ± 0.74	0.00

n – number of patients; IPSS – International Prostate Symptom Score; PVR – post-void residual urine volume; Qmax – maximum flow rate; IIEF – International Index of Erectile Function- Question 9

in urologic practice to date [3, 4]. Retrograde ejaculation, a well-known complication of TURP is seen in approximately 65–90% of patients undergoing TURP [5]. Earlier theories attributed antegrade ejaculation to bladder neck closure [7, 8]. The internal urethral sphincter formed by the smooth sphincter of the bladder neck was regarded as the key structure preventing retrograde ejaculation of expelled seminal fluid by active contraction of the bladder neck during ejaculation through a rich noradrenergic innervation by sympathetic nerves [7, 8]. So, removal of the smooth sphincter of the bladder neck was considered a major contributing factor leading to retrograde ejaculation following TURP. In an attempt to avoid this complication, most surgeons proposed a limited incision of the bladder neck, particularly in younger males with a prostate volume of <30 cc and no median lobe enlargement [12, 13]. With this technique, the incidence of post-TURP retrograde ejaculation recorded significantly decreased to as low as 20% in certain studies [2, 10, 14].

However, in 1994, Gil-Vernet et al. [9] proposed a contradictory theory suggesting the role of muscular tissue around the verumontanum in preventing retrograde ejaculation via a dynamic ultrasonographic study. He demonstrated that verumontanum underwent a slight caudal shift, making a momentary contact with the opposite urethral wall and the expelled seminal fluid from the ejaculatory ducts was directed caudally by coordinated contractions of the external sphincter and the bulbar urethra [9]. In addition, Hermabessiere et al. [15] in 1999 dem-

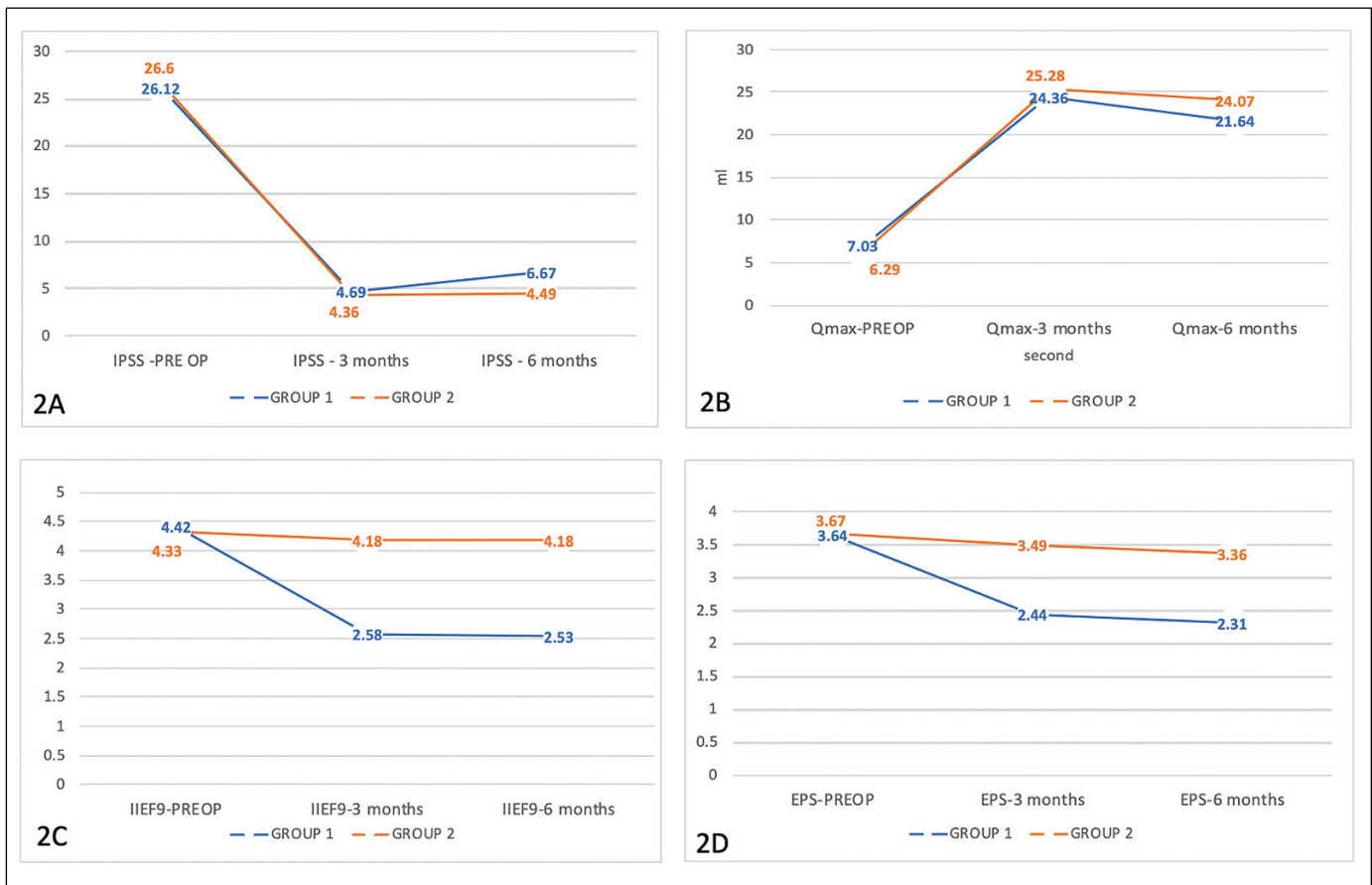


Figure 2. Mean change from baseline (preoperative) in objective and subjective functional measures. **A.** Mean change and comparison of IPSS at different time intervals between the groups. **B.** Mean change and comparison of Q-max at different time intervals between the groups. **C.** Mean change and comparison of IIEF9 at different time intervals between the groups. **D.** Mean change and comparison of EPS at different time intervals between the groups.

Qmax – maximum flow rate; IPSS – International Prostate Symptom Score; PREOP – preoperative; IIEF-9 – International Index of Erectile Function- Question 9; EPS – Ejaculation Projection Score

onstrated that the ejaculate is expelled directly into the inframontanal urethra with a direct closure mechanism of the paracollicular and supracollicular tissue (ejaculatory hood), without ballooning of the prostatic urethra. As a result, preserving the ejaculatory hood (the paracollicular and the supracollicular tissue, which is located 1 cm proximal to the verumontanum) prevented retrograde ejaculation. Based on this hypothesis, Allousi et al. [10] described a novel technique of ejaculation preserving TURP. They demonstrated excellent functional results with respect to micturition parameters and the persistence of antegrade ejaculation (91%) and comparable perioperative and postoperative morbidity to regular TURP thus proving that the apical part is the critical part of the prostate [10].

In order to achieve improved outcomes with regard to preservation of antegrade ejaculation, we combined the technique of bladder neck and ejaculatory

hood preservation for small prostate (50 cc) without median lobe hypertrophy. In our study, antegrade ejaculation was preserved in 88.89% of patients who underwent bladder neck and supramontanal sparing TURP. This was significant when compared to those who underwent conventional TURP (22.2%). We used the ejaculation projection scoring system to assess the degree of projection of the ejaculate. As per the scoring 0 : no ejaculation, 1 : few drops only, 2 : non projectile, 3 : projectile, 4 : strongly projectile [16]. EPS in the conventional TURP group showed a significant fall while those undergoing bladder neck and supramontanal preserving TURP remained fairly unchanged. A salient factor was that the ejaculatory function assessed by IIEF-9 did not show significant change pre- and post-treatment in the Ep-TURP group.

Another striking aspect noted is the decrease in the incidence of bladder neck contractures following

bladder neck preservation. While 6 (13.3%) patients in the conventional TURP group developed bladder neck contracture (BNC) within 6 months of follow-up, none in Ep-TURP group had BNC. The low incidence can be attributed to the avoidance of the proposed predisposing factors for BNC such as the extensive resection of the bladder neck and excessive fulguration at the bladder neck, when performing Ep-TURP. This low incidence of BNC is noted despite including patients with only small prostates of less than 50 cc. Ep-TURP when compared with conventional TURP has shown comparable improvements in terms of IPSS, Qmax and International Index of Erectile Function scores which are comparable to the earlier studies [10, 11, 17]. Hence, in addition to preventing retrograde ejaculation and bladder neck contractures, it significantly improves the outcomes and overall satisfaction. Ep-TURP is suitable in all included patients with a prostate size of less than 50 cc. All procedures were performed by 2 urologists with considerable skill and experience with no difference noted between the two. Since Ep-TURP is a modification from the conventional TURP, no learning curve is required to achieve satisfactory outcomes for experienced urologists already performing the standard TURP.

Limitations

Our study had a small cohort and a short follow-up duration of only 6 months. Long-term results of the study with larger cohorts need to be evaluated. Moreover, prostate volumes of >50 cc and those with median lobe enlargement were excluded from our present study. We need to assess the outcomes in patients with larger prostates and modification of the procedure may be needed in patients with median lobe enlargement. While we assessed the effect of the procedure on ejaculation, its impact on ED needs to be estimated.

CONCLUSIONS

Dual bladder neck and supramontanal ejaculation preserving transurethral resection of the prostate is superior to conventional TURP in preventing retrograde ejaculation and bladder neck contracture in prostates <50 cc. Furthermore, functional results are excellent and perioperative and postoperative morbidity is comparable to conventional TURP.

CONFLICTS OF INTEREST

The authors declare no conflicts of interest.

References

- Mebust WK, Holtgreve HL, Cockett ATK, Peters PC. Transurethral prostatectomy: Immediate and postoperative complications. A cooperative study of 13 participating institutions evaluating 3,885 patients. *J Urol.* 1989; 141: 243-247.
- Rassweiler J, Teber D, Kuntz R, Hofmann R. Complications of transurethral resection of the prostate (TURP)- incidence, management, and prevention. *Eur Urol.* 2006; 50: 969-979.
- Al-Rawashdah SF, Pastore AL, Salhi YA, et al. Prospective randomized study comparing monopolar with bipolar transurethral resection of prostate in benign prostatic obstruction: 36-month outcomes. *World J Urol.* 2017; 35: 1595-1601.
- Mayer EK, Kroeze SG, Chopra S, Bottle A, Patel A. Examining the 'gold standard': a comparative critical analysis of three consecutive decades of monopolar transurethral resection of the prostate (TURP) outcomes. *BJU Int.* 2012; 110: 1595-1601.
- Liao J, Zhang X, Chen M, et al. Transurethral resection of the prostate with preservation of the bladder neck decreases postoperative retrograde ejaculation. *Wideochir Inne Tech Maloinwazyjne.* 2019; 14: 96-101.
- Kim M, Song SH, Ku JH, Kim HJ, Paick JS. Pilot study of the clinical efficacy of ejaculatory hood sparing technique for ejaculation preservation in Holmium laser enucleation of the prostate. *Int J Impot Res.* 2015; 27: 20-24.
- Gallizia P. The smooth sphincter of the vesical neck, a genital organ. *Urol Int.* 1972; 27: 341.
- Marberger H. The mechanisms of ejaculation. *Basic Life Sci.* 1974; 4: 99-110.
- Gil-Vernet JM, Jr, Alvarez-Vijande R, Gil-Vernet A, et al. Ejaculation in men: A dynamic endorectal ultrasonographical study. *Br J Urol.* 1994; 73: 442-448.
- Alloussi SH, Lang C, Eichel R, Alloussi S. Ejaculation-preserving transurethral resection of prostate and bladder neck: short- and long-term results of a new innovative resection technique. *J Endourol.* 2014; 28: 84-89.
- Elshazly M, Sultan S, Shaban M, Zanaty F. Evaluation of a novel technique of bladder neck and supramontanal sparing ejaculatory preserving transurethral prostatectomy. *World J Urol.* 2021; 39: 4215-4219.
- Ruzic B, Trnski D, Kraus O, et al. New modification of transurethral incision of the prostate in surgical treatment of bladder outlet obstruction: Prospective study. *Croat Med J.* 2002; 43: 610-614.
- Lourenco T, Shaw M, Fraser C, MacLennan G, N'Dow J, Pickard R. The clinical effectiveness of transurethral incision of the prostate: a systematic review of randomised controlled trials. *World J Urol.* 2010; 28: 23-32.
- Ronzoni G, De Vecchis M. Preservation of anterograde ejaculation after transurethral resection of both the prostate and bladder neck. *Br J Urol.* 1988; 81: 830-833.
- Hermabessiere J, Guy L, Boiteux JP. Human ejaculation: physiology, surgical conservation of ejaculation. *Prog Urol.* 1999; 9: 305-309.

16. Wolters JP, Hellstrom JG. Current Concepts in Ejaculatory Dysfunction. *Rev Urol.* 2006; 8 (Suppl 4): S18-S25.
17. Gul Z, Chughtai B, Te AE, Thomas D, Kaplan SA. Ejaculatory preserving middle lobe onl-transurethral resection and vaporization of the prostate: 12-year experience. *Urology.* 2019; 134: 199-202. ■