

Complete Resolution of Skull Base Solitary Plasmacytoma Using Proton-Beam Radiotherapy: A Case Report

Review began 03/01/2022

Review ended 03/10/2022

Published 03/13/2022

© Copyright 2022

Khilji et al. This is an open access article distributed under the terms of the Creative Commons Attribution License CC-BY 4.0., which permits unrestricted use, distribution, and reproduction in any medium, provided the original author and source are credited.

Hamza Khilji ¹, Caroline Silver ², Doaa Morrar ³, Arpit M. Chhabra ⁴, Steven Mandel ⁵, David J. Langer ¹, Dana Shani ², Jason A. Ellis ¹

1. Neurosurgery, Lenox Hill Hospital/Donald and Barbara Zucker School of Medicine at Hofstra/Northwell, New York, USA 2. Hematology-Oncology, Lenox Hill Hospital/Donald and Barbara Zucker School of Medicine at Hofstra/Northwell, New York, USA 3. Pathology, Lenox Hill Hospital/Donald and Barbara Zucker School of Medicine at Hofstra/Northwell, New York, USA 4. Radiation Oncology, New York Proton Center, New York, USA 5. Neurology, Lenox Hill Hospital/Donald and Barbara Zucker School of Medicine at Hofstra/Northwell, New York, USA

Corresponding author: Jason A. Ellis, jellis2@northwell.edu

Abstract

Cranial solitary plasmacytomas are uncommon lesions, and localization to the skull base is rare. Here we present a case in a 36-year-old woman who complained of dizziness and mild headaches. Radiographic imaging indicated the presence of a solitary skull base lesion in the posterior cranial fossa. Laboratory tests and imaging excluded systemic disease. A biopsy of the lesion confirmed the diagnosis of plasmacytoma. The patient was treated with proton-beam radiation and had a complete clinical and radiographic resolution, demonstrating the previously unreported utility of monotherapy with proton-beam radiation in such cases.

Categories: Neurology, Radiation Oncology, Neurosurgery

Keywords: skull base, radiotherapy, proton radiation, multiple myeloma, chemotherapy, brain tumor

Introduction

Plasmacytomas arise from an abnormal proliferation of B-cell lymphocytes within the bone or soft tissue. Although rare, plasmacytomas of the skull base have previously been reported. The radiographic differential diagnosis for such tumors at the skull base is wide, but the more common pathologies include meningioma, chordoma, osteosarcoma, metastasis, and others [1]. Classic symptoms of skull base plasmacytomas include headache, double vision [2], and vertigo [3].

Specific categorization of plasmacytomas is based on histologic, anatomic, radiographic, and clinical criteria [4,5]. Presentation of a singular mass is denoted as “solitary,” while systemic involvement may indicate multiple myeloma (MM). Solitary plasmacytomas (SP) are further sub-classified based on location in bone (intramedullary) or soft tissue (extramedullary). Patients with solitary intramedullary plasmacytoma (SIP) have a <30% chance of progressing to multiple myeloma, while those with solitary extramedullary plasmacytoma (SEP) have a > 50% chance of progression [6].

The diagnostic workup for a solitary plasmacytoma includes a biopsy with evidence of clonal plasma cells, radiographic images demonstrating a lack of systemic lytic lesions, and a bone marrow aspirate and biopsy with no clonal plasma cell presence [7]. Whole-body computed tomography (CT) or positron emission tomography (PET) imaging are the preferred diagnostic imaging modalities [8].

When a solitary plasmacytoma is suspected, MM, POEMS syndrome, and metastatic carcinoma should be ruled out. Patients presenting with 10% or greater abnormal plasma cells in the bone marrow, systemic lesions, and renal insufficiency, likely have a diagnosis of MM. Patients with POEMS syndrome (Polyneuropathy, Organomegaly, Endocrinopathy, Monoclonal protein, Skin changes) present with a singular osteolytic bone lesion, defined by a sclerotic rim, a small quantity of monoclonal paraprotein, and elevated levels of vascular endothelial growth factor [9]. Patients with metastatic carcinoma present with multiple lytic lesions and <10% clonal plasma cells in the bone marrow; however, this may be more closely associated with an unrelated monoclonal gammopathy, rather than an SP, distinguishable by a lesion biopsy [7].

Since plasmacytomas are highly chemo/radio-sensitive than several other skull base tumors, prompt and accurate diagnosis is imperative [1,5,10]. Here we present a unique—and to our knowledge, previously unreported—case of a skull base plasmacytoma treated solely with proton radiation therapy. The patient demonstrated an excellent radiographic and clinical response.

Case Presentation

A previously healthy 36-year-old woman on no medications presented with dizziness and mild headaches.

How to cite this article

Khilji H, Silver C, Morrar D, et al. (March 13, 2022) Complete Resolution of Skull Base Solitary Plasmacytoma Using Proton-Beam Radiotherapy: A Case Report. *Cureus* 14(3): e23130. DOI 10.7759/cureus.23130

The physical and neurological examination was unremarkable.

Magnetic resonance imaging (MRI) and CT scans revealed an enhancing posterior cranial fossa skull base tumor with bulky disease anterior to the brainstem and medulla, extending into the left cerebellopontine angle (Figure 1). Due to the wide differential diagnosis, including en plaque meningioma, the patient was taken for a left retrosigmoid craniotomy to biopsy the tumor.

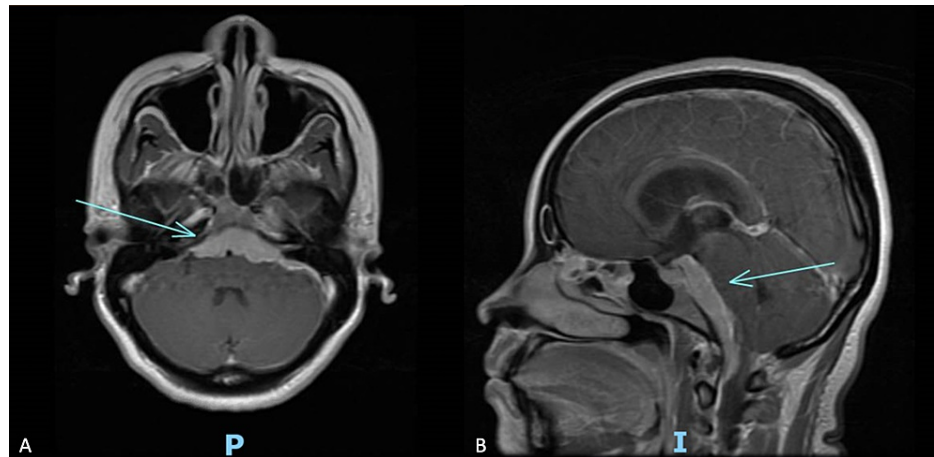


FIGURE 1: Pre-treatment brain MRI with contrast in axial (A) and sagittal (B) views demonstrate bulky enhancing tumor ventral to the pons at the skull base.

Immunohistochemical studies demonstrated positive staining of the plasma cells for CD138 and MUM-1 and negative staining for cyclin D1. A stain for CD20 highlighted B-lymphocytes in the background, and in situ hybridization studies for kappa and lambda showed lambda light chain restriction in the plasma cells. While the initial frozen section evaluation suggested possible lymphoma, the final specimen analysis was consistent with a plasma cell neoplasm (Figure 2, 3).

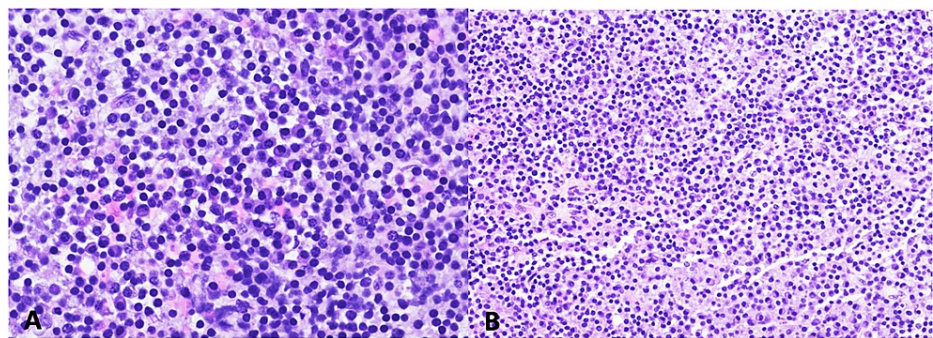


FIGURE 2: Microscopic examination shows a highly cellular tumor. The tumor comprises sheets of plasma cells and scattered lymphocytes which can be seen here at both high (A) and low magnification (B). The plasma cells have a moderate amount of cytoplasm. Mitoses were identified, and hemorrhagic areas were seen between the tumor cells.

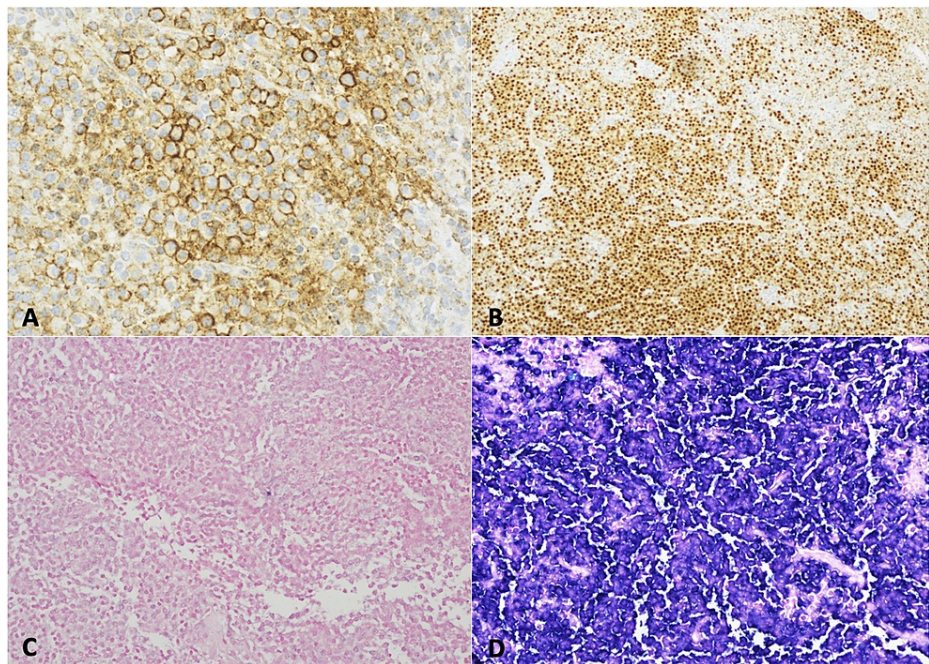


FIGURE 3: Immunohistochemistry showed the tumor to be CD 138 positive (A), MUM-1 positive (B), kappa negative (C), and lambda-positive (D).

A complete blood cell count with differential revealed iron deficiency anemia, and serum creatinine revealed normal kidney function. Immunoelectrophoresis revealed the presence of an IgG lambda monoclonal paraprotein, suggesting possible MM. Additional laboratory and radiographic tests were done to rule out MM and systemic disease (Table 1).

Type of Test	Pertinent Finding(s)	Reference Value
CBC with differential	RBC Count: 3.70 M/uL	3.80-5.20 M/uL
	HGB: 9.7 g/dL	11.5-15.5 g/dL
Serum β2 microglobulin	1.1 mg/L	0.8-2.2 mg/L
Metabolic Panel	Creatinine: 0.56 mg/dL	0.5-1.30 mg/dL
	Albumin: 4.4 g/dL	3.3-5.0 g/dL
Serum Immunoelectrophoresis	Beta-migrating paraprotein identified	n/a
	M-spike: 0.2 g/dL	0.0-0.0 g/dL
Serum Immunofixation	IgG lambda monoclonal paraprotein Identified: 1562 mg/dL	610-1660 mg/dL
Serum Ferritin	30 ng/ml	15-150 ng/ml
Bone Marrow Aspirate and Biopsy	No evidence of plasma cell myeloma	n/a
PET-CT FDG Skull to Thigh	No FDG-avid disease	n/a
Flow Cytometry	Insufficient for evaluation due to low specimen viability	n/a
Tumor Biopsy	Lambda light chain restricted neoplasm	n/a

TABLE 1: Diagnostic Testing

PET-CT-FDG: fluorodeoxyglucose-positron emission tomography

The serum $\beta 2$ microglobulin, albumin, and ferritin levels were normal. A whole-body PET-CT indicated no 2-(18F) fluoro-D-glucose (FDG) avid disease. A CT-guided bone marrow aspirate and biopsy confirmed a lack of systemic involvement, thereby excluding a diagnosis of MM.

The decision was then made to initiate treatment with proton beam radiotherapy using a 45 Gy dose delivered over 25 fractions (Figure 4). Follow-up imaging demonstrated complete resolution of the tumor (Figure 5). At three months follow-up, the patient remained asymptomatic, and the lambda monoclonal paraprotein was no longer detected.

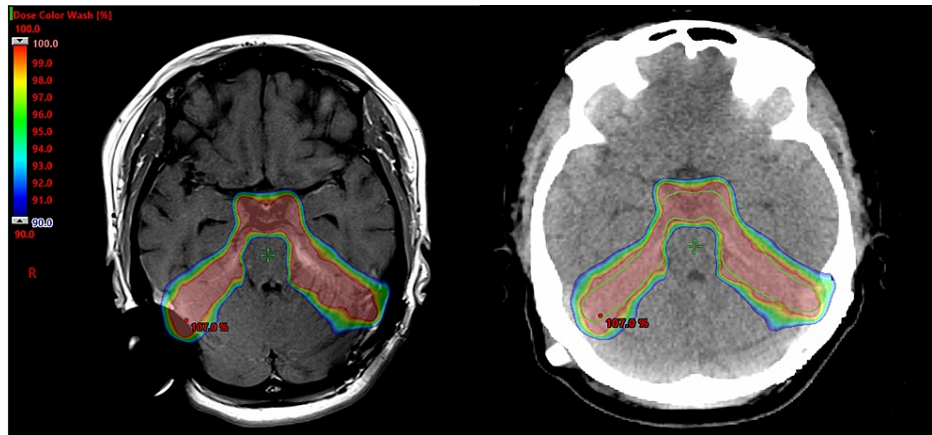


FIGURE 4: Proton-beam treatment plan. Here the dose spectrum highlights the steep radiation dose fall-off with limited exposure to the surrounding brain tissue. The target prescription dose of 45Gy (100%) is shown down to 40.8Gy (90% of prescription dose).

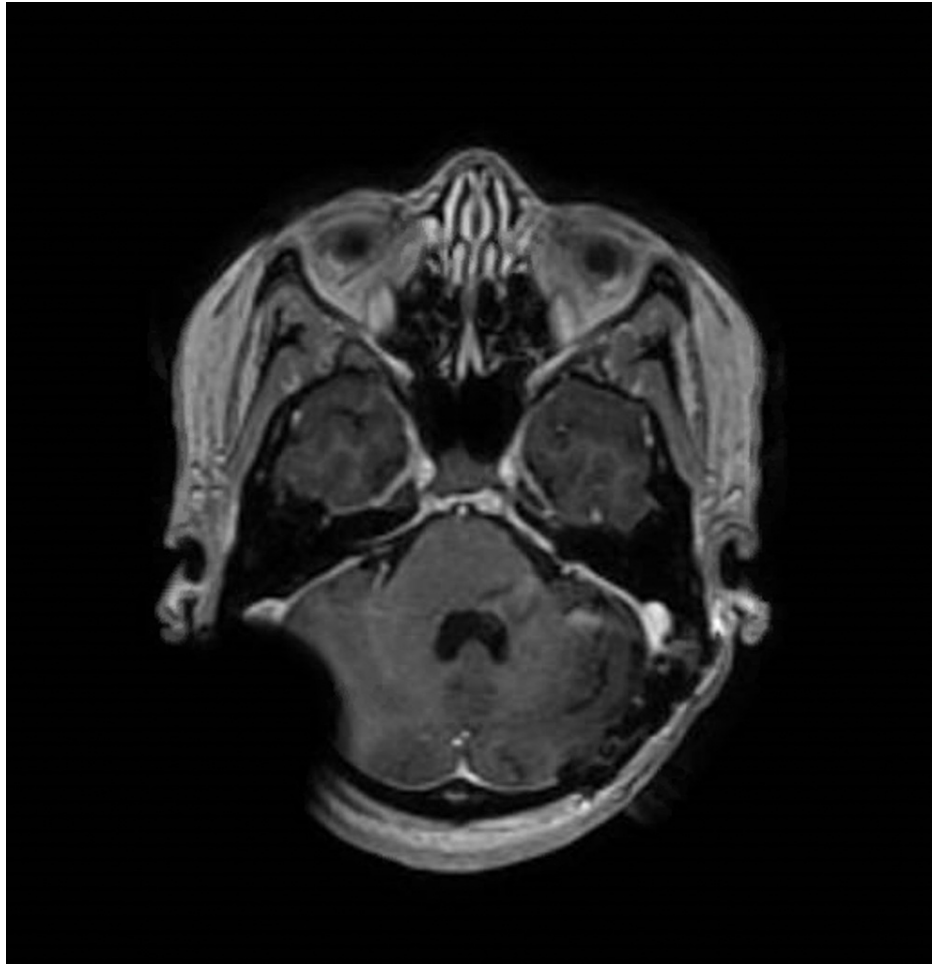


FIGURE 5: Contrast-enhanced MRI after completion of proton-beam radiotherapy shows complete resolution of the tumor.

Discussion

Solitary plasmacytomas (SP) comprise <10% of plasma cell neoplasms, while those isolated to the skull base are even rarer [1,3]. Nonetheless, patients with osseous plasmacytomas are at high risk for developing multiple myeloma (MM) in the years after treatment and require long-term monitoring [11]. While solitary plasmacytomas can progress to MM, they do not present with the typical clinical manifestations of MM, such as anemia and renal failure [12]. Thus, MM should always be initially ruled out in a patient with suspected SP not wrongfully to withhold needed systemic treatment [10,13].

We have found 12 previous reports of skull base SP identified in the literature from 2000 to 2018 (Table 2). The mean age of the patients was 49.2 years (range 28 to 66) at the time of diagnosis, and no gender predilection was noted. Anatomically, tumor locations include six cases in the clivus, one in the sphenoid sinus, one in the cavernous sinus, and four with speno-clival involvement. The most common presenting symptoms were headache and diplopia, attributable to associated third and sixth cranial nerve involvement [1,2,14]. The most common treatment reported was surgery followed by conventional radiotherapy (RT). The role of surgery in treating SPs is limited to diagnostic purposes and to assist with tumor debulking in lesions causing mass effect and neurologic deficits [1,2]. Conventional RT with a 40-50 Gy dose is typical [11,15,16].

Case	Date	Age	Sex	Location	Symptoms	Treatment	Radiation Dose	Follow-Up (months)	Author
1	2018	41	M	Central skullbase, clivus	Headache, diplopia, left eye strabismus	GTR, RT	50 Gy/25	3, stable	Siyag et al.
2	2012	50	F	Middle-upper clivus	Headache, diplopia	GTR, RT	46,8 Gy/26	165, stable	Gagliardi et al.
3	2012	53	F	Middle-upper clivus	Diplopia	GTR, RT	40 Gy/22	9, stable	Gagliardi et al.
4	2012	57	M	Upper clivus	Headache	STR, RT	45 Gy/25	20, stable	Gagliardi et al.
5	2012	66	F	Sellar region, upper clivus and sphenoid sinus	Bitemporal headache, diplopia	GTR, patient denial of CT and RT	n/a	3, death	Guinto-Balanzar et al.
6	2010	40	M	Clivus	Headache, blurry vision, diplopia,	RT, Thalidomide, Dexamethasone	30 Gy/10	2, stable	Kashyap et al.
7	2009	32	M	Sphenoid sinus	Ocular pain, diplopia	PR, RT	4,000cGy/20	8, stable	Park et al.
8	2008	54	F	Spheno-clival	Headache, right eye hemianopia, bilateral blind spot enlargement	PR, RT	45 Gy	22, stable	Liu et al.
9	2007	58	F	Right anterior petrous apex and clivus	Headache, right facial numbness	RT	45 Gy	18, stable	Husein et al.
10	2003	61	F	Cavernous sinus	Deteriorating vision, headaches	PR, RT	50 Gy	12, mass resolution	Brannan et al.
11	2003	50	M	Clivus	Binocular diplopia, headaches	RT, CT	45 Gy/25	8, stable	Brannan et al.
12	2000	28	M	Sphenoclival	Bifrontal headaches, diplopia	RT	5,400 cGy	3.5, stable	Wein et al.

TABLE 2: Solitary Plasmacytomas of the Skull Base

F, Female; M, Male; GTR, Gross Total Resection; STR, Sub-Total Resection; PR, Partial Resection; CT, Chemotherapy; RT, Radiotherapy

In the patient we present, proton radiotherapy resulted in complete tumor resolution within one month. Although the efficacy of proton beam therapy for myeloma and plasmacytoma has been suggested due to their known radiosensitivity, no rigorous studies have been performed [17,18]. This report is the first case demonstrating the utility of proton beam radiotherapy for a tumor of this kind in the skull base. The sharp dose fall-off profile of proton radiation makes it more appealing to use in the skull base than conventional RT [19]. This unique feature of proton beam therapy is especially valued in young patients.

As previously mentioned, SPs can progress to MM; however, the use of systemic therapy such as VRD (Velcade, Revlimid, and decadron) [20] is not thought to be preventative. Therefore, continued vigilant follow-up is indicated for patients like our present [1,21-24].

Conclusions

The case presented demonstrates the potential clinical utility of proton-beam radiation therapy as monotherapy in patients with skull base solitary plasmacytoma. In clinical scenarios such as this, consideration should be given to such a treatment approach to limit adjacent tissue radiation adverse effects and systemic toxicity. Additional studies will be needed to demonstrate the generalizability of this technique.

Additional Information

Disclosures

Human subjects: Consent was obtained or waived by all participants in this study. **Conflicts of interest:** In compliance with the ICMJE uniform disclosure form, all authors declare the following: **Payment/services info:** All authors have declared that no financial support was received from any organization for the submitted work. **Financial relationships:** All authors have declared that they have no financial relationships at present or within the previous three years with any organizations that might have an interest in the submitted work. **Other relationships:** All authors have declared that there are no other relationships or activities that could appear to have influenced the submitted work.

References

1. Siyag A, Soni TP, Gupta AK, Sharma LM, Jakhotia N, Sharma S: Plasmacytoma of the skull-base: a rare tumor. *Cureus*. 2018, 10:e2073. [10.7759/cureus.2073](https://doi.org/10.7759/cureus.2073)
2. Gagliardi F, Losa M, Boari N, Spina A, Reni M, Terreni MR, Mortini P: Solitary clival plasmocytomas: misleading clinical and radiological features of a rare pathology with a specific biological behaviour. *Acta Neurochir (Wien)*. 2013, 155:1849-56. [10.1007/s00701-013-1845-3](https://doi.org/10.1007/s00701-013-1845-3)
3. Na'ara S, Amit M, Gil Z, Billan S: Plasmacytoma of the skull base: a meta-analysis. *J Neurol Surg B Skull Base*. 2016, 77:61-5. [10.1055/s-0035-1560047](https://doi.org/10.1055/s-0035-1560047)
4. Husein OF, Jacob A, Massick DD, Welling DB: Recurrence of isolated multiple myeloma in the skull base: a case report and review of the literature. *Ear Nose Throat J*. 2007, 86:555-560. [10.1177/014556130708600910](https://doi.org/10.1177/014556130708600910)
5. Meyer JR, Roychowdhury S, Cybulski G, Russell EJ: Solitary intramedullary plasmacytoma of the skull base mimicking aggressive meningioma. *Skull Base Surg*. 1997, 7:101-5. [10.1055/s-2008-1058616](https://doi.org/10.1055/s-2008-1058616)
6. Wein RO, Papat SR, Doerr TD, Dutcher PO: Plasma cell tumors of the skull base: four case reports and literature review. *Skull Base*. 2002, 12:77-86. [10.1055/s-2002-31570-1](https://doi.org/10.1055/s-2002-31570-1)
7. Rajkumar SV, Dimopoulos MA, Palumbo A, et al.: International myeloma working group updated criteria for the diagnosis of multiple myeloma. *Lancet Oncol*. 2014, 15:538-548. [10.1016/s1470-2045\(14\)70442-5](https://doi.org/10.1016/s1470-2045(14)70442-5)
8. Cowan AJ, Green DJ, Kwok M, et al.: Diagnosis and management of multiple myeloma: a review. *JAMA*. 2022, 327:464-77. [10.1001/jama.2022.0003](https://doi.org/10.1001/jama.2022.0003)
9. Dispenzieri A, Kyle RA, Lacy MQ, et al.: POEMS syndrome: definitions and long-term outcome. *Blood*. 2005, 101:2496-506. [10.1182/blood-2002-07-2299](https://doi.org/10.1182/blood-2002-07-2299)
10. Bindal AK, Bindal RK, van Loveren H, Sawaya R: Management of intracranial plasmacytoma. *J Neurosurg*. 1995, 83:218-21. [10.3171/jns.1995.83.2.0218](https://doi.org/10.3171/jns.1995.83.2.0218)
11. Bolek TW, Marcus RB Jr, Mendenhall NP: Solitary plasmacytoma of bone and soft tissue. *Int J Radiat Oncol Biol Phys*. 1996, 36:329-333. [10.1016/s0360-3016\(96\)00334-3](https://doi.org/10.1016/s0360-3016(96)00334-3)
12. Di Micco P, Di Micco B: Up-date on solitary plasmacytoma and its main differences with multiple myeloma. *Exp Oncol*. 2005, 27:7-12.
13. Guinto-Balanzar G, Abdo-Toro M, Aréchiga-Ramos N, Leal-Ortega R, Zepeda-Fernández E, Nambo-Lucio Mde J: Plasma cell tumor of the clivus: report of two cases. *Cir Cir*. 2012, 80:171-176.
14. Movsas TZ, Balcer LJ, Eggenberger ER, Hess JL, Galetta SL: Sixth nerve palsy as a presenting sign of intracranial plasmacytoma and multiple myeloma. *J Neuroophthalmol*. 2000, 20:242-245.
15. Susnerwala SS, Shanks JH, Banerjee SS, Scarffe JH, Farrington WT, Slevin NJ: Extramedullary plasmacytoma of the head and neck region: clinicopathological correlation in 25 cases. *Br J Cancer*. 1997, 75:921-7. [10.1038/bjc.1997.162](https://doi.org/10.1038/bjc.1997.162)
16. Wong ET, Lu XQ, Devulapalli J, Mahadevan A: Cyberknife radiosurgery for basal skull plasmacytoma. *J Neuroimaging*. 2006, 16:361-3. [10.1111/j.1552-6569.2006.00062.x](https://doi.org/10.1111/j.1552-6569.2006.00062.x)
17. Kauffmann G, Buerki RA, Lukas RV, Gondi V, Chmura SJ: Case report of bone marrow-sparing proton therapy craniospinal irradiation for central nervous system myelomatosis. *Cureus*. 2017, 9:e1885. [10.7759/cureus.1885](https://doi.org/10.7759/cureus.1885)
18. Elsayad K, Oertel M, König L, et al.: Maximizing the clinical benefit of radiotherapy in solitary plasmacytoma: an international multicenter analysis. *Cancers (Basel)*. 2020, 12:[10.3390/cancers12050676](https://doi.org/10.3390/cancers12050676)
19. Hughes JR, Parsons JL: FLASH radiotherapy: current knowledge and future insights using proton-beam therapy. *Int J Mol Sci*. 2020, 21:[10.3390/ijms21186492](https://doi.org/10.3390/ijms21186492)
20. Joshi A, Jiang D, Singh P, Moffat D: Skull base presentation of multiple myeloma. *Ear Nose Throat J*. 2011, 90:E6-9. [10.1177/014556131109000113](https://doi.org/10.1177/014556131109000113)
21. Kashyap R, Kumar R, Kumar S: Cranial nerve palsy in multiple myeloma and solitary plasmacytoma. *Asia Pac J Clin Oncol*. 2010, 6:251-5. [10.1111/j.1743-7563.2010.01327.x](https://doi.org/10.1111/j.1743-7563.2010.01327.x)
22. Liu ZY, Qi XQ, Wu XJ, Luo C, Lu YC: Solitary intracranial plasmacytoma located in the sphenoclivar region mimicking chordoma: a case report. *J Int Med Res*. 2010, 38:1868-75. [10.1177/147323001003800535](https://doi.org/10.1177/147323001003800535)
23. Brannan SO, Matthews BN, Savant V, Brown RD, Matthews TD: Solitary intracranial extra-osseous plasmacytoma presenting with ophthalmic signs. *J Neuroophthalmol*. 2003, 23:268-71. [10.1097/00041327-200312000-00006](https://doi.org/10.1097/00041327-200312000-00006)
24. Park SH, Kim YZ, Lee EH, Kim KH: Endoscopic endonasal transsphenoidal resection of solitary extramedullary plasmacytoma in the sphenoid sinus with destruction of skull base. *J Korean Neurosurg Soc*. 2009, 46:156-60. [10.3340/jkns.2009.46.2.156](https://doi.org/10.3340/jkns.2009.46.2.156)