





Dual Microscope Indocyanine Green Video Angiography and Endoscopic Review to Treat Intracranial Aneurysm: A Review of the Literature Regarding a Case

Daniel Alejandro Vega-Moreno¹ Dragan Janković² Heba Azouz³ Mayank Nakipuria⁴ Yoko Kato⁵

¹Neurosurgery Department, Postgraduate Division, Faculty of Medicine, National Autonomous University of Mexico, Mexico City, Mexico

²Neurosurgery Department, University Hospital Mainz, Maguncia, Germany

³Neurosurgery Department, Children's Cancer Hospital Egypt, Cairo, Egypt

⁴Neurosurgery Department, GTB Hospital, New Delhi, India

Address for correspondence Daniel Alejandro Vega-Moreno, MD, Postgraduate Division, Faculty of Medicine, National Autonomous University of Mexico. Circuito de Posgrados s/n, Ciudad Universitaria, Coyoacán, C. P. 04510, Ciudad de México (e-mail: d2206.dv@gmail.com).

⁵Neurosurgery Department, Fujita Health University Banbuntane Hotokukai Hospital, Nagoya, Aichi, Japan

Asian J Neurosurg 2023;18:701–707.

Abstract

The use of the indocyanine green video angiography (ICG-VA) both endoscope and microscope has become popular in recent decades thanks to the safety, efficacy, and added value that they have provided for cerebrovascular surgery. The dual use of these technologies is considered complementary and has helped cerebrovascular surgeons in decision-making, especially for aneurysm clipping surgery; however, its use has been described for both aneurysm surgery, resection of arteriovenous malformations, or even for bypass surgeries. We conducted a review of the literature with the MeSH terms “microscope indocyanine green video angiography (mICG-VA),” “endoscopic review,” AND/OR “intracranial aneurysm.” A total of 97 articles that included these terms were selected after a primary review to select a total of 26 articles for the final review. We also present a case to exemplify its use, in which we use both technological tools for the description of the aneurysm, as well as for decision-making at the time of clipping and for reclipping. Both tools, both the use of the endoscope and the mICG-VA, have helped decision-making in neurovascular surgery. A considerable clip replacement rate has been described with the use of these technologies, which has helped to reduce the complications associated with poor clipping. One of the main advantages of their usefulness is that they are tools for intraoperative use, which is why they have shown superiority compared to digital subtraction angiography, which takes longer to use and has a higher risk of complications associated with the contrast medium. On the other hand, a very low rate of complications has been described with the use of the endoscope and mICG-VA, which is why they are considered safe tools to use. In some cases, mention has been made of the use of one or the other technology;

Keywords

- ▶ microscope indocyanine green video angiography
- ▶ endoscopic review
- ▶ intracranial aneurysm
- ▶ aneurysm clipping
- ▶ cerebrovascular surgery

article published online
November 30, 2023

DOI <https://doi.org/10.1055/s-0043-1775584>.
ISSN 2248-9614.

© 2023. Asian Congress of Neurological Surgeons. All rights reserved.

This is an open access article published by Thieme under the terms of the Creative Commons Attribution-NonDerivative-NonCommercial-License, permitting copying and reproduction so long as the original work is given appropriate credit. Contents may not be used for commercial purposes, or adapted, remixed, transformed or built upon. (<https://creativecommons.org/licenses/by-nc-nd/4.0/>)

Thieme Medical and Scientific Publishers Pvt. Ltd., A-12, 2nd Floor, Sector 2, Noida-201301 UP, India

however, we consider that its dual use provides more information about the status of the clip, its anatomy, its relationship with other vascular structures, and the complete occlusion of the aneurysm. We consider that the use of both technologies is complementary, so in case of having them both should be used, since both the endoscope and the mICG-VA provide additional and useful information.

Introduction

The use of the endoscope in neurosurgery dates back to 1910 and although its main use has been described for skull base surgeries or access to the ventricular system, it has also been described for other types of procedures, especially neurovascular surgery.¹ The technique of using the endoscope for vascular approaches has been called endoscope-assisted microneurosurgery, which has been useful from direct clipping procedures in endonasal approaches, clip revisions, clip replacement, search for perforating branches, and even revision of the aneurysm once clipped, reporting a very low rate of complications associated with its use.²⁻⁴ Direct clipping using only the endoscope is rare, so until now its use has been limited to checking the clip once it is in place and the shape of the aneurysm in relation to its perforating branches.⁵ Certainly, and despite its greater routine use in operating rooms, very little attention has been paid to reviewing and characterizing aneurysm domes, as well as their morphology, which is especially important since these characteristics inform us about trans-surgical risk of rupture, previous ruptures, or difficulty during clipping. The structure of the aneurysm dome, its shape, and the presence of added lesions such as cholesterol plaques, calcifications, or bleb can tell us about areas of greater hemodynamic stress, which is especially important since it can guide us in making decisions at the moment to place or reposition a clip.⁶ On the other hand, indocyanine green video angiography (ICG-VA) since 2003 has demonstrated its importance in decision-making in vascular neurosurgery, for the treatment of cerebral aneurysms, arterio-venous malformations, or bypass surgeries both microscopic and endoscopic.⁷ However, to date, priority has been given to the use of one or the other device, with very few studies that have been carried out with both devices and that have demonstrated their joint efficacy as dual management.

We present the case of clipping of an internal carotid artery aneurysm of the right communicating segment that underwent both endoscopic and microscope ICG-VA (mICG-VA) revision.

Materials and Methods

Methods

For the review, we used the MeSH terms “microscope indocyanine green video angiography,” “rigid endoscopy,” AND/OR “intracranial aneurysm” on the PubMed, Google Scholar, and Springer platforms. We initially reviewed a total of 97 articles, and after applying the inclusion terms and

reviewing the abstracts, we were left with a total of 26 articles that included meta-analyses, reviews, original articles, and case series. We included those articles that spoke directly about the dual use of both technologies for clipping and revision of intracranial aneurysms or other cerebrovascular pathologies, as well as benefits, uses, complications, and the comparison between both and with other technologies.

Case Presentation

A 71-year-old male presented with a history of hyperlipidemia and arterial hypertension, neurologically intact, who was diagnosed with an incidental aneurysm by magnetic resonance imaging (→Fig. 1). Conventional clipping was performed with the support of endoscope and mICG-VA. The microscope used for surgery was an KINEVO 900 (Carl Zeiss, Oberkochen, Germany) with 800 infrared cameras equipped with FLOW 800 software (Carl Zeiss, Oberkochen, Germany) and with real-time intraoperative ICG-VA that provides hemodynamic information on blood flow. Also, QEVO microinspection tool that is used as additional adjunctive endoscope was used under microscopic guidance.

First, the neck, dome, and related perforating branches were completely dissected. The dome presented yellowish-white areas, which translated into areas with greater thickness and less risk of surgical rupture. In addition, a bleb was found on the rostral face of the aneurysm dome close to the neck and in close relationship with a perforating vessel. The usefulness of the mICG-VA in this case was that since we could not mobilize the aneurysm too much due to the risk of rupture, we were able to use this tool to decide if what we were seeing was a bleb or a perforating branch, so with safety and after the application of the ICG-VA we were able to demonstrate that what appeared to be two perforating vessels, in fact only the most proximal was a perforating vessel and the most distal to the neck was a bleb. To review the dorsal face of the aneurysm under the microscope, it was very difficult to perform because this would entail greater mobilization of the dome and increase the risk of rupture, so we used the endoscopic review. By this means, we observed the relationship of the multiple perforating branches as well as an area of less intense red thickness, with a greater risk of rupture, for which reason we had to be more careful when placing the clip (→Fig. 1).

Once the clip is in place, we corroborate its position under the microscope. And although at first sight the rostral perforating branch seemed well positioned and with adequate flow, with the endoscope we noticed the occlusion of a

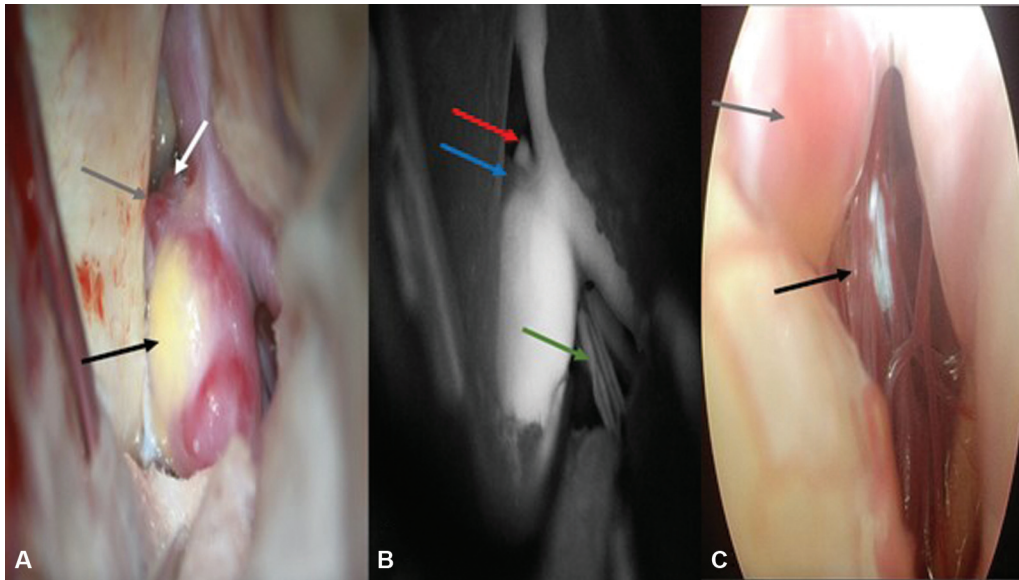


Fig. 1 (A) A completely dissected aneurysm was observed, a dome with abundant yellowish-white tissue that translates into a thicker area (black arrow). Multiple reddish areas on the dome of the aneurysm and some on the neck, which means an area of greater vessel weakness. Aneurysmal bleb (gray arrow), perforating branch (white arrow). (B) Support with microscope indocyanine green video angiography, perforating branch (red arrow) and aneurysmatic bleb (blue arrow) was observed on the rostral face of the aneurysm, as well as multiple perforating branches on the medial and dorsal face of the aneurysm (green arrow). (C) First endoscopic review before clipping where multiple perforating branches were observed on the internal and inferior face of the aneurysm (black arrow), as well as a thin neck with redness and yellowish-white tissue further toward its dome (gray arrow).

perforating vessel on the dorsal aspect, in addition to the incomplete occlusion of the neck of the aneurysm, for which reason it was decided to relocate it (–Fig. 2).

Once repositioned, the placement of the clip was verified first microscopically with the ICG-VA, which toward the rostral face, the perforating branch was appreciated with

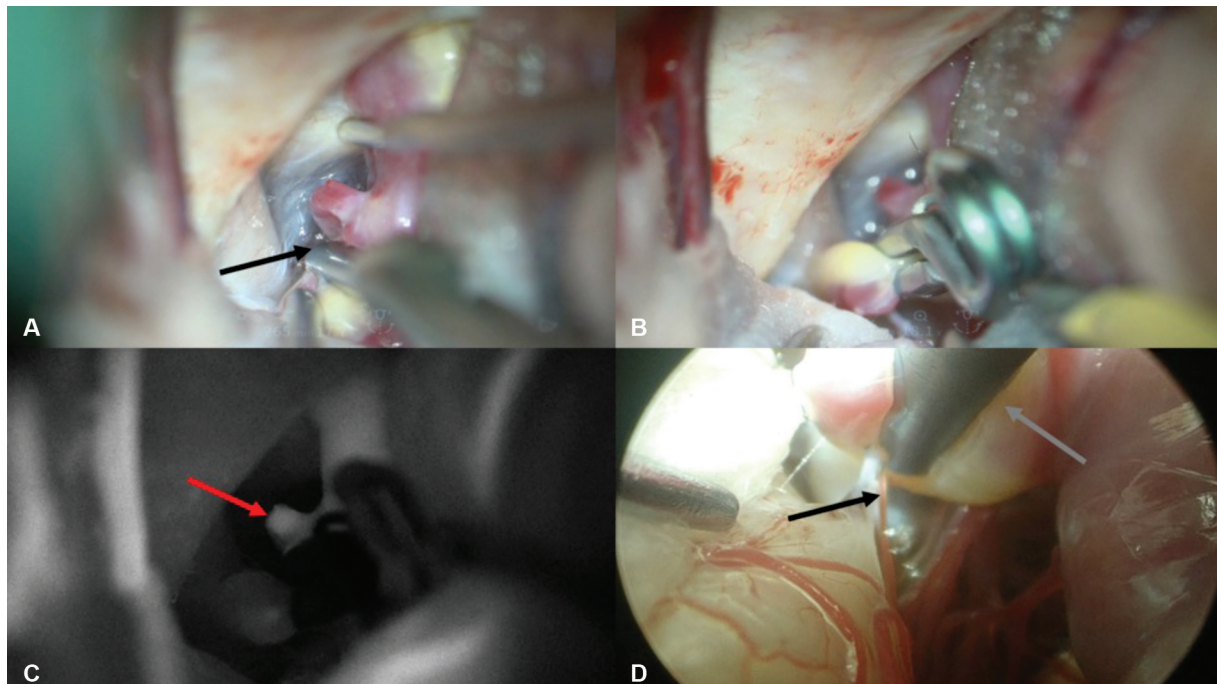


Fig. 2 (A and B) First clipping, note that it was decided to place a clip, leaving the perforating branch free but occluding the aneurysm bleb (black arrow). (C) Review with microscope indocyanine green video angiography. A free rostral perforating branch was observed (red arrow), with adequate flow after the first clipping. (D) Second endoscopic revision after the first clipping. Clamping of a perforating vessel (black arrow) was observed in the lower part of the clip, as well as incomplete occlusion of the aneurysm due to the white-yellow tissue found in the neck-dome transition site of the aneurysm (gray arrow).

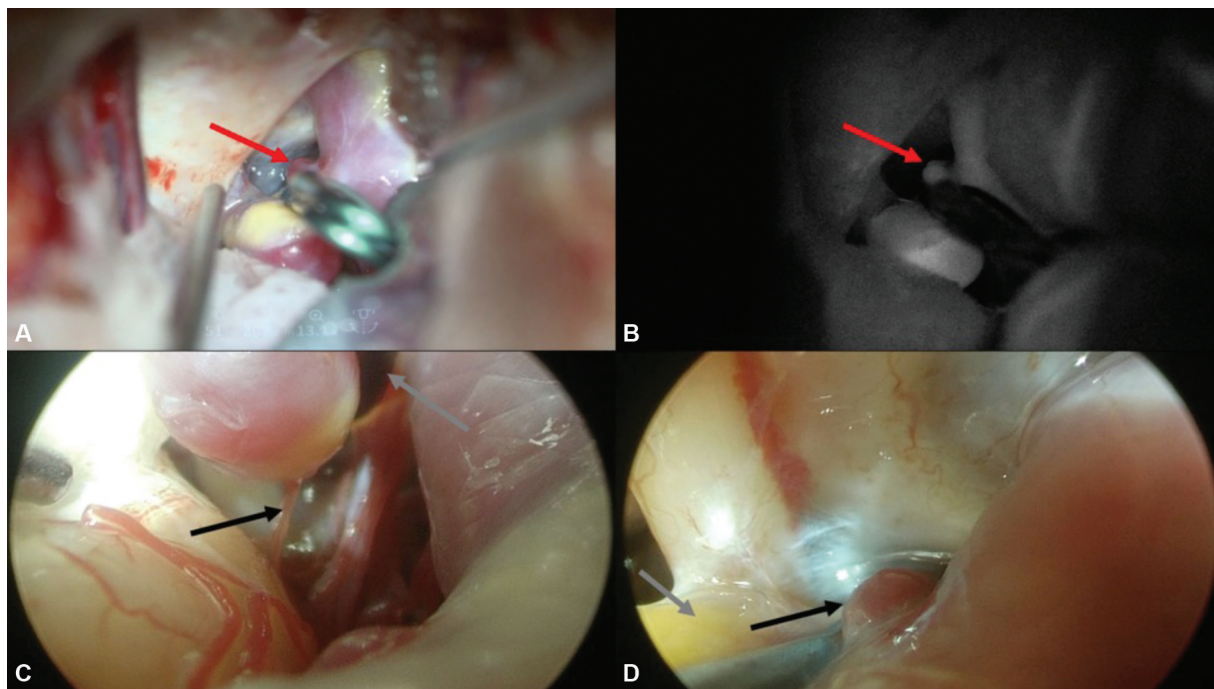


Fig. 3 (A and B) The proper position of the clip was observed, leaving the perforator vessel free on the rostral side of the aneurysm (black arrow), as well as adequate flow with the support of microscope indocyanine green video angiography (red arrow). (C) Third endoscopic revision. Inferior view, dorsal to the aneurysm, a totally free perforating vessel was observed (black arrow), dome of the aneurysm completely occluded from the circulation (grey arrow). (D) Superior view, rostral to the aneurysm, showing a free perforating vessel (black arrow) below the clip and abundant yellowish-white tissue (aneurysm thickening) in the aneurysm dome (grey arrow).

good flow and the aneurysmatic bleb was totally occluded and with the support of the endoscope we were able to verify the total occlusion of the aneurysmatic neck as well as the proper course and flow of the dorsal perforating branches (→Fig. 3). Surgery was completed without any postsurgical complications.

Discussion and Literature Review

It has been reported that aneurysms may have clearly defined sites of greater translucency (more redness than normal vessel) that suggest focal weakness, which translates into a greater risk of rupture of these sites.⁸ The morphology of the aneurysm dome has been classified as fine or superfine if translucent red areas are visible, or thick calcified for white or yellowish areas.⁶ In the same way, bleb can be found in the aneurysm during revisions, which can translate into areas of greater hemodynamic stress and with a greater risk of trans-surgical rupture.⁹ All of this can potentially be reviewed with an endoscope, reducing the mobilization of the aneurysm, its risk of rupture, or injury to adjacent vessels. Despite the more frequent use of the endoscope in vascular surgery, its use has been limited only to the revision of the clip, its repositioning, and its relationship with the perforating branches, but not in the revision of the aneurysm dome and, as we exemplified in our case, it is important to decide if a repositioning of the clip is feasible or not¹⁰⁻¹² (→Table 1).

In our case presented, we emphasize the need not only to review the perforating branches adjacent to the neck of the

aneurysm but also the characteristics of the dome, since as it happened, it was important for us to know that there were perforating branches on the dorsal face of the aneurysm but also that the clipped area was safe to attempt reclipping, since we found yellowish-white tissue present, which resulted in a thicker wall and therefore less risk of rupture when repositioning the clip.

Another important tool used in this case is the ICG-VA, which became popular in the ophthalmology in 1970s, but its use was more common from 2003 in neurosurgery.¹³ This tool has had an especially important use in vascular neurosurgery, mainly to reduce the risk of postclipping cerebral infarcts and to corroborate the patency of flow in the visualized perforating vessels.¹⁴ Far from thinking that both devices can compete with each other, it is preferred to think that both should be complementary, although endoscopic alone or with ICG-VA has certainly shown some superiority.¹⁵ In addition, one of the special advantages of the intraoperative use of mICG-VA and the endoscope is that the necessary clip adjustments can be made intraoperatively and do not require additional time as is the case with a digital subtraction angiography (DSA). The use of DSA can cause ischemia and cerebral infarcts due to the time required for the procedure or other complications associated with the use of contrast medium, arterial puncture, or manipulation of the internal carotid artery with a catheter.^{16,17} Adverse effects reported with the use of ICG-VA, whether microscopic or endoscopic, are seen in less than 0.1% of patients while up to 1.2% have been reported for conventional angiography

Table 1 Comparison of the use of endoscopic and microscopic devices with ICG-VA for aneurysm clipping surgery

Author and year	Type of study	Used device	Number of patients/aneurysms treated	Rate of position/reposition or change surgical decision	Overall complication rate	Direct related complications
Frazeo et al 1997 ¹	Case series	Endoscope (rigid, flexible and periscope)	10 patients (10 aneurysms)	0%	0%	0%
Shao et al 2022 ⁴	Meta-analysis	Endoscopic	1427 (1717 aneurysms)	13%	6%	0%
Fischer et al 2011 ⁵	Retrospective analysis	Endoscopic	124 (180 aneurysms)	20%	2.7%	0%
Raabe et al 2003 ⁷	Case series	mICG-VA	12 patients (12 aneurysms)	16%	0%	0%
Gallieni et al 2018 ¹⁰	Retrospective analysis	Endoscopic	191 (208 aneurysms)	20.2%	Not specified	2.4%
Chen, et al 2021 ¹¹	Case series	eICG-VA and mICG-VA	15 patients (15 aneurysms)	20%	0%	0%
Hashimoto, et al 2017 ¹²	Prospective	eICG-VA and mICG-VA	18 patients (18 aneurysms)	11%	11%	0%
Xue et al 2021 ¹⁴	Retrospective	mICG-VA	32 patients (42 aneurysms)	No specified	0%	0%
Fischer et al 2018 ¹⁵	Retrospective (comparative)	eICG-VA and mICG-VA	88 patients (108 aneurysms)	16.6% with eICG-VA and 12% to mICG-VA	6.5%	0%
Raabe, et al. 2005 ¹⁸	Prospective	mICG-VA	114 patients (124 aneurysms)	8%	No reported	0%
Nishiyama et al. 2012 ²²	Case series	eICG-VA and mICG-VA	three patients (three aneurysms)	33% with eICG-VA and 0% with mICG-VA	0%	0%
Cho et al 2017 ²³	Prospective	eICG-VA and mICG-VA	10 patients (10 aneurysms)	40% with ICG-VA and 0% with mICG-VA	50%	0%
Mielke et al 2014 ²⁴	Prospective	eICG-VA and mICG-VA	26 patients (30 aneurysms)	42.3% with eICG-VA and 3.3% with mICG-VA	No reported	0%

Abbreviations: eICG-VA, endoscopic indocyanine green video angiography; mICG-VA, microscopic indocyanine green video angiography.

studies because it is considered a completely invasive study.^{18,19} On the other hand, one of the main limitations of the use of mICG-VA is that the residual neck cannot be visualized if these is really small, or neither smaller caliber perforating branches due to limited viewing angles of the microscope; however, if we use both devices rigid endoscope and mICG-VA as in our case, on the one hand we can visualize the patency of the flow in the perforating vessels and on the other, with the endoscope, visualize if there were perforating vessels that are not recognized by mICG-VA and also the presence or absence of residual neck.^{20,21} Dual use of mICG-VA and endoscopy has been previously reported with good results and virtually no complications.²² Therefore, we consider that the dual use of these devices is completely safe and complementary, but not one superior to the other. A slight superiority of the use of the endoscope with ICG-VA has been demonstrated when the field to maneuver is small, such as in keyhole approaches for anterior circulation aneurysms; however, we consider that when it comes to an approach through a conventional craniotomy, there is no superiority between the two.²³

What most of us definitely agree on is that up to now, the use of the endoscope is the one that has generated the most number of retries and repositioning of the clip.^{15,23,24} Therefore, its utility in the future may take on greater strength and begin to be an indispensable tool for aneurysm clipping surgery.

Finally, one of the aspects to be highlighted is the usefulness of the ZEISS KINEVO microscope, with which it is possible to obtain images with intraoperative fluorescein and dually integrated endoscopic inspections; as well as 4K images that allow operating in exoscopic mode. This greatly facilitates the inspection of clipped aneurysms by surgeons, their relationship with perforating branches as well as the patency of flow within the aneurysm; it is also possible to switch manually or robotically from the microscopic view to the endoscopic view in a very simple and ergonomic.

Microscopic/endoscopic complementation is considered beneficial for high-quality visualization of fine structures and to reveal hidden anatomical details; however, despite its enormous advantages, one of its main limitations is that it lacks external fixation; its use is limited to working channel and the difficulty of changing to an optic from 0 to 30 degrees, that is, it is limited to a vision of 45 degrees only.^{25,26}

Conclusion

We present a case of a clipped cerebral aneurysm using two complementary technologies, the use of mICG-VA and endoscopic review, through which both devices provided us with valuable information for decision-making during surgery, for which we consider and recommend the dual use, as have demonstrated safe and highly effective. With the mICG-VA, we were able to observe the permeability of the perforating branches, as well as its correct flow; while with the endoscope, we could observe angles of the aneurysm that with the only use of the microscope would have been very difficult to visualize.

Authors' Contributions

Daniel Alejandro Vega-Moreno contributed to conceptualization, methodology, and writing—original draft. Dragan Janković was involved in investigation, review and editing—writing. Heba Azouz and Mayank Nakipuria were involved in investigation. Yoko Kato contributed to validation, supervision, and project administration. This manuscript was approved by Fujita Health University Banbuntane Hotokukai Hospital, Nagoya, Aichi, Japan.

Conflict of Interest

None declared.

References

- 1 Frazze JG, King WA, De Salles AA, Bergsneider M. Endoscopic-assisted clipping of cerebral aneurysms. *J Stroke Cerebrovasc Dis* 1997;6(04):240–241
- 2 Apuzzo MLJ, Heifetz MD, Weiss MH, Kurze T. Neurosurgical endoscopy using the side-viewing telescope. *J Neurosurg* 1977; 46(03):398–400
- 3 Sánchez-Calderón MD, Ochoa-Cacique D, Medina-Carrillo Ó, et al. [Clipping of an unruptured right paraclinoid aneurysm using an endoscopic endonasal approach: case report in a tertiary center in Mexico City]. *CIRU* 2021;89(S2):38–40
- 4 Shao D, Li Y, Zhang B, et al. Endoscope-assisted microneurosurgery for intracranial aneurysms: a systematic review and meta-analysis. *J Clin Neurosci* 2022;103:62–71
- 5 Fischer G, Oertel J, Perneczky A. Endoscopy in aneurysm surgery. *Neurosurgery* 2012;70(2, Suppl Operative):184–190, discussion 190–191
- 6 Kadasi LM, Dent WC, Malek AM. Cerebral aneurysm wall thickness analysis using intraoperative microscopy: effect of size and gender on thin translucent regions. *J Neurointerv Surg* 2013;5 (03):201–206
- 7 Raabe A, Beck J, Gerlach R, Zimmermann M, Seifert V. Near-infrared indocyanine green video angiography: a new method for intraoperative assessment of vascular flow. *Neurosurgery* 2003;52(01):132–139, discussion 139
- 8 Abruzzo T, Shengelaia GG, Dawson RC III, Owens DS, Cawley CM, Gravanis MB. Histologic and morphologic comparison of experimental aneurysms with human intracranial aneurysms. *AJNR Am J Neuroradiol* 1998;19(07):1309–1314
- 9 Satoh T, Yagi T, Sawada Y, Sugiu K, Sato Y, Date I. Association of bleb formation with peri-aneurysmal contact in unruptured intracranial aneurysms. *Sci Rep* 2022;12(01):1–8
- 10 Gallieni M, Del Maestro M, Luzzi S, Trovarelli D, Ricci A, Galzio R. Endoscope-Assisted Microneurosurgery for Intracranial Aneurysms: Operative Technique, Reliability, and Feasibility Based on 14 Years of Personal Experience [Internet]. In: Esposito G, Regli L, Kaku Y, Tsukahara T, eds. *Trends in the Management of Cerebrovascular Diseases*. Cham: Springer International Publishing; 2018:19–24
- 11 Chen DY, Xu CS, Fu K, et al. Application of neuroendoscopy combined with fluorescence angiography in anterior circulation aneurysm clipping. *Zhonghua Yi Xue Za Zhi* 2021;101(04): 254–258
- 12 Hashimoto K, Kinouchi H, Yoshioka H, et al. Efficacy of endoscopic fluorescein video angiography in aneurysm surgery—novel and innovative assessment of vascular blood flow in the dead angles of the microscope. *Oper Neurosurg (Hagerstown)* 2017;13(04): 471–481
- 13 Norat P, Soldozy S, Elsarrag M, et al. Application of indocyanine green videoangiography in aneurysm surgery: evidence, techniques, practical tips. *Front Surg* 2019;6:1–7

- 14 Xue T, Deng R, Gao B, et al. Intraoperative indocyanine green video angiography (ICG-VA) with FLOW 800 software in complex intracranial aneurysm surgery. *Chin Neurosurg J* 2021;7(01): 1–9
- 15 Fischer G, Rediker J, Oertel J. Endoscope- versus microscope-integrated near-infrared indocyanine green videoangiography in aneurysm surgery. *J Neurosurg* 2018;131:1–10
- 16 Balamurugan S, Agrawal A, Kato Y, Sano H. Intra operative indocyanine green video-angiography in cerebrovascular surgery: an overview with review of literature. *Asian J Neurosurg* 2011;6(02):88–93
- 17 Killory BD, Nakaji P, Gonzales LF, Ponce FA, Wait SD, Spetzler RF. Prospective evaluation of surgical microscope-integrated intraoperative near-infrared indocyanine green angiography during cerebral arteriovenous malformation surgery. *Neurosurgery* 2009;65(03):456–462, discussion 462
- 18 Raabe A, Nakaji P, Beck J, et al. Prospective evaluation of surgical microscope-integrated intraoperative near-infrared indocyanine green videoangiography during aneurysm surgery. *J Neurosurg* 2005;103(06):982–989
- 19 Vega-Moreno DA, Cordoba-Mosqueda ME, Aguilar-Calderón JR, et al. Retrospective analysis of two diagnostic tests: Carotid Doppler ultrasound and diagnostic cerebral angiography for carotid disease in the Mexican population. *Interdiscip Neurosurg* 2021;25:101138
- 20 Dashti R, Niemelä M, Hernesniemi J. The Role of Intra-operative Indocyanine Green Video-angiography in Cerebrovascular Surgery. *European Neurological Review* 2007:11–12
- 21 Mery FJ, Amin-Hanjani S, Charbel FT. Is an angiographically obliterated aneurysm always secure? *Neurosurgery* 2008;62(04):979–982, discussion 982
- 22 Nishiyama Y, Kinouchi H, Senboku Y, et al. Endoscopic indocyanine green video angiography in aneurysm surgery: an innovative method for intraoperative assessment of blood flow in vasculature hidden from microscopic view. *J Neurosurg* 2012;117(02):302–308
- 23 Cho W-S, Kim JE, Kang H-S, et al. Dual-channel endoscopic indocyanine green fluorescence angiography for clipping of cerebral aneurysms. *World Neurosurg* 2017;100:316–324
- 24 Mielke D, Malinova V, Rohde V. Comparison of intraoperative microscopic and endoscopic ICG angiography in aneurysm surgery. *Neurosurgery* 2014;10(Suppl 3):418–425, discussion 425
- 25 Nakao K, Thavara BD, Tanaka R, et al. Surgeon experience of the surgical safety with kinevo 900 in vascular neurosurgery: The initial experience. *Asian J Neurosurg* 2020;15(02):464–467
- 26 Schebesch K-M, Brawanski A, Tamm ER, Kühnel TS, Höhne J. QEVO® - A new digital endoscopic microinspection tool - a cadaveric study and first clinical experiences (case series). *Surg Neurol Int* 2019;10:1–5