

ORIGINAL ARTICLE

Analysis of the coincidence rate between imaging and pathological findings of pulmonary metastasis in 45 cases with invasive bone and soft tissue sarcoma

Zhen Huang¹, Keneng Chen², Xiaozheng Kang², Qing Zhang¹, Lin Hao¹, Yuan Li¹ & Xiaohui Niu¹

¹ Department of Orthopedic Oncology, Beijing Jishuitan Hospital, Peking University, Beijing, China

² Department of Thoracic, Beijing Cancer Hospital, Peking University, Beijing, China

Keywords

Bone and soft tissue sarcoma; coincidence rate; imaging; pathology; pulmonary metastasis.

Correspondence

Xiaohui Niu, Department of Orthopedic Oncology, Beijing Jishuitan Hospital, Peking University, Beijing, 100035, China.

Tel: +86 10 5851 6506

Fax: +86 10 5851 6736

Email: niuxiaohui@263.net

Received: 9 June 2014;

Accepted: 29 July 2014.

doi: 10.1111/1759-7714.12161

Thoracic Cancer 6 (2015) 180–185

Abstract

Background: It is not uncommon for imaging examinations of invasive bone and soft tissue sarcoma patients during initial treatment or postoperative follow-up to detect pulmonary nodules. This has important significance in determining the nature of nodules either for tumor staging and therapeutic regimen selection or for prognosis evaluation.

Methods: A review was carried out of invasive bone and soft tissue sarcoma patients diagnosed and treated in the department of orthopedic oncology of Beijing Jishuitan Hospital from June 2002 to June 2012. Data from patients who developed pulmonary metastases, diagnosed by imaging and treated surgically, were analyzed for consistency between imaging and postoperative pathological diagnoses.

Results: A total of 45 patients with pulmonary metastasis diagnosed by imaging and treated with resection of pulmonary lesions were included in the study. Thirty-eight cases with pulmonary metastases (84.4%) and seven cases without pulmonary metastases (15.6%) were confirmed by postoperative pathological examination. The most common pathological type in the latter patients was tuberculosis, with a total of four cases (57.1%).

Conclusion: There is a certain degree of misdiagnosis when using imaging for diagnosis of pulmonary metastasis, and attention should be paid to the pathological diagnosis of pulmonary metastasis in order to avoid overtreatment. Tuberculosis is most common in invasive bone and soft tissue sarcoma patients with pulmonary benign lesions, and it should be distinguished.

Introduction

As is well known, the lung is the most common site of metastases in invasive bone and soft tissue sarcoma (particularly osteosarcoma), and pulmonary metastasis is one of the major risk factors for death in bone and soft tissue sarcoma patients.^{1–3} According to statistics, the overall five-year survival rate for patients with osteosarcoma is 50–60%; however, after the occurrence of pulmonary metastasis, the five-year survival rate for patients with osteosarcoma drops to 37%.⁴ At present, the comprehensive treatment mode of chemotherapy combined with surgical resection of pulmonary metastases is the main therapeutic method for bone and soft tissue sarcoma with pulmonary metastases. The results of previous retrospective studies have shown that if the primary tumor is well controlled, radical resection of pulmonary

metastases can improve the survival rate of patients.^{5,6} However, there is no lack of bone and soft tissue sarcoma patients with benign pulmonary lesions in clinics and if they are misdiagnosed with pulmonary metastases, overtreatment will be harmful. Therefore, how to identify invasive bone and soft tissue sarcoma patients with benign or malignant pulmonary lesions is an urgent problem. Pulmonary lesions are difficult to diagnose and in order to avoid overtreatment and to determine the nature of the pulmonary lesions combined with bone and soft tissue sarcomas, thoracic surgery is of great significance. Therefore, we retrospectively analyzed the related data of 45 patients with pulmonary metastases diagnosed by imaging and treated with surgery. The aim of this paper was to explore and summarize the coincidence rate between imaging and pathological diagnoses and their characteristics.

Materials and methods

Patients

A review was carried out of invasive bone and soft tissue sarcoma patients diagnosed and treated in the department of orthopedic oncology of Beijing Jishuitan Hospital from June 2002 to June 2012. Patients who met the following criteria were enrolled in the study: (i) the primary tumor was confirmed by pathology; (ii) the standard treatment mode of pre-operative chemotherapy followed by surgery and postoperative chemotherapy, was adopted for the treatment of osteosarcoma;⁷ the treatment method for soft tissue sarcoma was radical surgery; patients with postoperative high risk factors (tumor > 5 cm, low histological grade, pulmonary metastases) were treated with adjuvant chemotherapy;⁸ patients without risk factors were observed regularly; (iii) patients underwent regular chest computed tomography (CT) examinations at first visit, before surgery, and every three months after surgery for two years; and (iv) indications for recommending patients for pulmonary surgery⁹ were that the primary tumor was cured and pulmonary metastases after chemotherapy were stable for more than three months, and patients with emerging pulmonary lesions needed to undertake pathological examination to determine strategies for further treatment.

Methods

A Toshiba Aquilion 64-Slice CT (Toshiba Medical Systems Corporation, Beijing, China) was used to scan the chest. The scanning conditions were as follows: 120KV, 20mAs, dose length product (DLP) 99.4mGy, slice thickness 0.8 mm, pitch 1.5. The pulmonary nodules were automatically extracted from the scan images of the chest using Toshiba post processing software (Lung nodules Analysis, Toshiba Medical Systems Corporation) and confirmed by two experienced radiologists; when the radiologists had different views, they could discuss with clinicians and determine the results together.

Chest CT examination revealed typical signs of pulmonary metastases, such as multiple spherical lesions with variable size in both lungs (≥ 10 mm), with smooth edges, uniform density, more commonly localized in the lower pulmonary fields.¹⁰ Clinical follow-up observation was carried out for patients who could not be definitely diagnosed in the first examination. If regular re-examination using chest CT showed that the pulmonary nodules were larger and increased, or if they shrank or disappeared, a diagnosis of pulmonary metastases could be considered.

Two pathologists with experience in the diagnosis of bone and soft tissue sarcomas checked the pathological slices simultaneously, and wrote a pathological report after com-

Table 1 Clinical features of 45 cases of bone and soft tissue sarcoma with pulmonary metastasis diagnosed by imaging

Gender	<i>n</i>
Male	30
Female	15
Median age	22 (10–61)
Primary tumor	
OS	32
CS	4
Other soft tissue sarcoma	9
Number of pulmonary lesions	
Single	34
Multiple	11
Median time to occurrence of pulmonary lesion (months)	8.8 (0–99)
At initial diagnosis	16
During chemotherapy	6
During follow up after treatment	23

CS, chondrosarcoma; OS, osteosarcoma.

paring the pathology of primary lesions with the postoperative pathology of pulmonary lesions.

The coincidence rate between imaging and pathological diagnoses was analysed and the incidence of bone and soft tissue sarcomas combined with other pulmonary lesions and the classification of common diseases were investigated.

Statistical analyses were performed according to the different pathological results. The coincidence rate between imaging and pathological diagnoses was evaluated using clinical features of the cases and the correlation of CT imaging features of pulmonary lesions (such as lesion edge, lesion location, whether there were signs of lobulation, internal calcification, and pleural retraction) with the pathological features of pulmonary lesions. SPSS16.0 statistical software was applied for statistical analysis and measurement data were analyzed using χ^2 test. A significant difference was defined as $P < 0.05$.

Results

General features

A total of 45 patients diagnosed with pulmonary metastases by chest CT were included in the study. After the primary lesion was cured and chemotherapy completed, the pulmonary metastases were stable for more than three months. When the emerging pulmonary lesions needed to be examined by pathology for determining the strategies for further treatment, resection of pulmonary lesions was performed. As shown in Table 1, among the 45 patients, there were 30 men (66.7%) and 15 women (33.3%), with a median age of 22 years (10–61 years). There were 32 cases of osteosarcoma (71.1%), four cases of chondrosarcoma (8.9%), and nine

cases of other soft tissue sarcomas (20.0%). According to the number of pulmonary lesions, there were 34 cases with multiple pulmonary lesions (75.6%) and 11 cases with solitary pulmonary lesions (24.4%). In the whole group of patients, the median time to occurrence of pulmonary metastases was 8.8 months (0–99 months). Sixteen (35.6%) patients with pulmonary metastases were diagnosed by imaging at initial treatment, six (13.3%) during treatment, and 23 (51.1%) after treatment. Reviewing the pulmonary lesions on chest CT, there were 31 cases of clear lesion edges (68.9%) and 14 cases of fuzzy boundaries (31.1%). The lesions were more commonly located in a single lung (34 cases, 75.6%), than in both lungs (11 cases, 24.4%), and there were 35 cases of peripheral lesions (77.8%) and 10 cases of central lesions (22.2%). The vast majority of patients had no mineralization of pulmonary lesions (37 cases, 82.2%). Varying degrees of mineralization were observed in the pulmonary lesions of eight patients (17.8%). Pulmonary lesions were demonstrated as signs of lobulation, burr, and pleural retraction, with 11 (24.4%), one (2.2%), and four cases (8.9%), respectively. None of the cases with pulmonary lesions showed voids.

Positron emission tomography (PET)-CT is very expensive for screening, so only 11 cases (24.4%) among the 45 received PET-CT examinations. In these eleven patients, the maximum diameter of pulmonary nodes was 0.87 cm (0.63–4.9 cm), and the average maximum standardized uptake value (SUV_{max}) was 1.65 (0–6.5), with three cases (27.3%) showing an SUV value greater than two.

Most patients with pulmonary metastases had no obvious symptoms; symptoms similar to those of the primary pulmonary cancer appear at an advanced stage. For example, with spontaneous pneumothorax pleural effusion and pleuritic chest pain are the first clinical manifestations; however, the vast majority of patients had no related positive signs. None of the patients experienced respiratory symptoms, such as chest pain, suffocation, hemoptysis, cough or fever.

Surgical methods

Among the 45 patients undergoing pulmonary surgery, three patients underwent lobectomy and 42 patients underwent pulmonary wedge resection. Two patients underwent secondary wedge resection of pulmonary metastases. Although the areas and purposes of the surgical resections were slightly different, all patients underwent surgery under the thoracoscope and were discharged after three to four days, with no wound complications.

The coincidence rate between pathological and imaging findings

Among 45 invasive bone and soft tissue sarcoma patients with pulmonary metastasis diagnosed by imaging and treated with

resection of pulmonary lesions, 38 patients (84.4%) were confirmed pathologically with pulmonary metastases and seven patients (15.6%) were diagnosed pathologically with non-metastatic lesions. Among seven cases with inconsistencies between pathological and imaging findings, the most common pulmonary lesion was tuberculosis (4 cases, 57.1%). Of the remaining three cases, one patient had cryptococcal infection; pathology showed chronic inflammatory cell infiltration and no cancer in one patient; and old subpleural hemorrhage with fibrous tissue hyperplasia in one patient (Fig 1a–e).

Correlation analysis of clinical and computed tomography morphological features of patients with pulmonary lesions

There were seven patients with an inconsistency between pathological and imaging findings (15.6%), and their clinical and imaging features are shown in Table 2. Among seven patients with non-metastatic lesions, the average time interval between surgery of the primary tumor and the occurrence of pulmonary lesions was 15.5 ± 31.2 months (0–85.5 months, the median time interval 2.8 months). All seven patients had single lesions: one lesion was centrally located, and the remaining six lesions were located in the periphery of lung. The average size of the pulmonary lesions was 12.5 ± 4.91 mm (6.3–18.4 mm, the median size 15 mm). CT showed that there were three cases (42.9%) of pulmonary lesions with clear edges and four cases (57.1%) with fuzzy edges. All seven patients had no signs of lobulation, pleural retraction, burrs or voids. Three patients had pulmonary lesions after the end of treatment and were treated immediately with pulmonary surgeries; pathology results showed two cases of tuberculosis and one case of cryptococcosis.

Three patients had pulmonary lesions during initial treatment. Two patients underwent pulmonary surgeries when the primary tumors were cured and the pulmonary metastases after chemotherapy were stable. Pathology results showed tuberculosis and chronic inflammatory cell infiltration, with no visible tumors. One patient with a low malignant tumor was observed routinely for six months after primary lesion resection, and then underwent pulmonary surgery. Postoperative pathological results showed tuberculosis. One patient had a pulmonary lesion during chemotherapy and underwent pulmonary surgery when the primary tumor was cured and the pulmonary metastasis after chemotherapy was stable. This case was pathologically considered as old subpleural hemorrhage with fibrous tissue hyperplasia (Fig 1).

Among 38 patients (84.4%) with coinciding clinical and pathological findings, the average time interval between surgery of the primary tumor and occurrence of the pulmonary lesion was 21.5 ± 22.8 months (0–99.7 months, median time interval 14.4 months), which was slightly longer than

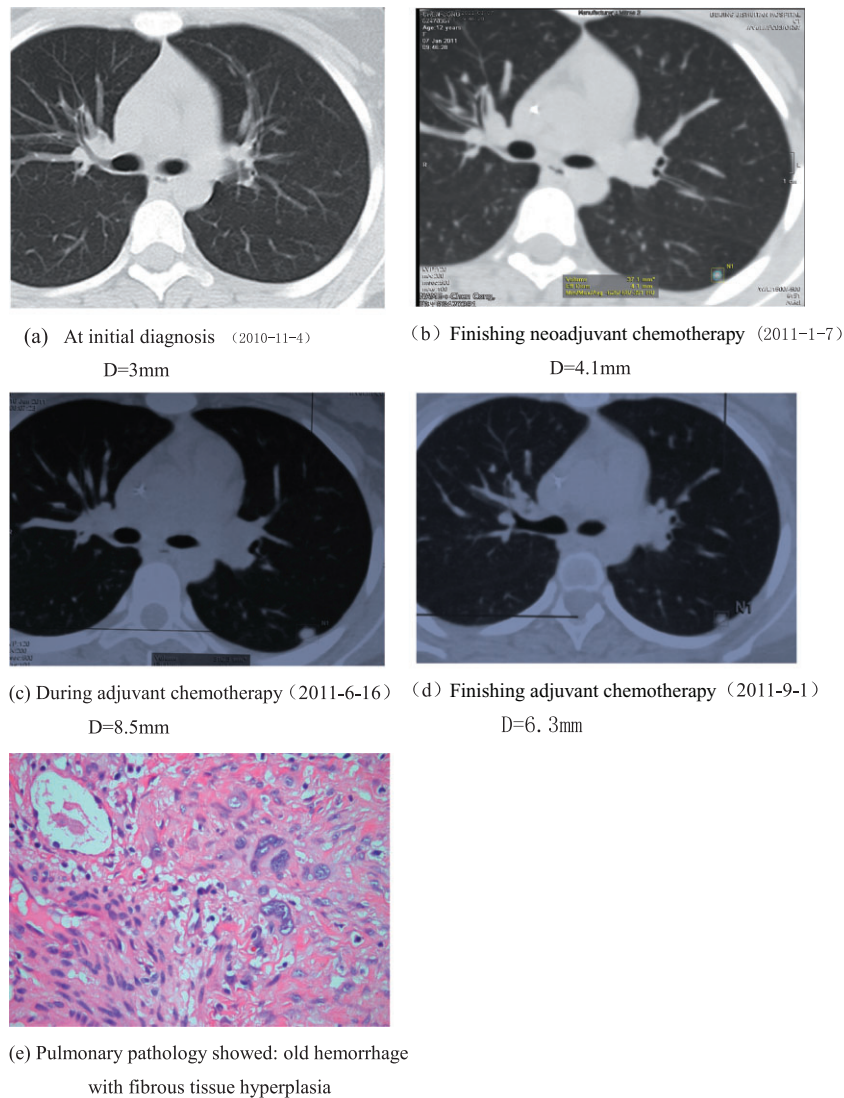


Figure 1 (a–e) A 12-year old female patient, diagnosed with osteosarcoma in the right distal femur. The small pulmonary nodule that occurred during initial treatment gradually enlarged during the process of treatment; the pulmonary lesion was stable after continuing chemotherapy, and then wedge resection of the pulmonary lesion was performed under the thoracoscope. Postoperative pathology showed a non-metastatic lesion.

that of patients whose clinical and pathological findings did not match, but did not reach statistical significance ($P = 0.595$). The average diameter of pulmonary lesions was 14.0 ± 8.1 mm (5–41 mm, the median diameter 11 mm), which was slightly greater than that of patients whose clinical and pathological findings did not match, but also did not reach statistical significance ($P = 0.278$).

Whether the pulmonary lesions of patients were metastatic or not had no relationship with gender ($P = 0.403$), diagnosis of primary tumor ($P = 0.7$), surgical method ($P = 0.582$), resection approach of pulmonary lesions ($P = 0.241$), pulmonary lesion location ($P = 0.216$), mineralization on CT ($P = 0.302$), lobulation ($P = 0.182$), burrs ($P = 0.870$), or pleural retraction ($P = 0.564$). However, these results suggest that

when patients with invasive bone and soft tissue sarcoma had multiple pulmonary lesions, the probability of pulmonary lesions to be pathologically confirmed as pulmonary metastases was greater ($P = 0.038$).

Discussion

It is not uncommon that patients with invasive bone and soft tissue sarcoma tumors, especially osteosarcoma, have small pulmonary nodules found accidentally by chest CT at the first visit or during follow-up; however, once found, how to identify metastases is always a problem for clinicians. Although imaging experts usually take a lesion diameter of more than 1 cm as a threshold value for diagnosis of malignant lesions,

Table 2 Clinical and imaging features of seven patients with inconsistencies between pathological and imaging findings

No.	Gender	Diagnosis	Surgical method for primary lesions	Pathologic result	Time to occurrence of pulmonary metastases (m)	Surgical method for pulmonary lesions	Number of pulmonary metastases	Location of pulmonary lesions	Morphology	Mineralization	Relationship with pulmonary field	Edge	Size (mm)
1	Male	Osteosarcoma in the right distal femur	Segmental excision + joint prosthesis	Tuberculosis	85.5	Wedge resection	Single	Superior lobe of right lung	Circular	No	Periphery	Clear	7.4
2	Male	Chondrosarcoma in the left ilium	Local resection	Tuberculosis	2.8	Wedge resection	Single	Superior lobe of left lung	Circular	No	Periphery	Unclear	15
3	Male	Osteosarcoma in the right proximal tibia	Segmental excision + joint prosthesis	Tuberculosis	0	Wedge resection	Single	Superior lobe of right lung	Elongated	No	Periphery	Unclear	16.8
4	Male	Spindle cell sarcoma in the left humerus	Segmental excision + joint prosthesis	Tuberculosis	0	Wedge resection	Single	Superior lobe of right lung	Elongated	No	Subpleural	Unclear	18.4
5	Female	Osteosarcoma in the right distal femur	Segmental excision + whole femur replacement	Negative	0	Wedge resection	Single	Superior lobe of left lung	Circular	No	Subpleural	Clear	6.3
6	Male	Osteosarcoma in the right proximal fibula	Segmental excision + joint prosthesis	Negative	8.5	Wedge resection	Single	Superior lobe of left lung	Circular	No	Periphery	Clear	8.7
7	Male	Osteosarcoma in the right distal femur	Segmental excision + joint prosthesis	Cryptococcus	12	Wedge resection	Single	Superior lobe of left lung	Quasi-circular	No	Central	Unclear	15

studies have indicated that a pulmonary lesion of less than 1 cm in diameter also has a high risk of malignancy (48–58%), and patients with a history of malignant tumor have a higher risk (62–81%).^{11,12} Munden *et al.* retrospectively studied the illness development situations of 102 tumor patients with small pulmonary nodules accidentally found during the period of follow-up (diameter less than 4 mm), and the results showed that 28% of pulmonary nodules were progressively enlarged, indicating that they were metastatic lesions.¹³ For patients with a history of extrapulmonary malignancy, the possibility of combined pulmonary nodules to be considered as metastases in the first instance is greater. However, in terms of the nature of pulmonary nodules, there may be several possibilities, such as primary pulmonary cancer, metastatic tumors, and benign lesions.¹⁰ Determining the nature of pulmonary nodules has important significance for tumor staging, treatment selection, and prognostic evaluation.

Chest CT is considered the most effective means to discover pulmonary metastases. Pulmonary metastases from osteosarcoma and soft tissue sarcoma are usually present as multiple forms; however, the single form is also not uncommon. The morphologies of pulmonary nodules on CT have suggested that significance lies in determining whether pulmonary nodules are primary or metastatic, or even judging the source of metastases.^{14,15} However, imaging is less reliable in deducing the nature of this type of pulmonary nodule with a history of extrapulmonary malignancy and it cannot be used as the sole basis for treatment decisions. The study of Peuchot and Libshitz on the relationship between X-ray and surgical findings of pulmonary metastases showed that in 237 pulmonary nodules, the coincidence rate between nodular pulmonary metastases identified by pre-operative CT scan and their surgical findings was only 73%.¹¹ Pulmonary metastases accounted for 84.4% (38/45) in this group, slightly higher than that reported in the literature. No primary pulmonary cancer was discovered, but the occurrence rate of non-metastatic lesions reached 15.6% (7/45), which also highlights the importance of surgery for pathological diagnosis. In this group, diagnostic accuracy was confirmed pathologically in 84.4% of patients with pulmonary metastases diagnosed by chest CT; however, the false positive rate was 15.6%, suggesting that if relying upon chest CT to diagnose pulmonary metastases in bone and soft tissue sarcoma patients, approximately 15.6% of the patients will be included into advanced stage and, subsequently, receive overtreatment. For the bone and soft tissue sarcoma patients with pulmonary metastases diagnosed by imaging, pathological confirmation should be actively recommended.

There is no dispute on the status of thoracic surgical intervention in the treatment of pulmonary metastases from osteosarcoma and soft tissue sarcoma. Surgical indications include: (i) the tumor in the primary site has been cured; (ii)

there is no extrapulmonary metastasis in other parts of the body; (iii) all metastases must be able to be resected completely; and (iv) a patient with a good heart and lung function can tolerate the surgery. Wedge resection or pulmonary lobectomy is the most common surgical treatment for pulmonary metastases. In the course of surgical resection, normal pulmonary tissues should be retained as far as is possible so that the patient can still accept surgical treatment if the recurrence of pulmonary metastases occurs; meanwhile, the quality of life of patients who cannot undergo surgery again may also be improved. Double lobectomy and even total pneumonectomy should be avoided if possible. The two kinds of surgical method were applied in this group of patients not only in order to remove the tumor, but also to preserve more normal pulmonary tissue.

Within the group of seven patients with inconsistencies between pathological and imaging findings, tuberculosis accounted for the vast majority of misdiagnosed pulmonary metastases. As immunity is low in patients with malignant tumors, the probability of developing tuberculosis is greater (57.1% in this group of patients). More attention should be paid to remind us to perform purified protein derivative (PPD), erythrocyte sedimentation rate (ESR), and Calmette's tests to assist in differential diagnosis in clinical practice when pulmonary lesions are discovered in patients with extrapulmonary malignancy.

Conclusion

There is a certain degree of misdiagnosis when using imaging for the diagnosis of pulmonary metastasis. Attention should be paid to the pathological diagnosis of pulmonary metastasis in order to avoid overtreatment. This single-center study with a small sample size showed that pulmonary metastases account for about 84.4% of pulmonary lesions combined with bone and soft tissue sarcoma, with a misdiagnosis rate of 15.6%. Tuberculosis is most common in misdiagnosed cases. It is difficult to clearly identify pulmonary lesions in patients with invasive bone and soft tissue sarcoma using imaging; therefore, pulmonary surgery should be performed to determine pathology and avoid overtreatment.

Disclosure

No authors report any conflict of interest.

References

- Davidson RS, Nwogu CE, Brentjens MJ, Anderson TM. The surgical management of pulmonary metastasis: current concepts. *Surg Oncol* 2001; **10**: 35–42.
- Tsuchiya H, Kanazawa Y, Abdel-Wanis ME *et al.* Effect of timing of pulmonary metastases identification on prognosis of patients with osteosarcoma: the Japanese Musculoskeletal Oncology Group study. *J Clin Oncol* 2002; **20**: 3470–7.
- Kager L, Zoubek A, Pötschger U *et al.* Primary metastatic osteosarcoma: presentation and outcome of patients treated on neoadjuvant Cooperative Osteosarcoma Study Group protocols. *J Clin Oncol* 2003; **21**: 2011–8.
- Briccoli A, Rocca M, Salone M, Guzzardella GA, Balladelli A, Bacci G. High grade osteosarcoma of the extremities metastatic to the lung: long-term results in 323 patients treated combining surgery and chemotherapy, 1985–2005. *Surg Oncol* 2010; **19**: 193–9.
- Koong HN, Pastorino U, Ginsberg RJ. Is there a role pneumonectomy in pulmonary metastases? International Registry of Lung Metastases. *Ann Thorac Surg* 1999; **68**: 2039–43.
- Putnam JB, Roth JA. Surgical treatment for pulmonary metastases from sarcoma. *Hematol Oncol Clin North Am* 1995; **9**: 869–87.
- Ferrari S, Bacci G, Picci P *et al.* Long-term follow-up and post-relapse survival in patients with non-metastatic osteosarcoma of the extremity treated with neoadjuvant chemotherapy. *Ann Oncol* 1997; **8**: 765–71.
- Maruzzo M, Rastrelli M, Lumachi F, Zagonel V, Basso U. Adjuvant and neoadjuvant chemotherapy for soft tissue sarcomas. *Curr Med Chem* 2013; **20**: 613–20.
- Negri F, Musolino A, Cunningham D, Ladas G, Norman AR. Retrospective study of resection of pulmonary metastases in patients with advanced colorectal cancer: the development of a preoperative chemotherapy strategy. *Clin Colorectal Cancer* 2004; **4**: 101–6.
- Quint LE, Park CH, Iannettoni MD. Solitary pulmonary nodules in patients with extrapulmonary neoplasms. *Radiology* 2000; **217**: 257–61.
- Peuchot M, Libshitz HI. Pulmonary metastatic disease: radiologic-surgical correlation. *Radiology* 1987; **164**: 719–22.
- Ginsberg MS, Griff SK, Go BD, Yoo HH, Schwartz LH, Panicek DM. Pulmonary nodules resected at video-assisted thoracoscopic surgery: etiology in 426 patients. *Radiology* 1999; **213**: 277–82.
- Munden RF, Pugatch RD, Liptay MJ, Sugarbaker DJ, Le LU. Small pulmonary lesions detected at CT: clinical importance. *Radiology* 1997; **202**: 105–10.
- Grampp S, Bankier AA, Zoubek A *et al.* Spiral CT of the lung in children with malignant extra-thoracic tumors: distribution of benign vs malignant pulmonary nodules. *Eur Radiol* 2000; **10**: 1318–22.
- Kang MC, Kang CH, Lee HJ, Goo JM, Kim YT, Kim JH. Accuracy of 16-channel multi-detector row chest computed tomography with thin sections in the detection of metastatic pulmonary nodules. *Eur J Cardiothorac Surg* 2008; **33**: 473–9.