

# Surgical Outcome and Complications of Nasal Septal Perforation Repair with Temporal Fascia and Periosteal Grafts

Paula Virkkula, Antti A. Mäkitie and Seija I. Vento

Department of Otorhinolaryngology—Head and Neck Surgery, University of Helsinki and Helsinki University Hospital, Helsinki, Finland.

## ABSTRACT

**AIMS:** Surgical treatment of nasal septal perforation remains a challenging field of rhinology. A large variety of techniques and grafts with promising results have been introduced for perforation repair. However, the use of fascia or fascia with periosteum has not been previously evaluated for a large sample of patients.

**METHODS:** During the years 2007–2014, 105 operations were performed and 98 patients were treated for nasal septal perforation at the Department of Otorhinolaryngology—Head and Neck Surgery, Helsinki University Hospital, Helsinki, Finland. We performed a retrospective review of closure rates and complications. Follow-up time ranged from 1 to 62 months.

**RESULTS:** Bleeding was the most common early complication (9%), followed by postoperative infection (5%) in the whole series. Our main technique, bipediced advancement flaps with fascia or fascia and periosteum, was performed for 81 patients. We obtained successful closure in 78% of these patients with this operative technique and the rate increased to 86% during the last 3 years of the study period.

**CONCLUSIONS:** Perforation repair with temporal fascia or fascia with periosteum requiring only one donor site seems to be a reliable option for nasal septal perforation repair.

**KEYWORDS:** septoplasty, reconstruction, postoperative, infection

**CITATION:** Virkkula et al. Surgical Outcome and Complications of Nasal Septal Perforation Repair with Temporal Fascia and Periosteal Grafts. *Clinical Medicine Insights: Ear, Nose and Throat* 2015;8 7–11 doi:10.4137/CMEN.S23230.

**RECEIVED:** January 6, 2015. **RESUBMITTED:** February 17, 2015. **ACCEPTED FOR PUBLICATION:** March 4, 2015.

**ACADEMIC EDITOR:** Brenda Anne Wilson, Editor in Chief

**TYPE:** Original Research

**FUNDING:** This study was supported by the Helsinki University Hospital Research Fund. The authors confirm that the funder had no influence over the study design, content of the article, or selection of this journal.

**COMPETING INTERESTS:** Authors disclose no potential conflicts of interest.

**COPYRIGHT:** © the authors, publisher and licensee Libertas Academica Limited. This is an open-access article distributed under the terms of the Creative Commons CC-BY-NC 3.0 License.

**CORRESPONDENCE:** paula.virkkula@hus.fi

Paper subject to independent expert blind peer review by minimum of two reviewers. All editorial decisions made by independent academic editor. Upon submission manuscript was subject to anti-plagiarism scanning. Prior to publication all authors have given signed confirmation of agreement to article publication and compliance with all applicable ethical and legal requirements, including the accuracy of author and contributor information, disclosure of competing interests and funding sources, compliance with ethical requirements relating to human and animal study participants, and compliance with any copyright requirements of third parties. This journal is a member of the Committee on Publication Ethics (COPE).

Published by Libertas Academica. Learn more about this journal.

## Introduction

Nasal septal perforation is encountered mostly in patients with Wegener's vasculitis, after septal surgery or other trauma, and often without a clear etiology. Several less common diseases such as sarcoidosis, systemic lupus erythematosus, infections, and neoplasias have been associated with nasal septal defects.<sup>1</sup> Patients without an obvious cause may have had dry bleeding or infected mucosa, and nasal manipulation may have further impaired their mucosal integrity. The use of nasal steroids or other drying medication for the mucosa may contribute, and many of these cases, will have a multifactorial background. Patients with a septal perforation report symptoms of nasal obstruction, crusting, recurrent bleedings, dryness, pain, and whistling.<sup>2</sup> A dry climate may increase the incidence of septal defects, but the prevalence has been investigated previously only by Öberg et al in Sweden and it was estimated to be 0.9% in an adult population.<sup>3</sup>

Patients considered as candidates for operative septal defect closure form a selected group in this population. Posterior perforations are often symptomless and do not need repair. Conservative treatments with regular saline irrigations, nasal ointments, and, occasionally, septal buttons are tried before

surgery. Patients with vasculitis are usually treated conservatively due to the large perforations involved and the high probability of scarring after surgery. Patients with active nasal manifestation of autoimmune diseases, such as sarcoidosis or systemic lupus erythematosus, have been reported to be more susceptible to poor outcomes.<sup>1</sup>

No consensus exists on the most feasible technique for septal perforation repair, and comparative studies have not been published. The reports of surgical outcome are mostly based on small sample sizes.<sup>4,5</sup> Fairbanks has described the use of a thin and easily obtainable temporal periosteum and/or fascia graft and preservation of the arterial supply to the nasal mucosa.<sup>6,7</sup> The preliminary results for 24 patients were excellent in over 90% of the cases. Favorable outcomes have been reported also after using cartilage interposition grafts, either with periosteum and/or fascia or even without any graft.<sup>2,8–11</sup> However, periosteum and fascia requiring only one distant donor site has not been evaluated earlier in a large patient series.<sup>4,5</sup>

In the present study, we evaluated the outcomes and complications of nasal septal perforation surgery in our hospital, and present the results of the bilateral bipediced

mucoperichondreal advancement flap with fascial or periosteal graft (BAF). Possible causes of perforation and predictive factors of surgical outcome were also assessed.

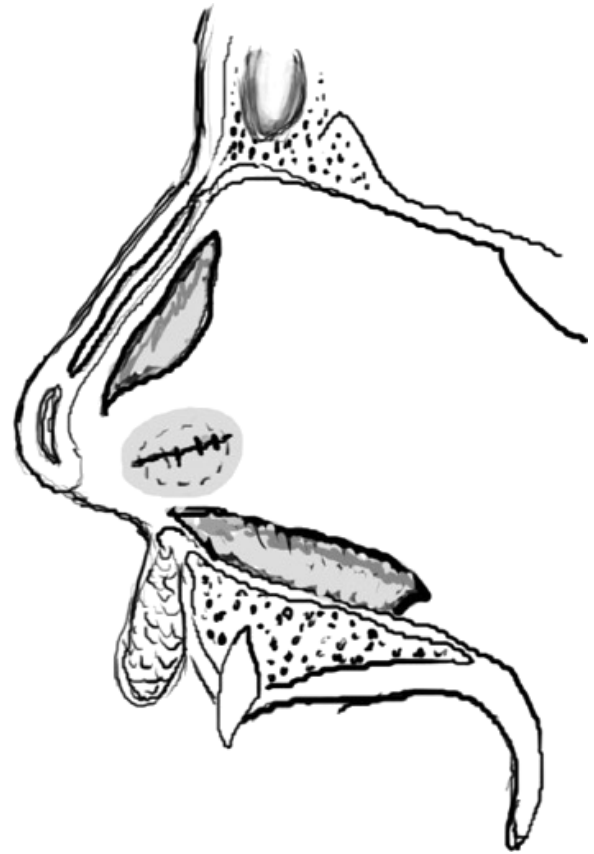
## Materials and Methods

This retrospective study was conducted at the Department of Otorhinolaryngology—Head and Neck Surgery, Helsinki University Hospital (HUU), Helsinki, Finland. The study complied with the principles of the Declaration of Helsinki. According to the law of Finland a Research Ethics Board approval will not be needed for retrospective hospital chart reviews. An institutional research approval was granted for the study. HUU is a tertiary care academic center for a population of 1.87 million and the only hospital in this referral area performing surgical management of nasal septal perforations. All patients with a nasal septal perforation operated on between April 2007 and August 2014 were included. Four out of the five operating surgeons were doctors in training for rhinosurgery, and they performed their first operations on septal perforations at the beginning of this study period. We collected data on comorbidities, smoking, medication, evident cause of perforation, perforation size, operative technique, tissue graft, closure rate, outcome, and complications.

All the patients had been instructed to apply moisturizing sprays and ointments regularly prior to making the decision for operative treatment. Administration of topical basitracine ointment or oral cephalosporine was used if necessary. The patients were counseled to refrain from nasal manipulation to decrease crusting and to allow healing of the perforation edges. Surgery was considered if their symptoms were not adequately controlled.

**Operative technique.** The patients were operated on while under general anesthesia. Intravenous antibiotics, typically cefuroxime, were administered during induction of anesthesia. In selected cases with large perforations or in reoperations, the lower turbinate flaps were raised and the temporal fascia was harvested.<sup>12</sup> For smaller perforations, various techniques were used with auricular cartilage graft when needed. Repair with a fat graft similar to the tympanic membrane repair was used in rare cases.<sup>13</sup> The endonasal approach was used in all but one BAF patient who needed an open rhinoplasty. The perforations were in the anterior part of the septum.

In the vast majority of patients, we used bilateral bipediced mucoperichondreal or mucoperiosteal advancement flaps with transpositioned temporal fascia (BAF technique), which was occasionally strengthened with the periosteum according to the technique described by Fairbanks.<sup>6,7</sup> A large graft was obtained from the temporal region before starting the nasal operation, and it was left to dry. Fascia and pericranium are easy to handle if bleeding does not occur at the time of placement of the grafts. Mucoperichondreal/periosteal upper and lower tunnels extending to the nasal floor or up to lower turbinates and lower mucosal incisions of bipediced flaps were then constructed before opening the perforation ring (Fig. 1). Usually, the bilateral advancement flaps are raised, but in small perforations, upper



**Figure 1.** The figure shows upper and lower incisions on the left side. On the right, an inferior incision continuous with hemitransfixation incision is performed. The fascia/periosteum (gray area) is inserted after suturing of the mucosal defects, and it should overlap with the cartilagenous defect well. The drawing was modified after Fairbanks.<sup>7</sup>

incision or both lower incisions may not be needed if suturing of both sides can be done without tension. This was followed by suturing of the perforation, preferably with madras sutures (Vicryl 5-0 or Polysorb 6-0) starting from the posterior edges. Nasoendoscopy or loops were used in part of the procedures, and loops were found to be especially useful during careful dissection around the perforations and suturing with both hands free. After placement of a large fascia to overlap the edges of the cartilagenous defect, the hemitransfixation incision was closed and silicon splints were fixed with transnasal sutures. The splints were usually removed 1–3 weeks (5–22 days) after surgery. Prophylactic antibiotics were typically (94%) used until removal of the silicon splints. Saline and ointments were used several weeks postoperatively to manage crusting.

**Statistical methods.** Fishers's exact tests with two-tailed *P*-values were used for analysis of categorical data for evaluation of the factors affecting surgical outcome. *P*-values less than 0.05 were considered significant.

## Results

There were 98 patients (55 men; mean age 41.2 years; range 13–69). Altogether 105 operations were performed and 11

**Table 1.** Etiology of perforations in 98 patients undergoing surgical repair.

Traumatic etiological factors:	n
All previous septal surgery	22
Recent septal surgery	12
Recent endoscopic sinus surgery	4
Removal of papilloma from septum	2
Nasogastric tube/nasal intubation	2
Silver nitrate cauterization	5
Nasal trauma	9
Use of local decongestants	1
Other possible causes:	
Smoking	11
Allergy	35
Polyposis	3
Diabetes	5
Autoimmune disease	15

(10%) of them were reoperations. The mean follow-up time was 8.8 months (range, 1–62). Five patients, having undergone their first operative closure of the septal perforation, were lost to follow-up after removal of the silicone splints and were excluded from the analysis of the operative results.

**Etiology.** The etiology of septal perforations in 98 patients operated is presented in Table 1. Twenty-two (22%) patients had undergone previous septal operations, and in 12 (12%) of these patients, the perforation had been discovered shortly after septal operation. Iatrogenic causes were found in 35 (36%) patients. Only 11 (11%) patients were smokers. Other possible predisposing conditions such as allergies (36%), polyposis (3%), and diabetes (5%) were infrequent, but autoimmune diseases (15%) were more prevalent than expected in this series. The rest of the patients had no obvious etiology for the perforation.

**Complications.** Perforation size, surgical technique, and postoperative complications for 93 patients are presented in Table 2. Five patients were lost to follow-up after their first postoperative follow-up visit for removal of silicone splints. Fourteen

(15%) out of the 98 patients had early postoperative complications. Bleeding was the most common complication (9%), followed by postoperative infection (5%). Three (4%) out of the 81 patients operated on with BAF technique and 2 out of the 4 patients operated on with fat graft had postoperative infections. All these patients had intravenous cefuroxime as antibiotic prophylaxis. There were no donor site infections. One patient experienced long-term loss of her smell and taste after BAF.

**BAF technique.** Eighty-one patients were operated on with the BAF technique, and in 40 patients this was combined with a temporal periosteum graft (Table 2). Perforation size ranged from 1 to 25 mm. Successful closure was achieved in 63 (78%) patients. One patient with successful primary closure was later referred to us with recurring symptoms and a reoperation 5 years after the primary operation. In the most recent part of the study period (2012–2014), 43 patients were operated on with this technique and the closure rate increased to 86%. Previous septal operations, including perforation reoperations, seemed to decrease operative outcome (NS) (Table 3).

## Discussion

Repair of nasal septal defects remains a challenge for surgical rhinology. The present study describes the used technique and outcome for 98 patients operated on for a septal perforation. Successful closure of perforations was obtained in 78% of the procedures performed with bilateral bipediced mucoperichondrial advancement flaps and a fascial/periosteal interposition graft (BAF). Previous septal surgery seemed to decrease the operative outcome. Altogether, early postoperative complications were found in 15% of the patients. Bleeding was found to be the most common type, occurring in nine patients, and only five patients had postoperative infection. These results compare well with the earlier reported outcome results using various techniques, and thus BAF is the recommended approach for septal perforation surgery at our institution.

The retrospective study design is a limitation of the present study as it is in almost all previous reports on perforation surgery.<sup>4,5</sup> Prospective studies with evaluation of quality-of-life parameters would be valuable to find the best surgical outcome and minimal rate of complications. We only report the rates of early complications, as a minimum follow-up period of one year

**Table 2.** Operative outcome and postoperative early complications in 93 patients operated on for nasal septal perforation.

TECHNIQUE	PATIENTS	PERFORATION SIZE, mm	SUCCESSFUL CLOSURE, n, (%)	EARLY COMPLICATIONS, n, (%)		
				NASAL BLEEDING	NASAL INFECTION	DONOR SITE SEQUELAE
Bipediced advancement flap with fascial/periosteal graft (BAF)	81	1–25	63 (78)	8 (9)	3 (4)	1 (1) (hematoma)
Bipediced flap +/- auricular cartilage graft	5	2–10	4	0	0	1 (hematoma)
Lower turbinate flap with fascial graft	3	7–30	1	0	0	0
Fat graft	4	3–6	1	0	2	0



**Table 3.** Data on perforation size, previous septum surgery, type of graft, use of silicone splints and successful closure rates of septal perforations in 81 patients operated with bipediced mucoperichondrial/mucoperiosteal advancement flap and temporal fascia with or without periosteal grafts (BAF).

	ALL, n (%)	SUCCESSFUL, n (%)
<b>Perforation size, mm:</b>		
Small (<10)	31	28 (90)
Medium (10–19)	38	29 (76)
Large (≥20)	11	5 (45)
<b>Previous septal surgery</b>		
No previous septal surgery	64	51 (80)
<b>Temporal periosteum and fascia</b>		
Temporal fascia	41	34 (83)
<b>Silicone splint ≤7 days</b>		
Silicone splint ≤7 days	36	30 (83)
<b>Silicone splint ≥10 days</b>		
Silicone splint ≥10 days	23	17 (74)

**Notes:** In one of the 81 patients preoperative size of the perforation was not reported. Previous nasal septal surgery, use of temporal fascia with or without periosteum and short or long postoperative use of silicone splints did not have an effect on operative outcome in statistical analysis ( $p = 0.51$ ;  $p = 0.30$ ;  $p = 0.51$ , respectively).

would be optimal to study long-term outcomes in this patient population. Due to the varying postoperative follow-up time, the number of long-term complications may be underestimated in the present study. However, our department is the only center providing surgical management of septal perforations in the area with 1.87 million inhabitants, and therefore patients with recurring symptoms or persisting perforations would likely have been referred to our institution. The advantages of this study are the fairly large sample size and evaluation of the fascia/periosteum as a single graft alternative for reconstruction.

The majority of the patients in the present series had no obvious cause for perforation. Possible iatrogenic causes of septal perforation were found in one-third of the patients, and one-fifth had undergone septoplasty earlier. Most studies on perforation surgery have found that the majority of the patients had had a septal operation earlier.<sup>1,9,11,14</sup> In the present study, only 12% of patients had undergone a recent septoplasty, indicating a certain causal relationship. These results may reflect better awareness of the benefits of conscientious subperichondrial dissection and, thus, changes in operative technique. Most patients had no obvious reason for their septal defect. Whether dry mucosa, local infection, and digital manipulation are causes or consequences of perforation is often difficult to discern at the first visit. In our evaluation of comorbidities, autoimmune diseases seemed more prevalent than expected. The prevalence of autoimmune diseases in Denmark is 5.3%.<sup>15</sup> Previous reports of some of these conditions also indicate that healing may be impaired and predisposed to perforation.<sup>1</sup>

There is no standardized method for septal perforation surgery. Previous studies have not been able to show

the superiority of any graft material. This study presents the results of bipediced mucoperichondrial advancement flaps and the fascia/periosteum graft in a large sample of 81 patients compared to earlier reports.<sup>4–7</sup> The operative outcome in the present study with the BAF technique was 78%, and after a learning period of four surgeons, the closure rate increased to 86%. Bipediced advancement flaps are now widely used by several centers. However, the use of the fascia/periosteal graft material and the need for only one distant donor site have not been properly evaluated. The largest studies have reported surgical outcomes with cartilage grafts or with the so-called sandwich grafts, ie, cartilage wrapped inside fascia.<sup>8,9,11</sup> A septal interposition graft has been considered important for successful closure of defects, but comparative studies with different techniques have not been published.<sup>4,5,16</sup> Only one study with a small sample size has tried to compare graft material, mainly allograft and conchal cartilage.<sup>14</sup> Some centers have reported good outcome without interposition grafts, and the promising results show that the need for an interposition graft is not yet established.<sup>2,17</sup> We consider a single donor site, a thin, large graft material, and preservation of vascular supply with bipediced advancement flaps as the main advantages of our present technique.

Some studies have investigated predictive factors of surgical outcome in perforation repair. A recent systematic review found that large perforations over 2 cm in size increased surgical failures.<sup>5</sup> However, bilateral closure of the defect with vascularized flap improved healing. Interposition grafts appeared to help closure, but this factor was not statistically significant. Successful outcome was reported for 78% of large perforations and in 90% of small-to-moderate perforations, but most studies comprised small patient series.<sup>5</sup> The reports with larger samples show outcome rates exceeding 90% for a single surgeon, but the results may not be equally repeatable.<sup>9,11</sup> The effect of the perforation size was also seen in the present study, with a good closure rate for small perforations. Large perforations still remain a challenge. In the present study, previous septal surgery seemed to decrease positive operative outcome. This is obviously due to the difficulty of raising mucoperichondrial flaps after a previous surgery. The better outcome with fascial grafts when compared to the combined fascia and periosteum ones may be the result of the learning curve in the early operations in the present study period. Further, some cases where both the fascia and periosteum were used might have had more complicated septal tissue defects requiring additional graft material.

Long-term postoperative complications for septal perforation surgery may include re-perforation, synechiae, vestibular stenosis, saddle deformity, lacrimal duct stenosis, hypoesthesia, dislocation of the cartilage graft, and postauricular granuloma.<sup>9,16</sup> Early postoperative complications of septal perforation surgery have seldom been reported.<sup>9</sup> Postoperative infections were infrequent in the present series, especially in the group operated on with the BAF technique. Surgery for septal perforation



is probably more susceptible to infections than, eg, septoplasty due to crusting, scarring, and the poor condition of the mucosa around the perforation, and partly also due to a longer operation time. A vast majority of our patients received prophylactic intravenous cefuroxime. A prophylactic dose of cefuroxime as part of the septoplasty procedure has been shown to reduce infection rates, especially if preoperative crusting or purulent secretion is seen. *Staphylococcus aureus* found in nasal bacterial swabs has been found to correlate with a significantly increased risk of postoperative infection.<sup>18</sup> The low number of infections in the present study may also be due to the long mucosal incisions, which allow free postoperative drainage. In the group with 81 BAF reconstructions, we found only one donor site complication, a postoperative hematoma. In contrast, using several donor sites during one procedure, as in sandwich grafts, may increase operative time and the risk of donor site complications.<sup>8,10,11</sup> More than one donor site may also be needed for concomitant rhinoplasty.

### Conclusions

The surgical outcome of our main operative technique using fascial/periosteal graft for nasal septal perforation repair was good. The most common early postoperative complication after perforation surgery was bleeding, and postoperative infections were rare. Previous septal surgery was no longer the major etiological factor for septal perforation. The bilateral bipediced mucoperichondrial advancement flap with fascial/periosteal graft remains our first reconstructive option for this patient population.

### Author Contributions

Conceived and designed the experiments: PV, AAM, SIV. Analyzed the data: PV, AAM, SIV. Wrote the first draft of the manuscript: PV. Contributed to the writing of the manuscript: PV, AAM, SIV. Agree with manuscript results and conclusions: PV, AAM, SIV. Jointly developed the structure and

arguments for the paper: PV, AAM, SIV. Made critical revisions and approved final version PV, AAM, SIV. All authors reviewed and approved of the final manuscript.

### REFERENCES

1. Lanier B, Kai G, Marple B, Wall GM. Pathophysiology and progression of nasal septal perforation. *Ann Allergy Asthma Immunol.* 2007;99:473–480.
2. Teymoortash A, Hoch S, Eivazi B, Werner JA. Experiences with a new surgical technique for closure of large perforations of the nasal septum in 55 patients. *Am J Rhinol Allergy.* 2011;25:193–197.
3. Öberg D, Åkerlund A, Johansson L, Bende M. Prevalence of nasal septal perforation: the Skövde population-based study. *Rhinology.* 2003;41:72–75.
4. Goh AY, Hussain SS. Different surgical treatments for nasal septal perforation and their outcomes. *J Laryngol Otol.* 2007;121:419–426.
5. Kim S-W, Rhee C-S. Nasal septal perforation repair: predictive factors and systematic review of the literature. *Curr Opin Otolaryngol Head Neck Surg.* 2012;20(1):58–65.
6. Fairbanks DN, Fairbanks GR. Nasal septal perforation: prevention and management. *Ann Plast Surg.* 1980;5(6):452–459.
7. Fairbanks DN. Nasal septal perforation repair: 25-year experience with the flap and graft technique. *Am J Cosmet Surg.* 1994;11:189–194.
8. André RF, Lohuis PJ, Vuyk HD. Nasal septum perforation repair using differently designed, bilateral intranasal flaps, with nonopposing suture lines. *J Plast Reconstr Aesthet Surg.* 2006;59:829–834.
9. Schultz-Coulon H-J. Three-layer repair of nasoseptal defects. *Otolaryngol Head Neck Surg.* 2005;132:213–218.
10. Pedroza F, Patrocinio LG, Arevalo O. A review of 25-year experience of nasal septal perforation repair. *Arch Facial Plast Surg.* 2007;9(1):12–18.
11. Ribeiro JS, Silva da Silva G. Technical advances in the correction of septal perforation associated with closed rhinoplasty. *Arch Facial Plast Surg.* 2007;9(5):321–327.
12. Stoor P, Grénman R. Bioactive glass and turbinate flaps in the repair of nasal septal perforations. *Ann Otol Rhinol Laryngol.* 2004;113:655–661.
13. Fiorino F, Barbieri F. Fat graft myringoplasty after unsuccessful tympanic membrane repair. *Eur Arch Otorhinolaryngol.* 2007;264:1125–1128.
14. Moon IJ, Kim SW, Han DH, et al. Predictive factors for the outcome of nasal septal perforation repair. *Auris Nasus Larynx.* 2011;38:52–57.
15. Eaton WW, Rose NR, Kalydjian A, Pedersen MO, Mortensen PB. Epidemiology of autoimmune diseases in Denmark. *J Autoimmun.* 2007;29:1–9.
16. Døsen LK, Haye R. Surgical closure of nasal septal perforation, early and long term observations. *Rhinology.* 2011;49:486–491.
17. Castellnuovo P, Ferrel F, Khodaei I, Palma P. Anterior ethmoidal artery septal flap for the management of septal perforation. *Arch Facial Plast Surg.* 2011;13(6):411–414.
18. Lilja M, Mäkitie AA, Anttila V-J, Kuusela P, Pietola M, Hytönen M. Cefuroxime as a prophylactic preoperative antibiotic in septoplasty. A double blind randomized placebo controlled study. *Rhinology.* 2010;49:58–63.