

# How to Perform a Giant Parameniscal Cyst Exeresis: Step by Step Technique



José Leonardo Rocha de Faria, M.D., Douglas Mello Pavão, M.D., M.Sc.,  
Marcos de Castro Moreirão, M.D., Hugo Alexandre de Barros Cobra, M.D., M.Sc.,  
Rodrigo Pires e Albuquerque, M.D., M.Sc. , Ph.D.,  
Eduardo Branco de Sousa, M.D., M.Sc., Ph.D., and Alan de Paula Mozella, M.D., M.Sc.

**Abstract:** Parameniscal cysts are usually small cystic lesions, less than 2 cm in size, found along the meniscal periphery. They are rarely associated with extra-articular palpable mass. Magnetic resonance imaging is the diagnostic method of choice; giant meniscal cysts (>5 cm at its greatest diameter) are very rare, with few cases described in the literature. We describe a step-by-step open exeresis and arthroscopic meniscal suture technique for the treatment of a 9-cm giant parameniscal cyst located on the lateral side of the knee. Treatment of giant meniscal lesions requires caution during dissection and exeresis. Because acute meniscal lesions benefit from meniscal suture rather than meniscectomy, horizontal degenerative lesions may also present excellent results with repair techniques. We conclude that the combination of the open excision of the giant cyst with careful dissection and protection of neurovascular structures, combined with the arthroscopic meniscal suture, is a good strategy to approach such lesions.

Parameniscal cysts are usually small cystic lesions, less than 2 cm in size, found along the meniscal periphery. They are rarely associated with extra-articular palpable mass.<sup>1,2</sup> The most accepted etiopathogenesis for this lesion is the extrusion of the intra-articular synovial fluid that passing through a meniscal lesion, generally horizontal.<sup>2</sup> Bursitis, Baker cyst, ganglion cyst, hematoma, and cystic neoplasms like a synovial sarcoma must be considered as differential diagnoses.<sup>2,3</sup>

Magnetic resonance imaging (MRI) is the diagnostic method of choice.<sup>4</sup> Campbell et al., evaluating 2,572 MRI scans, observed a 4% incidence of parameniscal cysts.<sup>1</sup> Giant meniscal cysts (>5 cm at greatest

*From the Knee Surgery Center of the National Institute of Traumatology and Orthopedics of Brazil, Rio de Janeiro, Brazil.*

*The authors report that they have no conflicts of interest in the authorship and publication of this article. Full ICMJE author disclosure forms are available for this article online, as [supplementary material](#).*

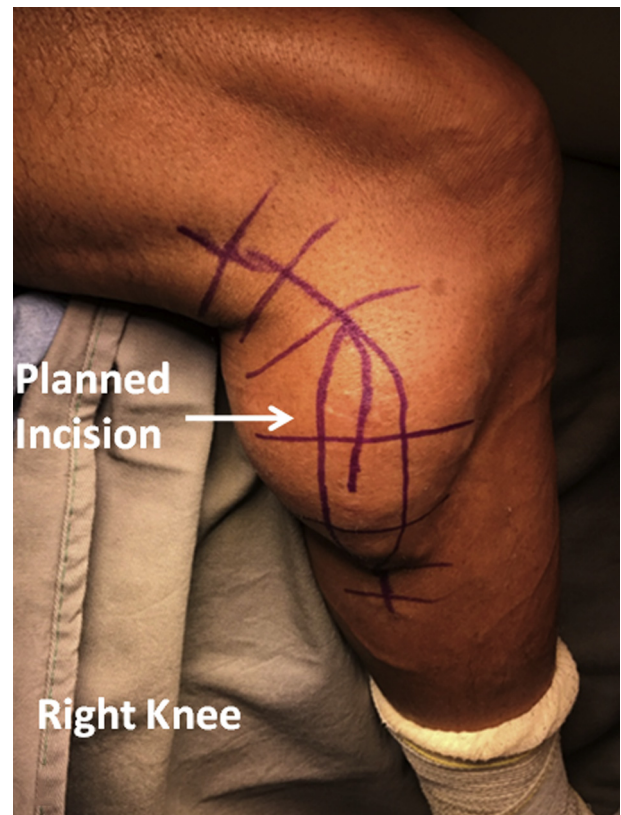
*Received October 19, 2019; accepted January 20, 2020.*

*Address correspondence to José Leonardo Rocha de Faria, M.D., Instituto Nacional de Traumatologia e Ortopedia Jamil Haddad - Av. Brasil, 500, Rio de Janeiro - RJ, Brazil CEP 20940-070. E-mail: [drjoseleonardorocha@gmail.com](mailto:drjoseleonardorocha@gmail.com)*

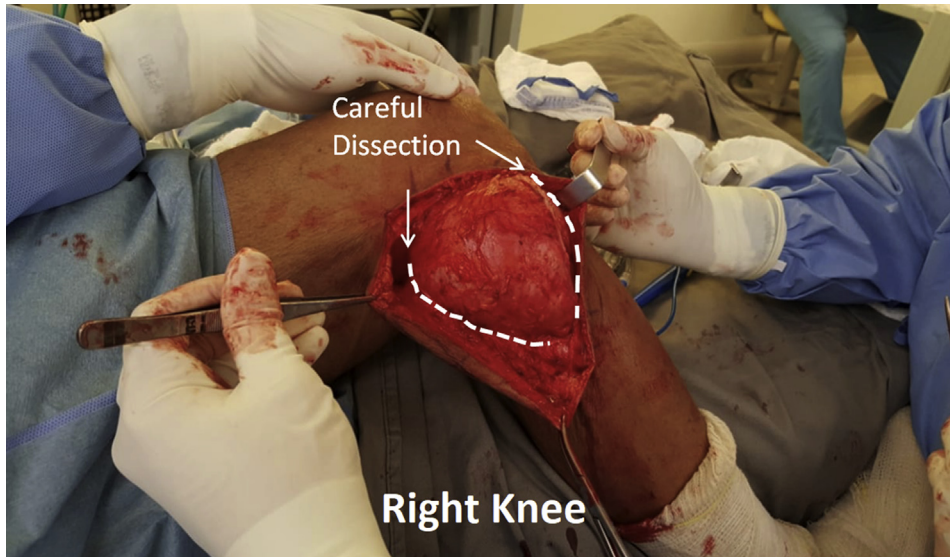
© 2020 by the Arthroscopy Association of North America. Published by Elsevier. This is an open access article under the CC BY-NC-ND license (<http://creativecommons.org/licenses/by-nc-nd/4.0/>).

2212-6287/191281

<https://doi.org/10.1016/j.eats.2020.01.021>



**Fig 1.** Planned lateral incision over the giant lateral parameniscal cyst on the right knee, flexed on the side of the operating table.



**Fig 2.** Careful giant parameniscal cyst dissection in its periphery to prevent perforation. Right knee, flexed on the side of the operating table.

diameter) are very rare; therefore, few cases have been described in the literature.<sup>5</sup> Open excision associated with arthroscopic meniscal suture is the treatment with the least chance of recurrence according to a recent study.<sup>6</sup>

We describe a step-by-step technique to open exeresis and arthroscopic meniscal suture of a 9-cm giant parameniscal cyst located on the lateral side of the knee.

## Surgical Technique

### Patient Positioning and Preparation

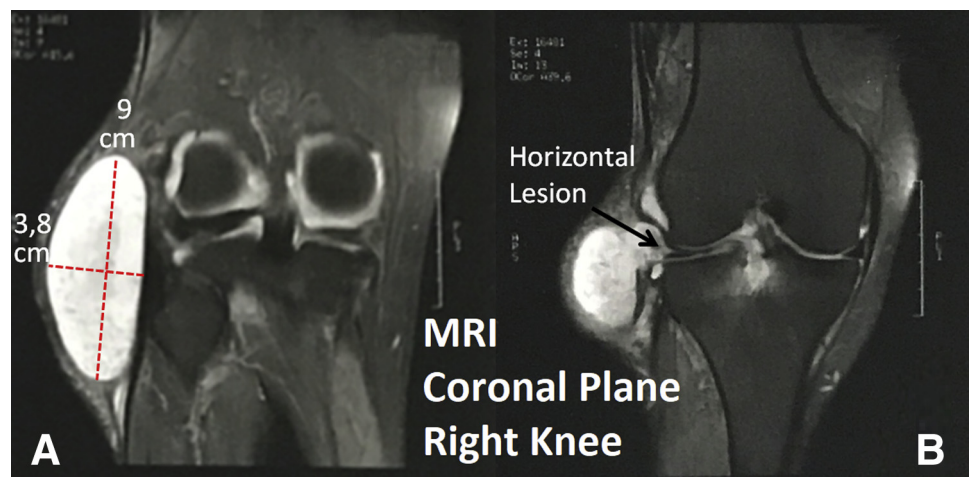
The patient is positioned in the prone position and anesthetized with spinal anesthesia. After anesthesia is completed, the pneumatic cuff is installed on the proximal one-third of the affected thigh. A lateral

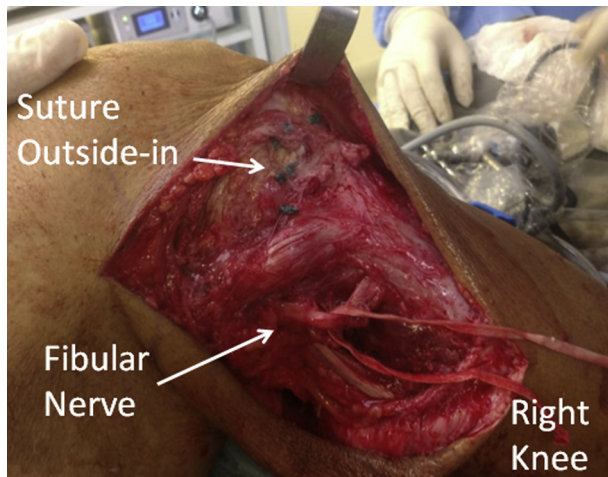
support is positioned at the level of the anterior lateral iliac spine. A cushion is placed below the thigh at the level of the pneumatic cuff and fixed to the operating table with sticking plaster. Detergent chlorhexidine is used to perform asepsis and alcoholic chlorhexidine for antisepsis. The surgical fields are then placed.

### Surgical Incision

A wide surgical incision is planned and drawn with a sterile dermatographic pen over the cyst, making an ellipse over it, so that the central region of the ellipse has a diameter of approximately one-third the total length of the cyst. The ellipse-shaped surgical incision is planned over the central region of the cyst, its concavity is posteriorly oriented and anteriorly convexity (Fig 1). Such an ellipse is used to prevent excess skin at the time

**Fig 3.** (A) T2-weighted MRI in the coronal plane showing a 9.0 cm x 3.8 cm giant parameniscal cyst. (B) A horizontal lesion on the lateral meniscus showing the pathway that communicated the cyst with the interior of the joint; right knee.





**Fig 4.** Fibular nerve was identified, isolated, and protected during cyst dissection. Sutures were used, with the outside-in technique visualized at the level of the articular joint line. Right knee, flexed on the side of the operating table.

of surgery closure after the cyst is resected. Three arthroscopic portals are then performed: 1 lateral parapatellar, 1 medial parapatellar, and 1 longitudinal transpatellar in the center of the patellar tendon.

### Surgical Procedure

The knee was positioned flexed at 90°, hanging off the side of the table. An incision was made over the previously drawn ellipse and careful dissection was performed around the cyst to avoid perforation (Fig 2). The pathway that connected the cyst with the interior of the joint was located at the articular interline, in the place of a horizontal lesion of the body and anterior horn of the lateral meniscus (Fig 3).

The dissection was cautiously performed using Metzenbaum scissors and No. 11 scalpel in all peripheral regions of the cyst. After the dissection was enlarged, the cyst was elevated and the femoral biceps tendon identified by its insertion into the fibular head. Then, we identified and isolated the fibular nerve, protecting it with a cardiac tape (Fig 4). The next step was to identify the location of the joint with the cyst (Table 1). We performed 2 stitches fair capsular and 2 stitches juxtacyst occluding the passage of the synovial fluid. Finally, the cyst was resected and sent with its contents for histopathological analysis (Fig 5).


The arthroscopic procedure began by performing joint inventory and identifying the horizontal lesion in the lateral meniscus previously seen on MRI scans. At the beginning of the arthroscopic procedure, we observed a moderate amount of saline coming out of the cyst already sutured externally with 2 Ethibond stitches. Two No. 14 Jelco (Johnson & Johnson) hypodermic needles were prepared by passing a 3.0 nylon in a No. 1 Jelco and a 2.0 Ethibond in a No. 2 Jelco. We introduced the No. 1 Jelco over the anterior horn of the lateral meniscus, forming a loop. Its 2 ends were symmetrically located outside the knee, and about 8 mm lateral to the first needle. Jelco No. 2 was introduced with Ethibond wire passing through the inside of the Jelco, prominent about 3 cm. The end of the Ethibond wire was grasped through the handle created by nylon. We pulled the loop by carrying the end of the Ethibond thread through the hole created by Jelco No. 1. We sutured the 2 ends of the Ethibond by completing the first suture. With the same surgical technique mentioned, we performed 3 additional vertical sutures and 2 more horizontal sutures, completely closing the cystic tract (Fig 6). Arthroscopy fluid pressure was increased to see if the old disorder remained active; no more saline output was observed (Table 2). The wound was sutured through anatomic planes and the patient progressed satisfactorily in the postoperative period, with good wound healing (Fig 7).

### Rehabilitation

We do not use braces or immobilizers for this type of surgery. In the first week, the focus is to passively mobilize the patella to prevent patellofemoral adhesions, quadriceps isometry, and passive knee flexion up to 90° flexion. From the second week on, we added abductor and adductor isometric exercises, both with body weight only. In the third week, we added active extension from 90° of knee flexion to full extension. Partial loading with the aid of crutches is recommended until the sixth week.

**Table 1.** Pearls and Pitfalls

Pearls	Pitfalls
Perform careful dissection of the cyst avoiding extravasation of the cyst	Make a too deep incision piercing the cyst already in the skin access
Isolate the fibular nerve with cardiac tape without leaving a hanging metal clamp avoiding traction by the weight of the clamp may generate injury in the postoperative period	Fibular nerve neuropraxia
A large lateral approach is necessary to avoid a nerve injury	In a fibular nerve lesion, there is a higher risk of infection and postoperative skin complications



**Fig 5.** (A) Aspect of the fluid found inside the cyst. (B) Actual cyst size is slightly larger than seen on MRI.

## Discussion

Parameniscal cysts occur most commonly at the level of the medial meniscus, especially in the posterior third. Because of their deeper location, in an area with greater soft-tissue coverage, they tend to be asymptomatic.<sup>5</sup>

In our video, the cyst is located on the lateral aspect of the knee and is quite symptomatic because of its large volume and superficial location (Video 1). Its topography agrees with other publications, which points out lateral injuries as the most commonly symptomatic.<sup>7</sup>

Arthroscopic evaluation and MRI scans showed the association of the cyst in the reported case with a horizontal type meniscal lesion located in the middle one-third of the lateral meniscus. This is in agreement with the literature, which claims these cysts are commonly associated with horizontal lesions or lesions with horizontal components in the meniscus. These lesions are

more frequent in the middle and anterior one-third of the lateral meniscus.<sup>1</sup> The association between horizontal meniscal tears and parameniscal cyst is 98%.<sup>8</sup>

Anderson published a study in 2010 showing that the contents of parameniscal cysts in 96% of cases are formed by synovial fluid.<sup>9</sup>

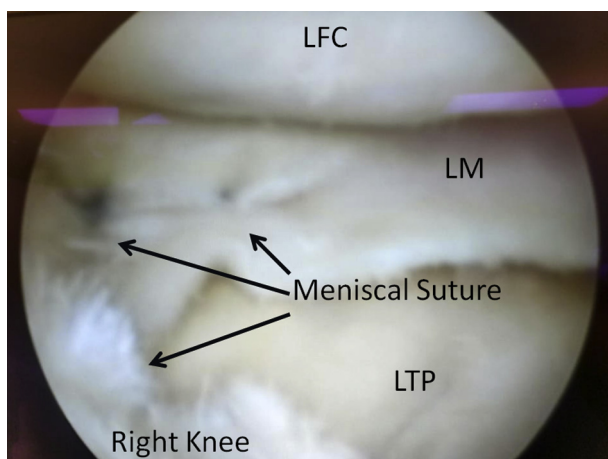
Treatment of horizontal meniscal tears associated with giant cysts includes decompression techniques through debridement of the meniscal lesion and removal of meniscal flaps and opening of the articular communication channel. Enlarging cyst dimensions beyond 5 mm allows the valve mechanism to be interrupted, causing the pressures to become numb and avoiding its recurrence.<sup>7</sup>

Isolated arthroscopic meniscal approach techniques without opening the cyst presented worse results than the combined approach.<sup>10</sup> An open surgical excision is indicated for large or multiloculated cysts.<sup>11</sup>

El-Assal et al. evaluated the arthroscopic approach alone in relation to combined cystectomy and found that in 82% of cases of arthroscopic cyst decompression was achieved only arthroscopically. However, in 18% of cases, an additional open cystectomy was required. Because of the large size of the cyst, we opted for an open excision combined with the arthroscopic meniscus approach.<sup>12</sup>

Ahn et al. reported a modified vertical outside-in suture technique in a lesion of the anterior horn of the lateral meniscus after the decompression of massive cyst.<sup>13</sup> Lu et al. also reported the successful treatment of a massive parameniscal cyst with an inside-out meniscal repair technique.<sup>14</sup>

Xu et al. published a paper in 2018 describing better clinical functional outcomes of meniscal repair compared with meniscectomy in the elderly.<sup>15</sup> Recently, Iorio et al. published a study evaluating 22 patients with lateral meniscal tear associated with parameniscal cysts in which patients underwent partial



**Fig 6.** Arthroscopic view of the right lateral meniscus, regarding the sutures on the anterior horn and body of lateral meniscus, lateral femoral condyle (LFC) and lateral tibial plateau (LTP).

**Table 2.** Advantages, Disadvantages, and Risks

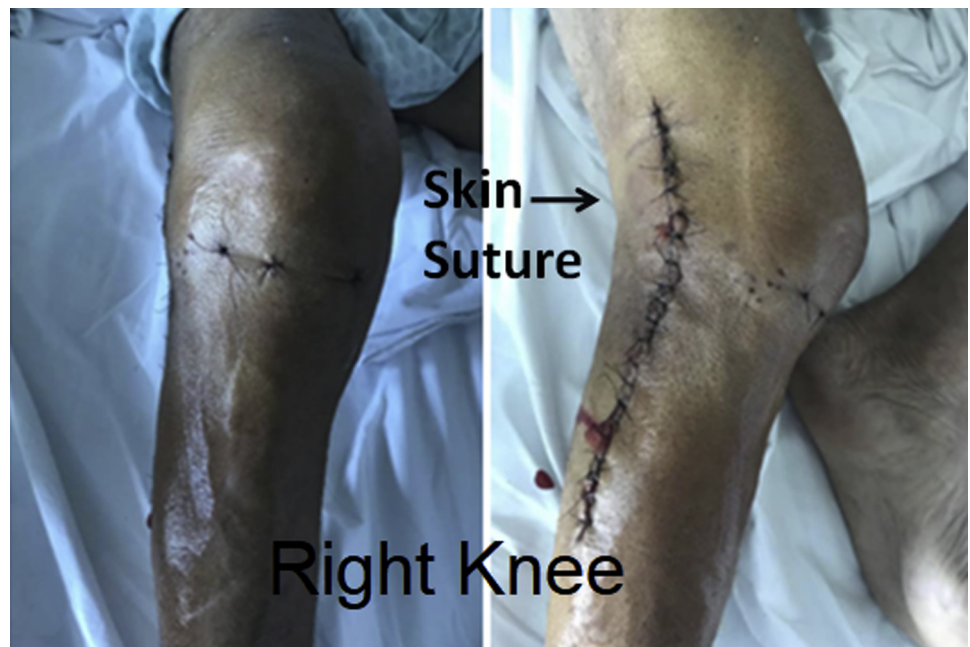Advantages	Disadvantages	Risks
An advantage of the lateral parameniscal cyst is that it is more easily diagnosed	However, it is more symptomatic than medial parameniscal cyst	Neurological injury
Arthroscopic meniscal suture closing the cystic tract minimizes the chance of parameniscal cyst recurrence	Increases surgical time, demands greater technical skill	Meniscal repair failure
Suturing the meniscus rather than simply expanding intra and extra-articular communications allows restoring the meniscus function	Wide surgical approach is required	Meniscal repair failure
Open cyst excision is advantageous over puncture emptying	It requires careful dissection of the nerve	Neurological injury

meniscectomy, preserving the meniscal periphery in 100% of the cases. In all cases performed, cyst decompression with associated with a percutaneous puncture to direct arthroscopic vision. The authors followed the patients for an average of 11 years, noting a significant clinical improvement without recurrence of the cysts and did not observe development of arthrosis during the period evaluated.<sup>16</sup>

Following the recommendations of meniscal preservation, seeking to restore their anatomy, we recommend a technique of meniscal repair using outside-in sutures, interrupting the extravasation channel of the joint fluid, and restoring the meniscal anatomy, instead of simply debriding and enlarging the meniscal lesion. In cases where lateral giant parameniscal cysts are diagnosed, identification, dissection,

and protection of the fibular nerve is required because of the expansion of the tumor close to its topography. We did not find reports of associated iatrogenic lesions of the fibular nerve during resection of lateral cysts in the literature, but we emphasize the importance of carefully identifying the nerve when the tumor extends posterior to the biceps femoral tendon and the fibular head.<sup>17</sup>

The treatment of giant meniscal lesions requires caution during dissection and exeresis, avoiding iatrogenic lesions of neurovascular structures, especially when located in the posterolateral region of the knee. Because acute meniscal lesions benefit from meniscal suture rather than meniscectomy, horizontal degenerative lesions may also present excellent results with repair techniques.



**Fig 7.** Final aspect of the right knee on the first postoperative day.

## References

1. Campbell SE, Sanders TG, Morrison WB. MR imaging of meniscal cysts: incidence, location, and clinical significance. *Am J Roentgenol* 2001;177:409-413.
2. Kose O, Erol B, Ozyurek S, Ege T. A giant medial parameniscal cyst of the knee joint. *BMJ Case Rep* 2013;2013.
3. Lui TH. Endoscopic resection of medial extra-articular cysts of the knee. *Arthrosc Tech* 2017;6(2):e461-e466.
4. Sivasubramanian H, Ee G, Srinivasaiah MG, et al. Not Always a Baker's cyst—an unusual presentation of a central voluminous postero-medial meniscal cyst. *Open Orthop J* 2012;6:424-428.
5. Ohishi T, Suzuki D, Matsuyama Y. Arthroscopic decompression for a giant meniscal cyst. *Orthopedics* 2016;39:e166-e168.
6. Chang JJ, Li YH, Lin GM, Wu CC, Shen HC, Pan RY. Comparison of the recurrence risk of parameniscal cysts between patients treated with arthroscopic excision and arthroscopic decompression techniques. *Knee Surg Sports Traumatol Arthrosc* 2016;24:1547-1554.
7. Cowden CH 3rd, Barber FA. Meniscal cysts: treatment options and algorithm. *J Knee Surg* 2014;27:105-111.
8. Tyson LL, Daughters TC Jr, Ryu RK, Crues JV III. MRI appearance of meniscal cysts. *Skeletal Radiol* 1995;24:421-424.
9. Anderson JJ, Connor GF, Helms CA. New observations on meniscal cysts. *Skeletal Radiol* 2010;39:1187-1191.
10. Reagan WD, McConkey JP, Loomer RL, Davidson RG. Cysts of the lateral meniscus: arthroscopy versus arthroscopy plus open cystectomy. *Arthroscopy* 1989;5:274-281.
11. Park SE, Panchal K, Jeong JJ, et al. Extra-articular ganglion cysts around the knee joint. *Knee Surg Relat Res* 2015;27:255-262.
12. El-Assal M, Mostafa M, Abdel-Aal A, El-Shafee M. Arthroscopy alone or in association with open cystectomy: in treatment of lateral meniscal cysts. *Knee Surg Sports Traumatol Arthrosc* 2003;11:30-32.
13. Ahn JH, Wang JH, Yoo JC, Kim SK, Park JH, Park JW. The modified outside-in suture: vertical repair of the anterior horn of the meniscus after decompression of a large meniscal cyst. *Knee Surg Sports Traumatol Arthrosc* 2006;14:1288-1291.
14. Lu KH. Arthroscopic meniscal repair and needle aspiration for meniscal tear with meniscal cyst. *Arthroscopy* 2006;22:1367.
15. Xu N, Zhao Y, Zhang Q. Arthroscopic meniscoplasty versus meniscectomy for knee meniscal injuries in elderly patients. *Int J Clin Exp Med* 2018;11:3800-3805.
16. Iorio R, Mazza D, Drogo P, et al. Lateral meniscal cysts: long-term clinical and radiological results of a partial meniscectomy and percutaneous decompressive needling [published online ahead of print, 2019 Dec 7]. *Int Orthop*.
17. Baima J, Krivickas L. Evaluation and treatment of peroneal neuropathy. *Curr Rev Musculoskelet Med* 2008;1:147-153.