

Received: 2017.08.25  
Accepted: 2017.10.16  
Published: 2018.01.17

e-ISSN 1941-5923  
© Am J Case Rep, 2018; 19: 61-67  
DOI: 10.12659/AJCR.906818

## Complex Reconstruction with Flaps After Abdominoperineal Resection and Groin Dissection for Anal Squamous Cell Carcinoma: A Difficult Case Involving Many Specialities





Authors' Contribution:  
Study Design A  
Data Collection B  
Statistical Analysis C  
Data Interpretation D  
Manuscript Preparation E  
Literature Search F  
Funds Collection G

E 1 **Claudia Reali**  
E 1 **Richard Guy**  
B 2 **Chris Darby**  
B 3 **Lucy Cogswell**  
E 1 **Roel Hompes**

1 Colorectal Unit, Oxford University Hospital, Headington, Oxford, U.K.  
2 Department of Vascular Surgery, Oxford University Hospitals, Headington, Oxford, U.K.  
3 Department of Plastic Surgery, Oxford University Hospitals, Headington, Oxford, U.K.

**Corresponding Author:** Claudia Reali, e-mail: [claudiareali88@live.it](mailto:claudiareali88@live.it)  
**Conflict of interest:** None declared

**Patient:** Male, 49  
**Final Diagnosis:** Anal squamo cell carcinoma  
**Symptoms:** Inguinal mass • inflammation • perineal tumor  
**Medication:** —  
**Clinical Procedure:** Abdominoperineal resection (APR) • groin dissection and closure of the inguinal defect with oblique rectus abdominis myocutaneous (ORAM) flap  
**Specialty:** Surgery  
**Objective:** Unusual setting of medical care  
**Background:** Anal squamous cell carcinoma accounts for about 2–4% of all lower gastrointestinal malignancies, with a distant disease reported in less than 5%. Although surgical treatment is rarely necessary, this often involve large dissections and difficult reconstructive procedures.  
**Case Report:** We present a complex but successful case of double-flap reconstruction after abdominoperineal resection and groin dissection for anal squamous cell carcinoma (cT3N3M0) with metastatic right inguinal lymph nodes and ipsilateral threatening of femoral vessels. A multi-specialty team was involved in the operation. A vascular and plastic surgeon performed the inguinal dissection with en bloc excision of the saphenous magna and a cuff of the femoral vein, while colorectal surgeons carried out the abdominoperineal excision. The 2 large tissue gaps at the groin and perineum were covered with an oblique rectus abdominis myocutaneous flap and a gluteal lotus flap, respectively. A partially absorbable mesh was placed at the level of the anterior sheath in order to reinforce the abdominal wall, whereas an absorbable mesh was used as a bridge for the dissected pelvic floor muscles. The post-operative period was uneventful and the follow-up at 5 months showed good results.  
**Conclusions:** An early diagnosis along with new techniques of radiochemotherapy allow patients to preserve their sphincter function. However, a persistent or recurrent disease needs major operations, which often involve a complex reconstruction. Good team-work and experience in specialized fields give the opportunity to make the best choices to perform critical steps during the management of complex cases.  
**MeSH Keywords:** Carcinoma, Squamous Cell • Lymph Node Excision • Myocutaneous Flap • Surgical Mesh  
**Full-text PDF:** <https://www.amjcaserep.com/abstract/index/idArt/906818>

 2222  —  10  32



## Background

Anal cancer is an uncommon malignancy, with the majority of cases comprising anal squamous cell carcinoma (ASCC), which accounts about 2–4% of all malignant colorectal tumors [1]. Despite its rarity, its incidence has increased over the last 4 decades, especially among men. Historically, ASCC has affected women at a greater rate than men, but US data reveals such a dramatic rise among males that a parity in the sex-specific annual incidence rate has been reached (about 2 per 100 000). Blacks have a higher annual mortality and incidence rate compared to whites, although it is unclear if disparities in cancer care affect these results [2]. However, in the UK, the sex trend was different because the incidence of ASCC increased 126% in women and 69% in men during a period of 20 years, from 1990 to 2010 [3].

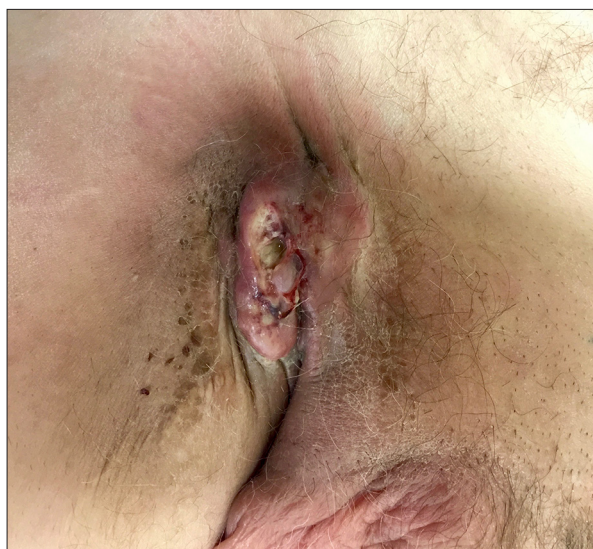Some aspects of ASCC carcinogenesis and etiology are similar to those of genital malignancies due to the close relation with Human Papillomavirus (HPV). Other predisposing factors include HIV infection, immune suppression after transplantation, Crohn's disease, and smoking [1,2,4–6].

ASCC rarely spreads outside the pelvis, with a distant disease reported in less than 5% of patients. Nowadays, an integrated and personalized treatment including radiochemotherapy (RCT) and surgery is considered the standard of care [1]. In the most complex cases, joint operations with gynecologists, urologists, vascular, plastic, and colorectal surgeons are essential to achieve good results.

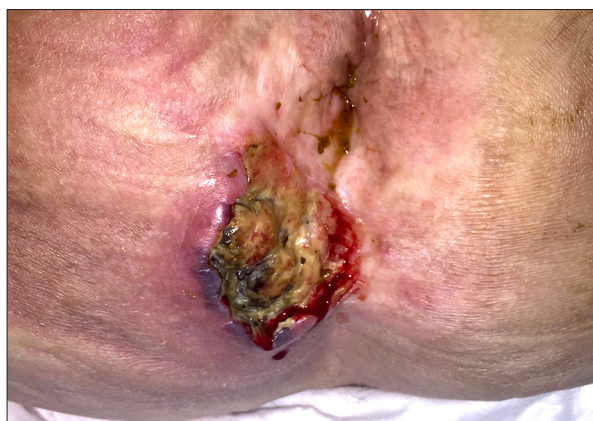We present our successful management of ASCC with inguinal lymph node metastasis and threatening of femoral vessels treated with an abdominoperineal resection (APR), groin dissection, and closure of the inguinal defect with an oblique rectus abdominis myocutaneous (ORAM) flap.

## Case Report

A 50-year-old man complaining of perianal discomfort, pain, and PR bleeding along with bulky right inguinal lymph nodes (Figure 1) was referred to the Colorectal Unit. He was a heavy smoker, but without any other co-morbidities (BMI 24.76). An EUA found a right-sided fungating mass invading the anal verge and the perineal skin (Figure 2). Anal biopsies were positive for moderately differentiated keratinizing squamous cell carcinoma, whereas right groin biopsy results were non-diagnostic. A staging MRI and PET/CT defined a tumor measuring 68×23 mm and extending to the skin of the natal cleft. The right inguinal lymph node with a necrotic center (56 mm) almost encased the right femoral vein without invading the lumen. There were no signs of distant disease (cT3N2M0).

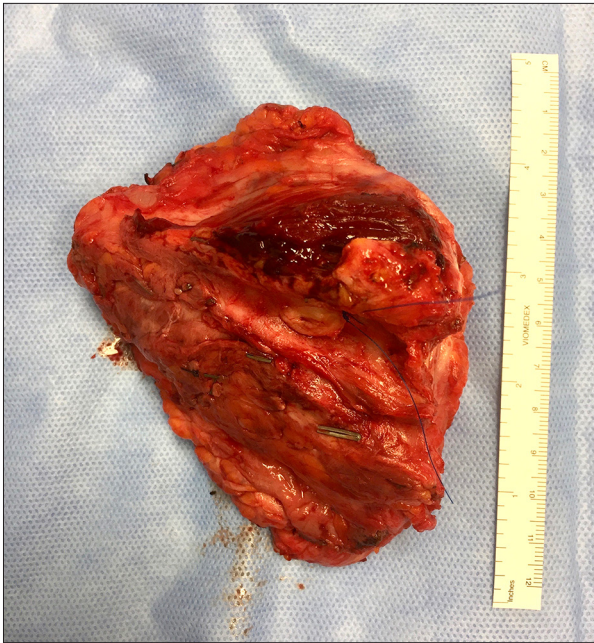

**Figure 1.** Inguinal lymph nodes. Bulky right inguinal lymph nodes (60×45 mm) encasing the femoral vein. Biopsy results were non-diagnostic. A preoperative course of antibiotics was administered to control the local infection.

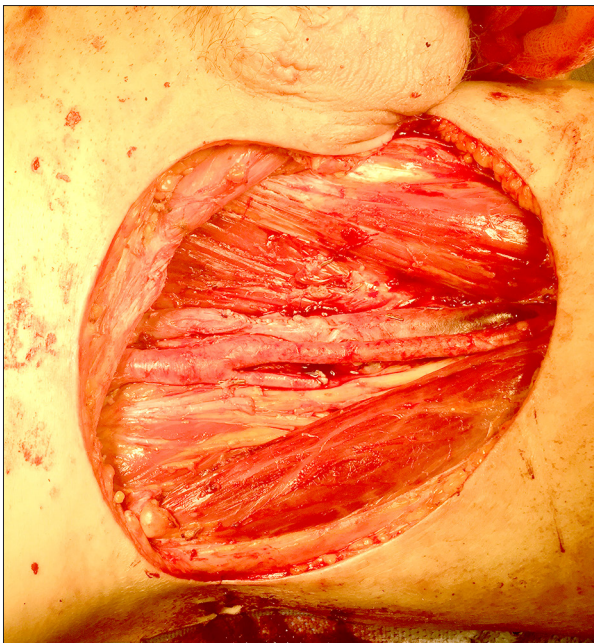

**Figure 2.** ASCC extending to perineal skin. Perineal lesion (70×30 mm) seen in Lloyd-Davis position. The tumor invades the right perineal skin at about 3 cm from the anus.

The multi-disciplinary team decided to start the treatment with RCT (53.2 Gy in 28 daily fractions, which was delivered by Intensity-Modulated Radiation Therapy (IMRT), associated with Mitomycin 12 mg/m<sup>2</sup> during the first day and Capecitabine 825 mg/m<sup>2</sup> during all the days of radiotherapy). Unfortunately, the patient missed the oncological outpatient appointment, causing a delay in the clinical evaluation and restaging, which was completed with MRI and PET/CT after 4 months from the end of the RCT. The anal cancer showed partial response (46 mm), but the inguinal lymph nodes were increased in volume to 62 mm. The major discomfort came from the inguinal mass that discharged serous fluid and resulted in *Bacteroides*



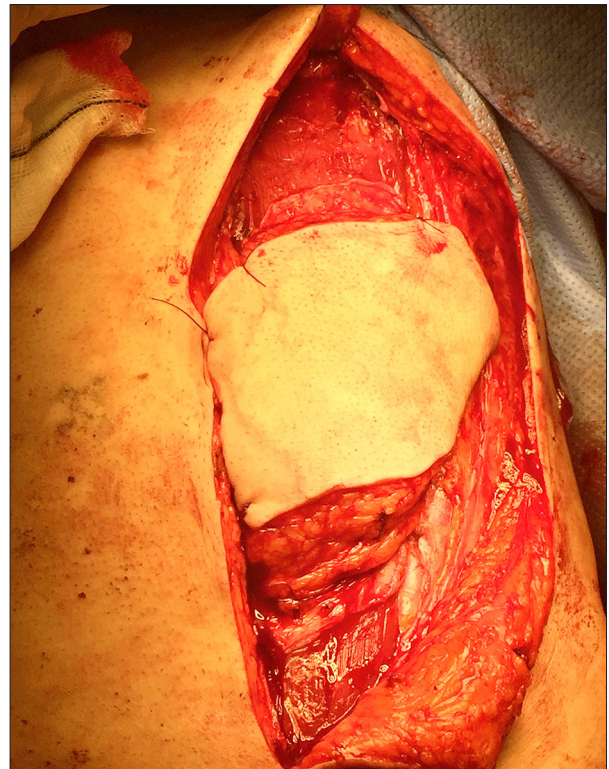**Figure 3.** Specimen of groin dissection. The specimen from inguinal dissection has a transversal cleft where femoral vessels were located. A cuff of femoral vein, taken to achieve negative margins, can also be noted at the center (marked with a knot).



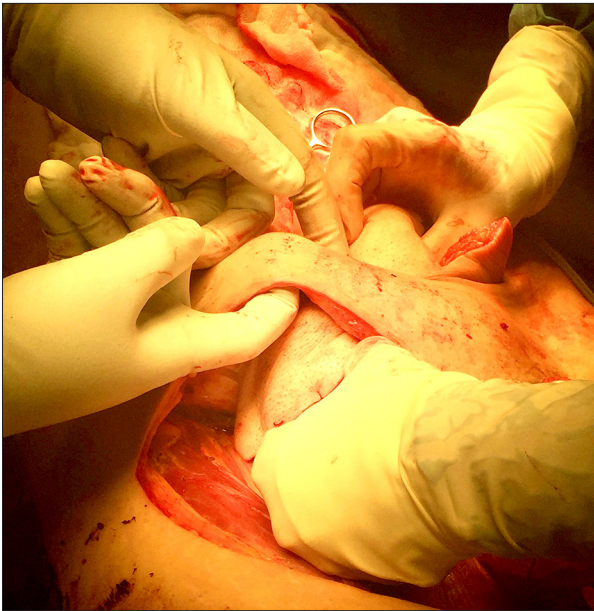
**Figure 4.** Completed inguinal dissection. The anatomy of Scarpa's triangle is shown after inguinal dissection. It is bounded superiorly by the inguinal canal, medially by the adductor longus muscle, and laterally by the sartorius muscle. At the center, the femoral vessels (with the vein sutured medial to the artery) can be noted.

*fragilis* infection. Antibiotic therapy with Metronidazole partially reduced the local edema and symptoms. Although morphine was necessary to control the pain when passing solid stool, the patient managed to keep a regular diet and maintain a stable weight.

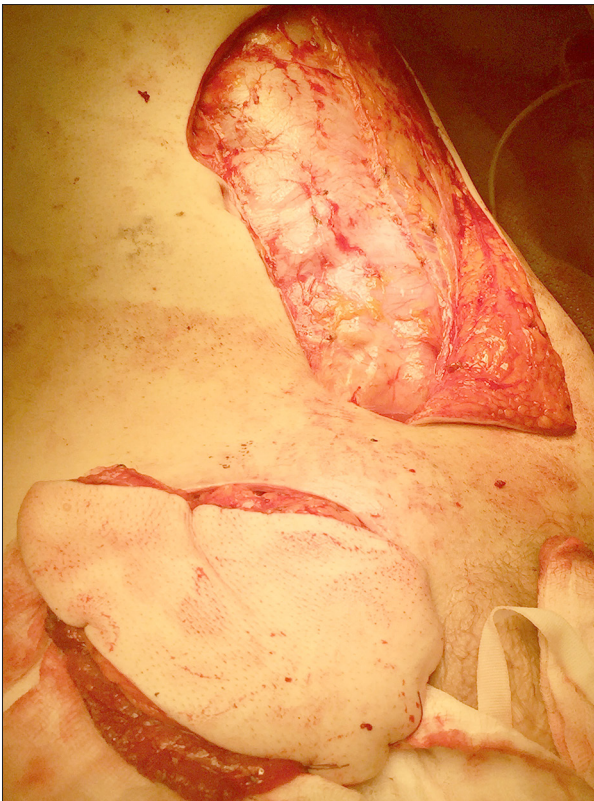The surgical operation was performed after 6 months from the end of the CRT. The first step was the groin dissection, which was performed by a plastic and vascular surgeon. Clear macroscopic lateral margins were achieved with a cranial approach over the external oblique fascia to femoral vessels. The femoral artery was not involved, but the saphenous magna vein was infiltrated and it was necessary to take a cuff of femoral vein to achieve negative margins (Figure 3). Cutaneous beaches of the femoral nerve were resected along with pectineus fascia and muscle (Figure 4). A left ORAM flap tunnelled subcutaneously to reach the groin was used to cover the defect (Figures 5–7). The second step was the abdominoperineal resection. A mid-line laparotomy was used to mobilize the sigmoid colon and achieve a low tie of the inferior mesenteric artery. The omental pedicle was vascularized by the left gastro-epiploic artery. The mesorectum was dissected down to the pelvic floor and



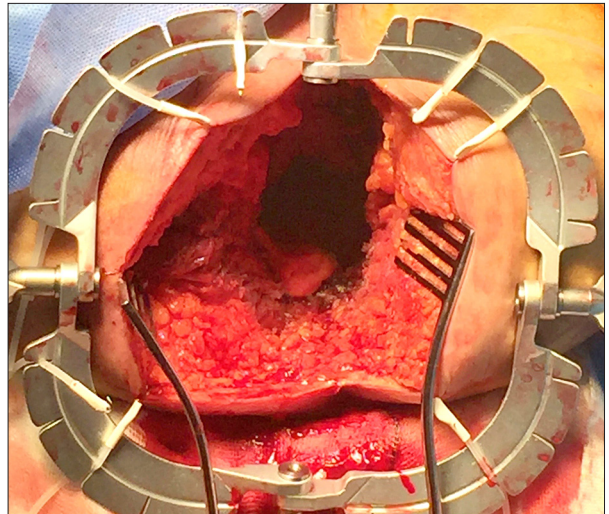
**Figure 5.** Abdominal myocutaneous flap preparation. The left abdominal wall was dissected to prepare the ORAM flap. The gap was subsequently reinforced with a partly absorbable lightweight multifilament mesh at the level of the anterior sheath. An end colostomy was formed in the right flank.



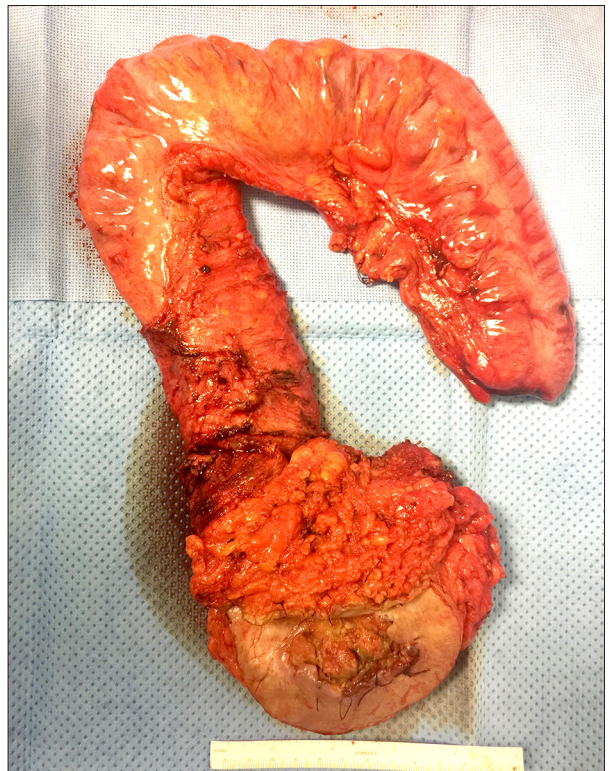**Figure 6.** Subcutaneous tunnel. A subcutaneous tunnel between the right abdominal dissection and the inguinal gap was formed to allow the passage of the myocutaneous flap to the right groin.



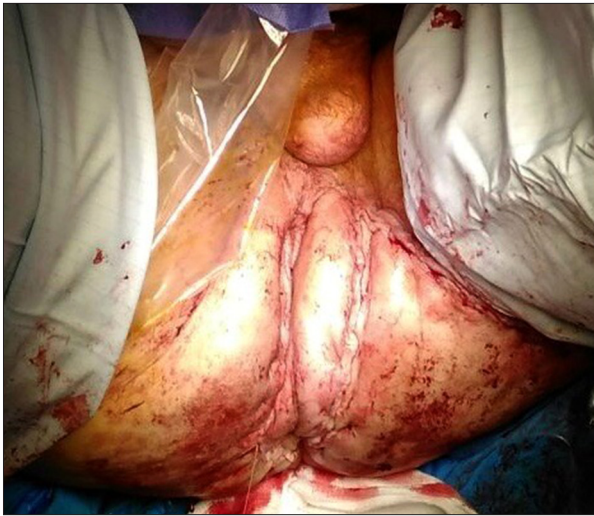**Figure 7.** Abdominal flap covering inguinal gap. The ORAM flap perfectly cover the inguinal gap. A partly absorbable lightweight multifilament mesh was later placed at the level of the abdominal dissection.



**Figure 8.** Completed perineal dissection. A large perineal defect was left by the extralevator abdominoperineal resection (Lloyd-Davis position). All the infiltrated skin was excised with clear margins.



**Figure 9.** Specimen of the abdominoperineal resection. The specimen from the abdominoperineal resection includes the sigmoid colon, ano-rectum, and perineal skin, with clear margins around the infiltrated site.



**Figure 10.** Completed perineal flap. The wide perineal gap was filled with an omental flap and a bridge absorbable mesh was stitched to the pelvic floor remnant to reinforce the pelvis. A gluteal lotus flap was used to close the perineal defect, with good result.

the end colostomy was fashioned in the right iliac fossa. The posterior sheath of the abdominal wall was closed with a continuous suture of Polydioxanone, whereas at the level of the anterior sheath, a partly absorbable lightweight multifilament mesh was placed. In lithotomic position, the wide perineal ulcerating lesion and the left ischio-rectal fossa fat with related lymph nodes were excised. The dissection continued up to the pelvic floor, with the removal of the coccyx, until meeting the abdominal dissection (Figures 8, 9). A drain was placed in the pelvis close to the omental flap. A bridge absorbable mesh was stitched to the pelvic floor remnant to reinforce the pelvis. A gluteal lotus flap was used to close the perineal defect (Figure 10).

The histopathology of the groin specimen showed a 60-mm tumor node with metastatic poorly differentiated squamous cell carcinoma, extensive necrosis with perineurial, and lymphovascular invasion. The tumor extended close to, although it did not invade, the underlying skeletal muscle. The femoral vein wall was adherent to the neoplastic tissue with a tumor thrombus/embolus inside. The histopathology of the abdominoperineal excision showed a poorly differentiated squamous cell carcinoma of the perianal skin, 14 mm in size, 60 mm distant to the dentate line, and without margin involvement or tumor budding (R0 ypT1 L0 V0 N2 M0). In light of the pathological result, no further radio- or chemotherapy was needed.

The post-operative period was uneventful and the patient was discharged on the 13<sup>th</sup> post-operative day. During the follow-up at 5 months after the operation, the wounds were well healed, there were no signs of lower-limb edema, and the patient only complained of moderate constipation.

## Discussion

Radiochemotherapy is the standard treatment for ASCC, whereas APR is usually reserved for patients presenting with recurrent or persistent disease [7]. Since ASCC rarely presents metastasis, the primary aim is local control with preservation of the anal sphincter, which can be obtained in most cases. Despite this, with doses of 50–60 Gy, anorectal function can be impaired [1,8]. New technologies (e.g., IMRT, rotational IMRT, image-guided radiotherapy, and stereotactic technique) have smaller margins and conformal plans, resulting in reduced radiation doses delivered to organs at risk, less acute toxicity, and shorter overall treatment time. Moreover, continuous radiosensitization is advisable to reinforce the efficiency and improve the sphincter preservation. In our case, a combination of Capecitabine and Mitomycin was administered. Oral Capecitabine, converted to 5-fluorouracil (5-FU) within the tumor, seems to be as tolerable and effective as intravenous 5-FU, which is more routinely utilized [9,10]. Furthermore, the benefits of Mitomycin in ASCC therapy are widely recognized and, although it has quick clearance, it lasts longer in hypoxic cells [11].

The overall 5-year survival ranges from 71% to 79% depending on the study, but the outcomes for cT3/T4 cancer with nodal disease are less favorable, with a 5-year disease-free survival of 31–38% [12,13]. Klas et al. reported a 62% survival rate at the 32-month follow-up in patients with adjuvant RCT and salvage APR [14].

The lymphatic drainage and the consequent lymph node metastasis depend on the relationship between the tumor and the dentate line: cancers located above the dentate line drain through the internal pudendal nodes into the internal iliac system, whereas tumors arising below the dentate line drain to the femoral and inguinal lymph nodes. The venous drainage follows a different path: the superior rectal/inferior mesenteric vein drains the blood from the upper half of the anal canal (portal system) and the inferior rectal vein from the lower half (systemic circulation). Also, the circumferential localization of the tumor is important: a carcinoma located laterally in the anal canal is more likely to metastasize to the lymph nodes of same side than the tumor midline location, which usually drains bilaterally [15].

Inguinal palpable lymph nodes are described in 16–25% of patients, and the probability of inguinal nodal involvement is about 20% in cT3/T4 cancers, with more than 50% of involved lymph nodes being <5 mm [1,15,16]. Although our patient had clear lymph node involvement without diagnostic discrepancy, a problem arises when metastatic lymph nodes are not evident to examination or imaging. Sentinel lymph node biopsy (SLNB) can be useful to detect micrometastasis in non-suspicious

lymph nodes, and it can spare the groin from irradiation and clarify controversial diagnostic imaging [17–19]. Mistrangelo et al. showed that SLNB is more accurate than PET-CT in staging groin lymph nodes [20]. However, thanks to the introduction of IMRT, which reduces acute toxicity and skin and femoral head damage, SLNB is losing importance in avoiding inguinal irradiation. Moreover, there are concerns that a difficult and prolonged inguinal wound healing could delay the start of RCT. Supporting that, De Jong et al. reported that 24% of post-operative complications occur in the groin [17,18].

One of the most important long-term complications of inguinal lymph node dissection is lymphedema (8–69%). Patients with more and larger lymph nodes tend to present with an earlier stage of secondary lymphedema [21,22]. Although our case had large and deep lymph node disease, lymphedema did not occur either before or after the operation.

En bloc lymphadenectomy often requires wide margins and a deep tissue excision, with a consequent large secondary defect that exposes femoral vessels or does not close directly. Furthermore, wounds in this region, which were often previously irradiated, have a higher percentage of dehiscence, lymphorrhea (6–40%), and infection (6–20%). There are several flaps that can be utilized for the groin reconstruction, of which the most commonly used are the tensor fascia lata pedicled and anterolateral thigh flap, and the ventral or oblique rectus abdominis myocutaneous flap. The first has some potential drawbacks, which include a thin distal part and bulkiness proximally (the flap rotation creates a “dog ear” which may interfere with sitting), potential loss of knee stability, and excessive tension with consequent suture separation or skin necrosis. Anterolateral thigh flaps have extremely small perforators that tend to thrombose soon after congestion develops, and the sacrifice of the deep fascia is associated with pain and weakness of the thigh. Rectus abdominis myocutaneous flaps have been largely used for the coverage of defects and protection of vessels in femoral and perineal regions because it provides an extensive cutaneous area, great thickness, no tension, good arch of rotation, well-vascularized tissue from a distal area to the irradiated groin, and a low rate of complications, with a single-stage procedure. In addition, when compared with the vertical rectus abdominis myocutaneous flap, the ORAM flap allows surgeons to more easily close the donor site and reduce the amount of muscle taken from the abdominal wall. However, only the contralateral muscle can be used because the inferior epigastric vessels on the ipsilateral side are often divided during inguinal dissection, compromising

the vascularization of the flap. For the same reason, previous cesarian sections and exploratory laparotomy are other contraindications. Because herniation or dehiscence have been reported in 9–17% of cases, stabilization of the donor site is recommended and is considered safe [22–25]. Furthermore, a decrease in maximum isometric flexion torque is reported to be about 20% at 1 year after the operation [26].

Since our patient had the groin defect closed with a myocutaneous flap and the perineal excision was not too extended, the wound was closed with a mesh and a lotus skin flap in order to avoid a further donor site dissection and become a source of possible additional complications. Despite this, myocutaneous flaps can be safely used to fill perineal defects because they reduce the duration of the wound healing and have a lower morbidity. In fact, primary closure is more than twice as likely to be associated with perineal complications compared with flap closure [27–30]. Biologic mesh has recently been introduced as an alternative form of reconstruction in order to improve perineal wound healing and reduce the perineal hernia rate. The mesh can be placed as an inlay or bridge across the defect and sutured to the origin of the elevator muscles. It has been suggested that biological mesh allows native cellular ingrowth, promotes tissue remodelling, acts as a physical barrier supporting the pelvic contents, and minimizes the pressure on the skin and ischioanal fat during the healing process. Despite the limited current data, reconstruction with mesh seems to have no significant difference in complication rate and has a shorter operative time compared with flap repair [31,32].

## Conclusions

This is the first described case, with good results and no complications, in which 2 flaps were used to cover large gaps left by the extensive oncological dissections. ASCC is a rare tumor, and an early diagnosis along with new techniques of RCT allow patients to preserve their sphincter function. In contrast, a persistent or recurrent disease needs major operations, which often involve a complex reconstruction. The involvement of gynecologists, urologists, and plastic and vascular surgeons is essential to decide the best approach, perform a good operation, and minimize post-operative complications. Good teamwork and experience in specialized fields give the opportunity to make the best choices to properly perform critical steps during the management of complex cases.

## References:

1. Glynne-Jones R, Salem W, Harrison M et al: Background and current treatment of squamous cell carcinoma of the anus. *Oncol Ther*, 2016; 4: 135–72
2. Johnson LG, Madeleine MM, Newcomer LM et al: Anal cancer incidence and survival: The surveillance, epidemiology and end results experience, 1973–2000. *Cancer*, 2004; 101: 281288
3. Wilkinson JR, Morris EJ, Downing A et al: The rising incidence of anal cancer in England 1990–2010: A population-based study. *Colorectal Dis*, 2014; 16(7): O234–39
4. Jamel A, Simard EP, Dorell C et al: Annual report to the nation on the status of cancer, 1975–2009. featuring the burden and trends in human papillomavirus – associated cancers and HPV vaccination coverage levels. *J Natl Cancer Inst*, 2013; 105: 175–201
5. Granata V, Fusco R, Reginelli A et al: Radiological assessment of anal cancer: An overview and update. *Infect Agent Cancer*, 2016; 11: 52
6. Szmulowicz UM, Wu JS: Squamous cell carcinoma of the anal canal: A review of the etiology, presentation, staging, prognosis and methods available for treatment. *Sex Health*, 2012; 9(6): 593–609
7. Glynne-Jones R, Rao S: Treatment of the primary tumour in anal canal cancers. *Surg Oncol Clin N Am*, 2017; 26(1): 73–90
8. Bentzen AG, Guren MG, Vonen B et al: Faecal incontinence after chemoradiotherapy in anal cancer survivors: Long-term results of a national cohort. *Radiother Oncol*, 2013; 108(1): 55–60
9. Deenen MJ, Dewit L, Boot H et al: Simultaneous integrated boost-intensity modulated radiation therapy with concomitant capecitabine and mitomycin C for locally advanced anal carcinoma: A phase 1 study. *Int J Radiat Oncol Biol Phys*, 2013; 85(5): e201–7
10. Thind G, Johal B, Follwell M, Kennecke HF: Chemoradiation with capecitabine and mitomycin-C for stage I–III anal squamous cell carcinoma. *Radiat Oncol*, 2014; 29(9): 124
11. Bartelink H, Roelofsens F, Eschwege F et al: Concomitant radiotherapy and chemotherapy is superior to radiotherapy alone in the treatment of locally advanced anal cancer: Results of a phase III randomized trial of the European Organization for Research and Treatment of Cancer Radiotherapy and Gastrointestinal Cooperative Groups. *J Clin Oncol*, 1997; 15(5): 2040–49
12. Gunderson LL, Moughan J, Ajani JA et al: Anal carcinoma: impact of TN category of disease on survival, disease relapse, and colostomy failure in US Gastrointestinal Intergroup RTOG 98-11 phase 3 trial. *Int J Radiat Oncol Biol Phys*, 2013; 87(4): 638–45
13. Baughman DM, Shah BK: Disparities in receipt of radiotherapy and survival age, sex and race among patients with non-metastatic squamous cell carcinoma of the anus. *J Gastrointest Oncol*, 2016; 7(6): 968–73
14. Klas JV, Rothenberger DA, Wong WD, Madoff RD: Malignant tumors of the anal canal: the spectrum of disease, treatment and outcomes. *Cancer*, 1999; 85(8): 1686–93
15. Tehrani S, Treglia G, Krag DN et al: Sentinel node mapping in anal canal cancer: Systematic review and meta-analysis. *J Gastrointestinal Liver Dis*, 2013; 22: 321–28
16. Gerard JP, Chapet O, Samiei F et al: Management of inguinal lymph node metastases in patients with carcinoma of the anal canal: Experience in a series of 270 patients treated in Lyon and review of the literature. *Cancer*, 2001; 92(1): 77–84
17. Swan MC, Furniss D, Cassell OCS: Surgical management of metastatic inguinal lymphadenopathy. *BMI*, 2004; 329: 1272–76
18. De Jong JS, Beukema JC, Van Dam GM et al: Limited value of staging squamous cell carcinoma of the anal margin and canal using the sentinel node lymph node procedure: Prospective study with long term follow up. *Am Surg Oncol*, 2010; 17: 2656–62
19. De Nardi P, Carvello M, Staudacher C: New approach to anal cancer: Individualised therapy based on sentinel lymph node biopsy. *World J Gastroenterol*, 2012; 18(44): 6349–56
20. Mistrangelo M, Pelosi E, Bellò M et al: Comparison of positron emission tomography scanning and sentinel node biopsy in the detection of inguinal node metastases in patients with anal cancer. *Int J Radiat Oncol Biol Phys*, 2010; 77: 73–78
21. Onoda S, Kimata Y, Yamada K et al: Relationship of the number and size of the superficial groin lymph nodes with the stage of secondary lymphatic edema. *J Surg Oncol*, 2016; 114(8): 940–46
22. Murthy V, Gopinath KS: Reconstruction of groin defects following radical inguinal lymphadenectomy: An evidence based review. *Indian J Surg Oncol*, 2012; 3(2): 130–38
23. Mao C, Peng X, Qu J: The effectiveness of prolene patch in hernia prevention following harvesting rectus abdomens myocutaneous flap. *Zhongguo Xiu Fu Chong Jian Wai Ke Za Zhi*, 2001; 15(6): 335–37
24. Navarro-Sanchez A, Von Room AC, Thomas RL et al: Soft tissue sarcoma in the thigh and groin. Reconstruction using ventral rectus abdominis myocutaneous flap. *Cir Esp*, 2014; 92: 693–94
25. Daigeler A, Simidjiiska-Belyaeva M, Drucke D et al: The versatility of the pedicled vertical rectus abdominis myocutaneous flap in oncologic patients. *Langenbecks Arch Surg*, 2011; 396(8): 1271–79
26. Daigeler A, Simidjiiska-Belyaeva M, Drucke D et al: The versatility of the pedicled vertical rectus abdominis myocutaneous flap in oncologic patients. *Langenbecks Arch Surg*, 2011; 396(8): 1271–79
27. Hardt J, Mai S, Weib C et al: Abdominoperineal resection and perineal wound healing in recurrent, persistent or primary anal carcinoma. *Int J Colorectal Dis*, 2016; 31(6): 1197–203
28. Devulapalli C, Jia Wei AT, DiBiagio JR et al: Primary versus flap closure of perineal defects following oncologic resection: A systematic review and meta-analysis. *Plast Reconstr Surg*, 2016; 137(5): 1602–13
29. Musters GD, Buskens CJ, Bemelman WA, Tanis PJ: Perineal wound healing after abdominoperineal resection for rectal cancer: A systematic review and meta-analysis. *Plast Reconstr Surg*, 2016; 137(5): 1602–13
30. Barker T, Branagan G, Wright E et al: Vertical rectus abdominis myocutaneous flap reconstruction of the perineal defect after abdominoperineal excision is associated with low morbidity. *Colorectal Dis*, 2013; 15(9): 1177–83
31. Alam NN, Narang SK, Kockerling F et al: Biologic mesh reconstruction of the pelvic floor after extra levator abdominoperineal excision: A systematic review. *Front Surg*, 2016; 3: 9
32. Foster JD, Pathak S, Smart NJ et al: Reconstruction of perineum following extralevator abdominoperineal excision for carcinoma of the lower rectum: A systematic review. *Colorectal Dis*, 2012; 14(9): 1052–59