



Stanford type B aortic dissection in an elderly patient with silent aortic coarctation

Choon-Bing Chua^a, Chih-Wei Hsu^a, Hsuan-Yin Wu^b, Chao-Sheng Chang^a, Kuo-Hsin Lee^{a,*}

^aDepartment of Emergency Medicine, E-Da Hospital and I-Shou University, Kaohsiung, Taiwan, ^bDivision of Cardiovascular Surgery, Department of Surgery, E-Da Hospital and I-Shou University, Kaohsiung, Taiwan

Received : 25-Nov-2016

Revised : 12-Dec-2016

Accepted : 06-Feb-2017

A 64-year-old man presented to our emergency department with sudden onset of severe back pain 1 h ago. He had been physically well without history of hypertension or other systemic diseases. On physical examination, a significant difference between blood pressure in the upper and lower limbs was noticed (183/93 and 183/99 mmHg in the right and left upper extremity; 148/98 and 163/104 mmHg in the right and left lower extremity, respectively). Chest radiography showed a prominent aortic knob. Chest computed tomography revealed a Stanford type B aortic dissection associated with an aortic coarctation and persistent left superior vena cava [Figure 1]. Furthermore, the coarctation was found to coexist with tubular arch hypoplasia [Figures 2 and 3]. Considering the extreme age and high risk for surgery, medical treatment with angiotensin receptor blocker was given. The patient was in good physical condition after a 6-month follow-up.

Aortic coarctation is an uncommon congenital luminal narrowing of the aortic arch which is commonly associated with cardiovascular abnormalities. Moreover, the persistent left superior vena cava is a rare vascular anomaly which is most commonly seen in isolation and could also be associated with coarctation of aorta [1]. By morphology, aortic coarctation is divided into two main types: discrete coarctation and tubular arch hypoplasia. These two types may coexist [2]. The average survival age of unrepaired aortic coarctation was 35 years of age with high mortality in advanced age. Without correction, coarctation resulted in high morbidity and mortality from hypertension, coronary heart disease, aortic dissection, heart failure, aortic rupture, and infective endarteritis [3].

Aortic dissection, especially type B, is rarely associated with coarctation. To the best of our knowledge, only 13 cases of aortic coarctation with type B dissection were reported with patients' ages ranging from 25 to 56 years [4-16]. The locations of coarctations were mostly distal to the left subclavian artery except one which was located between left carotid and subclavian arteries [15]. All the reported coarctations were discrete coarctations. Our case is unique not only of its extreme age but also of its discrete coarctation coexisting with tubular arch hypoplasia and persistent left superior vena cava.

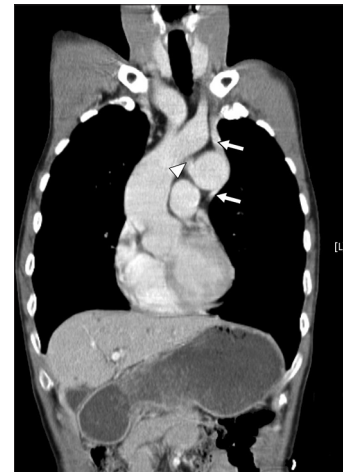


Figure 1: Contrast-enhanced coronal computed tomography image demonstrates the persistent left superior vena cava (white arrows) and the coarctation connecting from the tubular arch hypoplasia (white arrowhead)

Although uncomplicated type B dissection is well established to be treated conservatively, adult aortic coarctation is still considered a surgical candidate in the presence of peak-to-peak coarctation gradient >20 mmHg. The treatment for aortic coarctation included surgical repair, balloon angioplasty, and stenting [17]. While balloon angioplasty is the preferred treatment for discrete coarctation in infants and children between 4 months and 5 years of age (<25 kg), stenting is the first choice for larger patients (>25 kg). In the presence of complex coarctation anatomy such as arch hypoplasia, the decision to use balloon angioplasty or stenting versus surgical approach is made on a case-by-case basis. However, for the elderly concerning about the tissue integrity of the paracoarctation region with subsequent risk from complications of interventions, continued medical therapy with goal

*Address for correspondence:

Dr. Kuo-Hsin Lee,
Department of Emergency Medicine, E-Da Hospital, 1, Yi-Da Road, Jiao-Su Village, Yan-Chao District, Kaohsiung, Taiwan.
E-mail: peter1055@gmail.com

Access this article online

Quick Response Code:



Website: www.tcmjmed.com

DOI: 10.4103/tcmj.tcmj_65_17

This is an open access article distributed under the terms of the Creative Commons Attribution-NonCommercial-ShareAlike 3.0 License, which allows others to remix, tweak, and build upon the work non-commercially, as long as the author is credited and the new creations are licensed under the identical terms.

For reprints contact: reprints@medknow.com

How to cite this article: Chua CB, Hsu CW, Wu HY, Chang CS, Lee KH. Stanford type B aortic dissection in an elderly patient with silent aortic coarctation. Tzu Chi Med J 2017;29:183-4.

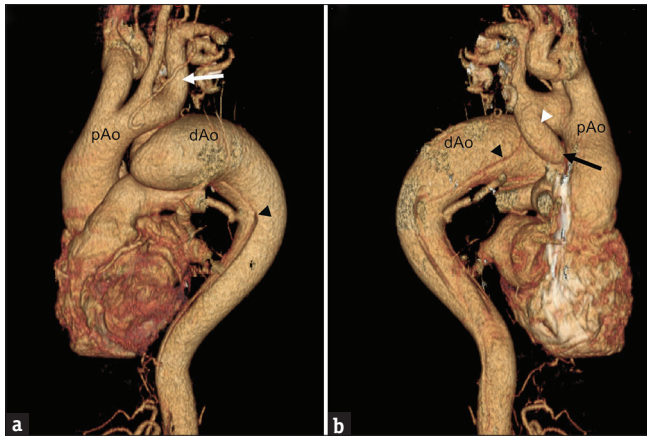


Figure 2: Three-dimensional reconstruction of a computed tomography angiography. (a) Anterior view shows a Stanford type B aortic dissection (black arrowhead) with obvious anomaly of aortic arch. The aortic arch is seemingly interrupted in the middle and divided into proximal and distal portion after bifurcation of left subclavian artery (white arrow). The distal portion of the arch enlarges to a bulbous aneurysm. (b) Posterior view demonstrates a downward curving tubular hypoplasia (white arrowhead) which arises from the proximal portion of the aortic arch and funnels down toward the discrete coarctation (black arrow). The dissection shows the intimal flap originated from the distal portion of aortic arch (black arrowhead)

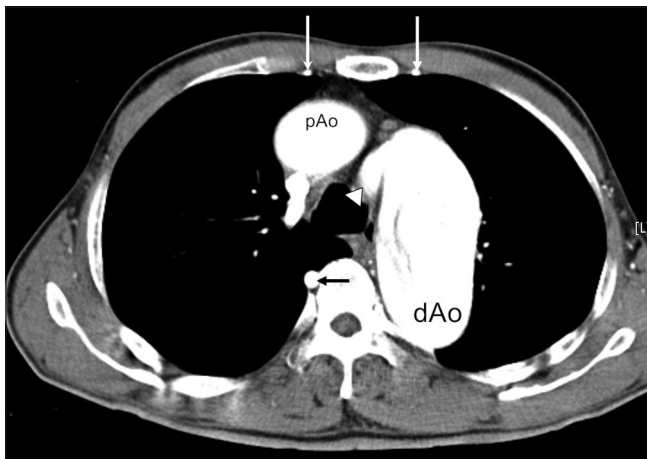


Figure 3: Contrast-enhanced transaxial computed tomography image demonstrates the aortic dissection started just after the discrete coarctation that was connected from the tubular hypoplasia (white arrowhead). There were collateral vessels of dilated internal mammary arteries (white arrows) and intercostal artery (black arrow). pAo: Proximal portion of aortic arch, dAo: Distal portion of aortic arch

of controlling pressure gradient using beta-blocker, angiotensin-converting enzyme inhibitors, or angiotensin receptor inhibitors may be an acceptable option [18].

Declaration of patient consent

The authors certify that the patient have obtained appropriate patient consent form. In the form, the patient has given his consent for his images and other clinical information to be reported in the journal. The patient understands that his name and initial will not be published and due efforts will be made to conceal their identity, but anonymity cannot be guaranteed.

Financial support and sponsorship

Nil.

Conflicts of interest

There are no conflicts of interest.

REFERENCES

- Goyal SK, Punnam SR, Verma G, Ruberg FL. Persistent left superior vena cava: A case report and review of literature. *Cardiovasc Ultrasound* 2008;6:50.
- Matsui H, Adachi I, Uemura H, Gardiner H, Ho SY. Anatomy of coarctation, hypoplastic and interrupted aortic arch: Relevance to interventional/surgical treatment. *Expert Rev Cardiovasc Ther* 2007;5:871-80.
- Jenkins NP, Ward C. Coarctation of the aorta: Natural history and outcome after surgical treatment. *QJM* 1999;92:365-71.
- Kassaian SE, Abbasi K, Mousavi M, Sahebjam M. Endovascular treatment of acute type B dissection complicating aortic coarctation. *Tex Heart Inst J* 2013;40:176-81.
- Yanase Y, Kawaharada N, Hagiwara T, Nakazawa J, Maeda T, Koyanagi T, et al. Surgical treatment for aortic coarctation with chronic type B dissection: Report of a case. *Ann Vasc Dis* 2011;4:353-5.
- Rodríguez-García J, García Reyes ME, Sambola A, Cortés Sánchez E, Fernández-Valenzuela V, García-Dorado D. Endovascular treatment of a complicated acute type B aortic dissection in a patient with aortic coarctation. *Rev Esp Cardiol (Engl Ed)* 2017;70:595-6.
- Senaha S, Uezu T, Shimoji M, Akasaki M. Stanford type B aortic dissection associated with coarctation of the aorta. *Kyobu Geka* 2015;68:184-7.
- Li Y, Fan Z, Huang L, Xue Y, Sun L. A novel approach for hybrid repair of type B aortic dissection associated with coarctation of the aorta. *J Vasc Surg* 2014;59:1422-5.
- Di Eusano M, Pilato E, Pantaleo A, Di Bartolomeo R. Type B aortic dissection complicating an isthmic coarctation in a Turner patient. *J Cardiovasc Med (Hagerstown)* 2012;13:225-8.
- Marque N, Gibault-Genty G, Galuscan G, Goudot B, Georges JL, Normand JP. Acute type-B aortic dissection associated with isthmic coarctation in adult. *Ann Cardiol Angeiol (Paris)* 2011;60:300-3.
- Kato W, Ueda Y, Akihiko U, Akita T, Oshima H, Shimomura T. Type B aortic dissection associated with coarctation of the aorta. *Gen Thorac Cardiovasc Surg* 2007;55:302-4.
- Shin JS, Sun K, Shim WJ, Kim KT, Kim HM. Acute descending aortic dissection associated with coarctation in adult. *Asian Cardiovasc Thorac Ann* 2002;10:354-5.
- Bhan A, Agarwal S, Sharma R, Venugopal P. Juxtaductal coarctation with type B dissection of the aorta: A new operative technique. *J Thorac Cardiovasc Surg* 2002;123:365-7.
- Milano A, De Carlo M, Gigoni R, Bortolotti U. Acute type-B aortic dissection in association with isthmic coarctation. *Tex Heart Inst J* 2001;28:152-3.
- Katsumata T, Westaby S. Operation of mid-arch coarctation. *Ann Thorac Surg* 1999;67:1386-90.
- Yamaguchi A, Adachi H, Kamio H, Murata S, Okada M, Adachi K, et al. A combination of preductal aortic coarctation and type B dissection: Report of a case. *Surg Today* 1998;28:435-7.
- Suradi H, Hijazi ZM. Current management of coarctation of the aorta. *Glob Cardiol Sci Pract* 2015;2015:44.
- Khan AN, Carter W, Mousa AY. Medical management of aortic coarctation is feasible & durable in selected patients: A case report & literature review. *W V Med J* 2015;111:18-21.