

## Review

# Clinical review: Alternative vascular access techniques for continuous hemofiltration

Joseph V DiCarlo<sup>1</sup>, Scott R Auerbach<sup>2</sup> and Steven R Alexander<sup>3</sup>

<sup>1</sup>Division of Pediatric Critical Care Medicine, Stanford University School of Medicine, Welch Road, Palo Alto, California 94304, USA

<sup>2</sup>Department of Pediatrics, Lucile Packard Children's Hospital, Stanford University School of Medicine, Welch Road, Palo Alto, California 94305, USA

<sup>3</sup>Division of Pediatric Nephrology, Stanford University School of Medicine, SUMC G306A, Stanford, California 94305, USA

Corresponding author: Joseph V DiCarlo, [jdicarlo@stanford.edu](mailto:jdicarlo@stanford.edu)

Published: 19 September 2006

This article is online at <http://ccforum.com/content/10/5/230>

© 2006 BioMed Central Ltd

*Critical Care* 2006, **10**:230 (doi:10.1186/cc5035)

## Abstract

Obtaining or maintaining vascular access for continuous hemofiltration can sometimes be problematic, especially in the child or adult in multiple organ failure with edema and/or coagulopathy. Problems commonly encountered include obstruction of the femoral vein by the catheter, insertion difficulties, safety concerns when cannulating the subclavian vein in coagulopathy, and catheter and circuit occlusion due to disseminated intravascular coagulation. For access in infants we describe a technique utilizing two single-lumen thin-walled vascular sheaths. For infants and small children initial access to the vein may be difficult due to edema or poor perfusion. For this situation we describe the 'mini-introducer' technique of securing the vein and facilitating subsequent insertion of a relatively large guide wire. At any age an alternative route to the subclavian vein, from above the clavicle, is potentially 'compressible' in the event of hemorrhage during the procedure. We remind the reader of the utility of ultrasound guidance for cannulation of the internal jugular and subclavian veins. And lastly we review the options for venous return via the umbilical vein in infants, and via the antecubital vein in larger children and adults.

## Introduction

Continuous hemofiltration can be administered safely to patients of all sizes, with the possible exception of the tiniest of premature newborns. However, obtaining vascular access can sometimes be problematic, especially in the small child with edema and/or coagulopathy. Problems commonly encountered include: venous obstruction caused by the hemofiltration catheter; difficulty with insertion of a large catheter in a small patient; cannulating the subclavian vein in the face of coagulopathy; and catheter and circuit clotting due to diffuse intravascular coagulation.

The femoral vein of a newborn often cannot accommodate a standard double lumen hemofiltration catheter without near-total occlusion of the vein and subsequent stasis affecting the

entire leg; for this we describe a strategy utilizing two single-lumen thin-walled vascular sheaths. For older infants and children access may be difficult due to edema or poor perfusion. For this we describe the mini-introducer technique of percutaneously securing the vein and facilitating insertion of the relatively large guide wire required for passage of the hemofiltration catheter. Subclavian venous access is relatively contraindicated at any age in the face of coagulopathy, but may sometimes be necessary for hemofiltration (or as supplemental venous access). For this we describe an alternative route to the subclavian vein, from above the clavicle, potentially 'compressible' in the event of hemorrhage. We remind the reader of the utility of ultrasound guidance for cannulation of the internal jugular and subclavian veins. And lastly we review the options for venous return via the umbilical vein in infants, and via the antecubital vein in larger children and adults.

## Rapid infusion catheter or sheath

Double-lumen hemofiltration catheters are currently available in sizes no smaller than 7 French (Fr; that is, outer diameter 2.3 mm). The femoral vein of a two-year-old is about 6 mm in diameter, as is the internal jugular vein [1] (Table 1). The femoral vein of a newborn is about 4.5 mm in diameter [2]; it sometimes cannot accommodate a 7 Fr catheter without near-total occlusion of the vein and subsequent stasis affecting the entire leg. To establish non-obstructive access for hemofiltration in a newborn, two single-lumen thin-walled vascular 'introducer' sheaths can be used in two separate veins. Sheaths are commonly used by anesthesiologists as 'rapid infusion' catheters during operative procedures associated with blood loss (for example, liver transplantation). During insertion over a guide wire, the thin wall of the sheath is supported by a removable tapered dilator. After removal of the dilator, the thin-walled catheter may be collapsible,

Fr = French.

**Table 1**

**Average diameter of veins by age**

Vessel	Diameter (mm)							
	2 years	4 years	6 years	8 years	10 years	13 years	16 years	18+ years
Internal jugular	6.7	7.8	8.9	10	11.1	12.8	14.5	16.2
Femoral vein	6.3	7.0	7.7	8.5	9.2	10.4	11.5	12.6
Antecubital vein								18.0

The average diameter (mm) of veins was measured by computed tomography (internal jugular, femoral [1]) or by ultrasound (antecubital [17]).

particularly in the femoral position if the infant is moving; temporary security with a leg board may be necessary.

The double sheath technique can be used for patients of any size. The hemofiltration circuit may be connected directly to the sheath; this configuration permits the most unimpeded flow (up to 850 ml/minute in a 9 Fr sheath). The sheath may also be configured with a side port for the convenience of accessing the system slightly remote from the body; however, a hemostasis valve is in position immediately above the proximal entry point to the sheath, and must be fully secured with an obturator to prevent air embolus. This extra hardware reduces maximum flow possible through the system by as much as 75% if both sidearm and obturator are used [3]; however, flow will still be adequate for standard hemofiltration. If both femoral veins are chosen as access sites, use introducers of different lengths to minimize recirculation.

Animal data suggest that polyurethane catheters are less likely than silastic to encourage the growth of bacteria in the presence of a fibrin sheath. Fibrin deposition was evident at ten days [4]. Data on the duration of implantation of introducer sheaths are invariably coupled to the use of pulmonary artery catheters. The sheath is often left in place once the pulmonary catheter is removed. In a series of 68 adults with cancer, the mean duration of usage was less than 4 days, but some sheaths were in place up to 18 days. The authors meticulously tracked colonization rates, and found that the sheath was no more likely to be colonized than the pulmonary artery catheter, and that colonization rates were about 14 per 1,000 days; no nosocomial infections were detected [5].

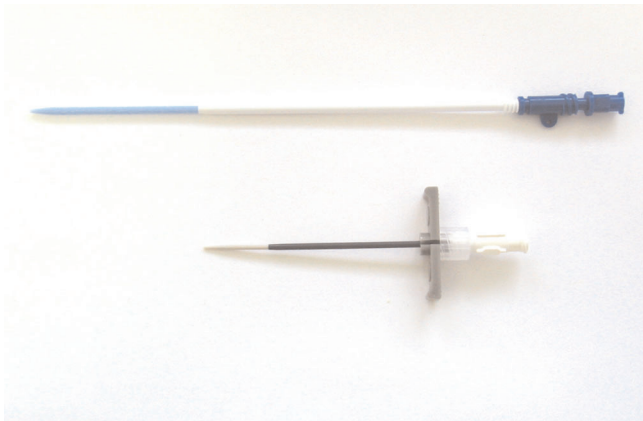
Manufacturers have recognized the utility of the introducer sheath as a very effective route for intravenous fluid delivery. However, catheters marketed as ‘rapid infusion sets’ are still just the same sheaths packaged with materials that enable quick placement either over a needle (in the field or in the emergency department) or via the Seldinger technique (in the operating room). Manufacturers have attempted to address the issue of catheter rigidity (and with it the attendant problems of kinking and cracking). The traditional sheath was composed of Teflon, which is stiffer than polyurethane. The

Cordis AVANTI®+ Sheath Introducer is designed to be kink-resistant by integrating a soft, flexible inner layer with a stiffer outer layer. The manufacturer (Arrow International Inc. Reading, PA, USA) claims that the catheter will maintain its patency ‘even in tortuous anatomy and scar tissue’. The Arrow-Flex® sheath is composed of a polyurethane blend with improved kink resistance.

Likely the most effective innovation on the horizon, however, is a method for integrating wound-wire reinforcement within the wall of the catheter [6]. One commercially available intra-aortic balloon catheter utilizes thicker coiled wire reinforcement, but to date no manufacturer has marketed a thin-walled introducer sheath employing the more refined version of the innovation. Applicability in pediatrics of this and other innovations will be difficult to verify, as there are simply too few appropriate pediatric cases in which to test them. However, the practitioner should be aware that kinking is less of an issue in catheters placed in the subclavian or internal jugular positions, and that improvements in technology are being directed at the problem of sheath kinking.

**Mini-introducer insertion technique**

For older infants (and the occasional newborn with exaggerated venous volumes from cardiac or liver disease) a 7 Fr catheter may fit without venous obstruction. But initial access to the vein, and particularly insertion of a 0.89 mm (0.035”) guide wire, may be difficult due to edema or poor perfusion. In this situation it may be easier to first access the vessel with a small (21 gauge) needle and 0.46 mm (0.018”) guide wire. Over the wire a dilator (1 Fr tapering up to 4 Fr) is inserted in tandem with a 4.5 Fr ‘mini-introducer’ sheath (Figure 1). When dilator and smaller guide wire are removed, the remaining sheath can accept the larger guide wire needed for insertion of a larger dilator, followed by a multi-lumen hemofiltration catheter. Mini-introducer kits include the tapered dilator. The sheath in these kits is sometimes of the peel-away variety, which probably confers no advantage over a sheath that does not peel away; in any event, the peel-away type cannot be left in place as a rapid infusion catheter. Any standard 4 Fr or 5 Fr introducer sheath kit would probably perform just as well for the mini-introducer technique. This approach may be counterproductive in the larger patient

**Figure 1**

Introducer sheath and 'mini-introducer' sheath.

(over 30 kg), as threading a dilator or catheter over a thin wire through thick subcutaneous tissue sometimes results in a kinked wire.

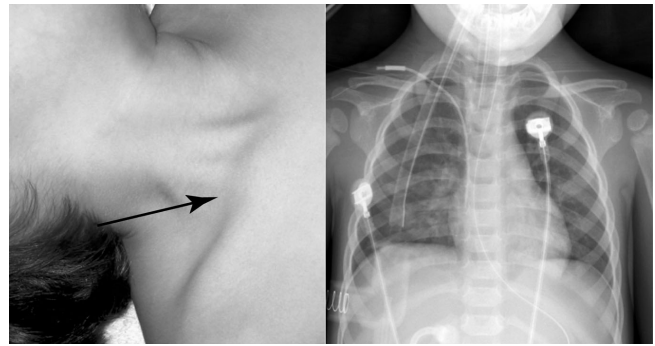
### Supraclavicular approach to subclavian

Access via the subclavian vein is relatively contraindicated in the coagulopathic patient, but may sometimes be necessary for hemofiltration (or as supplemental venous access). An alternative route to the subclavian vein is available, from above the clavicle (Figure 2). This site is potentially 'compressible' in the event of hemorrhage during the procedure.

For the supraclavicular approach, the patient lies supine with the head turned away from the side of insertion. The operator identifies the lateral aspect of the clavicular head of the sternocleidomastoid muscle. The needle enters just lateral to the insertion of the muscle, passing under the clavicle from above. The needle is then directed at an angle 45 degrees to the sagittal plane and 15 degrees forward of the coronal plane, in effect remaining shallow in the thorax. The needle should pass only through cervical fascia without danger of piercing the pleura or subclavian artery, both of which should be posterior to the needle's trajectory. The needle enters the subclavian vein close to the confluence of the subclavian vein with the internal jugular vein [7]. The advantages of this approach include less risk of subclavian artery and pleural puncture, better-defined landmarks, and a more consistent angular technique. The subclavian vein may actually be more easily accessed from above the clavicle [8,9] but the technique has not been widely studied in children.

### Ultrasound guidance

When compared with standard placement technique guided by anatomical landmarks alone, ultrasound guidance decreases the rate of failure at either the internal jugular or subclavian vein, decreases complications during catheter placement, and decreases the number of attempts at placement [10,11],

**Figure 2**

Landmarks for supraclavicular approach to the subclavian vein. Entry point for needle is from above the clavicle, just lateral to the clavicular head of the sternocleidomastoid muscle. Chest X-ray depicts origin of catheter.

particularly in children less than 1 year of age or under 10 kg [12]. Portable devices are commonplace in many intensive care units, and are standard equipment in anesthesia workrooms.

### The umbilical vein

Mechanical properties of the umbilical vein are comparable to those described for veins later in life [13]. The umbilical vein has been accessed as a return port for arterio-venous hemofiltration [14] and presumably could be utilized in veno-venous hemofiltration as well. The umbilical vein has been reported as a re-infusion site during veno-venous extracorporeal membrane oxygenation, accommodating a catheter as large as 10 Fr. The vessel tolerated return blood flows up to 250 ml/minute at a maximum pressure of 72 mmHg [15]. However, umbilical venous blood withdrawal can have direct impact on cerebral blood flow in preterm infants [16].

### The antecubital vein

The antecubital vein has not been reported as a return site for hemofiltration, but it is routinely accessed for apheresis. The antecubital vein in an adult is 18 mm in diameter, and can expand to 33 mm with maneuvers to increase venous stasis in the arm [17]. The antecubital vein has been reported as a return site for partial veno-venous bypass during liver transplantation, accommodating venous return flow up to 2,400 ml/minute via an 8.5 Fr introducer sheath [18].

### The hypercoagulable patient

Occasionally hemofiltration will be complicated by recurrent clotting of the catheter or hemofilter as a consequence of diffuse intravascular coagulation. This most commonly occurs with bacterial sepsis, or with fulminant hepatic failure, in which case hepatic necrosis is the instigator. If diffuse intravascular coagulation is suspected and circuit or access patency is problematic, a partial or single-volume plasma exchange will likely solve the problem. By inserting a four-way

Table 2

## Introducer sheaths and mini-introducers

Catheter	Size	Model	Notes
Arrow-Flex	6, 7, 8.5, 9 Fr × 10.5 cm	IK-09600	PSI kit; spring-wire guide: 0.89 mm (0.035") diameter; obturator [20]
Sheath obturator	14 cm	AO-07000	Arrow 8.5 and 9.0 Fr sheath valve assemblies
Arrow short obturator	Cap	AO-09000	Cap for hemostasis valve
Cordis AVANTI+	4, 5, 6 Fr × 5.5-7.5 cm	504-604P through 504-605S	With mini-wire 0.54 mm (0.021") [21]
Cook Access Plus	6 Fr, 9 Fr	C-FSSI-6.0-25-5.0	[22]
Argon Micro-Introducer	4 Fr	497811	Guide wire 0.46 mm (0.018") [23]
Enpath mini-introducer	4 Fr	10489-001	[24]
Arrow Simplicity	4 Fr		Guide wire 0.46 mm (0.018"); included in catheter kits 15 Fr
Cook Peel-Away	4.5 Fr	C-PLIP-4.5-21	Guide wire 0.54 mm (0.021") [22]
Bard MicroEZ PTFE Universal Safety Microintroducer Kit	4.5 Fr	0678945	[25]

If side-arm is included in sheath kit, obturators are usually included as well. French size conversions: 4 Fr (1.3 mm); 6 Fr (2.0 mm); 7 Fr (2.3 mm); 8 Fr (2.7 mm); 9 Fr (3.0 mm).

stopcock at the point of connection to the catheter, plasmapheresis can be performed without interrupting hemofiltration [19], but, in the case of circuit issues, it is more likely performed prior to the next attempt at re-establishing the hemofiltration circuit.

Table 2 lists the relevant characteristics of commercially available introducer sheaths and mini-introducers.

## Conclusion

The critical care physician should be able to establish vascular access for patients of any size in need of continuous hemofiltration even in the face of peripheral edema, bleeding diathesis or hypercoagulability. Options for venous access for continuous hemofiltration can be greatly expanded by utilizing introducer sheaths, either as venous output or return lines or as temporary ports for introduction of larger guide wires for insertion of standard hemofiltration catheters. Additional alternatives can be devised by adapting established vascular access techniques for apheresis, surgical veno-venous bypass, and neonatal extracorporeal membrane oxygenation.

## Competing interests

The authors declare that they have no competing interests.

## References

- Steinberg C, Weinstock DJ, Gold JP, Notterman DA: **Measurements of central blood vessels in infants and children: normal values.** *Cathet Cardiovasc Diagn* 1992, **27**:197-201.
- Akingbola OA, Nielsen J, Hopkins RL, Frieberg EM: **Femoral vein size in newborns and infants: preliminary investigation.** *Crit Care* 2000, **4**:120-123.
- Hyman SA, Smith DW, England R, Naukam R, Berman ML: **Pulmonary artery catheter introducers: do the component parts affect flow rate?** *Anesth Analg* 1991, **73**:573-575.
- Mehall JR, Saltzman DA, Jackson RJ, Smith SD: **Catheter materials affect the incidence of late blood-borne catheter infection.** *Surg Infect (Larchmt)* 2001, **2**:225-229; discussion 229-230.
- Blot F, Chachaty E, Raynard B, Antoun S, Bourgain JL, Nitenberg G: **Mechanisms and risk factors for infection of pulmonary artery catheters and introducer sheaths in cancer patients admitted to an intensive care unit.** *J Hosp Infect* 2001, **48**:289-297.
- Brustad JR, Adlparvar P, Aliahmad WR, et al., Applied Medical Resources Corporation, Rancho Santa Margarita, CA: *Kink-resistant access sheath and method of making same.* U.S. Patent 7005026. U.S. Patent and Trademark Office issued patent database. Search by patent number at <http://www.uspto.gov/patft/index.html>
- Yoffa D: **Supraclavicular subclavian venepuncture and catheterisation.** *Lancet* 1965, **2**:614-617.
- Nevarre DR, Domingo OH: **Supraclavicular approach to subclavian catheterization: review of the literature and results of 178 attempts by the same operator.** *J Trauma* 1997, **42**:305-309.
- Dronen S, Thompson B, Nowak R, Tomlanovich M: **Subclavian vein catheterization during cardiopulmonary resuscitation. A prospective comparison of the supraclavicular and infraclavicular percutaneous approaches.** *JAMA* 1982, **247**:3227-3230.
- Randolph AG, Cook DJ, Gonzales CA, Pribble CG: **Ultrasound guidance for placement of central venous catheters: a meta-analysis of the literature.** *Crit Care Med* 1996, **24**:2053-2058.
- Abboud PA, Kendall JL: **Ultrasound guidance for vascular access.** *Emerg Med Clin North Am* 2004, **22**:749-773.
- Leyvi G, Taylor DG, Reith E, Wasnick JD: **Utility of ultrasound-guided central venous cannulation in pediatric surgical patients: a clinical series.** *Paediatr Anaesth* 2005, **15**:953-958.
- Hellevik LR, Kiserud T, Irgens F, Stergiopoulos N, Hanson M: **Mechanical properties of the fetal ductus venosus and umbilical vein.** *Heart Vessels* 1998, **13**:175-180.
- Ronco C, Brendolan A, Bragantini L, Chiaramonte S, Feriani M, Fabris A, Dell'Aquila R, La Greca G: **Treatment of acute renal failure in newborns by continuous arterio-venous hemofiltration.** *Kidney Int* 1986, **29**:908-915.
- Kato J, Nagaya M, Niimi N, Tanaka S: **Venovenous extracorporeal membrane oxygenation in newborn infants using the umbilical vein as a reinfusion route.** *J Pediatr Surg* 1998, **33**:1446-1448.

16. Bray M, Stucchi I, Fumagalli M, Pagni L, Ramenghi L, Agosti M, Mosca F: **Blood withdrawal and infusion via umbilical catheters: effect on cerebral perfusion and influence of ibuprofen.** *Biol Neonate* 2003, **84**:187-193.
17. Nee PA, Picton AJ, Ralston DR, Perks AG: **Facilitation of peripheral intravenous access: an evaluation of two methods to augment venous filling.** *Ann Emerg Med* 1994, **24**:944-946.
18. Oken AC, Frank SM, Merritt WT, Fair J, Klein A, Burdick J, Thompson S, Beattie C: **A new percutaneous technique for establishing venous bypass access in orthotopic liver transplantation.** *J Cardiothorac Vasc Anesth* 1994, **8**:58-60.
19. Yorgin PD, Eklund DK, al-Uzri A, Whitesell L, Theodorou AA: **Concurrent centrifugation plasmapheresis and continuous venovenous hemodiafiltration.** *Pediatr Nephrol* 2000, **14**:18-21.
20. **Arrow International** [<http://www.arrowintl.com>]
21. **Cordis** [<http://www.cordis.com>]
22. **Cook Critical Care** [<http://www.cookcriticalcare.com>]
23. **Argon Medical Devices** [<http://www.argonmedical.com>]
24. **Enpath Medical** [<http://www.enpathmedical.com>]
25. **Bard Access Systems** [<http://www.bardaccess.com>]