



A case of isolated unilateral renal mucormycosis post COVID-19 pneumonia with fatal outcome

Rajiv Kumar Sethia, Aakib Hamid Charag^{*}

Urology and Kidney Transplant, Asian Institute of Medical Sciences, Faridabad, Haryana, India

ARTICLE INFO

Keywords:

Pyelonephritis
Emphysematous
COVID-19
Mucormycosis

ABSTRACT

Mucormycosis is a rare disease. It is typically seen in immunocompromised patients. Isolated renal mucormycosis is an extremely rare disease. We here report a case of isolated renal mucormycosis who had recently recovered from COVID-19 pneumonia. The patient was a known case of diabetes mellitus and had already developed acute kidney injury when he reported to us. Despite aggressive medical and surgical management, the patient succumbed to the disease.

1. Introduction

There has been an exponential increase in the rhinocerebral mucormycosis in India after second Covid-19 wave. Isolated renal mucormycosis is rare and has not been reported as a complication of Covid-19 disease. Our case developed isolated unilateral emphysematous pyelonephritis and renal mucormycosis after recovery from Covid-19 pneumonia.

2. Case report

A 46-year-old male patient had developed COVID-19 pneumonia two months back for which he was treated elsewhere with steroids and other supportive medications. Patient was a known case of diabetes and hypertension from last 15 years. One month after his recovery from COVID-19 pneumonia, patient developed persistent fever and left flank pain. He was diagnosed as a case of Class 3B Left Emphysematous Pyelonephritis (Fig. 1). His serum creatinine level was within normal limits. He was initially managed with broad spectrum antibiotics. Left DJ stenting and ultrasound guided drainage of perinephric collection was done with drain kept in situ.

He presented to our hospital two weeks after the placement of DJ stent and drain. He was still having fever episodes and left flank discomfort. His urine output had decreased over the past few days. On evaluation, he looked dehydrated and had facial puffiness. He had left ventricular dysfunction (LVEF – 40%). His blood glucose levels were in the range of 200–350mg/dl, hemoglobin was 10.1mg/dl and his serum

creatinine level was 2.4mg/dl. We did not obtain any specific serum fungal culture since we were not suspecting any fungal infection at the outset. Routine bacterial blood and urine culture at our hospital did not reveal any fungal growth.

After initial stabilization this patient was planned for Left Nephrectomy after discussing the procedure and anticipated complications with the family. Before surgery, patient underwent SLED (sustained low efficiency dialysis) as per nephrologist's advice in view of hyperkalemia and deranged arterial blood gas analysis. Procedure was initially attempted laparoscopically. However, in view of dense inflammation around the kidney, conversion to open surgery was done. Left subcostal incision was made and nephrectomy was completed. Large bowel could be dissected off the kidney. Left kidney was necrotic with multiple pockets of purulent fluid around the kidney. Perirenal fascia appeared thickened. Hilar vessels were encased in inflammatory tissue. Kidney was densely adherent to the posterolateral abdominal wall. A 28Fr abdominal tube drain was placed before the closure of incision. Towards the end of surgery, patient developed hypotension and metabolic acidosis. The blood loss was about 600ml. Despite blood transfusion, vasopressors and therapy for metabolic acidosis, patient could not be extubated. Patient was shifted to ICU and put on ventilatory support. During the post operative period, patient was managed with ventilatory support, antibiotics and other supportive care. In view of oliguria and persistent metabolic acidosis, nephrology consultation was done. Hemodialysis was done as per nephrologist's advice. Histopathology report of the nephrectomy specimen showed mucormycosis. Broad PAS positive hyphae (5–15 μ m diameter), irregularly branched with rare

^{*} Corresponding author. Department of Urology and Kidney Transplant, Asian Institute of Medical Sciences Sector 21A, Badkhal Flyover Road, Faridabad, Haryana, 121001, India.

E-mail address: ahc.gmc@gmail.com (A.H. Charag).

<https://doi.org/10.1016/j.eucr.2022.102061>

Received 27 February 2022; Received in revised form 20 March 2022; Accepted 23 March 2022

Available online 25 March 2022

2214-4420/© 2022 The Authors. Published by Elsevier Inc. This is an open access article under the CC BY-NC-ND license (<http://creativecommons.org/licenses/by-nc-nd/4.0/>).

septations (Fig. 2) and extensive necrosis (Fig. 3) were seen in the kidney. Liposomal Amphotericin B was started as per the intensivist advice on fourth post operative day. On fifth post operative day, patient developed sudden bradycardia for which resuscitation was done but patient developed cardiopulmonary arrest and could not be reviewed.

3. Discussion

Mucormycosis is rare in healthy immunocompetent individuals. However, the use of steroids for the management of Covid –19 disease has increased the risk of opportunistic infections especially in diabetic patients. Several cases of post Covid-19 mucormycosis involving different organs have been reported in literature. In August 2021, Singh AK et al.¹ have presented a systematic review of post covid-19 mucormycosis cases reported in literature. As per the study, 101 cases of mucormycosis in people with COVID-19 were reported which included predominantly male patients (78.9%).

Selarka L et al.² reported that out of 2567 COVID-19 patients admitted to 3 tertiary centres, 47 (1.8%) were diagnosed with mucormycosis. Most were not COVID-19 vaccinated and had developed moderate-to-severe pneumonia. All patients had received corticosteroids and broad-spectrum antibiotics while most ($n = 37$, 78.7%) received at least one anti-viral medication. Mean time elapsed from COVID-19 diagnosis to mucormycosis was 12.1 ± 4.6 days. Eleven (23.4%) subjects succumbed to their disease, mostly ($n = 8$, 72.7%) within 7 days of diagnosis. Among the patients who died, 10 (90.9%)

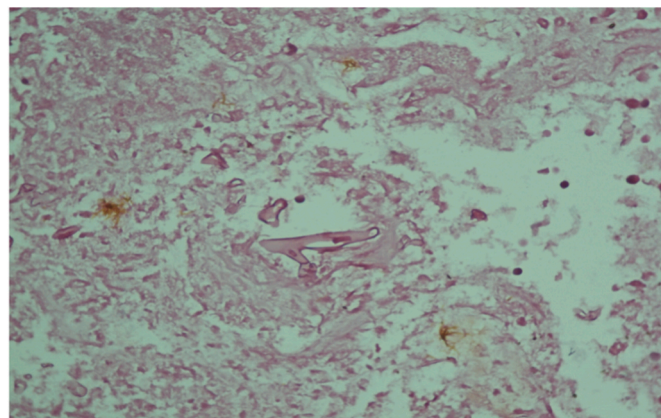


Fig. 2. Broad based hyphae seen on microscopy.

had pre-existing diabetes mellitus.

Rhinocerebral involvement is the most common form of mucormycosis. Less commonly involved organs include lung, skin or gastrointestinal system. Renal mucormycosis is an extremely rare disease. Bilateral renal mucormycosis is nearly 100% fatal especially in patients with acute kidney injury.³

A thorough review of literature revealed that till date none of the cases of “post COVID isolated renal mucormycosis” has been reported.

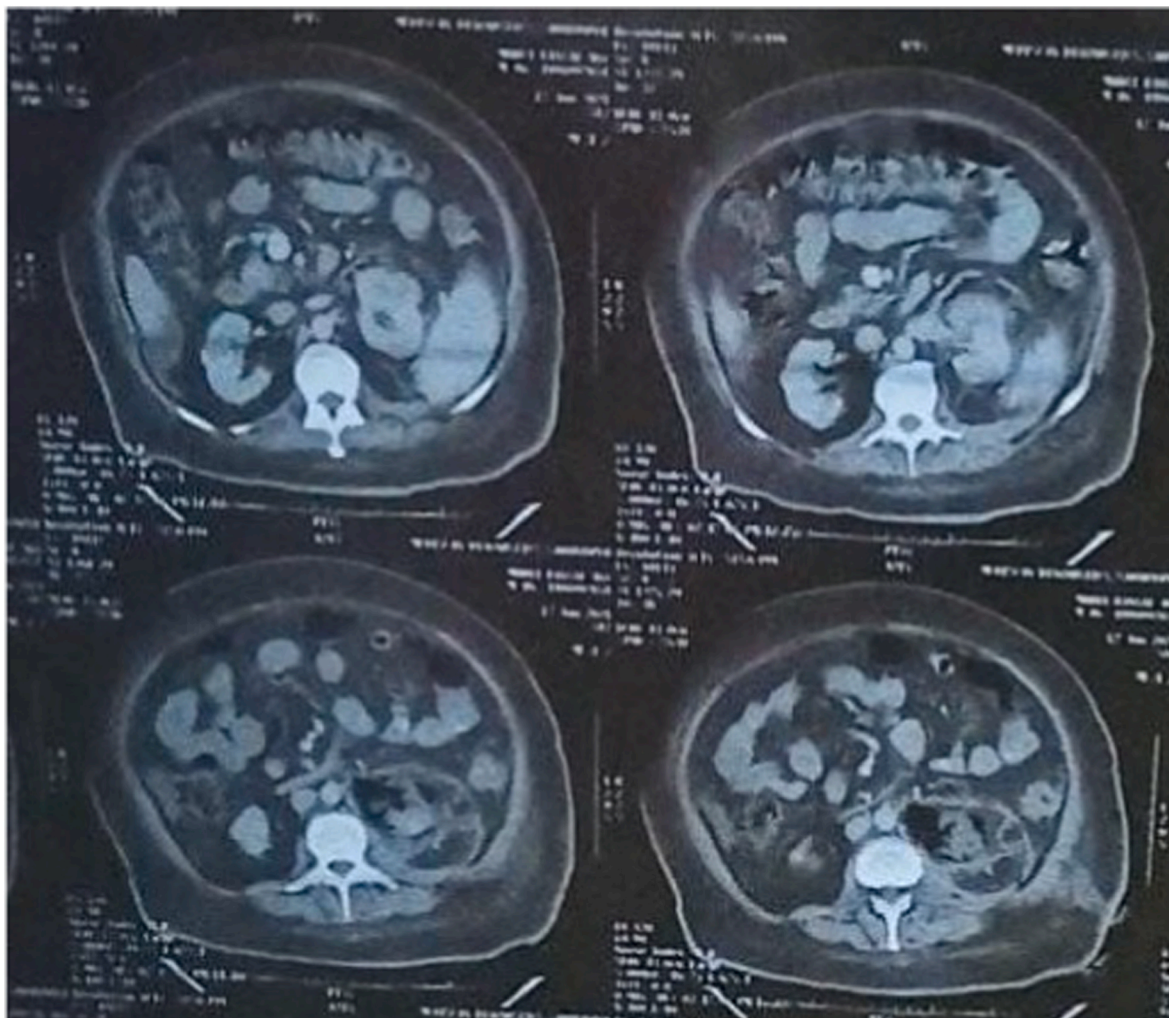


Fig. 1. Computed tomography images showing left emphysematous pyelonephritis.

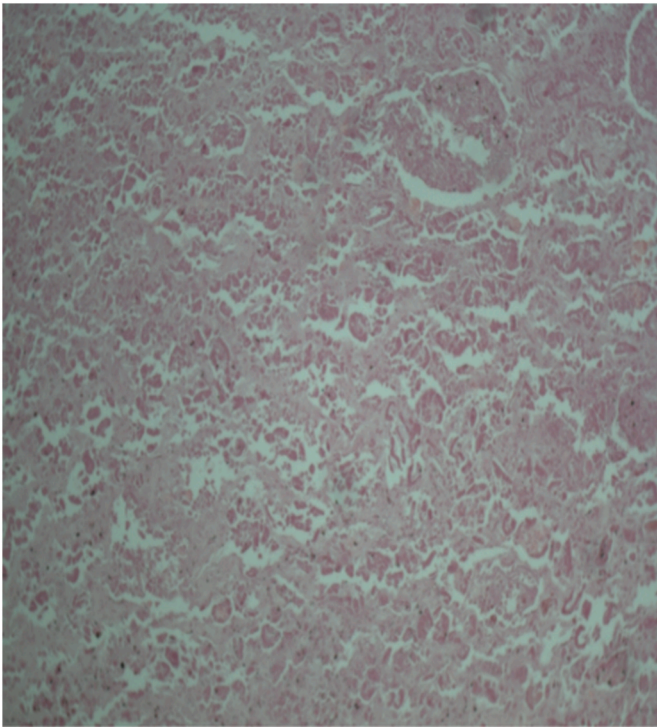


Fig. 3. Extensive necrosis seen in kidney.

Choudhary GR et al.⁴ has reported a case mucormycosis in a young male following recovery from COVID-19. This patient had simultaneous renal and bowel involvement. This patient was initially managed conservatively. Subsequently he underwent left-sided nephrectomy via the retroperitoneal incision. Intra-operatively, bowel appeared ischemic and congested for which an exploratory laparotomy was performed and gangrenous segment of the bowel beginning from the third part of

duodenum till proximal jejunum was resected. This patient developed severe metabolic acidosis, septic shock with anuria and succumbed to his illness after 10 hours. We also had a multi-disciplinary team approach for the management of our patient both in the preoperative and post operative period. Despite our best efforts we could not save the patient. Our patient had poorly controlled diabetes and already had acute kidney injury when he reported to our centre.

We believe that an immediate and proactive treatment would have changed the situation. Early nephrectomy should have been done since there was no improvement after placing DJ stent and drain. In fact, the condition of the patient was still deteriorating and he developed acute kidney injury. Early nephrectomy before acute kidney injury developed would have probably changed the outcome. Development of acute kidney injury is a bad prognostic factor in Emphysematous Pyelonephritis⁵ and is associated with fatal outcome in Renal Mucormycosis.

4. Conclusion

Isolated renal mucormycosis can be fatal. High index of suspicion should be there to make the diagnosis. Early detection and aggressive management may have a favourable outcome.

References

1. Singh AK, Singh R, Joshi SR, Misra A. Mucormycosis in COVID-19: a systematic review of cases reported worldwide and in India. *Diabetes, Metab Syndrome*. 2021;15(4), 102146. <https://doi.org/10.1016/j.dsx.2021.05.019>.
2. Selarka L, Sharma S, Saini D, et al. Mucormycosis and COVID-19: an epidemic within a pandemic in India. *Mycoses*. 2021;64:1253–1260. <https://doi.org/10.1111/myc.13353>.
3. Gupta K L, Gupta A. Mucormycosis and acute kidney injury. *J Nephropathol*. 2012;1(3):155–159. <https://doi.org/10.5812/nephropathol.8111>.
4. Choudhary GR, Aggarwal A, Jain V, Jena R. COVID-19 and fatal renal mucormycosis: contributory or coincidental? *Indian J Urol*. 2021;37(3):270–273. https://doi.org/10.4103/iju.iju_197_21.
5. Kapoor R, Muruganandham K, Gulia AK, et al. Predictive factors for mortality and need for nephrectomy in patients with emphysematous pyelonephritis. *BJU Int*. 2010 Apr;105(7):986–989. <https://doi.org/10.1111/j.1464-410X.2009.08930.x>. Epub 2009 Nov 20. PMID: 19930181.