

## Multiple Asymptomatic Hypopigmented Macules in a Child

A 15-year-old boy presented to our outpatient department with asymptomatic hypopigmented lesions over trunk and extremities for the past 5 years. There was no history of any preceding skin lesion, systemic complaints, loss of sensation, or swellings elsewhere in the body. On examination, there were multiple hypopigmented macules of varying size on the trunk, upper limbs and thighs [Figure 1]. Few lesions had overlying erythema. Peripheral nerves were not enlarged. General and systemic examinations were normal and there was no evidence of any lymphadenopathy or hepatosplenomegaly.

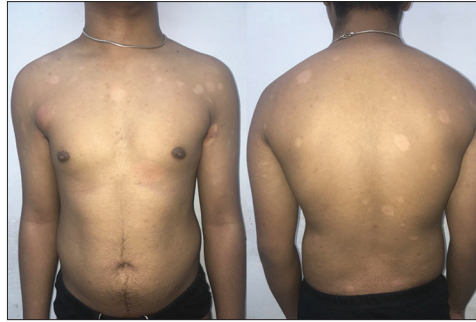Routine laboratory screening including a complete hemogram with peripheral smear for atypical lymphocytes and Sezary cells, liver and kidney function tests, serum LDH, chest X-ray, abdominal USG, CT scan of chest and abdomen flow cytometry were within normal limits. Skin biopsy done from the hypopigmented macule revealed mild orthokeratotic and focal parakeratotic hyperkeratosis, psoriasiform acanthosis and occasional basal apoptotic keratinocyte. Lymphocytes were seen tagged along with the basal layer and extending into lower epidermis [Figure 2]. Intraepidermal lymphocytes had a perinuclear halo and few had irregular enlarged nucleus. Mild wavy papillary dermal fibrosis were noted. Immunohistochemistry showed CD3+ epidermotropic and dermal T lymphocytic infiltrate with CD8+ cells constituting approximately 70% of lymphocytic population [Figure 3]; CD4+ was expressed in 60% cells in dermal infiltrate with most of the intraepidermal cells CD8+ve. 30% cells were CD7+ and 60% were CD2+. There was no loss of CD5.

### Question

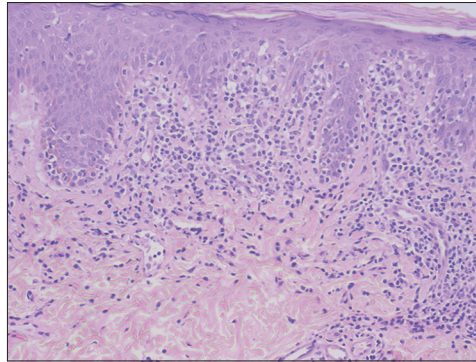
what is your diagnosis?

This is an open access journal, and articles are distributed under the terms of the Creative Commons Attribution-NonCommercial-ShareAlike 4.0 License, which allows others to remix, tweak, and build upon the work non-commercially, as long as appropriate credit is given and the new creations are licensed under the identical terms.

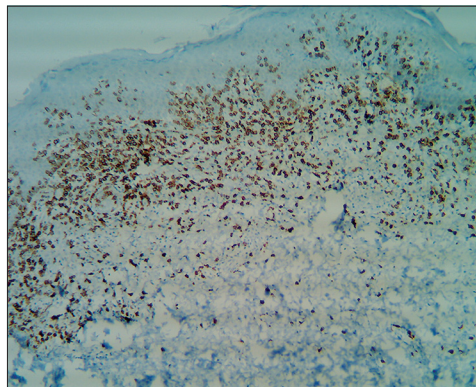
For reprints contact: WKHLRPMedknow\_reprints@wolterskluwer.com



**Figure 1:** Multiple hypopigmented macules of varying size on the trunk and upper limbs with few lesions showing overlying erythema



**Figure 2:** Epidermotropic lymphocytes are seen tagged along with the basal layer and extending into lower epidermis. Intraepidermal lymphocytes have perinuclear halo and few have an irregular enlarged nucleus. Mild wavy papillary dermal fibrosis is noted [H and E, ×20]



**Figure 3:** CD8 stains most of the epidermotropic lymphocytes and a major proportion of dermal lymphocytic infiltrate [IHC, ×10]

**How to cite this article:** Mathachan SR, Arora P, Sardana K, Batrani M. Multiple asymptomatic hypopigmented macules in a child. Indian Dermatol Online J 2021;12:193-4.

**Received:** 25-Nov-2019. **Revised:** 13-Dec-2019. **Accepted:** 06-Mar-2020. **Published:** 28-Sep-2020

**Sinu Rose Mathachan, Pooja Arora, Kabir Sardana, Meenakshi Batrani<sup>1</sup>**

Department of Dermatology, Venereology and Leprosy, Atal Bihari Vajpayee Institute of Medical Sciences and Dr. Ram Manohar Lohia Hospital, <sup>1</sup>Consultant Dermatopathologist, Delhi Derm Path Laboratory, 10, Aradhana Enclave, Ring Road, R K Puram, New Delhi, India

### Address for correspondence:

Dr. Pooja Arora,  
Department of Dermatology,  
Venereology and Leprosy,  
Atal Bihari Vajpayee Institute  
of Medical Sciences and  
Dr. Ram Manohar Lohia  
Hospital, New Delhi, India.  
E-mail: drpoojamrig@gmail.  
com

### Access this article online

**Website:** www.idoj.in

**DOI:** 10.4103/idoj.IDOJ\_575\_19

### Quick Response Code:



## Answer

Hypopigmented mycosis fungoides.

## Discussion

Mycosis fungoides (MF) is the most common primary cutaneous T cell lymphoma. Hypopigmented MF is an uncommon variant mostly seen in dark-skinned individuals and in children<sup>[1]</sup> with a median age of onset in children of around 10–12 years. The condition presents as hypopigmented macules that are asymptomatic, ill-defined with a slightly dry surface and may resemble other dermatological conditions like vitiligo, leprosy, pityriasis alba, pityriasis versicolor, pityriasis lichenoides chronica, progressive macular hypomelanosis, and postinflammatory hypopigmentation.<sup>[1-3]</sup> There are several theories that have been proposed for the depigmentation occurring in HMF, which include the destruction of melanocyte by the cytotoxic CD8+ T lymphocytes, abnormal melanogenesis and defective melanosome transfer from melanocytes to keratinocytes.<sup>[3]</sup> CD117, a stem cell factor receptor, that is present on epidermal melanocytes, has been found to be decreased in hypopigmented MF.<sup>[3]</sup>

Hypopigmented MF can be misdiagnosed as vitiligo or Hansen's disease. However, the lesions of vitiligo are depigmented and occur more frequently on exposed areas unlike MF. Leprosy was ruled out due to the absence hypoaesthesia and peripheral nerve thickening.

The histopathological and immunohistochemical analysis of HMF and classical MF may reveal peculiar features which may be helpful in differentiating them. Hypopigmented MF shows intense epidermotropism with haloed, large and atypical lymphocytes with convoluted nuclei, whereas Pautrier's microabscesses are rarely seen.<sup>[3]</sup> Immunophenotyping of HMF shows a CD8+ T lymphocytic predominance in contrast to classical MF (which shows a CD4+ T cell epidermotropism) as seen in our case. CD8+ cytotoxic T cells have a protective role as they prevent the shift from Th1 to Th2 and hence prevent the evolution from patches to plaques.<sup>[1,3,4]</sup> However, these findings are not always the rule and sometimes it may be impossible to distinguish HMF from classical MF and other benign inflammatory conditions including vitiligo.<sup>[1,5]</sup> In such cases, serial biopsies may be needed and PCR to look for monoclonal rearrangement of TCR can be helpful.<sup>[1,3]</sup> Hence, a high index of suspicion and well-organized diagnostic investigations including

serial biopsies, IHC, PCR for clonality, peripheral blood examination, quantification of Sézary cells and T lymphocytes using flow cytometry, physical examination and biopsy of peripheral lymph nodes, and imaging studies to exclude visceral impairment are the key to diagnosis.

Even though HMF carries an excellent prognosis, it should always be treated as a malignant condition and a regular follow-up is needed as the disease can recur months or years after the treatment and long-term survival data are currently not available.<sup>[3]</sup> Hypopigmented MF in adults and children shows a response to treatment with topical corticosteroids, UVB, PUVA, topical nitrogen mustard, or topical carmustine.<sup>[2]</sup> Our patient was treated with narrow-band UVB and showed partial repigmentation after 3 months. Complete repigmentation correlates with the clinical and histopathological resolution, whereas new hypopigmented lesions during remission suggest relapse.

## Declaration of patient consent

The authors certify that they have obtained all appropriate patient consent forms. In the form the patient(s) has/have given his/her/their consent for his/her/their images and other clinical information to be reported in the journal. The patients understand that their names and initials will not be published and due efforts will be made to conceal their identity, but anonymity cannot be guaranteed.

## Financial support and sponsorship

Nil.

## Conflicts of interest

There are no conflicts of interest.

## References

1. Ngo JT, Trotter MJ, Haber RM. Juvenile-onset hypopigmented mycosis fungoides mimicking vitiligo. *J Cutan Med Surg* 2009;13:230-3.
2. Khopkar U, Doshi BR, Dongre AM, Gujral S. A study of clinicopathologic profile of 15 cases of hypopigmented mycosis fungoides. *Indian J Dermatol Venereol Leprol* 2011;77:167-73.
3. Furlan FC, Sanches JA. Hypopigmented mycosis fungoides: A review of its clinical features and pathophysiology. *An Bras Dermatol* 2013;88:954-60.
4. Gameiro A, Gouveia M, Tellechea Ó, Moreno A. Childhood hypopigmented mycosis fungoides: A commonly delayed diagnosis. *BMJ Case Rep* 2014;2014:bcr2014208306.
5. Abdolkarimi B, Sepaskhah M, Mokhtari M, Aslani FS, Karimi M. Hypo-pigmented mycosis fungoides is a rare malignancy in pediatrics. *Dermatol Online J*. 2018 Nov 15;24 (11).