

# Case Report: Recurrent Mucoepidermoid Carcinoma of the Tongue in Adult Female Patient With Lung Cancer

Arielle Rubin, John Davis, Karim Jreije, Henry Wu and Randy Oppenheimer

Otolaryngology Section, Department of Surgery, Maricopa Medical Center, Maricopa Integrated Health System (MIHS), Phoenix, AZ, USA.

Clinical Medicine Insights:  
Ear, Nose and Throat  
Volume 10: 1–4  
© The Author(s) 2017  
Reprints and permissions:  
sagepub.co.uk/journalsPermissions.nav  
DOI: 10.1177/1179550617720462



**ABSTRACT:** There is a steady rise in incidence of malignant salivary gland tumors in the United States, with mucoepidermoid carcinoma (MEC) the most frequent. Although 40% of MECs are found in the parotid gland, these lesions possess the capacity to develop anywhere along the aerodigestive tract. Here, we present a case of recurrent tongue MEC in a young adult female patient with history of lung malignancy and multiple brain metastases. Without a universally accepted management protocol for recurrent MECs, the current clinical practice uses tumor grade, location, and clinical progression to determine both prognosis and goals of care. The patient had transoral laser excision of the first MEC lesion in 2013. Her tongue MEC recurred 3 years later with 2 distinct lesions. One was discovered on physical examination and computed tomography and the other diagnosed intraoperatively 1 month later. These lesions were located on a previously unaffected portion of dorsal tongue base. These lesions were completely excised in the operating room. The patient currently remains on chemotherapy. This underscores the importance for developing a guideline that delineates the most efficacious surveillance and treatment plans for recurrent MECs.

**KEYWORDS:** Mucoepidermoid carcinoma, parotid gland tumor, salivary gland tumor

**RECEIVED:** March 31, 2017. **ACCEPTED:** May 18, 2017.

**PEER REVIEW:** Three peer reviewers contributed to the peer review report. Reviewers' reports totaled 393 words, excluding any confidential comments to the academic editor.

**TYPE:** Case Report

**FUNDING:** The author(s) received no financial support for the research, authorship, and/or publication of this article.

**DECLARATION OF CONFLICTING INTERESTS:** The author(s) declared no potential conflicts of interest with respect to the research, authorship, and/or publication of this article.

**CORRESPONDING AUTHOR:** John Davis, Otolaryngology Section, Department of Surgery, Maricopa Medical Center, Maricopa Integrated Health System (MIHS), Hogan Building, 2601 E. Roosevelt Street, Phoenix, AZ 85008, USA.  
Email: John.Davis@mihs.org

## Introduction

The incidence of salivary gland masses in all head and neck cancers has been rising steadily in the United States from 6.3% in 1976 to 11% in 2006.<sup>1</sup> Mucoepidermoid carcinoma (MEC) is the most frequently occurring type, comprising approximately 35% of the salivary gland tumors. Although 40% of MECs are found in the parotid gland, they have the potential to develop anywhere along the aerodigestive tract.<sup>2</sup> Published data have shown MECs in minor salivary glands, buccal, lingual, retromolar, and labial mucosa. Although much less common, there are case reports of MECs found outside of the aerodigestive tract such as in the thyroid, laryngeal, conjunctival, and bronchogenic tissues.<sup>3–5</sup>

Important prognostic factors for MECs include progression of tumor size, obstructive symptoms, and histopathologic staging. The 5- and 15-year survival rates for low-grade MEC are 70% and 50%, respectively, whereas the 5- and 15-year survival rates for high-grade MECs are 50% and 25%, respectively.<sup>6</sup> There is a 3:2 preponderance of women to men ratio with an average age of onset around 48.<sup>7,8</sup> We present a distinctive case of a recurrent, multifocal MEC of the tongue in a young adult female patient with an unusual medical history of primary lung malignancy with multiple brain metastases.

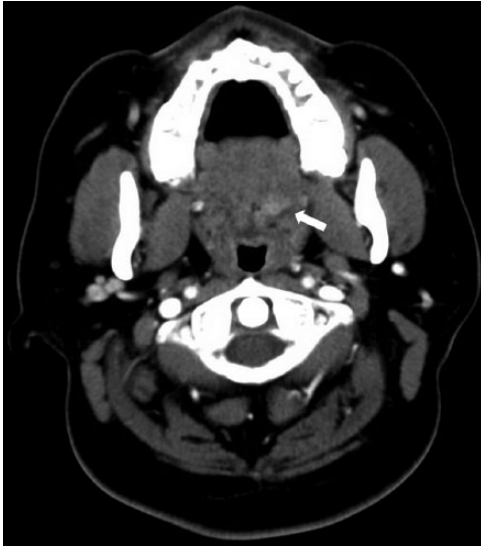
## Case Report

A 33-year-old Hispanic woman with a past medical history significant for biopsy and transoral laser excision of MEC in the anterior tongue presents to the clinic in 2013. The tissue specimen was positive for p63 on immunohistochemical assay

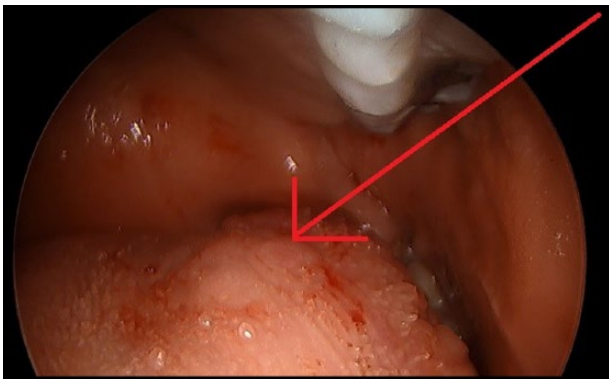
and mastermind-like 2 (MAML-2) rearrangement on fluorescent in situ hybridization. She presents to our clinic again in 2016 with a chief complaint of a palpable nodule at the left posterior aspect of her tongue. It is similar to the lesion excised in 2013. Patient's past medical history is further complicated by anaplastic lymphoma kinase (ALK)-positive lung cancer with multiple brain metastases. She was treated with continuous chemotherapy (alkaloid Navelbine 2010–2012, ALK inhibitor crizotinib 2014–2016 that was changed to alectinib in 2016) and 2 rounds of radiation therapy to the head and neck region. Her history of radiation exposure is a known risk factor for salivary gland tumors. She denied additional risk factors for salivary gland tumors such as chronic exposure to wood and leather tanning products. Her physical examination revealed a raised nodule at the left posterior tongue. An incisional biopsy of the lesion showed low-grade MEC positive for p63, cytokeratin 5/6 (CK 5/6), cytokeratin 7 (CK7), and epithelial membrane antigen (EMA).

As part of our preoperative workup, a neck computed tomography (CT) was obtained. It showed a 2.2-cm lesion in the left posterior tongue corroborating the findings on physical examination (Figure 1). A month after, the patient underwent transoral laser excision of the lesion with negative margins (Figure 2). During the excision, palpation of the right tongue base demonstrated an additional lesion that was previously undetected on physical examination or CT. An incisional biopsy of the new lesion also showed a low-grade MEC (Figure 3) with nontumoral margins. It was positive for p63

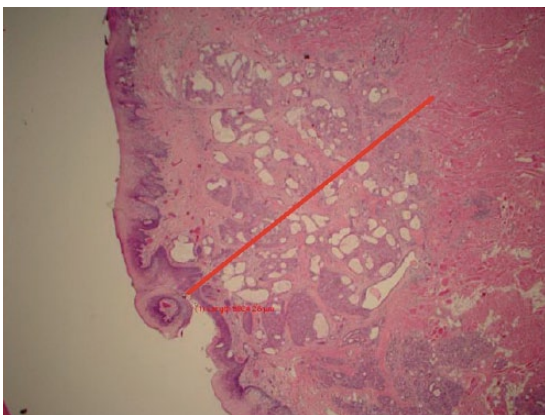




**Figure 1.** Neck soft tissue computed tomography showing a 2.2-cm hyperenhancing lesion with irregular margins arising from the left tongue base. White arrow points to the location of the lesion.



**Figure 2.** Photograph demonstrates recurrent tumors of the posterior left tongue at time of surgery. The thick red arrow indicates the atypical nodule visible on examination.



**Figure 3.** Section of the right posterior tongue lesion biopsy (hematoxylin-eosin). Submucosal mucous glands with extravasated mucin and few atypical glands suggestive of low-grade MEC. The thick line indicates the atypical area of interest. The magnification is x 200.

and CK 5/6 on immunoperoxidase staining. At postoperative follow-up, no nodule was palpable on clinical examination. A decision was made to serially evaluate the patient for potential recurrences of MEC. The patient is currently receiving chemotherapy and is not a candidate for radiation therapy as she had radiation in the past.

### Discussion

After a careful and thorough literature search, established guidelines for management and treatment of recurrent MECs of the tongue are lacking. Without a universally accepted treatment protocol, current clinical practice uses tumor grading to determine both prognosis and goals of care, necessitating a reliable tumor grading system. The Armed Forces Institute of Pathology developed a grading system to classify low-, intermediate-, or high-grade MEC based on histopathologic features.<sup>9</sup> This system uses the following histopathologic features: cystic components (0-2 points), perineural invasion (0-2 points), necrosis (0-3 points), mitotic activity (0-3 points), and anaplasia (0-4 points). A total of 0 to 4 points indicate low-grade MEC. These lesions are generally well circumscribed with a higher proportion of mucinous cells. Standard treatment is complete local excision with tumor-free margin. A total of 5 to 6 points are considered intermediate-grade MEC. In contrast to low-grade MEC, intermediate-grade tumors exhibit a more infiltrative pattern dominated by epidermoid anaplasia. The treatment, however, is the same for low-grade MEC consisting of wide local excision with nontumoral margins.<sup>8,10</sup> Seven or more points are indicative of high-grade MEC with more potential for malignant behavior. High-grade tumors tend to expand into surrounding structures with perineural invasion, lymphovascular invasion, and cellular atypia.<sup>11</sup> In addition to tumor-free margin surgical resection, treatment for high-grade MECs may include postoperative chemotherapy and/or radiation therapy.<sup>8,12</sup> There is no alternate standardized treatment protocol of recurrent MEC specific to the tongue.

In our case of recurrent tongue MECs, the biopsies from 2013 to 2016 exhibited no cytomorphic atypia or elevated mitotic activity. They were very similar in that they displayed mucous glands with extravasated mucin, few atypical glands, and a small focus of well-differentiated mucoepidermoid cells, consistent with histopathologic features of low-grade MECs. The biopsies were also positive for MEC-specific molecular markers—p63, CK 5/6, CK7, and EMA.<sup>13</sup> Yet, no study to date has correlated these molecular markers to tumor grade, rendering them with high diagnostic value but little prognostic significance. One notable exception is the fusion transcript of MAML-2 and MEC translocated gene-1 (MECT-1).<sup>14</sup> A recent study correlated MAML-2 and MECT-1 fusion to lower risk of local recurrence and metastasis and estimated median survival to be greater than 10 years compared with less than 2 years for fusion-negative patients.<sup>15</sup> Our patient's MEC

was positive for MAML-2 rearrangement on fluorescent in situ hybridization and had 2 recurrences of low-grade MECs within a 3-year span. Additional studies reviewed Ki-67 and p27Kip1 immunohistochemical stains, and multivariate survival analysis suggested that only p27Kip1 portended independent prognostic survival significance in MEC. Overexpression of Ki-67 was more frequently found in high-grade MEC but independently was not significantly associated with prognosis.<sup>16</sup> These stains were not ordered on our patient. It will be interesting to continue monitoring our patient longitudinally for possible recurrences and the associated tumor grade.

Also, the patient's extensive past medical history must be taken into account when considering our case of recurrent MECs. The patient had a history of primary ALK-positive lung adenocarcinoma with multiple metastases to the brain that was diagnosed in 2010. Afterward, the patient received 2 rounds of radiation therapy to the head and neck region, completed chemotherapy with alkaloid Navelbine from 2010 to 2012, had first MEC excision in 2013, and was on ALK inhibitor crizotinib from 2014 to the time of MEC recurrence identification in 2016. Even though both Navelbine and crizotinib have not been associated with MEC, the patient was switched from crizotinib to alectinib for continued treatment of her primary lung malignancy. How the patient's comorbidities and ongoing treatments for a separate cancer affect MECs clinical course remains to be seen.

The current standard for diagnosis of MEC is biopsy with histopathological grading, whereas the treatment for all grades of MECs is complete surgical resection.<sup>8-10</sup> High-grade MECs require possible postoperative chemotherapy or radiation therapy.<sup>8,12</sup> However, several questions remain unanswered in the diagnosis, management, and continued treatment of MECs: (1) What are the optimal surveillance intervals and methodology? (2) Do recurring low-grade MECs warrant chemotherapy and/or radiation therapy? (3) What are the benefits of postoperative chemoradiation therapy in recurring high-grade MECs? (4) How do different coexisting tumors affect clinical decisions on postoperative chemoradiation therapy? (5) Do other molecular or cytogenetic markers exist in conjunction with the MAML2-MECT1 assay that will improve the prognostic value and potentially direct clinical decisions on the optimal therapeutics for MECs and recurring MECs? (6) What are the implications of chronic chemotherapy use in development/recurrence of MECs? and (7) What are other predisposing risk factors for an individual to develop MECs?

The issue of managing recurrent MEC is well recognized.<sup>17,18</sup> Currently, there is an ongoing large phase 3 multicenter clinical trial evaluating the overall survival rates between postoperative chemotherapy and chemoradiation therapy for

intermediate- and high-grade MECs.<sup>19</sup> The aforementioned clinical questions are by no means comprehensive; nevertheless, they represent a subset of important inquiries that need to be addressed in a consensus guideline to fully evaluate, treat, and manage all grades of MECs.

## Conclusions

With multiple infiltration sites and diverse histopathological appearances, it is important to consider MEC in the differential and workup of chronic, atypical tongue lesions, especially in those with a history of radiation.<sup>10</sup> This patient's recurrent tongue nodules demonstrated the indeterminate pattern of MEC's presentation outside of the parotid gland. Given the high rates of mortality associated with MECs, early and accurate diagnosis, prompt interventions, and continued monitoring are paramount. After a thorough history and physical examination, tissue biopsy is advisable for tongue lesions suspicious for malignancy.<sup>20</sup> Follow-up imaging may be appropriate if no obvious lesion is visible and there are no symptoms including lymphadenopathy, palpable lesion, and/or persistent pain. Future areas of study include the relationship between MEC and lung tumors, particularly those that are ALK positive. We support the notion for further studies to develop an evidence-based guidelines for prognostic indicators and optimal clinical therapeutics for recurrent MECs.

## Acknowledgements

We would like to thank the Dr. Daniella Cocco for her editorial work to this case report.

## REFERENCES

1. Horner MJ, Ries LAG, Krapcho M, et al, eds. *SEER Cancer Statistics Review, 1975-2006*. Bethesda, MD: National Cancer Institute; 2009.
2. Agulnik M, McGann CF, Mittal BB, Gordon SC, Epstein JB. Management of salivary gland malignancies: current and developing therapies. *Oncol Rev*. 2008;2:86-94.
3. Williams JAD, Agrawal A, Wakely PE Jr. Mucoepidermoid carcinoma of the lacrimal sac. *Ann Diagn Pathol*. 2003;7:31-34.
4. Baloch ZW, Solomon AC, Livolsi VA. Primary mucoepidermoid carcinoma and sclerosing mucoepidermoid carcinoma with eosinophilia of the thyroid gland: a report of nine cases. *Mod Pathol*. 2000;13:802-807.
5. Dinopoulos A, Lagona E, Stinios I, Konstantinidou A, Kattamis C. Mucoepidermoid carcinoma of the bronchus. *Pediatr Hemat Oncol*. 2000;17:401-408.
6. Byrd SA, Spector ME, Carey TE, Bradford CR, McHugh JB. Predictors of recurrence and survival for head and neck mucoepidermoid carcinoma. *Otolaryngol Head Neck Surg*. 2013;149:402-408.
7. Triantafyllidou K, Dimitrakopoulos J, Iordanidis F, Koufogiannis D. Mucoepidermoid carcinoma of minor salivary glands: a clinical study of 16 cases and review of the literature. *Oral Dis*. 2006;12:364-370.
8. Brandwein MS, Ivanov K, Wallace DI, et al. Mucoepidermoid carcinoma: a clinicopathologic study of 80 patients with special reference to histological grading. *Am J Surg Pathol*. 2001;25:835-845.
9. Goode RK, Auclair PL, Ellis GL. Mucoepidermoid carcinoma of the major salivary glands: clinical and histopathologic analysis of 234 cases with evaluation of grading criteria. *Cancer*. 1998;82:1217-1224.
10. Ozawa H, Tomita T, Sakamoto K, et al. Mucoepidermoid carcinoma of the head and neck: clinical analysis of 43 patients. *Jpn J Clin Oncol*. 2008;38:414-418.

11. McHugh CH, Roberts DB, El-Naggar AK, et al. Prognostic factors in mucoepidermoid carcinoma of the salivary glands. *Cancer*. 2012;118:3928–3936.
12. Sobani ZA, Junaid M, Ghaffar S, Suhail A. Mucoepidermoid carcinoma of the base of tongue. *J Pak Med Assoc*. 2011;61:945–947.
13. Zhu S, Schuerch C, Hunt J. Review and updates of immunohistochemistry in selected salivary gland and head and neck tumors. *Arch Pathol Lab Med*. 2015;139:55–66.
14. Verdorfer I, Fehr A, Bullerdiek J, et al. Chromosomal imbalances, 11q21 rearrangement and MECT1-MAML2 fusion transcript in mucoepidermoid carcinomas of the salivary gland. *Oncol Rep*. 2009;22:305–311.
15. Behboudi A, Enlund F, Winnes M, et al. Molecular classification of mucoepidermoid carcinomas-prognostic significance of the MECT1-MAML2 fusion oncogene. *Genes Chromosomes Cancer*. 2006;45:470–481.
16. Miyabe S, Okabe M, Nagatsuka H, et al. Prognostic significance of p27<sup>Kip1</sup>, Ki-67, and *CRTC1-MAML2* fusion transcript in mucoepidermoid carcinoma: a molecular and clinicopathologic study of 101 cases. *J Oral Maxillofac Surg*. 2009;67:1432–1441.
17. Dai D. Postoperative irradiation in malignant tumors of submandibular gland. *Cancer Invest*. 1999;17:36–38.
18. Mücke T, Tannapfel A, Kesting MR, et al. Adenoid cystic carcinomas of minor salivary gland. *Auris Nasus Larynx*. 2010;37:615–620.
19. Cristina R, Adelstein DJ. RTOG 1008 protocol information: a randomized phase II/phase III study of adjuvant cocurrent radiation and chemotherapy versus radiation alone in resected high-risk malignant salivary gland tumors. <https://www.rtog.org/ClinicalTrials/ProtocolTable/StudyDetails.aspx?study=1008>. Accessed December 15, 2016.
20. Patton LL, Epstein JB, Kerr AR. Adjunctive techniques for oral cancer examination and lesion diagnosis: a systematic review of the literature. *J Am Dent Assoc*. 2008;139:896–905.