



Case Report

Comprehensive management of refractory autoimmune hemolytic anemia in pediatric beta-thalassemia major patient: A case report

Vincencius William, Desy Rusmawatingtyas^{*}, Firdian Makrufardi, Pudjo Hagung Widjajanto

Department of Child Health, Faculty of Medicine, Public Health and Nursing, Universitas Gadjah Mada/Dr. Sardjito Hospital, Yogyakarta, 55281, Indonesia



ARTICLE INFO

Keywords:

Thalassemia
Refractory AIHA
Cyclosporine
Leucodepleted PRC
Case report

ABSTRACT

Introduction: and importance: Autoimmune hemolytic anemia (AIHA) is characterized by the production of antibodies against the red blood cells (RBCs) leading to increased hemolysis. Incidence of AIHA in patients with beta-thalassemia major is 5 of 100 thalassemia patients.

Case presentation: A 15-year-old female patient with refractory AIHA and thalassemia was unresponsive to steroid therapy. In this report, she was treated with cyclosporine and prednisone in addition to leucodepleted packed red cell (PRC). She was successfully got remission during one-year monitoring.

Clinical discussion: Cyclosporine is an immunosuppressive agent that interferes with T-cells activation by inhibiting transcription of cytokines, such as interleukin 2 and interferon- γ . Cyclosporine and steroid have synergic effects to prevent antibody production. Nephrotoxicity is one of the most concerning effect in cyclosporine usage, but it rarely develops using doses lower than 5 mg/kgBW/day. In limited resources blood bank with ABO and Rh crossmatch only, leucodepleted PRC transfusion could be an effective way to prevent antibody formation to minor blood group.

Conclusion: Cyclosporine and steroid could be considered for management in refractory AIHA with thalassemia patients. Non-pharmacological therapy such as leucodepleted PRC transfusion and limited donor transfusion could be considered.

1. Introduction

Thalassemia is hemolytic anemia caused by the absence or reduced production of globin. The shortened lifespan of red blood cells of (RBC) makes patients with beta-thalassemia require repeated transfusions. However, several complications may occur, such as iron overload, transfusion reactions, infections, alloimmunization, and autoantibodies formation. Production of autoantibodies against the patient's RBCs leads to increased hemolysis called Autoimmune Hemolytic Anemia (AIHA). AIHA results in difficulty in cross-matching blood and shortening of the duration of RBC's survival requiring immunosuppressive therapy or splenectomy [1,2]. Risk factors for RBC alloimmunization are age, female gender, splenectomy, first transfusion before 2–3 years of age, and RBC units received/duration of blood transfusion/transfusion frequency. On the contrary, increased antigen matching for Rh and Kell and the use of leucodepleted RBC were found as protective factors [3].

In the general population, RBC autoantibodies occurred in 1.4%, against 6.5% in chronically or recurrent transfusion. In thalassemia, RBC

alloimmunization ranged from 2.9% to 37.0%. The incidence of AIHA in thalassemia beta major with recurrent transfusion is 5 per 100 patients [2]. Children with primary AIHA have a mortality rate of 4% [4].

First-line therapy for AIHA is corticosteroids; approximately 80% of patients responded at a dose equivalent to prednisolone 2 mg/kgBW/day. IVIg may be a useful rescue therapy; 54% of patients responded to doses of 0.4 to 2 g/kgBW/day for 2–5 days. The best-studied second-line therapy is rituximab, with 75–100% response rates in children with primary or secondary AIHA. Small series and case reports suggest that azathioprine, cyclosporine, and danazol may also have some activity in childhood AIHA [5]. One study reported 13 cases of pediatric AIHA, with 4 out of 13 cases who did not respond with first-line therapy, and 2 out of 4 using cyclosporine as the second-line therapy. One case showed no relapse during 10 months of follow-up, the other case showed 2 times of relapse during 2 years and 10 months follow-up [6]. Cyclosporine has been proven effective in some refractory immune hematological diseases such as AIHA, immune thrombocytopenic purpura (ITP), and Evans' syndrome in adults. However, there are only a limited number

^{*} Corresponding author.

E-mail addresses: vincencius.william@mail.ugm.ac.id (V. William), desy.rusmawatingtyas@ugm.ac.id, desy.rusmawatingtyas@ugm.ac.id (D. Rusmawatingtyas), firdianmakruf@gmail.com (F. Makrufardi), pudjo.hagung.w@ugm.ac.id (P.H. Widjajanto).

<https://doi.org/10.1016/j.amsu.2021.102853>

Received 6 August 2021; Received in revised form 9 September 2021; Accepted 10 September 2021

Available online 13 September 2021

2049-0801/© 2021 Published by Elsevier Ltd on behalf of IJS Publishing Group Ltd. This is an open access article under the CC BY license

(<http://creativecommons.org/licenses/by/4.0/>).

and inconsistent reports related to cyclosporine usage in children [7]. This case was reported in line with the Surgical CAse REport (SCARE) criteria [8].

1.1. Case presentation

A 15-year-old female patient with refractory AIHA and beta-thalassemia major was treated in our hospital. She has been diagnosed with thalassemia since 2009 from hemoglobin electrophoresis, with fetal hemoglobin (HbF) of 53.3% and alpha 2 hemoglobin (HbA2) of 46.7% (Fig. 1). She was given a packed red cell (PRC) transfusion once a month until 2017. Early in 2017, she had difficulty in cross-matching blood with more frequent transfusion needs; direct and indirect Coombs tests were positive. Treatment with high dose steroids using methylprednisolone 8 mg/kgBW/day was tapered to 1 mg/kgBW/day, and there were 3 episodes of relapse when using doses at 1 mg/kgBW/day. When a relapse occurred, the patient was treated using the similar therapy as before. IVIg could not be given to the patient due to financial problem that very common in our setting.

In the third relapse to our hospital, the physical examination of this patient appeared with pallor. Blood pressure was found to be 120/70 mm Hg. She had a regular pulse with a rate of 80 bpm. Moon face, as a side effect of long-term steroid usage, was observed. The results of lung and heart examinations were normal. In the abdominal examination, there was hepatosplenomegaly with abdominal striae. Bilateral legs striae were observed.

Hemoglobin level was 5.1 g/dL, hematocrite level was 15.5%, leukocyte was 6170/ μ L, platelet count was 195.000/ μ L, total bilirubin level was 3.74 mg/dL, direct bilirubin 1.11 mg/dL, direct Coombs test was +3, and indirect Coombs test was +1.

Treatment using cyclosporine and steroids for refractory AIHA was initiated. Cyclosporine treatment protocol was chosen rather than other second-line therapy due to the availability of this treatment. Regular leucodepleted PRC transfusion was scheduled, and an iron-chelating agent with deferoxamine was continued. Limited donor transfusion program was initiated.

Direct and indirect Coombs tests were negative after 10 days of cyclosporine therapy. Steroid and cyclosporine were tapered off and stopped after 6 weeks. Direct and indirect Coombs scores were reassessed, and the results were negative. Twelve months of follow-up showed remission of AIHA. Side effects of cyclosporine, steroids, and iron-chelating agents, such as nephrotoxicity, hepatotoxicity, endocrinology problem, hypertension, and abnormal glucose level, did not occur during follow-up.

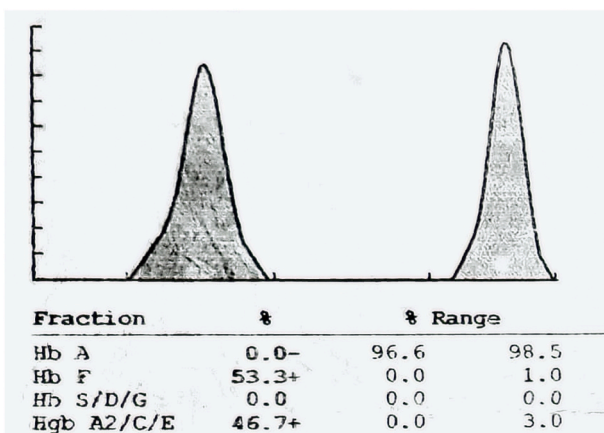


Fig. 1. Patient's hemoglobin electrophoresis result.

2. Discussion

We reported comprehensive management of a 15-year-old female with refractory AIHA and beta-thalassemia major treated with cyclosporine and prednisolone as pharmacological therapy in addition to leucodepleted PRC transfusion and limited donor transfusion as non-pharmacological therapy.

Cyclosporine is an immunosuppressive agent that interferes with T-cells activation by inhibiting the transcription of cytokines, such as interleukin 2 and interferon- γ . Cyclosporine and steroid have synergic effects to prevent antibody production. Nephrotoxicity is one of the most concerning effect in cyclosporine usage, but nephrotoxicity rarely develops using doses lower than 5 mg/kgBW/day [7]. Cyclosporine 2,5 mg/kgBW twice per day as second-line therapy for AIHA in adult patients shows 58% of response rate [9]. Our patient's cyclosporine dose was initially at 4 mg/kgBW/day, then tapered to 2 mg/kgBW/day and alternate dose, and finally the patient obtained a good response after 6 weeks of cyclosporine. During follow-up, the patient's direct Coombs test was still negative, and no sign of nephrotoxicity.

The best-studied second-line therapy is rituximab, with 75–100% response rates in children with primary or secondary AIHA. Small series and case reports suggest that azathioprine, danazol, and cyclosporine may also have some activity in childhood AIHA. Azathioprine 100–200 mg/day in adult population showed 60% of remission in refractory AIHA [5]. Danazol showed 58%–77% of remission in refractory AIHA [6]. However, our hospital did not have rituximab and danazol for patients' treatment. Cyclosporine has been proven effective in some refractory immune hematological diseases such as AIHA, immune thrombocytopenic purpura (ITP), and Evans' syndrome in adults. However, there was only a limited number and inconsistent reports related to cyclosporine usage in children [7].

A study reported 13 cases of pediatric AIHA, 4 out of 13 cases did not respond with first-line therapy, 2 out of 4 using cyclosporine as the second-line therapy. A case showed no relapse during 10 months follow up, the other case showed 2 times of relapse during 2 years and 10 months follow up [6].

Leucodepleted PRC is a protective factor for antibody production in recurrent transfusion. A study revealed that RBC antibody formation in the leucodepleted group was 0.3% compared to a range from 2.9% to 37% in the non-leucodepleted group [10]. In blood banks with limited resources with ABO and Rh crossmatch only, leucodepleted PRC transfusion could be an effective way to prevent antibody formation to minor blood group [11].

Some studies stated that patients may benefit from receiving RBC transfusions based on extended crossmatch for prevention of RBC antibody formation [12–14]. Molecular matching is more promising to prevent antibody formation than serological matching, despite the cost of molecular matching being higher than serological matching [13]. Grouping of limited donors with extended crossmatch will be beneficial to patient with recurrent transfusion. Previous study revealed that thalassemia patient with limited donor transfusion between 3 and 5 donors showed lower frequency (8.3% vs. 21.6%) of antibody formation compared to non-limited donor transfusion [14].

There are some limitations in this report. First, we did not classify the type of AIHA, either warm or cold autoantibody type. Confirmation of warm or cold autoantibody type is not a protocol in our tertiary hospital, and patients will treat with the same protocol. Second, IVIg as first line therapy in patient with AIHA had not been given. Both of limitations due to the limited coverage of health insurance and patient can not afford because of financial problems. These are common problems in developing country that may affect patients outcome. In contrast to the situation in developed countries, in developing country settings such as Indonesia, physicians are often faced with conditions where the drug of choice for a disease is not available. With these limitations, we combine pharmacological and non-pharmacological for long-term management of patients.

3. Conclusions

Cyclosporine and steroids could be considered for management in refractory AIHA with thalassemia patients. Non-pharmacological therapy such as leucodepleted PRC transfusion and limited donor transfusion could also be considered.

Consent

Written informed consent was obtained from the patient's parents for publication of this case report and accompanying images. A copy of the written consent forms is available for review by the Editor-in-Chief of this journal on request.

Declaration of competing interest

No potential conflict of interest relevant to this article was reported.

Acknowledgment

We want to thank all collaborators and medical staff in the patient care.

Appendix A. Supplementary data

Supplementary data to this article can be found online at <https://doi.org/10.1016/j.amsu.2021.102853>.

Funding source

This research did not receive any specific grant from funding agencies in the public, commercial, or not-for-profit sectors.

Provenance and peer review

Not commissioned, externally peer-reviewed.

Ethical approval

The informed consent form was declared that patient data or samples will be used for educational or research purposes. Our institutional review board also do not provide an ethical approval in the form of case report.

Sources of funding

The authors declare that this study had no funding source.

Author contribution

Vincencius William, Desy Rusmawatingtyas, Pudjo Hagung Widjajanto conceived the study and approved the final draft. Vincencius William, Desy Rusmawatingtyas, Firdian Makrufardi, Pudjo Hagung Widjajanto drafted the manuscript, and critically revised the manuscript for important intellectual content. Vincencius William, Desy Rusmawatingtyas, Firdian Makrufardi, Pudjo Hagung Widjajanto facilitated all project-related tasks.

Conflicts of interest

No potential conflict of interest relevant to this article was reported.

Registration of research studies

This is not a 'first in humans' report, so it is not in need of registration.

Guarantor

Desy Rusmawatingtyas.

Consent

Written informed consent was obtained from the patient for publication of this case report and accompanying images. A copy of the written consent is available for review by the Editor-in-Chief of this journal on request.

References

- [1] L. Xu, J. Fang, W. Weng, K. Huang, Y. Zhang, Autoimmune hemolytic anemia in patients with β -thalassemia major, *Pediatr. Hematol. Oncol.* 107 (2012) 235–240.
- [2] M.B. Khaled, M. Ouederni, N. Sahli, N. Dhouib, A.B. Abdelaziz, S. Rekaya, R. Kouki, H. Kaabi, H. Slama, F. Mellouli, M. Bejaoui, Predictors of autoimmune hemolytic anemia in beta-thalassemia patients with underlying red blood cells autoantibodies, *Blood Cells Mol. Dis.* 79 (2019) 102342, <https://doi.org/10.1016/j.bcmd.2019.102342>.
- [3] M. Franchini, G.L. Forni, G. Marano, M. Cruciani, C. Mengoli, V. Pinto, L. De Franceschi, D. Venturelli, M. Casale, M. Amerini, M. Capuzzo, G. Grazzini, F. Masiello, I. Pati, E. Veropalumbo, S. Vaglio, S. Pupella, G.M. Liunbruno, Red blood cell alloimmunisation in transfusion-dependent thalassaemia: a systematic review, *Blood Transfus* 17 (1) (2019) 4–15, <https://doi.org/10.2450/2019.0229-18>.
- [4] N. Aladjidi, G. Leverger, T. Leblanc, M.Q. Picat, G. Michel, Y. Bertrand, B. Bader-Meunier, A. Robert, B. Nelken, V. Gandemer, H. Savel, J.L. Stephan, F. Fouyssac, J. Jeanpetit, C. Thomas, P. Rohrllich, A. Baruchel, A. Fischer, G. Chène, Y. Perel, Centre de Référence National des Cytopenies Auto-immunes de l'Enfant (CEREVANCE), New insights into childhood autoimmune hemolytic anemia: a French national observational study of 265 children, *Haematologica* 96 (5) (2011) 655–663, <https://doi.org/10.3324/haematol.2010.036053>.
- [5] Q.A. Hill, R. Stamps, E. Massey, J.D. Grainger, D. Provan, A. Hill, British Society for Haematology, The diagnosis and management of primary autoimmune haemolytic anaemia, *Br. J. Haematol.* 176 (3) (2017 Feb) 395–411, <https://doi.org/10.1111/bjh.14478>.
- [6] M. Weli, A. Ben Hlima, R. Belhadj, B. Maalej, A. Elleuch, N. Mekki, L. Gargouri, T. Kamoun, M.R. Barbouche, A. Mahfoudh, Diagnosis and management of autoimmune hemolytic anemia in children, *Transfus. Clin. Biol.* 27 (2) (2020) 61–64, <https://doi.org/10.1016/j.tracli.2020.03.003>.
- [7] N. Yarali, T. Figgin, A. Kara, F. Duru, Successful management of severe chronic autoimmune hemolytic anemia with low dose cyclosporine and prednisone in an infant, *Turk. J. Pediatr.* 45 (4) (2003 Oct-Dec) 335–337.
- [8] R.A. Agha, T. Franchi, C. Sohrabi, G. Mathew, A. Kerwan, SCARE Group, The SCARE 2020 guideline: updating consensus surgical CAse REport (SCARE) guidelines, *Int. J. Surg.* (2020 Nov 9), <https://doi.org/10.1016/j.ijssu.2020.10.034>. S1743–S9191.
- [9] U. Jäger, W. Barcellini, C.M. Broome, M.A. Gertz, A. Hill, Q.A. Hill, B. Jilma, D. J. Kuter, M. Michel, M. Montillo, A. Röth, S.S. Zeerleder, S. Berentsen, Diagnosis and treatment of autoimmune hemolytic anemia in adults: recommendations from the first international consensus meeting, *Blood Rev.* 41 (2020 May) 100648, <https://doi.org/10.1016/j.blre.2019.100648>.
- [10] S. Mangwana, A. Kacker, N. Simon, Red cell alloimmunization in multi-transfused, oncology patients: risks and management, *Glob. J. Transfus. Med.* 4 (1) (2019) 74, https://doi.org/10.4103/GJTM.GJTM_11_19.
- [11] A. Handa, N. Kukar, R.N. Maharishi, N. Syal, H. Arora, Analysis of red cell alloimmunization in multi transfused patients at a Tertiary care teaching hospital, *J. Fam. Med. Prim. Care* 9 (6) (2020) 2907–2911, <https://doi.org/10.4103/jfmpc.jfmpc.351.20>.
- [12] S.F. Jalali, A. Oodi, A. Azarkeivan, S. Gudarzi, N. Amirizadeh, Kidd blood group genotyping for thalassemia patient in Iran, *Indian J. Hematol. Blood Transfus.* 36 (3) (2020) 550–555, <https://doi.org/10.1007/s12288-020-01283-y>.
- [13] A. Belsito, D. Costa, S. Signoriello, C. Fiorito, I. Tartaglione, M. Casale, S. Perrotta, K. Magnussen, C. Napoli, Clinical outcome of transfusions with extended red blood cell matching in β -thalassemia patients: a single-center experience, *Transfus. Apher. Sci.* 58 (1) (2019) 65–71, <https://doi.org/10.1016/j.transci.2018.11.006>.
- [14] A.S. el-Danasoury, D.G. Eissa, R.M. Abdo, M.S. Elalfy, Red blood cell alloimmunization in transfusion-dependent Egyptian patients with thalassemia in a limited donor exposure program, *Transfusion* 52 (1) (2012 Jan) 43–47, <https://doi.org/10.1111/j.1537-2995.2011.03234.x>.