



Biportal endoscopic surgery for lumbar spine herniated discs: a narrative review of its clinical application and outcomes

Wireko A. Awuah, MBBS^{a,*}, Favour T. Adebusoye, MBBS^a, Yasir Alshareefy, MBBS^b, Jyi Cheng Ng, MD^c, Amanda L. Tomas Ferreira, MBChB, MPhil^d, Amanda L. Abdus Salam, MBBS^e, Amanda L. Shankhaneel Ghosh, MBBS^f, Amanda L. Weng Yee, MBBS^g, Adele Mazzoleni, MBBS^h, Jack Wellington, MScⁱ, Ebtessam Toufik Abdul-Rahman, MBBS^a, Ebtessam Abdulla, B.Med.Sc., MD^j

Abstract

Lumbar disk herniation (LDH) is a common condition affecting millions worldwide. The management of LDH has evolved over the years, with the development of newer surgical techniques that aim to provide better outcomes with minimal invasiveness. One promising emerging technique is biportal endoscopic spinal surgery (BESS), which utilizes specialized endoscopic equipment to treat LDH through two small incisions. This review aims to assess the effectiveness of BESS as a management option for LDH by analyzing the available literature on surgical outcomes and potential complications associated with the technique. Our review shows that BESS is associated with favorable postoperative results as judged by clinical scoring systems, such as visual analog scale, Oswestry disability index, and MacNab criteria. BESS has several advantages over traditional open surgery, including minimized blood loss, a shorter duration of hospitalization, and an expedited healing process. However, the technique has limitations, such as a steep learning curve and practical challenges for surgeons. Our review offers recommendations for the optimal use of BESS in clinical practice, and provides a foundation for future research and development in this field, aiming to improve patient outcomes and quality of life.

Keywords: Biportal Endoscopy, Lumbar Disk Herniation, Spine Surgery

Introduction

Lumbar disk herniation (LDH) is a common condition that affects a considerable number of individuals worldwide. It is characterized by the displacement of disk material outside of the intervertebral space, resulting in compression of the spinal cord and its nerves^[1]. This condition affects 5 to 20 cases per 1000

^aSumy State University, Sumy, Ukraine, ^bSchool of Medicine, Trinity College Dublin, Ireland, ^cUniversity of Malaya, Kuala Lumpur, Malaysia, ^dDepartment of Clinical Neurosciences, School of Clinical Medicine, University of Cambridge, Cambridge, UK, ^eDepartment of Surgery, Khyber Teaching Hospital, Peshawar, Pakistan, ^fInstitute of Medical Sciences and SUM Hospital, Siksha 'O' Anusandhan, Bhubaneswar, India, ^gFaculty of Medicine and Health Sciences, University of Putra Malaysia, Serdang, Malaysia, ^hBarts and the London School of Medicine and Dentistry, ⁱCardiff University School of Medicine, Cardiff University, Wales, UK and ^jDepartment of Neurosurgery, Salmaniya Medical Complex, Manama, Bahrain

Sponsorships or competing interests that may be relevant to content are disclosed at the end of this article.

*Corresponding author. Address: Faculty of Medicine, Sumy State University, Sanatorna Street, 31, Sumy, Sumy Oblast 40000, Ukraine. Tel./fax +380 639 759 910. E-mail: Favouadebusoye@gmail.com (F.T. Adebusoye).

Copyright © 2023 The Author(s). Published by Wolters Kluwer Health, Inc. This is an open access article distributed under the terms of the Creative Commons Attribution-Non Commercial-No Derivatives License 4.0 (CCBY-NC-ND), where it is permissible to download and share the work provided it is properly cited. The work cannot be changed in any way or used commercially without permission from the journal.

Annals of Medicine & Surgery (2023) 85:3965–3973

Received 6 April 2023; Accepted 1 July 2023

Published online 7 July 2023

<http://dx.doi.org/10.1097/MS9.0000000000001053>

HIGHLIGHTS

- Biportal endoscopic spinal surgery (BESS) has emerged as a less invasive alternative for the treatment of lumbar disk herniation.
- The use of BESS in lumbar disk herniation treatment has yielded positive postoperative outcomes, as indicated by clinical scoring systems such as visual analog scale, Oswestry disability index, and MacNab criteria. These criteria demonstrate notable improvements compared to preoperative scores.
- However, BESS does have limitations, including a steep learning curve for surgeons and practical challenges during the procedure. Surgeons should consider these limitations and carefully evaluate the benefits of BESS against other available treatment options based on patient needs.

individuals, with a higher occurrence observed during the third and fifth decades of life, and is more common in males^[2]. The etiology of LDH is primarily attributed to degenerative changes associated with spinal aging, and risk factors include smoking, obesity, diabetes mellitus, and occupations involving heavy lifting^[3]. Symptoms of LDH typically manifest as radicular and lower back pain accompanied by sensory deficits, which vary depending on the anatomical location of the herniation^[4]. Sciatica, a severe complication of LDH, accounts for 90% of cases of radicular pain throughout the sciatic nerve's dermatomal distribution^[5]. The diagnosis of LDH requires a multimodal

approach, with MRI serving as the gold-standard imaging modality^[6]. While the majority of individuals with LDH experience transient symptoms that resolve within 2 months, surgical intervention becomes a last resort for patients enduring persistent and incapacitating symptoms^[4,7].

In recent years, the management of lumbar spine herniated disks has witnessed significant progress, marked by the emergence of novel surgical techniques aiming to achieve superior outcomes with minimal invasiveness. One such technique is biportal endoscopic spinal surgery (BESS), which involves the use of two small incisions and specialized endoscopic equipment to access and treat the herniated disk^[8]. It is important to emphasize that BESS is not a standalone procedure but rather a category encompassing various specialized techniques, including biportal endoscopic discectomy, recurrent lumbar disk herniation, biportal endoscopic revision lumbar discectomy, and unilateral biportal endoscopic discectomy. Furthermore, indications for BESS include LDH, foraminal stenosis, lumbar spinal stenosis, facet joint syndrome, and epidural adhesions, while contraindications may include severe spinal instability, inadequate visualization, multilevel disease, significant medical comorbidities, and surgical inexperience^[4,7,8].

BESS presents several advantages over traditional open surgery, including mitigated intraoperative bleeding, a lesser duration of hospital confinement, and a shortened recovery period^[8]. However, as a technique that is still evolving, it is important to fully understand its outcomes and limitations. This review aims to assess the role of BESS as a viable management option for lumbar spine herniated disks. Through an analysis of the existing literature on surgical outcomes and potential complications associated with BESS and by comparing it to other surgical methods for this condition, we aim to provide readers with a comprehensive understanding of the advantages and disadvantages of BESS. Furthermore, we aim to offer recommendations for the effective implementation of BESS in clinical practice. Given the increasing demand for minimally invasive surgical options and the growing availability of endoscopic equipment and training programs, BESS has the potential to become a widely adopted technique for the treatment of herniated disks in the lumbar spine. By providing a foundation for future research and development in this field, our paper aims to improve patient outcomes and quality of life.

Methodology

A narrative review was conducted to evaluate the role of BESS as a management option for LDH. A comprehensive search was performed across multiple electronic databases, including PubMed, MEDLINE, and the Cochrane Library, using the keywords ‘biportal endoscopy’, ‘spine surgery’, and ‘lumbar disk herniation’.

Eligible articles were selected based on inclusion criteria, which encompassed case series, retrospective and prospective cohort studies, and randomized controlled trials (RCTs). Only articles published in the English language were considered. Studies focusing on the surgical outcomes and potential complications associated with BESS in the treatment of LDH were included, while those concentrating on the use of BESS for other spinal conditions, as well as reviews and non-English studies, were excluded.

To ensure the reliability and consistency of article selection, two independent reviewers (A.S. and F.T.A.) performed the initial screening for eligibility. Any disagreements were resolved independently by a third reviewer (W.A.A.). Data extraction was carried out from the selected articles, encompassing study type, disease or population, positive findings, and complications associated with BESS. A descriptive approach was employed to analyze the data, which were presented using tables and figures. Common themes and trends identified in the literature were summarized in narrative form. This methodology allowed for a comprehensive evaluation of the existing literature on the surgical outcomes and potential complications associated with BESS in the treatment of LDH, providing valuable insights and synthesizing the findings to guide clinical decision-making.

Results

Study and population characteristics

A total of 14 articles that met the inclusion criteria were analyzed for study characteristics, patient demographics, positive findings, and complications associated with BESS in the treatment of LDH. Among these studies, there were 12 retrospective and prospective cohort studies, along with one technical note and one RCT. It is important to note that the majority of the included studies originated from Korea or China, reflecting the geographical areas where the technique has primarily been implemented thus far. The study populations exhibited variations in terms of sample size, age distribution, and sex representation, ranging from small case series to larger cohort studies.

Outcomes and complications of BESS in treating LDH

Positive outcomes

Several scoring systems exist for the objective evaluation of symptom improvement following surgery. The visual analog scale (VAS), Oswestry disability index (ODI), and modified MacNab criteria are among the most commonly employed scoring systems (results summarized in Table 1).

Visual Analog Scale (VAS) Improvement: The VAS is a widely recognized pain scoring system used for the assessment of subjective acute and chronic pain, allowing for the measurement of pain progression and treatment outcomes^[22]. A decrease in VAS scores indicates a reduction in pain intensity. The reviewed studies consistently demonstrated a decrease in VAS scores. Kang *et al.*^[13] reported significant postoperative improvement in VAS scores and high satisfaction rates. Ahn *et al.*^[10] observed a decrease in VAS scores specifically for radicular leg pain. In addition, Zuo *et al.*^[19] demonstrated significant improvement in VAS scores for both back pain and leg pain in the UBE/BESS group. Furthermore, several other studies^[8,11,12,15,16,18,20] also reported significant improvements in VAS scores, indicating successful pain management. Overall, the consistent decrease in VAS scores across these studies suggests an effective reduction in pain intensity.

Oswestry Disability Index (ODI) Improvement: The ODI scoring system is a valuable tool for assessing disability and measuring treatment outcomes and functional progression in patients with back pain^[23]. A decreased ODI score signifies improved functional ability and reduced disability. Notably, Park *et al.* (2023) demonstrated positive ODI scores at 12 months

Table 1
Recent studies on biportal endoscopic surgery for lumbar spine herniated disks: populations, findings, and complications.

References	Study type	Sample size	Positive findings	Complications
Eun <i>et al.</i> , ^[8]	Technical note	28 patients	VAS of the leg and ODI scores improved significantly VAS score of the legs Preoperative: 7.875 ± 1.24 Postoperative: 0.87 ± 0.64 ODI Preoperative: 51.73 ± 18.57 Postoperative: 63.27 ± 7.67	No complications were recorded
Choi <i>et al.</i> , ^[9]	Prospective study	80 patients	Postoperative VAS and ODI of UBED were similar with MD, PEID and PELD	No complications were recorded
Ahn <i>et al.</i> , ^[10]	Retrospective study	88 patients	The mean VAS score of radicular leg pain had decreased from 6.5 ± 1.7 preoperatively to 4.4 ± 1.4 at final follow-up Modified MacNab criteria was fair in 81 patients while poor in 7 patients	No complications were recorded
Foocharoe ^[11]	Retrospective study	51 patients	VAS and ODI scores improved significantly in both left-sided and right-sided BESS; MacNab score was excellent or good in 96% of the patients Both In left-sided BESS patients: VAS score of the back Preoperative: 6.3 ± 2.6 Postoperative: 2.1 ± 1.9 . VAS score of the leg Preoperative: 8.4 ± 1.3 6-month postop: 2.2 ± 1.9 iii. ODI Preoperative: 74.4 ± 10.3 6-month postop: 18.7 ± 13.5 In right-sided BESS patients: i. VAS score of the back Preoperative: 5.2 ± 3.1 Postoperative: 1.9 ± 1.1 ii. VAS score of the leg Preoperative: $.7 \pm 1.0$ 6-month postop: 1.8 ± 1.2 . ODI Preoperative: 76.5 ± 13.5 6-month postop: 12.7 ± 8.2	Two out of 20 patients (6.5%) had complications in left-sided BESS group (1 immediate postoperative epidural hematoma and 1 inadequate disk removal, both underwent revision surgery). Three out of 31 patients (15%) had complications in right-sided BESS group (1 converted to open surgery because the visual field was obscured by bleeding, and 2 had wrong level surgery that needed portal extensions)
Heo <i>et al.</i> , ^[12]	Retrospective study	11 patients	Postoperative MRI revealed optimal nerve root decompression in all patients VAS score of the legs Preoperative: 8.4 ± 1.1 Postoperative: 2.8 ± 1.4 ODI Preoperative: 60.2 ± 5.5 Postoperative: 22.1 ± 3.4 MacNab score was excellent or good in 10 patients (71.4%), fair in 3 patients (21.4%) and poor in 1 patient (7%)	Out of the 2 patients (14%) who experienced abdominal pain, 1 patient (7%) had perirenal fluid collection
Kang <i>et al.</i> , ^[13]	Retrospective study	36 patients	VAS significantly improved postoperatively Modified MacNab criteria: Excellent or good satisfaction rates of BE-RLD; 2 weeks 81.25%, 6 weeks 81.25%, 6 months 75%, 12 months 81.25% Length of hospital stay was significantly shorter in patients treated with BE-RLD compared to OM-RLD, peak serum CRP and CPK values were significantly lower compared to OM-RLD	Out of 16 patients, 1 (6.3%) had incidental durotomy, and 2 (12.5%) had persistent leg dysesthesia
Kang <i>et al.</i> , ^[14]	Retrospective study	262 patients	Clinical outcomes (ODI, VAS, and modified Macnab criteria) and operation time were similar between high-grade migration group and low-grade migration group treated with BED	i. 1 out of 208 patients (0.5%) in the low-migration group experienced a hematoma, and 3 out of 54 patients (5.6%) in the high-migration group had to undergo revision surgeries ii. Concerns were described regarding the high levels of irrigation needed and the possible risks of increased intracranial pressure

Table 1

(Continued)

References	Study type	Sample size	Positive findings	Complications
Hao <i>et al.</i> , ^[15]	Retrospective study	50 patients	MacNab score was excellent or good in 90% of the patients VAS score of the back Preoperative: 7.32 ± 0.82 6-month postop: 1.51 ± 0.32 VAS score of the leg Preoperative: 7.05 ± 0.59 6-month postop: 1.12 ± 0.33 ODI Preoperative: 71.52 ± 3.68 6-month postop: 11.65 ± 1.26	One patient (5%) had CSF leakage and one patient (5%) experienced a headache postoperatively
Jiang <i>et al.</i> , ^[16]	Retrospective study	54 patients	VAS score and ODI decreased significantly in the UBE group VAS score of the back Preoperative: 5.75 ± 0.99 6-month postop: 0.46 ± 0.66 VAS score of the leg Preoperative: 7.04 ± 2.12 6-month postop: 0.67 ± 1.34 ODI Preoperative: 62.25 ± 13.57 6-month postop: 6.50 ± 9.08	One out of 24 patients (4%) incurred a dural tear
Park <i>et al.</i> , ^[17]	Retrospective study	360 patients	MacNab score was excellent or good in 83.33% of the patients ODI, EQ-5D and VAS for low back pain and radiating leg pain significantly decreased with time up to 12 months after surgery	Out of 115 patients, 4 (3.5%) had incidental durotomy, 3 (2.6%) had facet injury, 1 (0.9%) had surgery on the wrong level
Yuan <i>et al.</i> , ^[18]	Retrospective study	50 patients	VAS score significantly improved Preoperative: 7.02 ± 0.35 Postoperative: 1.05 ± 0.54	Two out of 22 patients (9.1%) had CSF leakage
Zuo <i>et al.</i> , ^[19]	Retrospective study	92 patients	VAS and ODI scores improved significantly in UBE/BESS group ii. VAS score of the back Preoperative: 3.95 ± 3.00 1-year postop: 0.29 ± 0.46 iii. VAS score of the leg Preoperative: 8.14 ± 1.26 1-year postop: 0.43 ± 0.59 iv. ODI Preoperative: 66.07 ± 13.48 1-year postop: 4.98 ± 3.11	One out of 42 patients (2%) incurred a dural tear
Park <i>et al.</i> , ^[20]	Randomized control trial	32 patients	Primary outcome of the ODI score at 12 months post-op; i. PROM: no significant difference ii. VAS: pain for back pain: preoperatively 4 postoperatively 1-year later 2.43 +/- 1.57 iii. ODI: 13.89 (+/-9.25) in BESS groups	a. Complications during surgery: In the microscopy group, 2 patients experienced incidental durotomy, 1 facet injury, and 7 incomplete discectomy In the BESS group: 5 experienced facet injury, 1 had a wrong site surgery, and 4 incomplete discectomies b. Complications at 1-year follow-up: Microscopy group: 14 asymptomatic hematomas, 4 wound dehiscence, 1 surgical site infection, 4 recurrences of herniation, 1 neurologic deterioration BESS group: 7 asymptomatic hematomas, 7 recurrences of herniation, 1 neurologic deterioration

Table 1**(Continued)**

References	Study type	Sample size	Positive findings	Complications
Wang <i>et al.</i> ^[21]	Observational study	70 patients	<p>Postop MRI showed sufficient decompression of nerve root and preservation of the ligamentum flavum in all 70 patients</p> <p>Lower back and leg pain were significantly relieved postoperatively</p> <p>Postoperative ODI showed significant improvement as compared to preoperative ODI</p> <p>After a 2-year follow-up, muscle strength and sensory of nerve roots showed significant recovery</p> <p>MacNab score was excellent or good in 66 patients, fair in two patients and poor in two patients</p>	No complications were recorded

BED, biportal endoscopic discectomy; BE-RLD, biportal endoscopic revisional lumbar discectomy; CSF, cerebrospinal fluid; CPK, creatine phosphokinase; CRP, C-reactive protein; EQ-5D, euroQol five-dimension scale questionnaire; LSCS, lumbar spinal canal stenosis; LDH, lumbar disk herniation; LSS, lumbar spinal stenosis; MD, microdiscectomy; ODI, Oswestry disability index; OM-RLD, open microscopic revisional lumbar discectomy; PELD, percutaneous endoscopic lumbar discectomy; PEID, percutaneous endoscopic interlaminar discectomy; Postop, postoperative; PROM, patient recorded outcome measure; RLDH, recurrent lumbar disk herniation; UBED, unilateral biportal endoscopic discectomy; VAS, visual analog scale.

postoperation, while Jiang *et al.* (2022) reported a significant reduction in ODI scores in the UBE group at 6 months postoperative^[16,20]. Foocharoen (2020) also documented significant improvements in ODI scores for both left-sided and right-sided BESS patients, indicating enhanced functional ability and decreased disability^[11].

Furthermore, Wang *et al.*^[21] observed significant postoperative ODI improvement alongside the recovery of muscle strength and sensory function of nerve roots. Similarly, Zuo *et al.*^[19] demonstrated substantial improvement in ODI scores for the UBE/BESS group before and one year after surgery. Moreover, consistent findings across additional studies^[8,9,12,14,15,17] consistently revealed significant improvements in ODI scores following various treatments. These findings collectively underscore the effectiveness of the evaluated interventions in producing significant improvements in ODI scores.

MacNab criteria improvement: The modified MacNab criteria are commonly used to evaluate patient satisfaction and well-being following surgery, allowing patients to rate their satisfaction on a scale ranging from 'excellent' to 'poor'^[23]. Several studies have reported positive outcomes based on the modified MacNab criteria in patients who underwent spinal surgery.

Kang *et al.*^[13] found that patients who underwent bilateral endoscopic discectomy had excellent or good outcomes. Similarly, Wang *et al.* (2023) and Jiang *et al.* (2022) observed favorable MacNab scores following surgical interventions^[16,21]. Additionally, Foocharoen (2020) reported high MacNab scores in patients who underwent BESS^[11]. These findings collectively suggest positive patient experiences and outcomes associated with these surgical approaches.

Complications

Complications associated with BESS procedures can vary in nature and impact patients. One category of complications involves hematoma, which refers to the accumulation of blood outside blood vessels. In a study by Kang *et al.*^[14], hematoma was reported in the high-migration group, suggesting a higher susceptibility to this complication in this subgroup. Furthermore, Foocharoen *et al.* (2020) found instances of immediate postoperative epidural hematoma specifically in the left-sided BESS group, indicating a potential influence of the procedure's location on hematoma formation^[14].

Another commonly reported complication is incidental durotomy, an unintended tear in the protective dural covering of the spinal cord. Both Kang *et al.* (2020) and Park *et al.* (2022) observed incidental durotomy as a potential complication, emphasizing the associated risks and the need for meticulous surgical techniques^[14,17].

Persistent leg dysesthesia, characterized by abnormal sensations in the legs, was identified as a complication in the study by Kang *et al.*^[14]. This finding highlights the potential adverse effects of spinal endoscopy procedures.

Poor outcomes following the procedure were also reported by Ahn *et al.*^[10], indicating variability in postoperative results. This suggests the importance of careful monitoring and individualized care to optimize patient outcomes.

Other complications associated with spinal endoscopy procedures include dural tear, cerebrospinal fluid leakage, postoperative headaches, abdominal pain, perirenal fluid collection, facet injury, surgery on the wrong level, as well as various postoperative complications such as asymptomatic hematoma, wound dehiscence, surgical site infection, recurrences, and neurologic deterioration. These complications were reported in studies by Jiang *et al.* (2022), Hao *et al.* (2022), Yuan *et al.* (2022), and Heo *et al.* (2020)^[12,15,16,18]. These findings underscore the importance of accurate surgical planning, meticulous execution, and long-term monitoring and follow-up care to mitigate potential complications and ensure optimal patient outcomes. Revision surgeries were also found to be necessary in some patients from the high-migration group, as indicated by Kang *et al.*^[14]. This finding emphasizes the importance of additional surgical interventions to address complications that may arise after the initial procedure (results summarized in Table 1).

Discussion

Advantages of biportal technique over conventional methods

The BESS group demonstrated superior clinical outcomes compared to the single-channel interforaminal endoscopic group in terms of postoperative residual nucleus pulposus and recurrence rates^[18]. Furthermore, the procedure exhibited prolonged outcomes, highlighting its effectiveness in removing problematic tissue^[18]. BESS also offers a wider field of view, which is vital for

ensuring surgical precision and accuracy. Foocharoen^[11] successfully demonstrated the enhanced visibility and surgical site access provided by BESS, reporting higher success rates in decompression surgeries compared to traditional open lumbar discectomy methods.

In recent years, BESS has emerged as a practical alternative to conventional methods for managing early postoperative pain. A randomized controlled experiment conducted by Park *et al.* provides further evidence of the benefits of BESS, indicating that patients who underwent BESS experienced marginally less severe early surgical site pain compared to those who underwent traditional microscopic decompression (MD) techniques^[20]. In comparison to open MD, BESS offers several advantages, including mitigated excessive blood loss, shortened inpatient stay, and a lower incidence of early postoperative back pain^[9]. Additionally, the technique demonstrates superior outcomes in pain management, functional impairment, and patient satisfaction. Choi *et al.* observed significantly higher levels of back pain on postoperative days 1 and 3 in patients who received MD compared to those who underwent BESS^[9]. Furthermore, Foocharoen^[11] reported immediate-term follow-up advantages and reduced postoperative complications associated with the application of the BESS technique.

In summary, the BESS technique demonstrates superior outcomes, lower recurrence rates, a broader field of view, and increased precision and accuracy compared to single-channel procedures. BESS demonstrates advantages such as controlled intraoperative blood loss, improved early postoperative pain management, decreased length of hospitalization, and improved patient satisfaction.

Considerations of the optimal field of view in BESS procedures

To provide an optimal field of view, particular attention must be paid to the location of the endoscope tip. It has been suggested that a right-handed individual performing the procedure may be more accustomed to achieving superlative proficiency^[24].

Additionally, the surgical approach and location of the operative site are dependent on the positioning of the surgeon's hands, where said adjustment may need altering. A surgeon implementing a right-sided technique would need to utilize both hands, one for instrumentation and the other for scoping, and swap sides at some point to improve their field of vision. Moreover, due to anatomical variations and the necessity to determine the proper angle, the instruments in a right-sided approach must be positioned differently from those in a left-sided approach^[25].

A dearth of evidence within the current literature makes it difficult to determine whether a surgeon who operates with their right or left hand would feel and complete the procedure wholly with comfort and ease. Even so, during most of the procedure, when applying a right-handed technique, the instrument is often held in the right hand and the scope in the left^[25]. However, the field of vision and the mobility acquired with BESS procedures seem, thus far, suitable to suppose that the field of vision achieved is comfortable enough for surgeons to undertake the surgery. Forceful measures may result in postoperative problems.

Difficulties of the biportal technique compared to conventional methods

However, despite recent studies demonstrating the favorable outcomes of biportal endoscopic treatment, it is essential to emphasize that this technique still has limitations. The existence of a steep learning curve associated with BESS has been identified as a significant hindrance in various studies^[10,26].

In addition to the steep learning curve, BESS also presents practical difficulties for surgeons during the procedure. For instance, due to the nature of the technique, the surgeon must hold the endoscope with one hand while simultaneously handling the surgical instrument with the other, potentially requiring additional assistance, resulting in increased costs and prolonged processing times^[26]. Right-handed surgeons may encounter additional challenges when performing the treatment from the right side since the working portal is located on their nondominant hand, potentially leading to prolonged intraoperative time, greater blood loss, or an elevated risk of complications, as observed in the studies conducted by Hao *et al.* and Foocharoen *et al.*^[11,15].

For a novice surgeon, BESS may be challenging to perform. One significant challenge of the biportal technique is creating sufficient visual space in the working area. This requires the relaxation and detachment of some muscles, as noted by Choi *et al.* and Ahn *et al.*^[10,24]. The process demands precision and delicacy to avoid damaging surrounding tissues during separation, rendering it a difficult task for inexperienced surgeons. Moreover, the control of epidural hemorrhage and the maintenance of a fluid saline outflow are vital for the success of the Biportal Technique procedure. Another limitation involves the need for a careful approach to the contralateral side during the procedure. Novice surgeons may find this feat challenging, as even minor errors can have significant consequences^[24]. A comprehensive understanding of anatomy and a steady hand are paramount to preventing any complications.

On the other hand, unilateral biportal endoscopy (UBE), a form of BESS, is another technique employed in spinal surgery. According to Yuan *et al.*^[18], UBE may result in greater trauma due to the creation of two surgical incisions, separation of muscles attached to the vertebral lamina, creation of two operation spaces, and chiseling a portion of the vertebral lamina, leading to bleeding and iatrogenic injury. In addition, this technique has the potential to harm the anatomical integrity of the multifidus and longissimus pectoralis muscles. Likewise, postoperative care may involve the use of a drainage ball to prevent the occurrence of an intraspinal hematoma. Furthermore, compared to poroscopy, UBE is more likely to cause postoperative anemia. Unlike UBE, lateral intervertebral foramen technology can be performed under local anesthesia. However, there is an elevated risk of cerebrospinal fluid leakage due to dural injury when the ligamentum flavum and lamina are removed during UBE surgery.

In summary, BESS has demonstrated positive outcomes, but it is not without its limitations, such as the steep learning curve, practical difficulties during the procedure, and potential complications. Surgeons should consider these limitations and carefully weigh the benefits of BESS against other available options based on the individual needs of the patient. Further research is required to improve the safety and effectiveness of BESS. Ultimately, the surgeon's expertise, the patient's condition, and the surgical goals should

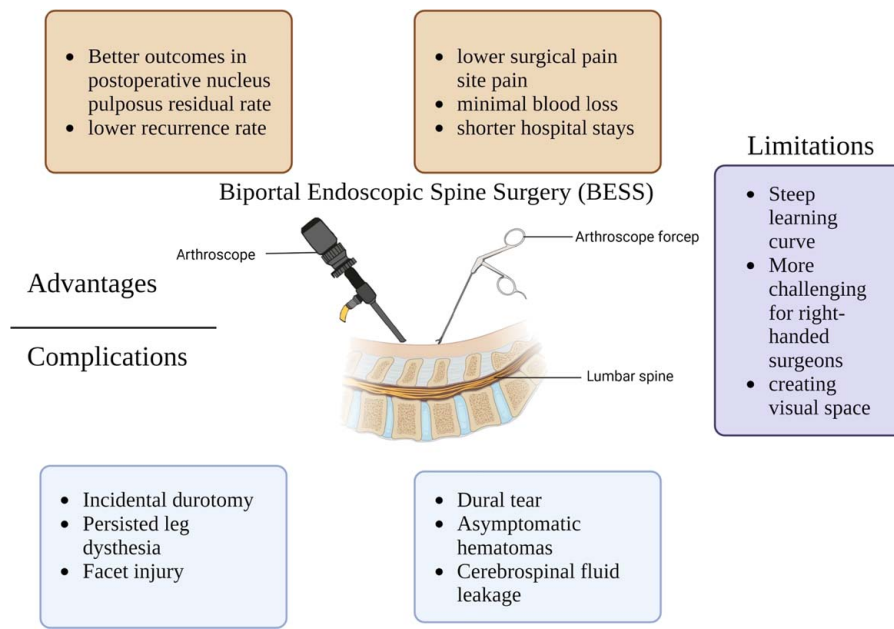


Figure 1. The advantages and drawbacks of using Biportal Endoscopic Spine Surgery on Lumbar Disk Herniation. (Created with Biorender.com).

guide the choice of technique. The summary of the advantages and drawbacks of BESS for LDH has been illustrated in Figure 1.

Future prospects

An essential factor for future advancements in biportal endoscopic surgery for lumbar spine herniated disks lies in the continuous progression of technology. As the field evolves, we anticipate notable improvements in endoscopic equipment, including advancements in high-definition imaging systems, enhanced illumination, and specialized instrumentation. These advancements will bolster the visualization and precision of biportal endoscopic procedures, empowering surgeons to perform surgeries with enhanced accuracy and confidence. Moreover, the integration of augmented reality and robotic-assisted platforms holds promise for further augmenting the capabilities of biportal endoscopic surgery. This integration will facilitate more precise and efficient interventions through improved spatial awareness, accurate instrument guidance, and haptic feedback.

As experience and proficiency with biportal endoscopic techniques expand, we expect the potential range of spinal conditions suitable for this approach to broaden. Presently, BESS is primarily employed for LDH and spinal stenosis. However, future applications are likely to encompass other conditions such as spinal tumors, deformities, and infections. Through ongoing research and advancements, surgeons will have the opportunity to address a wider spectrum of spinal pathologies using this minimally invasive biportal technique.

Another promising aspect of BESS is the potential for improved patient outcomes. Minimally invasive procedures inherently involve reduced tissue trauma, resulting in minimal blood loss, decreased postoperative pain, and accelerated recuperation. Furthermore, the precision and accuracy enabled by the biportal approach have the potential to lead to

improved clinical outcomes and heightened patient satisfaction. Continued advancements in surgical techniques and equipment are expected to contribute to further improving patient outcomes in relation to pain relief, functional recovery, and overall quality of life.

To ensure the widespread adoption and success of BESS, it is crucial to invest in specialized training programs and educational initiatives. As the technique gains popularity, the development of dedicated training courses can effectively educate and train spine surgeons in the intricacies of biportal endoscopic procedures. This will ensure that a sufficient number of skilled surgeons are proficient in performing these surgeries, thereby driving the broader adoption and advancement of the technique.

Limitations of study

Despite the comprehensive approach, there are certain limitations that should be acknowledged. Firstly, the search was conducted across multiple electronic databases, such as PubMed, MEDLINE, and the Cochrane Library, potentially resulting in the omission of valuable literature on the topic. Moreover, the inclusion criteria focused exclusively on studies published in English, which introduces a potential language bias and excludes non-English publications that could offer valuable insights.

Another limitation pertains to the selection of keywords, which may have inadvertently excluded relevant literature using different terminology or indexing. Additionally, it is important to acknowledge that the review focused specifically on retrospective and prospective cohort studies and RCTs pertaining to BESS for LDH. This narrow focus may not capture the full range of relevant literature available on BESS for LDH. Furthermore, the majority of the included studies

originated from Korea or China, suggesting the presence of a potential geographical bias that may limit the generalizability of the findings to other regions.

Lastly, the review included a total of 14 articles that met the inclusion criteria. While efforts were made to encompass a representative range of studies, the limited number of available publications on BESS for LDH may have restricted the depth and breadth of the analysis, potentially overlooking certain aspects of the topic.

It is important to consider these limitations when interpreting the results of the review.

Conclusion

In conclusion, our research highlighting the possible advantages of BESS in postoperative outcomes shows that it is a promising therapy option for LDH. However, it is important to acknowledge that surgical outcomes depend significantly on the experience and skill of the operating surgeon. To maximize the benefits of BESS, it is crucial for surgeons to undergo proper education and training programs to ensure proficiency in performing the procedure. By prioritizing investments in surgeon education and training, we can effectively address the limitations and barriers to adoption, ultimately providing patients with access to the most effective and efficient therapies for LDH.

Ethical approval

Not applicable.

Consent

Not applicable.

Source of funding

The authors did not receive any financial support for this work.

Author contribution

W.A.A.: conceptualized the ideas; W.A.A., F.T.A., Y.A., J.C.N., T.F., A.S., S.G., A.L.W.Y., A.M., J.W., T.A.R., and E.A.: reviewed and edited the manuscript. All authors were involved in writing of initial draft.

Conflicts of interest disclosure

The authors declare that there is no conflicts of interest.

Research registration unique identifying number (UIN)

1. Name of the registry: not applicable.
2. Unique Identifying number or registration ID: not applicable.
3. Hyperlink to your specific registration (must be publicly accessible and will be checked): not applicable.

Guarantor

Favor Tope Adebusoye.

Data availability statement

No data available.

Provenance and peer review

Not commissioned, externally peer reviewed.

References

- [1] Hahne AJ, Ford JJ, McMeeken JM. Conservative management of lumbar disc herniation with associated radiculopathy: a systematic review. *Spine* 2010;35:E488–504.
- [2] Dydyk AM, Ngnitewe Massa R, Mesfin FB. Disc Herniation. *StatPearls* [Internet]. StatPearls Publishing; 2022.
- [3] Schroeder GD, Guyre CA, Vaccaro AR. The epidemiology and pathophysiology of lumbar disc herniations. *InSem Spine Surg* 2016;28:2–7.
- [4] Al Qaraghli MI, De Jesus O. Lumbar Disc Herniation [Updated 2022 Aug 22]. *StatPearls* [Internet]. StatPearls Publishing; 2022. Available from <https://www.ncbi.nlm.nih.gov/books/NBK560878/>
- [5] Koes BW, Van Tulder MW, Peul WC. Diagnosis and treatment of sciatica. *Bmj* 2007;334:1313–7.
- [6] Amin RM, Andrade NS, Neuman BJ. Lumbar disc herniation. *Curr Rev Musculosk Med* 2017;10:507–16.
- [7] Arts MP, Kuršumović A, Miller LE, *et al.* Comparison of treatments for lumbar disc herniation: systematic review with network meta-analysis. *Medicine* 2019;98:e14410.
- [8] Eun SS, Eum JH, Lee SH, *et al.* Biportal endoscopic lumbar decompression for lumbar disk herniation and spinal canal stenosis: a technical note. *J Neurol Surg A Cent Eur Neurosurg* 2017;78:390–6.
- [9] Choi KC, Shim HK, Hwang JS, *et al.* Comparison of surgical invasiveness between microdiscectomy and 3 different endoscopic discectomy techniques for lumbar disc herniation. *World Neurosurg* 2018;116:e750–8.
- [10] Ahn JS, Lee HJ, Park EJ, *et al.* Multifidus muscle changes after biportal endoscopic spinal surgery: magnetic resonance imaging evaluation. *World Neurosurg* 2019;130:e525–34.
- [11] Foocharoen T. Biportal endoscopic spine surgery for single lumbar disc herniation or lumbar stenosis: comparison between right and left side approach of right-handed surgeon. *J Southeast Asian Orthop* 2020;44:11–8.
- [12] Heo DH, Lee N, Park CW, *et al.* Endoscopic unilateral laminotomy with bilateral discectomy using biportal endoscopic approach: technical report and preliminary clinical results. *World Neurosurg* 2020;137:31–7.
- [13] Kang T, Park SY, Park GW, *et al.* Biportal endoscopic discectomy for high-grade migrated lumbar disc herniation. *J Neurosurg* 2020;33:360–5.
- [14] Kang MS, Hwang JH, Choi DJ, *et al.* Clinical outcome of biportal endoscopic revisional lumbar discectomy for recurrent lumbar disc herniation. *J Orthop Surg Res* 2020;15:1–9.
- [15] Hao J, Cheng J, Xue H, *et al.* Clinical comparison of unilateral biportal endoscopic discectomy with percutaneous endoscopic lumbar discectomy for single l4/5-level lumbar disk herniation. *Pain Pract* 2022;22:191–9.
- [16] Jiang HW, Chen CD, Zhan BS, *et al.* Unilateral biportal endoscopic discectomy versus percutaneous endoscopic lumbar discectomy in the treatment of lumbar disc herniation: a retrospective study. *J Orthop Surg Res* 2022;17:30.
- [17] Park HJ, Choi JY, You KH, *et al.* Clinical and radiologic outcomes of biportal endoscopic lumbar discectomy in obese patients: a retrospective case-control study. *BMC Musculosk Dis* 2022;23:1–0.
- [18] Yuan C, Wen B, Lin H. Clinical analysis of minimally invasive percutaneous treatment of severe lumbar disc herniation with ube two-channel endoscopy and foraminal single-channel endoscopy technique. *Oxidative Med Cellular Long* 2022;2022:9264852.

- [19] Zuo R, Jiang Y, Ma M, *et al.* The clinical efficacy of biportal endoscopy is comparable to that of uniportal endoscopy via the interlaminar approach for the treatment of L5/S1 lumbar disc herniation. *Front Surg* 2022;9:1014033.
- [20] Park SM, Lee HJ, Park HJ, *et al.* Biportal endoscopic versus microscopic discectomy for lumbar herniated disc: a randomized controlled trial. *Spine J* 2023;23:18–26.
- [21] Wang JC, Li ZZ, Cao Z, *et al.* Modified unilateral biportal endoscopic lumbar discectomy results in improved clinical outcomes. *World Neurosurg* 2023;169:e235–44.
- [22] Delgado DA, Lambert BS, Boutris N, *et al.* Validation of digital visual analog scale pain scoring with a traditional paper-based visual analog scale in adults. *J Am Acad Orthop Surg Glob Res Rev* 2018;2:e088.
- [23] Brodke DS, Goz V, Lawrence BD, *et al.* Oswestry disability index: a psychometric analysis with 1,610 patients. *Spine J* 2017;17:321–7.
- [24] Choi DJ, Choi CM, Jung JT, *et al.* Learning curve associated with complications in biportal endoscopic spinal surgery: challenges and strategies. *Asian Spine J* 2016;10:624.
- [25] Kim JE, Choi DJ, Park EJ. Risk factors and options of management for an incidental dural tear in biportal endoscopic spine surgery. *Asian Spine J* 2020;14:790–800.
- [26] Park SM, Kim HJ, Kim GU, *et al.* Learning curve for lumbar decompressive laminectomy in biportal endoscopic spinal surgery using the cumulative summation test for learning curve. *World Neurosurg* 2019;122:e1007–13.