



# Ultrasonic diagnosis of parietal peritoneal lipoma torsion in the second trimester: a case description

Zhiheng Yan<sup>1</sup>, Pingan Qi<sup>1</sup>, Gang Wang<sup>1</sup>, Yanwu Yao<sup>1</sup>, Tiangang Li<sup>1</sup>, Yuan Wang<sup>1</sup>, Bin Ma<sup>1,2</sup>

<sup>1</sup>Ultrasound Medicine Center, Gansu Provincial Maternity and Child-Care Hospital, Lanzhou, China; <sup>2</sup>Ultrasound Medicine Center, Lanzhou University Second Hospital, Lanzhou, China

*Correspondence to:* Bin Ma, MD. Ultrasound Medicine Center, Gansu Provincial Maternity and Child-Care Hospital, 143, North Street, Qilihe District, Lanzhou 730050, China; Ultrasound Medicine Center, Lanzhou University Second Hospital, Lanzhou 730050, China. Email: waiwairain@foxmail.com.

Submitted Dec 28, 2022. Accepted for publication Jul 11, 2023. Published online Jul 19, 2023.

doi: 10.21037/qims-22-1440

View this article at: <https://dx.doi.org/10.21037/qims-22-1440>

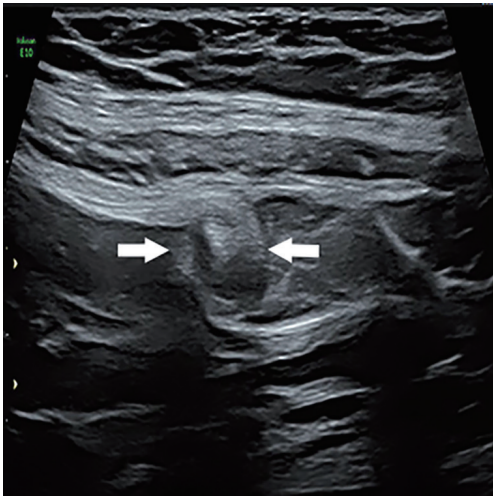
## Introduction

Lipoma is a very common benign tumor composed of mature adipose tissue that can occur anywhere in the body (1). There have been some reports of mesenteric or omental lipomas; however, parietal peritoneal lipoma is extremely rare (2), and no case of ultrasonic diagnosis of parietal peritoneal lipoma torsion during pregnancy has been reported. The abdominal pain caused by torsion of parietal peritoneal lipoma during pregnancy is similar to that of appendicitis. Herein, we describe a case of parietal peritoneal lipoma torsion that occurred in the second trimester of pregnancy. The tumor was cured following successful resection, the abdominal pain was resolved, and the pregnancy progressed to birth.

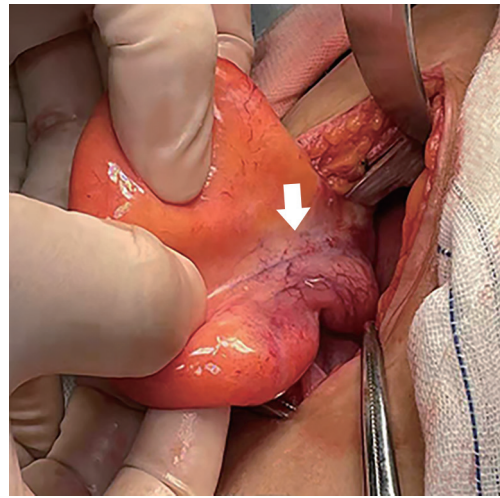
## Case description

All procedures performed in this study were in accordance with the ethical standards of the institutional and/or national research committee(s) and with the Helsinki Declaration (as revised in 2013). Written informed consent was provided by the patient for publication of this case report and accompanying images. A copy of the written consent is available for review by the editorial office of this journal. A 33-year-old woman, pregnant 26w+, presented with persistent right lower abdominal pain that has been present for 2 days. Physical examination showed tenderness and rebound pain in the right lower abdomen, no obvious mass was detected upon palpation, and the bowel sound was normal. The patient had not experienced nausea, vomiting,

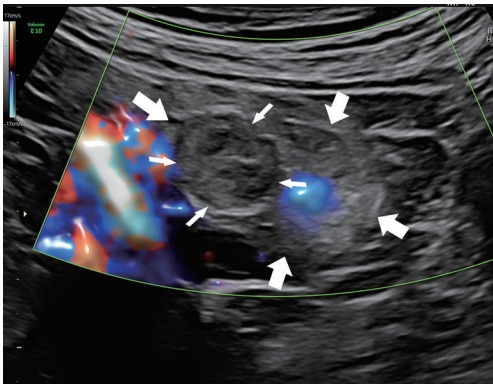
or fever. Laboratory examination of white blood cells returned the following:  $10.36 \times 10^9/L$ , neutrophil percentage 78.6%, 2.79 mg/L, and procalcitonin 0.08 ng/mL. Ultrasound examination revealed an extrauterine hyperechoic mass in the right abdominal cavity; the size was about 52 mm × 27 mm, the boundary was clear, the capsule was visible, and a hypoechoic nodule, the size 10 mm × 8 mm (*Figure 1*), showed a whirlpool sign. Color Doppler flow imaging (CDFI) revealed that there was no obvious blood flow signal in the mass (*Figure 2*), which suggested the possibility of peritoneal tumor torsion, appendicitis to be excluded; the bilateral ovaries were clearly displayed, and no obvious abnormality was found. An abdominal magnetic resonance imaging (MRI) scan revealed a round iso-T1 and slightly longer T2 signal mass of 54 mm × 43 mm × 12 mm in the abdominal cavity on the right lateral side of the uterus (*Figure 3*), which was clearly delineated from the uterus and not obviously connected to the peritoneum, with no abnormal signal in diffusion-weighted imaging (DWI), and no abnormal signal in both ovaries. After anti-inflammatory treatment was proven ineffective, laparotomy was performed. Taking McBurney's incision of the right lower abdomen, a tumor with a size of 60 mm × 50 mm × 50 mm was found in the peritoneum of the right abdominal wall (*Figure 4*). The tumor was soft and yellow, with calcified nodules scattered on the surface, the pedicle was twisted clockwise at the base of the right lower abdomen, and the local blood vessels of the tumor were blue. The size of the resected specimen was 60 mm × 45 mm × 15 mm, which was pathologically diagnosed as benign lipoma with local necrosis (*Figure 5*). Postoperatively, the patient's abdominal



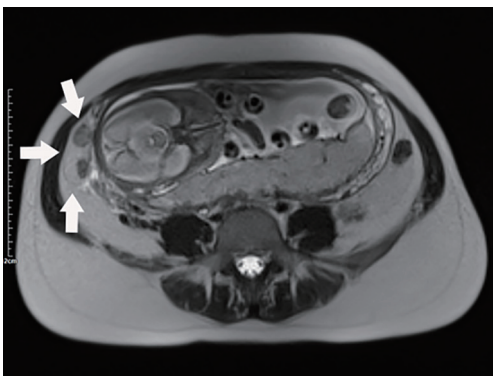
**Figure 1** Ultrasound showing torsion nodules of a parietal peritoneal lipoma, size 10 mm × 8 mm (arrows).



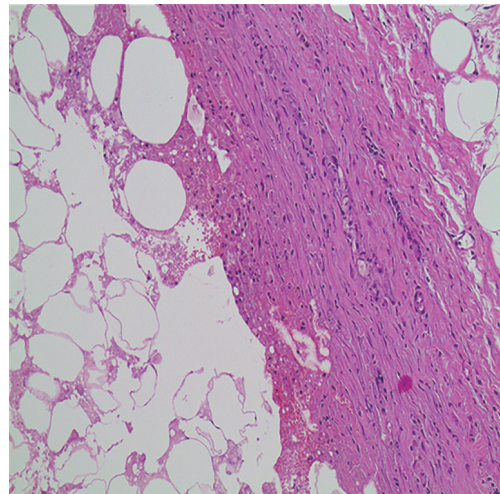
**Figure 4** Parietal peritoneal lipoma twisted during operation, local vascular cyanosis (arrow).



**Figure 2** Ultrasound showing that there was no blood flow signal and internal infarction (thin arrows) in the parietal peritoneal lipoma (thick arrows).



**Figure 3** MRI showing parietal peritoneal lipoma on the right side of the abdominal cavity (arrows). MRI, magnetic resonance imaging.



**Figure 5** Pathology showing that the mature adipocytes in parietal peritoneal lipoma (HE staining, ×10). HE, hematoxylin-eosin.

pain was relieved, and she was discharged on the 3rd day after operation without any other discomfort.

## Discussion

Lipoma is a common benign soft tissue tumor, and although it can occur in any part of the body, the superficial part is common in the neck, trunk, or limbs, and the deep part can occur in the chest, mediastinum, and retroperitoneum (1). Abdominal lipoma usually occurs in the omentum and mesentery. Parietal peritoneal lipoma is an extremely rare

disease; despite having been reported in the literature, the origin and pathogenesis are still unclear. Some scholars believe that the origin tissue may be peritoneal adipose tissue or fat implantation in peritoneal fluid (3). Since 2006, when Barut *et al.* (4) reported the first case of parietal peritoneal lipoma, a total of nine cases have been reported, but pregnancy complicated with parietal peritoneal lipoma torsion has not been reported. In these previous reports, eight cases had abdominal pain and two cases had torsion. The case described here also presented with pain, and we made an initial ultrasonic diagnosis of peritoneal mass torsion. Right lower abdominal pain in the second and third trimesters of pregnancy has two possible causes, which refer to the obstetrics and gynecology or surgery, respectively. Adnexal torsion is the most common in gynecology and obstetrics, whereas appendicitis is the most common in surgery. In this case, the right lower abdominal pain caused by torsion of parietal peritoneal lipoma is another rare presentation, which is clinically similar to appendicitis. This may be because the sigmoid colon occupies the left side of the pelvic cavity during pregnancy, whereas the right side of the pelvic cavity is empty, and a peritoneal lipoma located on the right side is more likely to be twisted. During ultrasound examination, it was found that the hypoechoic mass under the peritoneum had a capsule, the boundary was clear, the internal echo was not uniform, a cord-like strong echo could be seen within it, and the tumor activity was not obvious under probe compression. Therefore, peritoneal lipoma was considered first. When the torsion of the pedicle is found, the diagnostic thought becomes clearer. Torsion of a parietal peritoneal lipoma should be distinguished from appendicitis and adnexal torsion, which have typical ultrasonographic features and can thus be clearly identified. Appendicitis is mainly characterized by appendiceal swelling, greater omentum echo enhancement, and leukocytosis; adnexal torsion is mainly a space-occupying lesion in the adnexal area, and the torsion nodules adjacent to it can be observed. When the patient does the Valsalva's movement, the adnexal torsion has a significant relative motion to the abdominal wall.

It has been reported that the value of computed tomography (CT) in the diagnosis of parietal peritoneal lipoma is positive (2), showing a well-defined homogeneous fat density mass. The diagnostic value of ultrasound has not been reported. According to our experience, ultrasound can be used as the first choice for the examination of parietal peritoneal lipoma, which can be used for real-time dynamic evaluation of mass by two-dimensional (2D) and color

Doppler. The torsion and blood supply of the mass can also be found by ultrasound. In addition, when women are in a state of pregnancy, CT radiation is not recommended, so ultrasound is particularly valuable in the diagnosis of parietal peritoneal lipoma. The ultrasonographic findings of parietal peritoneal lipoma were as follows: a hyperechoic mass was detected in the abdominal cavity, the boundary was clear, the capsule was intact, the strong echo-like cord could be seen in the parietal peritoneal lipoma, and the tumor movement was synchronized with the abdominal wall. This case involved a torsion of parietal peritoneal lipoma, so scattered hypoechoic infarction and its adjacent torsional pedicle could be seen in the uniform hyperechoic mass. Due to the patient being pregnant, the movement relationship between the mass and the abdominal wall could not be observed by Valsalva's movement. Although MRI can diagnose parietal peritoneal lipoma, it is not the first choice because of the longer time required and high cost. Obvious physiological and anatomical changes occur during pregnancy, which brings difficulties to the discovery and treatment of acute abdominal conditions, making early detection, early diagnosis, and early treatment of acute abdominal complaints particularly important. Appropriate and reasonable treatment can not only reduce the pain of pregnant women, but also reduce the risk of fetal loss (5). Early diagnosis, in particular, is of great guiding significance for clinical decision-making and treatment. Therefore, accurate and timely diagnosis of parietal peritoneal lipoma torsion has a significant impact on the mother and fetus in the second and third trimesters of pregnancy. Ultrasound is a non-invasive and non-radiation examination method, which has high application value for investigating acute abdominal complaints during the second and third trimesters of pregnancy.

## Acknowledgments

*Funding:* None.

## Footnote

*Conflicts of Interest:* All authors have completed the ICMJE uniform disclosure form (available at <https://qims.amegroups.com/article/view/10.21037/qims-22-1440/coif>). The authors have no conflicts of interest to declare.

*Ethical Statement:* The authors are accountable for all aspects of the work in ensuring that questions related

to the accuracy or integrity of any part of the work are appropriately investigated and resolved. All procedures performed in this study were in accordance with the ethical standards of the institutional and/or national research committee(s) and with the Helsinki Declaration (as revised in 2013). Written informed consent was provided by the patient for publication of this case report and accompanying images. A copy of the written consent is available for review by the editorial office of this journal.

*Open Access Statement:* This is an Open Access article distributed in accordance with the Creative Commons Attribution-NonCommercial-NoDerivs 4.0 International License (CC BY-NC-ND 4.0), which permits the non-commercial replication and distribution of the article with the strict proviso that no changes or edits are made and the original work is properly cited (including links to both the formal publication through the relevant DOI and the license). See: <https://creativecommons.org/licenses/by-nc-nd/4.0/>.

**Cite this article as:** Yan Z, Qi P, Wang G, Yao Y, Li T, Wang Y, Ma B. Ultrasonic diagnosis of parietal peritoneal lipoma torsion in the second trimester: a case description. *Quant Imaging Med Surg* 2023;13(9):6301-6304. doi: 10.21037/qims-22-1440

## References

1. Pillay Y. Parietal peritoneal lipomas: a first case report of two lipomas of the parietal peritoneum. *J Surg Case Rep* 2021;2021:rjab162.
2. Choi H, Ryu D, Choi JW, Xu Y, Kim Y. A giant lipoma of the parietal peritoneum: Laparoscopic excision with the parietal peritoneum preserving procedure - a case report with literature review. *BMC Surg* 2018;18:49.
3. Bang CS, Kim YS, Baik GH, Han SH. A case of lipoma of parietal peritoneum causing abdominal pain. *Korean J Gastroenterol* 2014;63:369-72.
4. Barut I, Tarhan OR, Cerci C, Ciris M, Tasliyar E. Lipoma of the parietal peritoneum: an unusual cause of abdominal pain. *Ann Saudi Med* 2006;26:388-90.
5. Marquez A, Wasfie T, Korbitz H, Wong V, Pearson E, Holsinger H, Hella J, Barber K. Role of Abdominal Ultrasound and Magnetic Resonance Imaging in Pregnant Women Presenting With Acute Abdominal Pain. *Am Surg* 2022;88:1875-8.