

# An uncommon side effect from the 'king of fruit': A case report on life-threatening hyperkalaemia after eating durian fruit

SAGE Open Medical Case Reports  
Volume 9: 1–4  
© The Author(s) 2021  
Article reuse guidelines:  
sagepub.com/journals-permissions  
DOI: 10.1177/2050313X211063195  
journals.sagepub.com/home/sco



Alvin Oliver Payus<sup>1</sup> , Fatimah Ahmedy<sup>2</sup>,  
Syed Sharizman Syed Abdul Rahim<sup>3</sup> and Doreen Sumpat<sup>1</sup>

## Abstract

Hyperkalaemia is a condition of excess potassium level that occurs as a result of increased intake, or reduced renal clearance, or both. In a severe condition, hyperkalaemia is a medical emergency that can be life-threatening especially if recognised late and left untreated. There are many causes of hyperkalaemia. However, eating durian fruit in the background of impaired kidney function is a very rare occurrence. In this article, we report a case of an elderly lady who presented with a life-threatening hyperkalaemia as a result of eating large amount of durian fruit while having multiple diarrhoeal episodes due to acute gastroenteritis that led to acute kidney injury. She was successfully treated and was discharged well. The objective of this case report is to share the rare cause of a life-threatening hyperkalaemia where prompt diagnosis and treatment initiation are crucial to prevent mortality.

## Keywords

Hyperkalaemia, fruit, acute kidney injury

Date received: 8 September 2021; accepted: 10 November 2021

## Introduction

Durian is a very famous fruit in the Southeast Asia. It is often called the 'king of fruit' by the local people in this region. Apart from being sweet and tasty, it also contains high amount of potassium.<sup>1</sup> Therefore, people with impaired renal function who eats huge amount of durian have a risk to develop hyperkalaemia.<sup>2</sup> Hyperkalaemia is common electrolyte disturbance that can be caused by increase uptake, reduce uptake or both. Severe hyperkalaemia is a life-threatening medical emergency that can lead to sudden cardiac death.<sup>3</sup> Here, we report a case of a life-threatening hyperkalaemia as a result of taking large amount of durian fruit that developed in a patient with acute kidney injury from severe gastroenteritis. And to the best of our knowledge, this is the first case report that describes a life-threatening hyperkalaemia due to eating durian fruit in a patient with acute kidney injury. Although durian fruit is not popular among the Western population due to the pungent smell, similar condition can happen after taking any other fruit which is rich in potassium, such as banana and jackfruit.

## Case report

A 79-year-old woman with hypertension, dyslipidaemia and diabetes mellitus presented with lethargy and palpitation for 1 day duration. She had a preceding history of intermittent fever with watery diarrhoea 1 week prior to admission which has already resolved 1 day prior to the presentation. She described the diarrhoeal episode as watery, with more than five passing per day, but no history of passing mucous or fresh blood. She denied vomiting, abdominal pain, change in

<sup>1</sup>Medicine Based Department, Faculty of Medicine and Health Science, Universiti Malaysia Sabah (UMS), Kota Kinabalu, Malaysia

<sup>2</sup>Rehabilitation Medicine Unit, Faculty of Medicine and Health Science, Universiti Malaysia Sabah (UMS), Kota Kinabalu, Malaysia

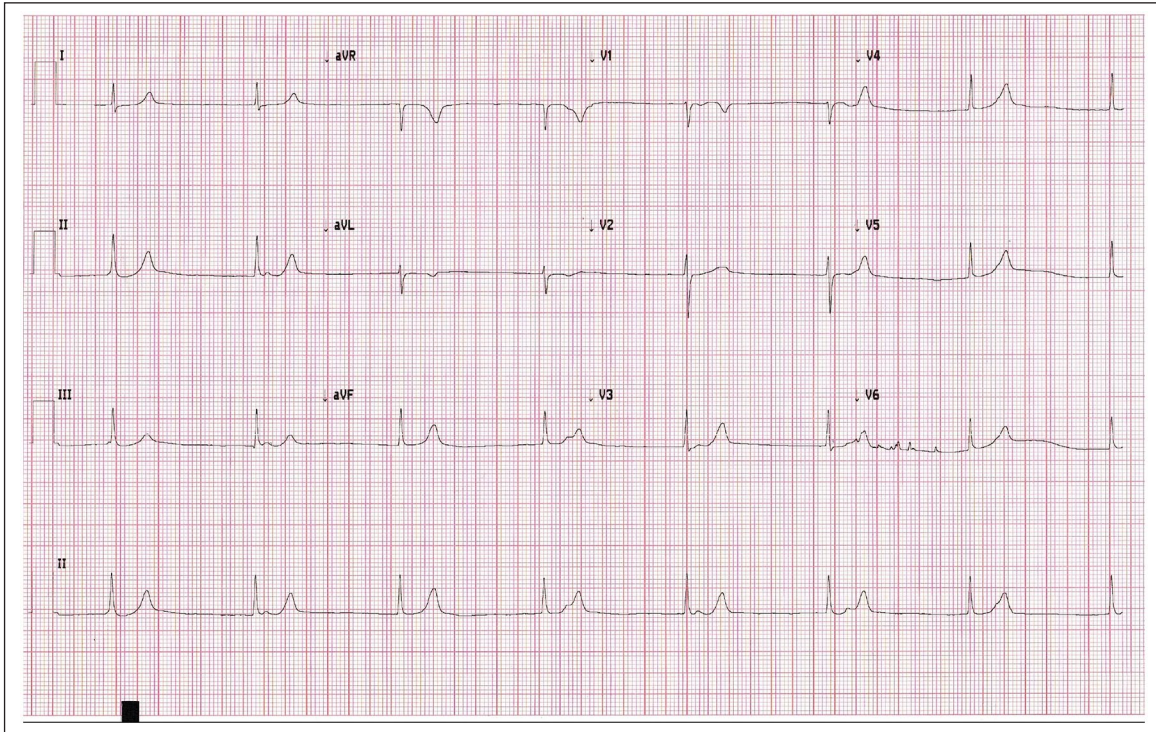
<sup>3</sup>Public Health Medicine Department, Faculty of Medicine and Health Science, Universiti Malaysia Sabah (UMS), Kota Kinabalu, Malaysia

### Corresponding Author:

Alvin Oliver Payus, Medicine Based Department, Faculty of Medicine and Health Science, Universiti Malaysia Sabah, Jalan UMS, Kota Kinabalu 88400, Sabah, Malaysia.

Email: dralvinpayus@ums.edu.my





**Figure 1.** Electrocardiogram done on admission before treatment initiated shows tall-tented symmetrical T wave and flattened P wave, which signify hyperkalaemia.

appetite, headache nor body weakness. Her list of medications includes oral metformin 500 mg twice daily, oral glimepiride 80 mg twice daily, oral amlodipine 10 mg once daily and oral simvastatin 20 mg once during night time. She denied taking any over the counter or traditional medication, and also any alcohol-contained beverage. Upon further history, she reported taking a large amount of durian fruit for the past few days despite having multiple episodes of diarrhoea.

Upon arrival to emergency department, her vital signs were stable with blood pressure of 153/70 mm Hg and pulse rate of 76 beats per minute. She was afebrile and her oxygen saturation was normal. On physical examination, she was clinically dehydrated, but otherwise pink and not jaundiced. Her abdomen was soft, not tender, and there was no palpable mass nor organomegaly noted. Her bowel sound was reactive and normal. Examination of her cardiovascular and respiratory system was normal as well as her nervous system. Electrocardiogram (ECG) was done and showed absence of P waves, junctional bradycardia with the heart rate of 40 beats per minute, and widespread tall and tented T waves all over the precordial leads (Figure 1). Initial blood investigation revealed severe hyperkalaemia with the potassium of 8.1 mmol/L in the background of impaired kidney function (estimated glomerular filtration rate (eGFR) of 18.7 mL/min/1.73 m<sup>2</sup>) and metabolic acidosis (Table 1). Her baseline urea and creatinine which was taken 3 months ago during medical check-up was 5 mmol/L and 90 µmol/L.

In view of severe hyperkalaemia, she was instantly given a combination of 10 mL of intravenous (IV) calcium gluconate 10%, intravenous actrapid 10 U and 50 mL of IV dextrose 50%, which was repeated four times. She was also given 2 L of 0.9% normal saline drip daily. In view of the history of fever and multiple episodes of watery diarrhoea prior to admission, she was given IV ceftriaxone 2 g bolus and 1 g once daily thereafter to cover for infective acute gastroenteritis. After 3 days, her potassium level and kidney function returned to normal. She never required haemodialysis during the admission. Her repeated ECG showed sinus rhythm with heart rate of 75 beats per minute (Figure 2). She was discharged well and continued her follow-up with health clinic for her hypertension, dyslipidaemia and diabetes mellitus. She was advised to consume durian in moderation if she experienced multiple bouts of diarrhoea again in the future.

## Discussion

Durian is a very popular fruit in Southeast Asia and often named as the ‘king of fruit’ by the local people. Apart from having a very strong pungent smell, durian is well-known for its sweet and savoury taste. It also contains a very high amount of nutrients and antioxidants which are beneficial to the human body.<sup>1,4</sup> Durian also is rich in potassium where 100 g of durian flesh contain 436 mg of potassium, which makes it one of the highest potassium contain fruit, followed

by banana and jackfruit, which both contain 358 and 303 mg in 100 g, respectively.<sup>1,2</sup> In a healthy individual, consumption of these fruits will not cause any danger as the body capable of excreting the excessive potassium through the kidneys. However, this feedback mechanism is lost when the kidney

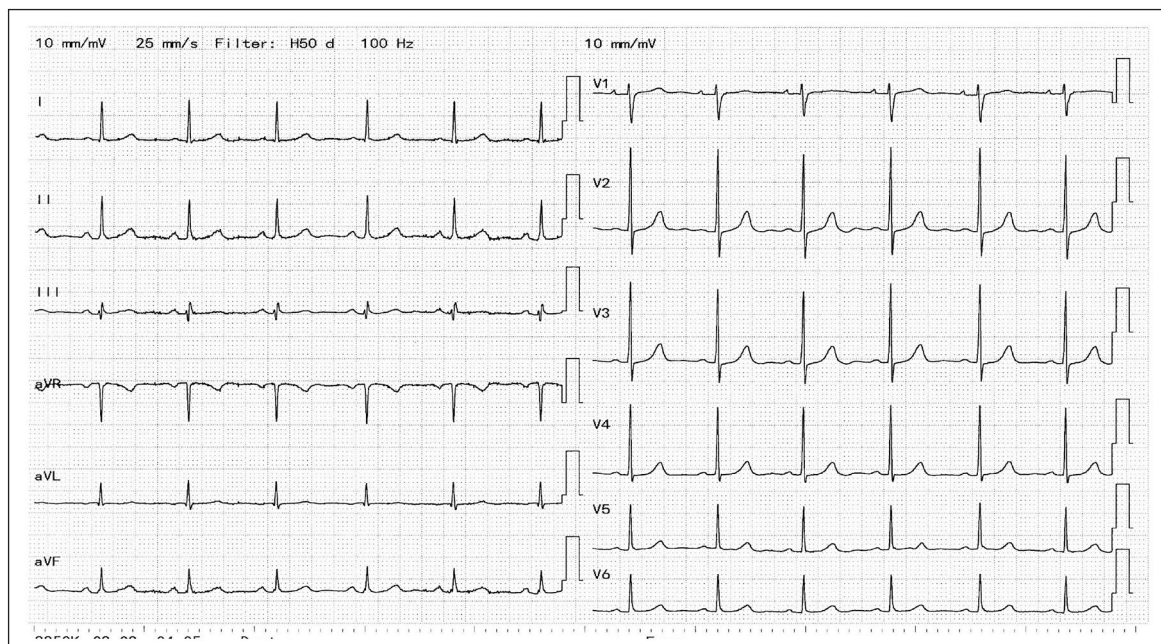
**Table 1.** Initial blood investigation taken upon arrival to emergency department showed moderate hyponatremia and severe hyperkalaemia. There was raised urea and creatinine as well which signify kidney impairment. There was also metabolic acidosis as evidence by low serum pH and bicarbonate level. The serum lactate level was mildly elevated which may signify hypoperfusion from hypovolemia. Otherwise, there was no other abnormality noted.

Blood parameters	Result	Normal range
Haemoglobin	11.2 g/dL	12–18 g/dL
Platelet	330 × 10 <sup>9</sup> /L	150–400 × 10 <sup>9</sup> /L
White blood cell	12.7 × 10 <sup>9</sup> /L	4.0–11.0 × 10 <sup>9</sup> /L
Albumin	35 g/L	35–50 g/L
Alkaline phosphatase	250 U/L	50–150 U/L
Alanine transaminase	90 U/L	5–35 U/L
Total bilirubin	3.6 μmol/L	0–13 μmol/L
Creatinine	220 μmol/L	60–120 μmol/L
Sodium	125 mmol/L	135–150 mmol/L
Potassium	8.1 mmol/L	3.5–5.0 mmol/L
Urea	15.8 mmol/L	1.7–8.0 mmol/L
Magnesium	0.9 mmol/L	0.66–1.07 mmol/L
Serum pH	7.3	7.35–7.45
Serum CO <sub>2</sub>	38.7 mm Hg	35–45 mm Hg
Bicarbonate	18.5 mmol/L	21–28 mmol/L
Serum lactate	3.6 mmol/L	0.5–2.0 mmol/L

function is impaired. Therefore, those with kidney failure are at a risk of developing hyperkalaemia if they consume durian fruits or any other food with high potassium content excessively. This was first described by Leo et al.<sup>2</sup> in a case report of patient with end-stage kidney disease who develop a life-threatening hyperkalaemia after consuming huge amount of durian. In the report, the authors advised patients with end-stage renal failure to avoid food with high potassium content.

In contrast to the case reported by Leo et al.,<sup>2</sup> our patient's kidney function was previously normal and acutely impaired as a result of the recent episode of severe watery diarrhoea which led to dehydration. Therefore, as her renal function was impaired, she was unable to remove the excess potassium intake from the consumption of huge amount of durian fruit. Fortunately, she was managed promptly with aggressive fluid therapy and potassium lowering treatment. She never requires haemodialysis. She was advised to take moderation amount of durian or any high potassium diet.

The clinical manifestations of hyperkalaemia are very subtle and non-specific which includes muscle weakness, palpitations, fatigue and so on. In extreme cases, hyperkalaemia is a life-threatening medical emergency. This usually happens when the potassium level is above 8 mmol/L which can lead to cardiac conduction delay, fatal cardiac arrhythmias and eventually cardiac arrest. Electrocardiogram changes of hyperkalaemia include tall and tented T wave with shortened QT intervals, progressive prolongation of PR intervals, flattened P wave, widening of QRS complex, 'sine-wave' and ultimately asystole.<sup>5</sup> Treatment of hyperkalaemia is targeted to protect the heart from the lethal effect of high potassium and also to reduce the serum potassium level back to normal. This involves prompt administration of



**Figure 2.** Electrocardiogram repeated after treatment shows normal sinus rhythm.

a cocktail of medication which consist of calcium gluconate 10%, short-acting insulin 10 U and dextrose 50%. Sometimes, intravenous infusion of sodium bicarbonate 100 mL is also given to drive the excess potassium into the cells. In resistant cases, urgent haemodialysis may be required to rapidly remove the excess potassium from the body.<sup>6</sup>

## Conclusion

In conclusion, consuming a large amount of durian fruit in the background of acute kidney injury secondary to dehydration can lead to a life-threatening hyperkalaemia. A prompt detection and timely management is vital to prevent sudden cardiac arrest and save lives.

## Acknowledgements

The authors thank the patient for giving his consent and cooperation in the writing of this case report. The authors also thank the Director General of Ministry of Health of Malaysia for his permission to publish this article.

## Declaration of conflicting interests

The author(s) declared no potential conflicts of interest with respect to the research, authorship and/or publication of this article.

## Ethics approval

Our institution does not require ethical approval for reporting individual cases or case series.

## Funding

The author(s) received no financial support for the research, authorship and/or publication of this article.

## Informed consent

Written informed consent was obtained from the patient(s) for their anonymised information to be published in this article.

## ORCID iD

Alvin Oliver Payus  <https://orcid.org/0000-0003-4675-103X>

## References

1. Ho LH and Bhat R. Exploring the potential nutraceutical values of durian (*Durio zibethinus* L.) – an exotic tropical fruit. *Food Chem* 2015; 168: 80–89.
2. Leo CL, Leong WS, Tieh CS, et al. Durian induced hyperkalaemia. *Med J Malaysia* 2011; 66(1): 66–67.
3. Bianchi S, Aucella F, De Nicola L, et al. Management of hyperkalemia in patients with kidney disease: a position paper endorsed by the Italian Society of Nephrology. *J Nephrol* 2019; 32(4): 499–516.
4. Payus CM, Refdin MA, Zahari NZ, et al. Durian husk wastes as low-cost adsorbent for physical pollutants removal: ground-water supply. *Mater Today: Proc* 2021; 42: 80–87.
5. Littmann L and Gibbs MA. Electrocardiographic manifestations of severe hyperkalemia. *J Electrocardiol* 2018; 51(5): 814–817.
6. Mount DB. *Treatment and prevention of hyperkalemia in adults*. Waltham, MA: UpToDate, 2013.