

Treatment of Primary Pigmented Nodular Adrenocortical Disease



Authors

Xinming Liu¹, Siwen Zhang¹, Yunran Guo¹, Xiaokun Gang^{1‡}, Guixia Wang^{1‡}

Affiliations

1 Department of Endocrinology and Metabolism, The First Hospital of Jilin University, Changchun, China

Key words

primary pigmented nodular adrenocortical disease (PPNAD), adrenocorticotropin hormone (ACTH)-independent Cushing's syndrome (CS), hypercortisolemia, Carney complex (CNC), adrenalectomy

received 21.12.2021

accepted after revision 14.09.2022

Bibliography

Horm Metab Res 2022; 54: 721–730

DOI 10.1055/a-1948-6990

ISSN 0018-5043

© 2022. The Author(s).

This is an open access article published by Thieme under the terms of the Creative Commons Attribution-NonDerivative-NonCommercial-License, permitting copying and reproduction so long as the original work is given appropriate credit. Contents may not be used for commercial purposes, or adapted, remixed, transformed or built upon. (<https://creativecommons.org/licenses/by-nc-nd/4.0/>)

Georg Thieme Verlag KG, Rüdigerstraße 14, 70469 Stuttgart, Germany

Correspondence

Dr. Guixia Wang

The First Hospital of Jilin University

Department of Endocrinology and Metabolism

NO.1 Xinmin Street

130021 Changchun

China

Tel.: +86 431 8878-2078, Fax: +86 431 8878-6066

gwang168@jlu.edu.cn

Xiaokun Gang

The First Hospital of Jilin University

Department of Endocrinology and Metabolism

NO.1 Xinmin Street

130021 Changchun

China

gangxk@jlu.edu.cn

ABSTRACT

Primary pigmented nodular adrenocortical disease (PPNAD) is a rare cause of adrenocorticotropin hormone (ACTH)-independent Cushing's syndrome (CS), which mainly occurs in children and young adults. Treatment options with proven clinical efficacy for PPNAD include adrenalectomy (bilateral or unilateral adrenalectomy) and drug treatment to control hypercortisolemia. Previously, the main treatment of PPNAD is bilateral adrenal resection and long-term hormone replacement after surgery. In recent years, cases reports suggest that unilateral or subtotal adrenal resection can also lead to long-term remission in some patients without the need for long-term hormone replacement therapy. Medications for hypercortisolemia, such as Ketoconazole, Metyrapone and Mitotane et.al, have been reported as a preoperative transition for in some patients with severe hypercortisolism. In addition, tryptophan hydroxylase inhibitor, COX2 inhibitor Celecoxib, somatostatin and other drugs targeting the possible pathogenic mechanisms of the disease are under study, which are expected to be applied to the clinical treatment of PPNAD in the future. In this review, we summarize the recent progress on treatment of PPNAD, in which options of surgical methods, research results of drugs acting on possible pathogenic mechanisms, and the management during gestation are described in order to provide new ideas for clinical treatment.

Introduction

Primary pigmented nodular adrenocortical disease (PPNAD) is a rare cause of adrenocorticotropin hormone (ACTH)-independent Cushing's syndrome (CS) and is characterized by small, black and brown

pigmented micronodules in adrenal cortex. PPNAD mainly occurs in children and young adults. The incidence of PPNAD is unknown at present [1]. PPNAD accounts for only about 1.1–1.8% of all causes of CS [2, 3]. It may be isolated or associated with Carney complex (CNC). About 10% of patients with PPNAD without familial history or other manifestations of CNC, are generally termed as isolated

‡ These authors contributed equally.

PPNAD (i-PPNAD) [4]. CNC is a rare autosomal dominantly inherited multiple neoplasia syndrome characterized by spotty skin pigmentation, multiple endocrine neoplasia, and myxomas [5]. It is most frequently caused by mutations in the type 1a regulatory subunit gene of protein kinase A (PKA) (*PRKAR1A*), and approximately 30 % of cases occur sporadically. Clinical manifestations of CNC include lentigines, blue nevus, myxomas in the heart, skin, and breast, pituitary tumors, adrenocortical tumors, and thyroid neoplasms. PPNAD and the consequent ACTH-independent Cushing's syndrome is one of the most common endocrine manifestations of CNC, accounting for about 25–60 % of CNC patients [6, 7].

Hypercortisolism in PPNAD can be overt, subclinical, cyclic or atypical. And adrenal imaging is also often non-specific, which makes the diagnosis and treatment of the disease difficult [8–11]. In the last two decades, much progress has been made in describing the various forms, clinical manifestations, and pathogenesis of PPNAD. However, there is still controversy regarding the treatment of the disease. Treatment options with proven clinical efficacy for PPNAD included adrenalectomy (bilateral or unilateral adrenalectomy) and drug treatment to control hypercortisolemia. The preferred treatment is surgery. Bilateral adrenalectomy is the universal recommended option, which will cause permanent adrenal insufficiency and require a life-long hormone replacement therapy [12]. In recent years, some authors considered that unilateral adrenalectomy or subtotal adrenalectomy can also let selected patients to obtain long-term remission without hormone replacement therapy, so that patients have a better quality of life [13–15]. As PPNAD often leads to mild, occult or atypical Cushing's syndrome, drug therapy may be a good candidate. In medical treatment, Ketoconazole, Metyrapone, Mitotane and other drugs can be used to treat hypercortisolemia for patients who have severe hypercortisolemia before surgery and refuse to undergo further surgery or who have surgical contraindications [16]. In addition, a number of promising drugs are being studied and may be used in the clinic in the future. Along with the basic research of PPNAD, scholars found that there were several alternative drugs associated with the possible mechanism targets of the disease: tryptophan hydroxylase inhibitor, 5-hydroxytryptamine receptor antagonist, COX2 inhibitor celecoxib and somatostatin, etc. [17–19]. These drugs are promising, but most of them only are proven in animal studies, and further research is needed to illustrate whether they can be used in the clinic.

PPNAD is now better recognized, an increasing number of endocrinologists and urologists were aware of its numerous manifestations and the need for effective management. Furthermore, the management of some special groups, such as children and pregnant women, need multidisciplinary cooperation. Appropriate treatment strategy and follow-up management are important to prognosis of disease. In this review, we will summarize the update of diagnosis and treatment of PPNAD, including treatment experience on patients during gestation, and results of studies on new type drugs acting on new molecular targets.

Clinical Characteristics of PPNAD

PPNAD patients are generally younger. The age of PPNAD patients associated with CNC appeared to be bimodally distribution, with a

few appearing in the first 2–3 years and most in the twentieth and thirtieth decades [20]. Among a total of 212 patients with PPNAD, the prevalence was significantly higher in women than in men (71 vs. 29 %). The median age of PPNAD diagnosis was 34 years, and women were diagnosed at a younger age than men (30 years vs. 46 years). Such gender difference became apparent after puberty [21].

CS usually starts insidiously, and the main features are hypertension, weight gain, and growth restriction in children, although it is not seen in all patients. Typical features also include osteoporosis, proximal muscle weakness, wide purple striae, full moon face, central obesity, irregular menstruation in women, hirsutism, acne, decreased cognitive function, and so on [22, 23]. According to previous literature, hypercortisolism in PPNAD can be overt, subclinical, cyclic or atypical [8–11]. Due to the variable Cushing's syndrome phenotypes of PPNAD, its symptoms and signs may not be obvious. Patients always visit doctors repeatedly until the diagnosis of ACTH-independent CS can be clearly diagnosed [12]. Whether these different CS phenotypes are related to the genotype of PPNAD remains to be further explored.

Osteoporosis and osteoporotic fractures are more common in patients with PPNAD compared with other causes of Cushing's syndrome. In a 10-year retrospective study of 1652 Chinese Cushing's syndrome patients, osteoporotic fractures were observed more frequently in PPNAD than in adrenocortical adenoma (ADA) and primary bilateral macronodular adrenal hyperplasia (PBMAH) patients (26.7 vs. 9.0 vs. 4.9 %) [3]. In another Chinese PPNAD cases (25 patients), PPNAD patients are more likely to develop osteoporosis than ADA patients (78.3 vs. 48.0 %), while there are no differences between PPNAD and PBMAH patients [9]. In addition, some patients are accompanied by hyperandrogenemia, with hirsutism and irregular menstruation as the main symptoms [8, 24, 25]. In a case series of 6 patients from India, one patient had CS associated with symptoms of hyperandrogenism (hirsutism and irregular menses) [8].

Since the majority of PPNAD patients are associated with CNC, patients usually have clinical manifestations associated with CNC, such as spotty skin pigmentation, heart myxoma, skin myxoma. And many patients have a family history of CNC or PPNAD [7, 26].

Although CS is rare in children, it can lead to significant morbidity and even mortality. CS should be diagnosed early by clinician [27]. PPNAD mainly occurs in late childhood or youth, and is very rare in infancy, the reported youngest patients are only 15 months [8]. Bilateral adrenal resection and replacement therapy were the most common treatment strategies [28, 29], Ketoconazole and other drugs can be used for transition before surgery [8]. They always showed catch-up growth and improvement in the BMI after adrenalectomy [8, 28, 30]. PPNAD may be a signal of CNC, so patients with dominant CS at a younger age may requires genetic testing and long-time follow-up.

PPNAD is very rare in infancy, whereas CS associated with McCune – Albright syndrome (MAS) is usually in infancy. MAS is a sporadic heterogeneous disorder caused by an activating mutation in *GNAS*, which encodes the alpha subunit of the Gs G-coupled protein receptor [31]. It is characterized by congenital polyostotic fibrous bone dysplasia, café-au-lait skin plaques, precocious puberty and other endocrine disorders. About 7.1 % of patients can present with CS, which is usually severe, and is also associated with

other endocrine dysfunction, such as hyperthyroidism and precocious puberty [32].

Adrenal causes of CS, such as PBMAH and adrenal cortical adenoma, may be closely associated with anomalous adrenal hormone receptors, especially G-coupled protein receptors, such as the gastric inhibitory polypeptide (GIP) receptor, the luteinizing hormone/human chorionic gonadotropin (LH/HCG) receptor, vasopressin (AVP) receptor, and the beta-adrenergic receptor [33]. These aberrant adrenal hormone receptors are functionally associated with steroidogenesis. Although less reported in PPNAD, aberrant 5-HT receptors have recently been found to be expressed in PPNAD [17]. The detection of abnormal adrenergic hormone receptors provides a new target for treatment.

Diagnosis of PPNAD

The diagnosis of PPNAD is challenging, especially for patients without other manifestations of CNC or family history due to: 1) clinical manifestations may not be obvious, atypical, and progress slowly; 2) laboratory tests can be normal during the non-secretory period of periodic CS; 3) those without CNC-related clinical manifestations (skin pigmentation, myxoma, etc.) and family history which effect judgement; and 4) it is difficult to accurately find small nodules on CT.

First, the diagnosis of CS should be established. After excluding exogenous glucocorticoid exposure, initial screening tests include urine free cortisol (UFC), late night salivary cortisol, 1 mg overnight dexamethasone suppression test (DST) and 2 mg/d for 48 hours DST [34]. The dexamethasone-CRH test or the midnight serum cortisol test can be used as subsequent evaluation to establish the cause of CS in patients with concordantly positive results from two different initial tests [34].

Adrenal imaging should be evaluated in patients with suspicious adrenal cause CS. In PPNAD, computed tomography (CT) imaging examinations may show normal size adrenal glands and several small bead-like nodules [22, 35]. But 'normal' imaging is often reported too [10]. CT with slice thickness of 3 mm or less may be helpful for diagnosis [36]. Single-photon emission computed tomography (SPECT-CT) with the use of iodomethyl-norcholesterol (I-131) showed bilateral glands uptake was increased [25]. It supported the diagnosis of PPNAD. In addition, adrenal cortical imaging with (6–131I) iodomethyl-19 cholesterol-lowering (NP-59) also can be an optional imaging examination. Vezzosi et al. compared CT scans and adrenal cortical imaging with (6–131I) iodomethyl-19 cholesterol-lowering (NP-59) in 17 patients with diagnosed PPNAD. NP-59 imaging showed bilateral adrenal uptake in all patients, and asymmetric uptake was observed in 59% of patients [37]. Besides, bone scintigraphy will help identify bone lesions associated with MAS [38].

Laboratory examination often show that patients with overt CS have ACTH-independent cortisol secretion hypercortisolism unrelated to ACTH and lack of cortisol diurnal rhythm. However, laboratory tests may be normal during the non-secretory period of periodic CS. It is worth noting that patients with PPNAD often appear an abnormal increase in urinary free cortisol during the Liddle test [39]. This increase in urinary glucocorticoid excretion following dexamethasone administration is one of the diagnostic criteria for CNC. But

recently, a prospective study showed that only 39 percent of patients with confirmed or probable PPNAD had an abnormally elevated UFC [40]. In 2018, for the first time Chen et al. proposed to distinguish PPNAD from bilateral macronodular adrenal hyperplasia and adrenal cortical adenoma (ADA) by using the ratio of UFC to pre-HDDST 24 hours after high-dose dexamethasone inhibition test (HDDST). When 24-hour UFC (post-H-DEX)/UFC (pre-H-DEX) was >1.08 , the sensitivity and specificity were 84.0 and 75.6%, respectively [9]. In addition, adrenal tissue ACTH immunohistochemistry will help identify the presence of ACTH paracrine secretion [41].

ACTH is a regulator of androgen secretion from the adrenal cortex. Due to the inhibitory effect of excessive cortisol secretion on ACTH, the dehydroepiandrosterone (DHEAS) of adrenal CS patients were often lower than those of healthy individuals [17]. According to previous reports of patients with PPNAD, laboratory results showed frequent decreases in serum DHEAS levels [18], and some patients showed overproduction of testosterone and normal DHEAS [6]. Overproduction of androgens by PPNAD-associated adenomas leading to virilization and infertility has also been reported in the literature [19].

ACTH is a regulator of androgen secretion from the adrenal cortex. Due to the inhibitory effect of excessive cortisol secretion on ACTH, the dehydroepiandrosterone (DHEAS) of adrenal CS patients were often lower than those of healthy individuals [42]. According to previous reports of patients with PPNAD, laboratory results showed frequent decreases in serum DHEAS levels [25], and some patients showed overproduction of testosterone and normal DHEAS [24]. Overproduction of androgens by PPNAD-associated adenomas leading to virilization and infertility has also been reported in the previous literature [43].

Both CNC and PPNAD can be associated with inactivating mutations of the *PRKAR1A* gene. In 353 patients with PPNAD or CNC, 73% carried 80 different *PRKAR1A* mutations [21]. Such inactivating *PRKAR1A* germline mutations are also common in i-PPNAD [24, 44]. In addition, mutations in *PDE11A* [45] and *PDE8B* [46] are described for PPNAD. Somatic defects in *PRKAR1A* gene [47], and β -catenin gene (*CTNNB1*) [48] have been also observed in PPNAD patients, which has potential clinical and genetic significance. The study of genetic mutations in adrenal tissue will help to identify such somatic mutations. And genetic testing may be of great help in diagnosing PPNAD.

Adrenalectomy

Bilateral adrenalectomy

Bilateral adrenalectomy is the universal recommended surgical type for PPNAD treatment because of its feature for involvement of bilateral adrenal glands [8, 12, 49–51]. Clinical Practice Guidelines for the treatment of CS from Endocrine Society suggested that laparoscopic bilateral adrenalectomy is the definite treatment for PPNAD [52]. Laparoscopic surgery can be performed as transabdominal or retroperitoneal approach, both of which have significant advantages over open surgery, including a clear field of vision, small incisions, less bleeding, and shorter hospital stays. The retroperitoneal approach, which can avoid abdominal stimulation has shorter operative time, fewer complications and less postoperative

pain. But it has a smaller workspace and may increase intraocular pressure due to the need for prone position [53]. The advantages of bilateral adrenalectomy are that it rapidly cures CS, has low risk of recurrence, and is suitable for patients of all ages [8, 28, 54]. Bilateral adrenalectomy was performed in most patients presenting with overt CS. According to the current literatures, most of patients have biochemical remission after bilateral adrenalectomy, and the corresponding symptoms can disappear. The children always catch-up with growth, and the weight of patients can return to normal, and the Cushing appearance can disappear. Most of the patients were followed up for a short period of time. It is conceivable that bilateral adrenalectomy will cause permanent adrenal insufficiency and require a life-long careful glucocorticoid and mineralocorticoid replacement therapy. Such patients are prone to acute adrenal crisis as a complication especially under stress or infection, and may have a lower quality of life, so they have to be good compliance [8, 12, 15, 35]. Unilateral total adrenalectomy associated with contralateral partial adrenal (adrenal-sparing surgery) has been observed to achieve good treatment results in PBMAH [55]. This approach avoids the need for lifelong steroid replacement in most cases and has a low rate of adrenal insufficiency and recurrence [56]. It may be a potential surgery approach for PPNAD.

In 31 patients with adrenal hyperplasia (MAH) or PPNAD who underwent bilateral adrenalectomy, 30 (97 %) patients are cured biochemically [12]. These patients had complete resolution for Cushing's syndrome symptoms at 9 to 12 months postoperatively. Six patients in their cases presented with hypertension, and all were cured or improved after surgery. Five of them were able to discontinue all antihypertensive drugs, and the remaining one required only one antihypertensive drug. In the case series of Memon et al. on a mean age of 8.2 years, 5 patients are cured after bilateral adrenalectomy, and 1 of them die about 2 years after surgery probably caused by an adrenal crisis. All patients showed improvement in height post-surgery [8]. Two adolescent brothers with complaints of weight gain and growth retardation had typical Cushing's syndrome manifestations: hypertension, moon-shaped face, facial plethora, centripetal obesity, and red-purple skin striae. One month after bilateral adrenalectomy, they lost 5–6 kg of weight their skin textures fades and there was a reduction in the facial plethora. And their blood pressure, lipids and heart ejection fraction were improved [28]. A 20-year-old woman presenting with overt CS had bilateral avascular necrosis of the femoral heads. After bilateral adrenalectomy, her presentation of cortisol excess improved, and her femoral head necrosis resolved without orthopedic intervention with 1-year follow-up [57].

Unilateral adrenalectomy

In recent years, more studies have shown that unilateral adrenal resection can achieve remission of long-term symptoms and biochemical for some patients without adrenal insufficiency [51]. Some case reports [58, 59] and cases series proved the feasibility and effectiveness of unilateral adrenalectomy [10, 13, 60]. Most patients acquired biochemical remission and disappearance of clinical symptoms after unilateral adrenalectomy. But some patients reappear with symptoms of hypercortisolism after surgery, usually less severe than at the time of presentation. And most patients

with recurrence undergo contralateral resection, while some are treated with medication.

A 16-year-old female patient with complaints of weight gain and irregular menstruation had a preoperative iodocholesterol scintigraphy showing unilateral uptake of the left adrenal gland. She underwent left adrenalectomy. After 10 months of follow-up, she had significant weight loss, disappearance of the features of CS and biochemical remission [51]. Xu et al. reviewed 13 PPNAD patients who underwent unilateral adrenalectomy, of whom only 1 patient recurred with a requirement of contralateral adrenal resection, while the rest achieved remission (Median follow-up time: 47 months) [13]. Kyrilli et al. summarized the patients with unilateral adrenal resection in the literature. There were 24 cases with unilateral adrenalectomy, followed by contralateral resection in 5 cases, with the duration of contralateral resection ranging from 2 months to 25 years [14].

Cohen et al. reported a case of successful pregnancy after unilateral adrenal resection without adrenal hypofunction during pregnancy, indicating that unilateral adrenal resection may be considered as an option for women with fertility needs [59]. There were two 15-year-old patients with complaints of weight gain and growth retardation, with typical manifestations of hypercortisolism on examination (central obesity, hirsutism, purplish streaks, facial acne). They underwent unilateral adrenalectomy. 5–6 months postoperatively, they had significant clinical and biochemical improvement, weight loss, accelerated growth, and regression of skin streaks and acne. One required HC replacement for a short period of time and one not required HC replacement. Then they reappeared with CS symptoms and laboratory tests suggesting loss of cortisol circadian rhythm, so contralateral adrenalectomy was performed at 8 and 10 months postoperatively [61].

Bilateral adrenocortical hyperplasia (BAH) mainly includes Primary Bilateral Macronodular adrenocortical hyperplasia (PBMAH) and PPNAD [62]. Studies have shown that unilateral adrenalectomy improves clinical symptoms and biochemical status successfully for PBMAH for adult patients, particularly for patients with asymmetric hyperplasia and mildly phenotypes [62–64]. Similar to PBMAH, PPNAD is often manifested as mild to moderate CS. That suggested that unilateral resection for PPNAD may also be a feasible approach.

Some patients have bilateral adrenal nodular hyperplasia with the presence of macronodules. Research studies of Vezzosi et al. about Adrenal [6 β -¹³¹I]-iodomethyl-19-norcholesterol] (NP-59) scintigraphy revealed that asymmetrical adrenal uptake associated with macronodules in 10 of 17 patients (59 %) [37]. In those patients with unilateral greater nodular hyperplasia, selective resection of the side with greater nodules may be a good option. There are twins female patients with PPNAD from Belgium who underwent unilateral adrenalectomy have ongoing clinical and biochemical remissions without any adrenal insufficiency after 3 years and 18 months follow-up after surgery, respectively [14]. Unilateral adrenalectomy was chosen because the symptoms were mild and asymmetric bilateral adrenal uptake or size was shown on imaging (¹³¹I iodomethyl-norcholesterol scintigraphy coupled with single-photon emission computed tomography (SPECT)/CT Adrenal CT scan) [14].

It seems unilateral adrenalectomy can relieve the symptoms of mild to moderate CS without causing adrenocortical insufficiency. When NP-59 scintigraphy or (SPECT)/CT scan revealed asymmetrical adrenal uptake [37], selective resection of the side with prevalent uptake may be a good option [14]. But scintigraphy is not available in many countries. Adrenal volume measurement, adrenal vein sampling are also modalities that can substitute scintigraphy. Clinicians should also consider the possibility that unilateral resection may not be a complete cure and may require a second operation. There is also a case showed that adrenal crisis occurred during a viral infection 3 weeks after unilateral adrenalectomy [50]. But we thought the probability for adrenal crisis of unilateral adrenalectomy is much lower than bilateral resection. Most adrenalectomies are performed by laparoscopy with less trauma. For patients who have the possibility of remission after resection of one side, they and their doctors may prefer to remove one side first and then remove the other side after recurrence. Compared with permanent adrenal insufficiency caused by bilateral adrenal resection, it may be better to selectively remove one side of the adrenal gland for patients with atypical or mild symptoms. In addition, genotypic-phenotypic correlation indicated that some gene mutation sites were associated with milder phenotypes, which may be a basis for determining surgical approaches, but further studies are needed [21]. Therefore, we suggested that clinicians should select unilateral or bilateral adrenal resection based on a comprehensive evaluation of the degree of increased cortisol, symptoms, preoperative imaging evaluation, and the patient's willingness, to choose the surgical procedure with the best benefit. Due to the rarity of PPNAD, clinical studies about the treatment were limited, the indication and long-term efficacy of unilateral adrenal resection remained to be studied. If further studies could confirm the indications for unilateral adrenal resection, it may greatly improve the quality of life of patients without long-term hormone replacement on the basis of disease control.

Drug Therapy

Drugs that inhibit steroid production and action

There are several kinds of drugs to treat hypercortisolism as conservative managements. These include steroidogenic inhibitors (Metyrapone, Mitotane, Etomidate, LCI699) and glucocorticoid receptor antagonists (Mifepristone) [65]. They can be used as preoperative transition for patients with severe hypercortisolemia or maintenance therapy for patients who refuse surgery [65]. Medication is also needed for patients who are not cured completely after surgery [44].

If patients have severe hypercortisolemia preoperatively, they should receive adrenolytic medications for weeks preoperatively [12]. In the literature, Ketoconazole can as a bridge therapy before surgery [8, 25]. It is worth noting that Ketoconazole has potential side effects such as liver enzyme elevation, gastrointestinal discomfort, androgen reduction and pruritus [66]. Therefore, it is not generally preferred for men, and it should be used under liver enzyme monitoring [67]. Ketoconazole treatment has been used successfully in several cases of CS pregnancy and did not cause birth

defects to the fetus [68, 69]. Fluconazole has been considered as an alternative to Ketoconazole [70]. Navarro et al. reported case series in which a patient showed a significant decrease in urinary cortisol after 3 months of Fluconazole treatment. But he discontinued due to the side effects of pruritus and facial rash; Another patient remained on low-dose Metyrapone as maintenance therapy after unilateral adrenalectomy [44].

As for a patient who refused surgery, long-term and low-dose mitotane therapy (from 0.5 g/d to 4 g/d) was an effective method to correct hypercortisolism. The typical symptoms of Cushing's syndrome and hyperandrogenism gradually subsided at two months from the beginning of the treatment. The size of the adrenal glands appeared to be reduced after 7 months adrenolytic treatment. The patient was still in remission after 122 months follow-up [16].

Besides, Osilodrostat as an oral 11 β -hydroxylase (CYP11B1) inhibitor, catalyzes the final step of cortisol synthesis. And it is administered less frequently than conventional drugs, with fewer adverse effects and fewer interactions with other drugs [71, 72]. Phase III clinical trial results have confirmed its safety and efficacy in adult CS patients, and it may be a new option for the treatment of PPNAD.

New drugs targeting possible pathogenic mechanisms

The pathogenic mechanisms of PPNAD are still not clear up to now, a possible mechanism is that genetic events lead to structural activation of cAMP/PKA (cyclic adenosine monophosphate/protein kinase A) signal pathway [73, 74]. The PKA consists of two molecules of regulatory (R) subunits bound to two molecules of catalytic (C) subunits. *PRKAR1A* as a tumor-suppressor gene located at 17q22–24 encodes the type 1a regulatory subunit of cAMP-dependent PKA [73, 75]. Inactivation mutation of *PRKAR1A* cause premature stop codons through the nonsense-mediated mRNA decay (NMD). This process would lead to a truncated protein product which contributes to increased signal by PKA [76]. In addition, mutations in the phosphodiesterase *PDE11A* [45] and *PDE8* and the PKA catalytic subunit *PRKACA* gene [77] are also detected in patients with PPNAD, and all of these gene events lead to structural activation of the cAMP/PKA signaling pathway, resulting in high glucocorticoid secretion independent of ACTH.

There are a number of drug candidates currently under study that target possible mechanisms of the disease, such as Rapamycin, Celecoxib, tryptophan hydroxylase inhibitors (► Fig. 1). These drugs have been proven in animal or in vitro tests, but there are no clinical studies have been reported.

Rapamycin

The mammalian target of Rapamycin sensitive complex 1 (mTORC1) pathway was activated by PKA signaling in adrenal glands of specific *PRKAR1A* knockout mouse and human PPNAD tissues, leading to increased cell survival. PKA/mTOR activation was correlated with BAD (a member of the BCL-2 apoptotic family) hyperphosphorylation which may lead to apoptosis resistance and tumor formation. Rapamycin is an effective and selective mTOR inhibitor that acts on the PKA/mTOR pathway. Treatment with Rapamycin specifically sensitized ADKO adrenal cortical cells to

dexamethasone-induced apoptosis in animal experiments, indicating its potential efficacy in the treatment of adrenal hyperplasia [78, 79].

Celecoxib

In specific *PRKAR1A* knockout mice, Sahut et al. observed that the atypical hyperplasia of fetal-like cortex at the corticomedullary junction. And such hyperplasia extended to the periphery over time. Fetal-like adrenal cortical cells (FLACs) caused by the lack of R1a cannot be clear out and then morbid hyperplasia of adrenal cortical [80]. Celecoxib is a prostaglandin peroxidase synthase 2 (PTGS2) [also known as cyclooxygenase 2 (COX2)] inhibitor that is currently used to inhibit the growth of certain tumors. It is mainly related to the inhibition of prostaglandinE2 (PGE2), and the reduction of stem cell-like cells induced by this molecule [19]. Celecoxib can effectively reduce the proliferation of adrenal cortical cells induced by FLACs and thereby reduce glucocorticoid production, which has been verified in mice and human adrenal cells in vitro [81].

Somatostatin analogues

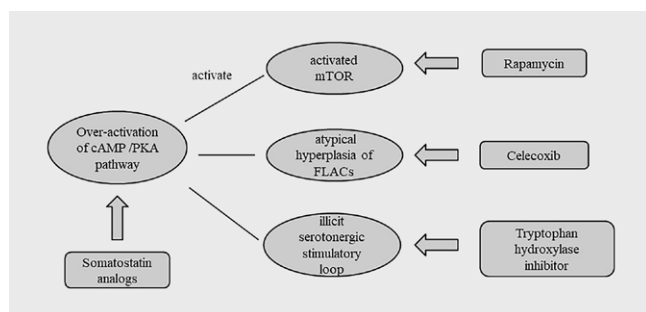
Somatostatin (SST) analogues (SSA) like Octreotide can reduce intracellular cAMP production and thus may reduce cortisol secretion in PPNAD and other ACTH-independent CS patients. A short-term preliminary clinical study on the application of Octreotide in patients with PPNAD showed that the expression levels of somatostatin receptors (SSTRs) in PPNAD tissues were significantly higher than those in normal adrenal glands. But short-acting SSA Octreo-

tide had no significant effect on cortisol secretion in patients with PPNAD. However, because of the sample size of this study was small, only Octreotide was used and further SSA-related studies with larger sample sizes may be possible in the future to further explore its effect on PPNAD [18].

Tryptophan hydroxylase inhibitor

Bramet et al. found that adrenal tissues removed from PPNAD patients overexpress the key enzyme tryptophan hydroxylase type 2 (TPH2) and the 5-hydroxytryptamine receptors (5-HT4R, 5-HT6R and 5-HT7R) because of cAMP/PKA pathway activation, leading to an illicit serotonergic stimulatory loop associated with hypercortisolemia [17]. Later, Le Mestreet et al. confirmed this by studying adrenal tissues exposed to high plasma ACTH levels for a long time and found that TPH and/or 5-HT4/6/7 receptors were overexpressed in tissues of different disease types. In addition, they found that 5-HT4R antagonists can reduce the stimulatory effect of 5-HT in vitro. It is suggested that tryptophan hydroxylase inhibitors may also be a promising drug for the treatment of PPNAD [82].

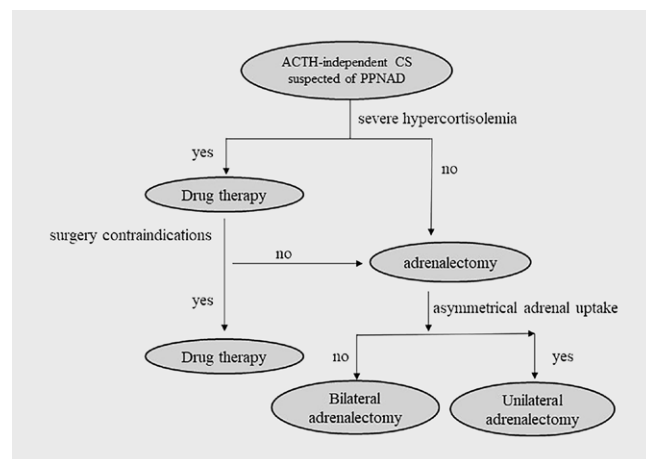
Drug therapy is commonly used as a transition treatment preoperatively for patients with severe hypercortisolemia currently [65]. The drugs targeting the specific mechanism of PPNAD are very promising. But they only have been proven in animal or in vitro tests. We expect these drugs to be proven clinically and look forward to the clear indications for drug therapy. Although there are still many problems to be solved in the treatment of PPNAD, we proposed a brief treatment strategy for PPNAD by summarizing the literature (► Fig. 2). We look forward to more studies that will tell us more about specific treatments.



► **Fig. 1** Drug candidates under study that target possible mechanisms of PPNAD. One of pathogenic mechanisms of PPNAD is that genetic events lead to structural activation of cAMP/PKA signal pathway, resulting in high glucocorticoid secretion independent of ACTH. The mTORC1 pathway was activated by PKA signaling. Rapamycin is a mTOR inhibitor that acts on the PKA/mTOR pathway. Activated PKA signal leads to FLACs cannot be clear out and then morbid hyperplasia of adrenal cortical. Celecoxib can effectively reduce the proliferation of adrenal cortical cells induced by FLACs and thereby reduce glucocorticoid production. There is an illicit serotonergic stimulatory loop associated with hypercortisolemia because of cAMP/PKA pathway activation in adrenal tissues. Tryptophan hydroxylase inhibitors can reduce the stimulatory effect of 5-HT. Somatostatin analogs can reduce intracellular cAMP production and thus may reduce cortisol secretion in PPNAD. PPNAD, Primary pigmented nodular adrenocortical disease; cAMP/PKA, cyclic adenosine monophosphate/protein kinase A; mTORC1, the mammalian target of Rapamycin sensitive complex 1; FLACs, Fetal-like adrenal cortical cells; 5-HT, 5-hydroxytryptamine.

Management of PPNAD During Gestation

Using “PPAND” and “pregnancy” as key words, we searched English literature published before May 2021 in PubMed database and found 3 cases with PPNAD during pregnancy [83–85]. There are 2 patients received Metyrapone to control hypercortisolemia during pregnancy [83, 84]. All the 3 patients were successfully delivered by cesarean section, and the causes of delivery included



► **Fig. 2** treatment strategy for PPNAD.

► **Table 1** Published reports of PPNAD during pregnancy.

Authors [Ref]	Pa-tient age	Period	Therapy	Medication using during pregnancy	Perinatal morbidity	Birth weight (g)	Apgar scores (1 min, 5 min)	Fetal complications
Spaniol et al. [84]	24	18–26 weeks	drug therapy, bilateral adrenalectomy 4 months postpartum	Metyrapone (500 mg/day)	preeclampsia	650	2, 6	NS
Schulz et al. [85]	31	32 weeks	bilateral adrenalectomy postpartum	None	severe preeclampsia	1700	4, 8	moderate respiratory distress syndrome
Ralser et al. [83]	31	26–31 weeks	drug therapy, remission at 6 weeks postpartum	Metyrapone (1000 mg/day)	recurrent vaginal bleeding	1740	8, 10	transient hyponatremia

IUGR: Intrauterine fetal growth restriction; NS: Not stated.

preeclampsia and recurrent vaginal bleeding. All the infants survived after birth, and two infants developed respiratory distress syndrome and transient hyponatremia (► **Table 1**).

Hypercortisolism in PPNAD may be related to the high estradiol level during pregnancy. Catichaet.al. observed that estradiol can stimulate cortisol secretion in a dose-dependent manner with the absence of ACTH in vitro of PPNAD cells [86]. Most drugs in the hypercortisolism treatment are contraindicated during pregnancy [87, 88]. Metyrapone is an 11 β -hydroxylase inhibitor that has been used safely during pregnancy [65, 89]. It can reduce serum cortisol levels, but adrenocorticotrophic hormone (ACTH) is stimulated with the decreased cortisol levels, which increases the production of mineralocorticoid, possibly leading to hypertension. This point should be vigilant in clinical practice [89]. Due to the limited evidence reported in the literature, it should be used cautiously.

Due to high blood pressure, diabetes, weight gain and skin purple lines may also associate with pregnant, the diagnosis of CS during pregnancy is challenging. In addition, the physiological changes during pregnancy can also include the increase of serum cortisol and urine free cortisol [89]. However, the loss of circadian rhythm of cortisol secretion and the significant increase of 24-hour urine free cortisol level are still helpful for the diagnosis of CS. If severe preeclampsia is diagnosed and blood pressure is difficult to control, pregnancy or delivery may need to be terminated promptly. In patients with a history of bilateral adrenal resection, hormone replacement must be monitored, and a stress dose of glucocorticoids administered at delivery. Unfortunately, there is no data on long-term follow-up of mothers and fetuses after completion of delivery of PPNAD. We have no idea about long-term remission. In conclusion, the pregnancy decision of PPNAD patients requires multidisciplinary cooperation. Due to the genetic characteristics of PPNAD and CNC, the fetus should be screened for genetic diseases after birth and a detailed follow-up strategy should be developed to detect and manage the possible related diseases at an early stage.

Conclusion

PPNAD is a rare disease with atypical symptoms and difficult clinical diagnosis. And the exact mechanism remains unclear. Surgery is the treatment of PPNAD, while the appropriate surgical methods should be selected according to individual circumstances. For patients who cannot receive surgical treatment or only have mild hypercortisolemia, drug treatment can be candidate. The drugs that may have therapeutic potential for PPNAD, such as tryptophan hydroxylase inhibitor, 5-HT receptor antagonist, COX2 inhibitor celecoxib and somatostatin, still need further clinical studies to confirm. Furthermore, we should pay attention to the management of PPNAD in children and pregnancy, strengthen interdisciplinary teamwork, and long-term follow-up should be conducted no matter what treatment plan is selected.

Conflict of Interest

The authors declare that they have no conflict of interest.

References

- [1] Shenoy BV, Carpenter PC, Carney JA. Bilateral primary pigmented nodular adrenocortical disease. Rare cause of the Cushing syndrome. *Am J Surg Pathol* 1984; 8: 335–344
- [2] Ammini AC, Tandon N, Gupta N et al. Etiology and clinical profile of patients with Cushing's syndrome: a single center experience. *Indian J Endocrinol Metab* 2014; 18: 99–105
- [3] Zhou J, Zhang M, Bai X et al. Demographic characteristics, etiology, and comorbidities of patients with Cushing's syndrome: a 10-year retrospective study at a large general hospital in China. *Int J Endocrinol* 2019; 7159696:
- [4] Stratakis CA. Adrenocortical tumors, primary pigmented adrenocortical disease (PPNAD)/Carney complex, and other bilateral hyperplasias: the NIH studies. *Horm Metab Res* 2007; 39: 467–473

- [5] Carney JA, Gordon H, Carpenter PC et al. The complex of myxomas, spotty pigmentation, and endocrine overactivity. *Medicine* 1985; 64: 270–283
- [6] Bertherat J. Carney complex (CNC). *Orphanet J Rare Dis* 2006; 1: 21
- [7] Correa R, Salpea P, Stratakis CA. Carney complex: an update. *Eur J Endocrinol* 2015; 173: M85–M97
- [8] Memon SS, Thakkar K, Patil V et al. Primary pigmented nodular adrenocortical disease (PPNAD): single centre experience. *J Pediatr Endocrinol Metab* 2019; 32: 391–397
- [9] Chen S, Li R, Lu L et al. Efficacy of dexamethasone suppression test during the diagnosis of primary pigmented nodular adrenocortical disease in Chinese adrenocorticotrophic hormone-independent Cushing syndrome. *Endocrine* 2018; 59: 183–190
- [10] Lowe KM, Young WF Jr., Lyssikatos C et al. Cushing syndrome in Carney complex: clinical, pathologic, and molecular genetic findings in the 17 affected Mayo clinic patients. *Am J Surg Pathol* 2017; 41: 171–181
- [11] Gunther DF, Bourdeau I, Matyakhina L et al. Cyclical Cushing syndrome presenting in infancy: an early form of primary pigmented nodular adrenocortical disease, or a new entity? *J Clin Endocrinol Metab* 2004; 89: 3173–3182
- [12] Powell AC, Stratakis CA, Patronas NJ et al. Operative management of Cushing syndrome secondary to micronodular adrenal hyperplasia. *Surgery* 2008; 143: 750–758
- [13] Xu Y, Rui W, Qi Y et al. The role of unilateral adrenalectomy in corticotropin-independent bilateral adrenocortical hyperplasias. *World J Surg* 2013; 37: 1626–1632
- [14] Kyriilli A, Lytrivi M, Bouquegneau MS et al. Unilateral adrenalectomy could be a valid option for primary nodular adrenal disease: evidence from twins. *J Endocr Soc* 2019; 3: 129–134
- [15] Sarlis NJ, Chrousos GP, Doppman JL et al. Primary pigmented nodular adrenocortical disease: reevaluation of a patient with carney complex 27 years after unilateral adrenalectomy. *J Clin Endocrinol Metab* 1997; 82: 1274–1278
- [16] Campo MR, Lamacchia O, Farese A et al. Mitotane and Carney complex: ten years follow-up of a low-dose mitotane regimen inducing a sustained correction of hypercortisolism. *Hormones (Athens, Greece)* 2015; 14: 300–304
- [17] Bram Z, Louiset E, Ragazzon B et al. PKA regulatory subunit 1A inactivating mutation induces serotonin signaling in primary pigmented nodular adrenal disease. *JCI Insight* 2016; 1: e87958
- [18] Bram Z, Xekouki P, Louiset E et al. Does somatostatin have a role in the regulation of cortisol secretion in primary pigmented nodular adrenocortical disease (ppnad)? a clinical and in vitro investigation. *J Clin Endocrinol Metab* 2014; 99: E891–E901
- [19] Kurtova AV, Xiao J, Mo Q et al. Blocking PGE2-induced tumour repopulation abrogates bladder cancer chemoresistance. *Nature* 2015; 517: 209–213
- [20] Stratakis CA, Kirschner LS, Carney JA. Clinical and molecular features of the Carney complex: diagnostic criteria and recommendations for patient evaluation. *J Clin Endocrinol Metab* 2001; 86: 4041–4046
- [21] Bertherat J, Horvath A, Groussin L et al. Mutations in regulatory subunit type 1A of cyclic adenosine 5'-monophosphate-dependent protein kinase (PRKAR1A): phenotype analysis in 353 patients and 80 different genotypes. *J Clin Endocrinol Metab* 2009; 94: 2085–2091
- [22] Lacroix A, Feelders RA, Stratakis CA et al. Cushing's syndrome. *Lancet* 2015; 386: 913–927
- [23] Boscaro M, Barzon L, Fallo F et al. Cushing's syndrome. *Lancet* 2001; 357: 783–791
- [24] Groussin L, Julian E, Perlemoine K et al. Mutations of the PRKAR1A gene in Cushing's syndrome due to sporadic primary pigmented nodular adrenocortical disease. *J Clin Endocrinol Metab* 2002; 87: 4324–4329
- [25] Cyranska-Chyrek E, Filipowicz D, Szczepanek-Parulska E et al. Primary pigmented nodular adrenocortical disease (PPNAD) as an underlying cause of symptoms in a patient presenting with hirsutism and secondary amenorrhea: case report and literature review. *Gynecol Endocrinol* 2018; 34: 1022–1026
- [26] Stratakis CA, Carney JA, Lin JP et al. Carney complex, a familial multiple neoplasia and lentiginosis syndrome. Analysis of 11 kindreds and linkage to the short arm of chromosome 2. *J Clin Invest* 1996; 97: 699–705
- [27] Stratakis CA. Diagnosis and clinical genetics of Cushing syndrome in pediatrics. *Endocrinol Metab Clin North Am* 2016; 45: 311–328
- [28] Attri B, Aggarwal A, Mattoo S et al. Cushing's syndrome due to primary pigmented nodular adrenal disease in two brothers with Carney complex. *Pediatr Endocrinol Diabetes Metab* 2020; 26: 155–158
- [29] da Silva RM, Pinto E, Goldman SM et al. Children with Cushing's syndrome: primary pigmented nodular adrenocortical disease should always be suspected. *Pituitary* 2011; 14: 61–67
- [30] Storr HL, Chan LF, Grossman AB et al. Paediatric Cushing's syndrome: epidemiology, investigation and therapeutic advances. *Trends Endocrinol Metab* 2007; 18: 167–174
- [31] Lumbroso S, Paris F, Sultan C. Activating Gsalpha mutations: analysis of 113 patients with signs of McCune-Albright syndrome – a European collaborative study. *J Clin Endocrinol Metab* 2004; 89: 2107–2113
- [32] Brown RJ, Kelly MH, Collins MT. Cushing syndrome in the McCune-Albright syndrome. *J Clin Endocrinol Metab* 2010; 95: 1508–1515
- [33] El Ghorayeb N, Bourdeau I, Lacroix A. Multiple aberrant hormone receptors in Cushing's syndrome. *Eur J Endocrinol* 2015; 173: M45–M60
- [34] Nieman LK, Biller BM, Findling JW et al. The diagnosis of Cushing's syndrome: an endocrine society clinical practice guideline. *J Clin Endocrinol Metab* 2008; 93: 1526–1540
- [35] Carney JA, Young WFJ. Primary pigmented nodular adrenocortical disease and its associated conditions. *Endocrinologist* 1992; 2: 6–21
- [36] Courcousakis NA, Tatsi C, Patronas NJ et al. The complex of myxomas, spotty skin pigmentation and endocrine overactivity (Carney complex): imaging findings with clinical and pathological correlation. *Insights Imaging* 2013; 4: 119–133
- [37] Vezzosi D, Tenenbaum F, Cazabat L et al. Hormonal, radiological, NP-59 scintigraphy, and pathological correlations in patients with Cushing's syndrome due to primary pigmented nodular adrenocortical disease (PPNAD). *J Clin Endocrinol Metab* 2015; 100: 4332–4338
- [38] Defilippi C, Chiappetta D, Marzari D et al. Image diagnosis in McCune-Albright syndrome. *J Pediatr Endocrinol Metab* 2006; 19: 561–570
- [39] Stratakis CA, Sarlis N, Kirschner LS et al. Paradoxical response to dexamethasone in the diagnosis of primary pigmented nodular adrenocortical disease. *Ann Intern Med* 1999; 131: 585–591
- [40] Espiard S, Vantyghem MC, Assié G et al. Frequency and incidence of Carney complex manifestations: a prospective multicenter study with a three-year follow-up. *J Clin Endocrinol Metab* 2020; 105: dgaa002. doi:10.1210/clinem/dgaa002
- [41] Bourdeau I, Parisien-La Salle S, Lacroix A. Adrenocortical hyperplasia: a multifaceted disease. *Best Pract Res Clin Endocrinol Metab* 2020; 34: 101386
- [42] Morio H, Terano T, Yamamoto K et al. Serum levels of dehydroepiandrosterone sulfate in patients with asymptomatic cortisol producing adrenal adenoma: comparison with adrenal Cushing's syndrome and non-functional adrenal tumor. *Endocr J* 1996; 43: 387–396
- [43] Hofland J, de Herder WW, Derks L et al. Regulation of steroidogenesis in a primary pigmented nodular adrenocortical disease-associated adenoma leading to virilization and subclinical Cushing's syndrome. *Eur J Endocrinol* 2013; 168: 67–74

- [44] Navarro Moreno C, Delestienne A, Marbaix E et al. Familial forms of Cushing syndrome in primary pigmented nodular adrenocortical disease presenting with short stature and insidious symptoms: a clinical series. *Horm Res Paediatr* 2018; 89: 423–433
- [45] Horvath A, Boikos S, Giatzakis C et al. A genome-wide scan identifies mutations in the gene encoding phosphodiesterase 11A4 (PDE11A) in individuals with adrenocortical hyperplasia. *Nat Genet* 2006; 38: 794–800
- [46] Horvath A, Giatzakis C, Tsang K et al. A cAMP-specific phosphodiesterase (PDE8B) that is mutated in adrenal hyperplasia is expressed widely in human and mouse tissues: a novel PDE8B isoform in human adrenal cortex. *Eur J Hum Genet* 2008; 16: 1245–1253
- [47] Kamilaris CDC, Faucz FR, Andriessen VC et al. First somatic PRKAR1A defect associated with mosaicism for another PRKAR1A mutation in a patient with Cushing syndrome. *J Endocr Soc* 2021; 5: bvab007
- [48] Tadjine M, Lampron A, Ouadi L et al. Detection of somatic beta-catenin mutations in primary pigmented nodular adrenocortical disease (PPNAD). *Clin Endocrinol* 2008; 69: 367–373
- [49] Storr HL, Mitchell H, Swords FM et al. Clinical features, diagnosis, treatment and molecular studies in paediatric Cushing's syndrome due to primary nodular adrenocortical hyperplasia. *Clin Endocrinol* 2004; 61: 553–559
- [50] Kumorowicz-Czoch M, Dolezal-Oltarzewska K, Roztoczynska D et al. Causes and consequences of abandoning one-stage bilateral adrenalectomy recommended in primary pigmented nodular adrenocortical disease – case presentation. *J Pediatr Endocrinol Metab* 2011; 24: 565–567
- [51] Ferreira SH, Costa MM, Rios E et al. Carney complex due to a novel pathogenic variant in the PRKAR1A gene – a case report. *J Pediatr Endocrinol Metab* 2019; 32: 197–202
- [52] Nieman LK, Biller BM, Findling JW et al. Treatment of Cushing's syndrome: an endocrine society clinical practice guideline. *J Clin Endocrinol Metab* 2015; 100: 2807–2831
- [53] Madani A, Lee JA. Surgical approaches to the adrenal gland. *Surg Clin North Am* 2019; 99: 773–791
- [54] Kiriakopoulos A, Linos D. Carney syndrome presented as a pathological spine fracture in a 35-year-old male. *Am J Case Rep* 2018; 19: 1366–1369
- [55] Yoshiaki Tanno F, Srougi V, Almeida MQ et al. A new insight into the surgical treatment of primary macronodular adrenal hyperplasia. *J Endocr Soc* 2020; 4: bvaa083
- [56] Zhang Y, Li H. Classification and surgical treatment for 180 cases of adrenocortical hyperplastic disease. *Int J Clin Exp Med* 2015; 8: 19311–19317
- [57] Zhang CD, Pichurin PN, Bobr A et al. Cushing syndrome: uncovering Carney complex due to novel PRKAR1A mutation. *Endocrinol Diabetes Metab Case Rep* 2019; 18–0150. doi:10.1530/EDM-18-0150 Online ahead of print
- [58] Guanà R, Gesmundo R, Morino M et al. Laparoscopic unilateral adrenalectomy in children for isolated primary pigmented nodular adrenocortical disease (PPNAD): case report and literature review. *Eur J Pediatr Surg* 2010; 20: 273–275
- [59] Cohen O, Bogat S, Dolitzki M et al. Successful pregnancy after unilateral adrenalectomy in a case of primary pigmented adrenocortical disease. *J Matern-Fetal Neonat Med* 2005; 17: 161–163
- [60] Zhu Y, Wu YX, Rui WB et al. Primary pigmented nodular adrenocortical disease report of 5 cases. *Zhonghua wai ke za zhi [Chin J Surg]* 2005; 43: 944–947
- [61] Pasternak-Pietrzak K, Stratakis CA, Moszczyńska E et al. Detection of new potentially pathogenic mutations in two patients with primary pigmented nodular adrenocortical disease (PPNAD) – case reports with literature review. *Endokrynol Pol* 2018; 69: 675–681
- [62] Iacobone M, Albiger N, Scaroni C et al. The role of unilateral adrenalectomy in ACTH-independent macronodular adrenal hyperplasia (AIMAH). *World J Surg* 2008; 32: 882–889
- [63] Vezzosi D, Cartier D, Régnier C et al. Familial adrenocorticotropin-independent macronodular adrenal hyperplasia with aberrant serotonin and vasopressin adrenal receptors. *Eur J Endocrinol* 2007; 156: 21–31
- [64] Lamas C, Alfaro JJ, Lucas T et al. Is unilateral adrenalectomy an alternative treatment for ACTH-independent macronodular adrenal hyperplasia?: Long-term follow-up of four cases. *Eur J Endocrinol* 2002; 146: 237–240
- [65] van der Pas R, de Herder WW, Hofland LJ et al. New developments in the medical treatment of Cushing's syndrome. *Endocr Relat Cancer* 2012; 19: R205–R223
- [66] Varlamov EV, Han AJ, Fleseriu M. Updates in adrenal steroidogenesis inhibitors for Cushing's syndrome – a practical guide. *Best Pract Res Clin Endocrinol Metab* 2021; 35: 101490
- [67] Castinetti F, Guignat L, Giraud P et al. Ketoconazole in Cushing's disease: is it worth a try? *J Clin Endocrinol Metab* 2014; 99: 1623–1630
- [68] Costenaro F, Rodrigues TC, de Lima PB et al. A successful case of Cushing's disease pregnancy treated with ketoconazole. *Gynecol Endocrinol* 2015; 31: 176–178
- [69] Boronat M, Marrero D, López-Plasencia Y et al. Successful outcome of pregnancy in a patient with Cushing's disease under treatment with ketoconazole during the first trimester of gestation. *Gynecol Endocrinol* 2011; 27: 675–677
- [70] Riedl M, Maier C, Zetting G et al. Long term control of hypercortisolism with fluconazole: case report and in vitro studies. *Eur J Endocrinol* 2006; 154: 519–524
- [71] Bertagna X, Pivonello R, Fleseriu M et al. LCI699, a potent 11 β -hydroxylase inhibitor, normalizes urinary cortisol in patients with Cushing's disease: results from a multicenter, proof-of-concept study. *J Clin Endocrinol Metab* 2014; 99: 1375–1383
- [72] Fleseriu M, Pivonello R, Young J et al. Osilodrostat, a potent oral 11 β -hydroxylase inhibitor: 22-week, prospective, phase II study in Cushing's disease. *Pituitary* 2016; 19: 138–148
- [73] Skalhogg BS, Tasken K. Specificity in the cAMP/PKA signaling pathway. Differential expression, regulation, and subcellular localization of subunits of PKA. *Front Biosci* 2000; 5: D678–D693
- [74] Kirschner LS, Sandrini F, Monbo J et al. Genetic heterogeneity and spectrum of mutations of the PRKAR1A gene in patients with the carney complex. *Hum Mol Genet* 2000; 9: 3037–3046
- [75] Casey M, Vaughan CJ, He J et al. Mutations in the protein kinase A R1 α regulatory subunit cause familial cardiac myxomas and Carney complex. *J Clin Invest* 2000; 106: R31–R38
- [76] Kirschner LS, Carney JA, Pack SD et al. Mutations of the gene encoding the protein kinase A type I- α regulatory subunit in patients with the Carney complex. *Nat Genet* 2000; 26: 89–92
- [77] Berthon AS, Szarek E, Stratakis CA. PRKACA: the catalytic subunit of protein kinase A and adrenocortical tumors. *Front Cell Develop Biol* 2015; 3: 26
- [78] de Joussineau C, Sahut-Barnola I, Tissier F et al. mTOR pathway is activated by PKA in adrenocortical cells and participates in vivo to apoptosis resistance in primary pigmented nodular adrenocortical disease (PPNAD). *Hum Mol Genet* 2014; 23: 5418–5428
- [79] Mavrakis M, Lippincott-Schwartz J, Stratakis CA et al. Depletion of type IA regulatory subunit (R1 α) of protein kinase A (PKA) in mammalian cells and tissues activates mTOR and causes autophagic deficiency. *Hum Mol Genet* 2006; 15: 2962–2971
- [80] Sahut-Barnola I, de Joussineau C, Val P et al. Cushing's syndrome and fetal features resurgence in adrenal cortex-specific Prkar1a knockout mice. *PLoS Genet* 2010; 6: e1000980

- [81] Liu S, Saloustros E, Berthon A et al. Celecoxib reduces glucocorticoids in vitro and in a mouse model with adrenocortical hyperplasia. *Endocrinol Relat Cancer* 2016; 23: 15–25
- [82] Le Mestre J, Duparc C, Reznik Y et al. Illicit upregulation of serotonin signaling pathway in adrenals of patients with high plasma or intra-adrenal ACTH levels. *J Clin Endocrinol Metab* 2019; 104: 4967–4980
- [83] Ralser DJ, Strizek B, Kupczyk P et al. Obstetric and neonatal outcome of pregnancy in Carney complex: a case report. *Front Endocrinol* 2020; 11: 296
- [84] Spaniol A, Mulla BM, Daily JG et al. Carney complex: a rare cause of Cushing syndrome in pregnancy. *Obstetr Gynecol.* 2014; 124: 426–428
- [85] Schulz S, Redlich A, Köppe I et al. Carney complex – an unexpected finding during puerperium. *Gynecol Obstetr Invest* 2001; 51: 211–213
- [86] Caticha O, Odell WD, Wilson DE et al. Estradiol stimulates cortisol production by adrenal cells in estrogen-dependent primary adrenocortical nodular dysplasia. *J Clin Endocrinol Metab* 1993; 77: 494–497
- [87] Brue T, Amodru V, Castinetti F. Management of endocrine disease: management of Cushing's syndrome during pregnancy: solved and unsolved questions. *Eur J Endocrinol* 2018; 178: R259–R266
- [88] Caimari F, Valassi E, Garbayo P et al. Cushing's syndrome and pregnancy outcomes: a systematic review of published cases. *Endocrine* 2017; 55: 555–563
- [89] Lim WH, Torpy DJ, Jeffries WS. The medical management of Cushing's syndrome during pregnancy. *Eur J Obstetr Gynecol Reprod Biol* 2013; 168: 1–6