

Safety and efficacy of microwave ablation for breast cancer thoracic metastases

Bin Liu^{1,*}
Zhenjie Wu^{1,*}
Hao Mo^{1,*}
Juliang He¹
Xiang Lin¹
Jian Guan¹
Changyuan Wei^{2,*}
Zhenchao Yuan^{1,*}

¹Department of Bone and Soft Tissue Neurosurgery, Affiliated Tumor Hospital of Guangxi Medical University, Nanning 530021, Guangxi, People's Republic of China;

²Department of Breast Tumor Surgery, Affiliated Tumor Hospital of Guangxi Medical University, Nanning 530021, Guangxi, People's Republic of China

*These authors contributed equally to this work

Background: The objective of the study was to assess the safety and efficacy of microwave ablation (MWA) for breast cancer thoracic metastasis.

Materials and methods: Twelve patients in our institution with a single lesion of breast cancer thoracic metastases received MWA and invasive spine surgery from August 2014 to November 2016. MWA was executed using the MWA system (2,450 MHz) at 40 W or 50 W with thermometers to control the ablation end points. The pathology of thoracic metastases was confirmed through intraoperative biopsy before ablation. The postoperative complications were recorded. The patients were followed up at 1, 3 and 6 months with contrast-enhanced computed tomography and magnetic resonance imaging to monitor for tumor recurrence.

Results: The average duration of follow-up for breast cancer thoracic metastases patients (mean age 52.7±8.4 years) was 10.2 months. The rate of postoperative main complications was 8.3% (1/12). The recurrence rate was 16.6% (2/12) as confirmed by persistent enhancement.

Conclusion: MWA may be used as the adjuvant treatment for thoracic metastases of breast cancer. Results showed that few significant complications and less local recurrence occurred during the follow-up stage. Future research should aim at discovering more about the time controls for microwave–tissue interaction and treatment parameters before widespread use.

Keywords: breast cancer, thoracic metastasis, microwave ablation, complication

Introduction

Spinal metastasis is the most common tumor in the spinal system. The most common histologies for spinal metastases are the breasts, the lungs and the prostate.¹ The compression or invasion of the spinal cord and/or nerve roots is the most common presentation in patients with advanced-stage cancer. Although affected patients with spinal tumor burdens can be treated with laminectomy, quality of life is not actually enhanced after such treatment. Surgical interventions are palliative rather than curative for most patients because of the frequent local recurrence of the tumor. Radiation therapy is still needed after surgery. In clinical practice, postoperative chemotherapy in some patients is more urgent than radiation therapy. Therefore, the reduction of postoperative recurrence has become a priority in these patients. Microwave ablation (MWA) therapy has been widely used in treating liver tumors, but it has been rarely reported in spinal metastases treatment. Given the long survival period of breast cancer patients and the superficial thoracic anatomic position, treating thoracic metastases with MWA is beneficial and easy. Therefore, this study was designed to assess the feasibility and outcome of MWA performed for patients with breast cancer thoracic metastases. It aimed to assess the safety and short-term efficacy of MWA in patients with breast cancer thoracic metastases.

Correspondence: Changyuan Wei
Department of Breast Tumor Surgery,
Affiliated Tumor Hospital of Guangxi
Medical University, No. 71, He Di Road,
Nanning 530021, Guangxi, People's
Republic of China
Email doctorwei2017@126.com

Zhenchao Yuan
Department of Bone and Soft Tissue
Neurosurgery, Affiliated Tumor Hospital
of Guangxi Medical University, No. 71
He Di Road, Nanning 530021, Guangxi,
People's Republic of China
Email ZhenchaoYuan2018@yeah.net

Materials and methods

Patients

The clinical data of all patients with a single lesion of breast cancer thoracic metastases treated with MWA between August 2014 and November 2016 in our institution were collected and reviewed. The patients with the following criteria were included in the study: Tokuhashi score greater than 8 with definite indications for operation (pathological compression fractures, mechanical instability, radiological and/or clinical metastatic spinal cord compression). The relevant human materials were reviewed and approved by the ethics committee of the Affiliated Tumor Hospital of Guangxi Medical University, and the study is deemed to meet the medical ethical requirements. All patients provided their written informed consent for the publication of the accompanying images and for this study.

Procedure

A posterior or lateral approach was used in patients undergoing breast cancer thoracic metastases surgery. After the

exposure of the thoracic metastases lesions with decompression and a posterior internal fixation with a screw-rod system, the 2,450 MHz MWA system (ECO-100A1, YiGao Medical Instruments, Nanjing, People's Republic of China) was used with antennae. Single or double MWA surgical antennae were introduced through a vertebral pedicle using X-ray guidance (Table 1). Thermal sensors were laid at the vertebral anterior, vertebral center and vertebral posterior margin. Before ablation with the antennae in place, a tissue biopsy was performed with a biopsy needle under C-arm guidance (Figure 1). The microwave antenna was inserted into the vertebral body through a vertebral pedicle, and MWA was typically started with simultaneous thermometry until the treatment end point of 45°C. Ablation was conducted at 40 W or 50 W for 15–30 minutes of ablation depending on whether the ablation temperature reached the target temperature (Table 1). The remainder of the procedure was identical to the thoracic spine decompression surgery procedure.

Table 1 Tumor characteristics and procedure characteristics

Patient number	Age (y)	Tumor location	MWA power setting (w)	MWA time (min)	No. of antenna (n)	Neurological symptoms and imaging (mo)			Recurrence	Clinical follow-up (mo)
						1	3	6		
1	41	T2	50	15	1	N	N	P	Yes	8
2	46	T8	50	20	1	N	N	N	No	11
3	43	T9	50	15	2	N	P	P	No	10
4	53	T11	40	20	1	N	N	N	No	6
5	51	T8	50	25	1	N	N	N	No	12
6	55	T11	50	20	2	N	N	N	No	9
7	53	T10	50	15	1	N	N	N	No	13
8	59	T5	40	20	1	N	N	N	No	14
9	55	T8	50	25	2	N	N	P	Yes	15
10	44	T10	50	30	1	N	N	N	No	10
11	65	T12	40	15	2	N	N	N	No	6
12	68	T4	50	20	1	N	N	N	No	9

Abbreviations: MWA, microwave ablation; N, negative; P, positive; T, thoracic vertebrae.

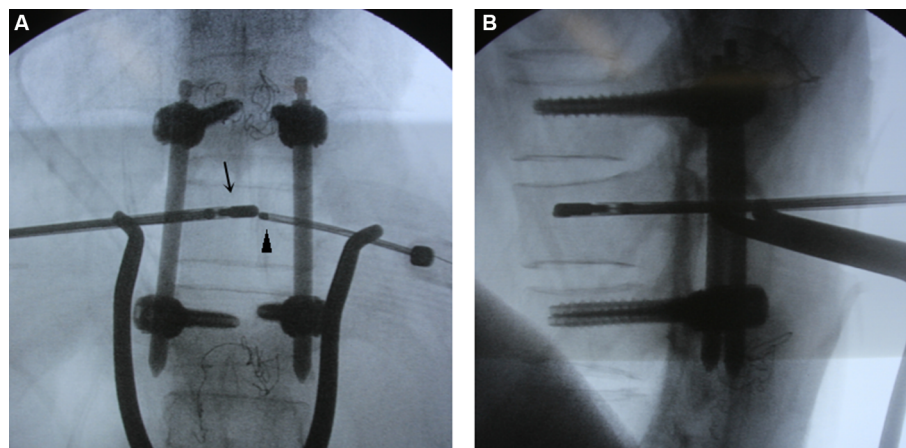


Figure 1 Microwave ablation therapy for breast cancer thoracic metastasis ([A] anteroposterior film; [B] lateral film).

Note: The microwave ablation needle (arrow) inserts into vertebral metastases by the pedicle with C-arm-assisted navigation for improving accuracy of position, and thermal sensor (arrow head) is situated in the vertebral center, monitoring the vertebral center temperature.

Imaging follow-up and data recording

The following data were collected and recorded in a computerized database. Surgical prognosis was appraised using the ASIA impairment scale and thoracic vertebra contrast-enhanced computed tomography and magnetic resonance imaging at 1, 3 and 6 months after operation (Table 1). A complication was described as any adverse event after MWA, including fever, acute pain, nerve injury and leakage of cerebrospinal after the surgery. Treatment recurrence was defined as any recurrence (including neurological symptoms and imaging) in the breast cancer thoracic spine after MWA treatment. Complications were graded according to the Common Terminology Criteria for Adverse Events (Version 5.0). The variables were expressed as the mean \pm SD. Patient treatment outcomes were measured in terms of complication rate and recurrence rate.

Results

Characteristics of patients

The patient tumor characteristics and procedure characteristics are summarized in Table 1. During the study period, 12 female patients with an average age of 52.7 ± 8.4 years (range: 41–68 years) underwent MWA for breast cancer thoracic metastases. The average ablation time was 20.0 ± 4.7 minutes (range: 15–30 minutes). All patients were followed up after surgery.

Procedure-related complications and recurrence rate

Among the 12 patients, major complications were observed only in one (8.3%): a nerve injury that required medical intervention. The patient eventually recovered. All the other patients with other complications recovered within 1 week after appropriate symptomatic treatments (Table 2). For all the patients, the recurrence rate was 16.6% (2/12). During a mean follow-up period of 10.2 months (range: 6–15 months), one patient developed local tumor progression at the MWA site within 3 months after ablation and one patient developed local tumor progression at the MWA site within 6 months after ablation. At the end of

the study, no postoperative complications were observed (Table 1).

Discussion

Posterior laminectomy has been used since the 1980s to improve the local control of spinal metastases in tumor patients with severe neurological deficits.² The elimination of spinal cord compression caused by spinal metastases is the goal of the treatment. Even if spinal metastases surgery is initially successful, it could ultimately fail because of short- and intermediate-term local recurrence. The traditional surgery treatment recurrence rate for spinal metastases is high. Therefore, most patients need further radiotherapy to control the progression of the tumor. In 1995, Hellman and Weichselbaum proposed a new term, “oligometastases,” to describe the local control of the metastatic tumor.³ For oligometastases, patients show distant relapse in a limited number of regions. Local treatment, such as surgery, radiotherapy and ablation, can significantly improve the quality of life of patients. New techniques for tissue destruction have been created with rapid technological developments, such as microwaves. MWA has been applied to control multitudinous tumors with fewer complications^{4–7} and it has been investigated in the treatment of spinal metastases.⁸ However, data on the safety and efficacy of MWA combined with open surgery as a palliative treatment for spinal metastases are still lacking. The study chose thoracic spine metastases of breast cancer to further verify the safety and efficiency of MWA.

The most important safety predictors of microwave therapy are the needle position and the ablation temperature. The needle position is the most significant independent factor related to the increased risk for ablation failure in lesions of breast cancer thoracic metastases. Moreover, the main problem associated with efficacy is the relatively restricted ablation scope. In this study, after surgical decompression for the posterior column of the spine, the anterior spinal metastases can be destroyed with a single antenna or double antennae in the right position through the vertebral pedicles. The pedicle approach is the most efficient and the safest method for

Table 2 Complications of MWA

MWA complication n/12 (%)	CTCAE-graded toxicity				
	Grade 1	Grade 2	Grade 3	Grade \geq 4/5	All grades
Fever	4 (33.3)	3 (25.0)	0	0	7 (58.3)
Acute pain	4 (33.3)	2 (16.7)	0	0	6 (50.0)
Nerve injury	1 (8.33)	0	0	0	1 (8.33)
Leakage of cerebrospinal	1 (8.33)	2 (16.7)	0	0	3 (25.0)

Abbreviations: CTCAE, Common Terminology Criteria for Adverse Events (Version 5); MWA, microwave ablation.

preventing nerve injury. Moreover, temperature is the most predominant environmental factor in causing injury to living cells. The upper lethal temperature for plants and animals is less than 50°C. When temperatures reach 60°C–100°C, the instantaneous induction of protein coagulation induces irreversible damage to key cytosolic and mitochondrial enzymes as well as to the nucleic acid–histone protein complex.⁹ Thus, the key goal of ablative therapies is theoretically achieving and maintaining a 60°C–100°C temperature in the center of the vertebral body within a controllable range. Studies have proved that heating nervous tissue at 45°C for 10.8 minutes causes 50% damage.^{10,11} To protect the spinal cord, portions of spinal metastases do not reach the 60°C–100°C temperature during ablation. A non-uniform ablation zone refers to the tissue and water content heterogeneity between different spinal metastatic carcinomas. Based on the above restrictions, repeated ablation remains the primary treatment modality for thoracic metastatic carcinomas in the short-term to avoid unremitting high temperature. This study proved the safety of ablation treatment for breast cancer thoracic metastases. Few complications were observed in the MWA procedure, and all patients tolerated the procedure well. Procedure-related nerve injury was defined as limb paresthesia or leg weakness and occurred infrequently (1/12, 8.33%).

In this study, all the patients suffered from compression or invasion of the tumor or were at risk of being compressed or invaded. The goal of local control was to prevent tumor progress and/or to reduce tumor bulk. The findings of this study suggest that MWA has distinct advantages in the local control of breast cancer thoracic metastases. First, in the electromagnetic environment, a high intratumoral temperature is produced by the agitation of water molecules. Consequently, MWA causes cellular death through coagulation necrosis. Therefore, microwaves have the advantage of deeper penetration, which is insensitive to impedance. The use of microwaves is extremely beneficial to bone, given its high impedance for less energy deposition. In contrast to MWA, radiofrequency ablation (RFA) has physical limitations in bone. Similarly, carbonization secondary to temperature changes limits electrical conduction. Many studies have demonstrated that MWA takes less time to treat bone lesions than RFA.^{8,12,13} Second, previous studies showed that microwaves have no direct effect on revascularization and new bone formation¹⁴ and that osteoconduction properties do not change after heat necrosis. The devitalized osseous structure provides an effective biological scaffold for reconstruction. To reduce the risk of a vertebral

body pathological fracture, the scope of resection should be limited to 30% or less in the vertebral body. Furthermore, cementoplasty can be performed in association with MWA to prevent pathological fracture and defend against metastatic tumor development.¹⁵ Third, MWA is suitable for use in areas that have been previously irradiated and areas near the spinal cord, where radiation therapy is contraindicated. The efficacy of MWA has been increasingly demonstrated in larger tumors. During the follow-up period in this study, one patient presented with breast cancer thoracic spine recurrence evidenced by new tumors at 3 months and one patient presented with spine recurrence evidenced by new tumors at 6 months. The 6-month 16.6% recurrence rate of target thoracic spine metastases demonstrates that MWA is an effective local treatment in patients with breast cancer thoracic spine metastases.

Until now, experience with breast cancer thoracic metastases treatment using microwaves remains limited. Breast cancer thoracic metastases lesions are adjacent to the spinal cord and require small ablation zones that many systems cannot provide. The smaller ablation areas can be produced by modulating energy and time. The application of this method makes ablation for the surrounding metastasis tissue of the spinal cord feasible. This work is a small sample study without long-term follow-up and a control group. Therefore, larger prospective, randomized trials of ablation for breast cancer thoracic metastases cases are needed, and longer follow-up periods are required in the future.

Conclusion

Our data suggest that MWA may be considered an alternative therapy in breast cancer thoracic metastases cases. The results show that MWA can be performed with less complications and help to control local recurrence in breast cancer thoracic metastases cases, especially those located in the center of the spinal vertebral body, because lesions are at a safe distance from neurological and vascular non-target structures in this location. Furthermore, future studies are required to evaluate how to control microwave energy and time to further improve the safety and efficacy of treatment for breast cancer thoracic metastases.

Acknowledgments

We would like to thank the patients and families involved in this study. This work was supported by the Guangxi self-funded research project (grant numbers Z20170425 and Z20170428).

Disclosure

The authors report no conflicts of interest in this work.

References

1. Jemal A, Thun MJ, Ries LA, et al. Annual report to the nation on the status of cancer, 1975-2005, featuring trends in lung cancer, tobacco use, and tobacco control. *J Natl Cancer Inst.* 2008;100(23):1672-1694.
2. Nordlinger B, De Sena G, Szawlowski A, et al. Surgical resection of hepatic metastases of cancers of the colon and rectum. *Gastroenterol Clin Biol.* 1983;7(3):240-243.
3. Hellman S, Weichselbaum RR. Oligometastases. *J Clin Oncol.* 1995;13(1):8-10.
4. Kastler A, Alnassan H, Pereira PL, et al. Analgesic effects of microwave ablation of bone and soft tissue tumors under local anesthesia. *Pain Med.* 2013;14(12):1873-1881.
5. Goldberg SN, Gazelle GS, Compton CC, Mueller PR, Tanabe KK. Treatment of intrahepatic malignancy with radiofrequency ablation: radiologic-pathologic correlation. *Cancer.* 2000;88(11):2452-2463.
6. Froese G, Das RM, Dunscombe PB. The sensitivity of the thoracolumbar spinal cord of the mouse to hyperthermia. *Radiat Res.* 1991;125(2):173-180.
7. Letcher FS, Goldring S. The effect of radiofrequency current and heat on peripheral nerve action potential in the cat. *J Neurosurg.* 1968;29(1):42-47.
8. Goetz MP, Callstrom MR, Charboneau JW, et al. Percutaneous image-guided radiofrequency ablation of painful metastases involving bone: a multicenter study. *J Clin Oncol.* 2004;22(2):300-306.
9. Kastler A, Alnassan H, Aubry S, Kastler B. Microwave thermal ablation of spinal metastatic bone tumors. *J Vasc Interv Radiol.* 2014;25(9):1470-1475.
10. Kastler B, Jacamon M, Aubry S, et al. Combined bipolar radiofrequency and cementoplasty of bone metastases. *J Radiol.* 2007;88(9 Pt 2):1242-1247.
11. Pusceddu C, Sotgia B, Fele RM, Melis L. Treatment of bone metastases with microwave thermal ablation. *J Vasc Interv Radiol.* 2013;24(2):229-233.
12. Munk PL, Murphy KJ, Gangi A, Liu DM. Fire and ice: percutaneous ablative therapies and cement injection in management of metastatic disease of the spine. *Semin Musculoskelet Radiol.* 2011;15(2):125-134.
13. Deschamps F, Farouil G, Hakime A, Teriitehau C, Barah A, de Baere T. Percutaneous stabilization of impending pathological fracture of the proximal femur. *Cardiovasc Intervent Radiol.* 2012;35(6):1428-1432.
14. Si ZM, Wang GZ, Qian S, et al. Combination Therapies in the Management of Large (≥ 5 cm) Hepatocellular Carcinoma: Microwave Ablation Immediately Followed by Transarterial Chemoembolization. *J Vasc Interv Radiol.* 2016;27(10):1577-1583.
15. Thamtorawat S, Hicks RM, Yu J, et al. Preliminary Outcome of Microwave Ablation of Hepatocellular Carcinoma: Breaking the 3-cm Barrier? *J Vasc Interv Radiol.* 2016;27(5):623-630.

Cancer Management and Research

Publish your work in this journal

Cancer Management and Research is an international, peer-reviewed open access journal focusing on cancer research and the optimal use of preventative and integrated treatment interventions to achieve improved outcomes, enhanced survival and quality of life for the cancer patient. The manuscript management system is completely online and includes

Submit your manuscript here: <https://www.dovepress.com/cancer-management-and-research-journal>

a very quick and fair peer-review system, which is all easy to use. Visit <http://www.dovepress.com/testimonials.php> to read real quotes from published authors.

Dovepress