

REVIEW

Robotic partial nephrectomy: The new horizon

Humberto Laydner, Jihad H. Kaouk *

Center for Laparoscopic and Robotic Surgery – Urology, Cleveland Clinic Foundation, Cleveland, OH, United States

Received 11 October 2011, Received in revised form 25 October 2011, Accepted 25 October 2011

Available online 20 December 2011

KEYWORDS

Robotics;
Partial nephrectomy;
Kidney neoplasms;
Laparoscopic;
Nephron-sparing

ABBREVIATIONS

RPN, (robotic) partial nephrectomy; RN, radical nephrectomy; WIT, warm ischaemia time; EBL, estimated blood loss; LOS, length of stay; eGFR, estimated GFR; NSS, nephron-sparing surgery; BMI, body mass index

Abstract Background: There has been an exponential growth in the reporting of series of robotic partial nephrectomy (RPN). We review the technique of RPN and the outcomes from large single-centre series of RPN.

Methods: We searched databases to identify original articles related to RPN. For the technical aspects, we describe our technique and provide a general review of previous work. For outcomes, we reviewed previous reports using more rigid criteria, including only single-institution studies with at least 50 patients undergoing RPN.

Results: We found seven retrospective studies that met our criteria, with a total of 701 patients. Mean tumour size was 2.8 cm, with an average R.E.N.A.L. score (Radius, tumour size as maximum diameter; Exophytic/endophytic properties of the tumour, Nearness of tumour deepest portion to the collecting system or sinus, Anterior, a/posterior, p, descriptor, and the Location relative to the polar line) of 6.8. The mean warm ischaemia time was 21 min and mean operative duration was 196 min. The mean estimated blood loss was 182 mL, with a 7.4% transfusion rate.

* Corresponding author. Address: Glickman Urology and Kidney Institute/Q10-1, Cleveland Clinic, 9500 Euclid Avenue, Cleveland, OH 44195, United States. Tel.: +1 216 444 2976; fax: +1 216 445 7031.
E-mail address: kaoukj@ccf.org (J.H. Kaouk).



The conversion rate was 1.7% and the postoperative complication rate was 14%. The mean length of stay was 3.6 days. There were positive surgical margins in 1.7% of patients. The mean decrease in renal function was 5.4% and the mean follow-up was 8.4 months.

Conclusions: RPN is feasible and safe for different levels of complexity of renal tumours. Perioperative outcomes are comparable to those found with more established techniques. Future studies should compare different approaches and prioritise prospective and randomised designs.

© 2012 Arab Association of Urology. Production and hosting by Elsevier B.V.
All rights reserved.

Introduction

Over the past 20 years the diagnosis of RCC has increased [1–3], thought to be secondary to the expanded use of abdominal imaging, accompanied by an increased incidence of the disease [4]. Radical nephrectomy (RN) has been considered for decades as the primary treatment for renal masses, including stage 1 tumours. However, studies have shown that RN is associated with a greater risk of overall mortality and cardiovascular events after surgery than for partial nephrectomy (PN) [5,6]. Previously, Go et al. [7] reported an association between reduced GFR and the risk of death, cardiovascular events, and hospitalisation.

Since its development, nephron-sparing surgery (NSS) has increasingly gained acceptance, showing oncological outcomes similar to those of RN [8–10]. Currently it is considered in many major guidelines as the primary treatment for managing small (T1a) renal lesions [11,12]. In addition, there is increasing evidence supporting the use of NSS for higher-stage lesions, with improved overall survival and similar cancer-specific survival compared with RN [13–15]. The improved overall survival after NSS was also reported in patients with unanticipated benign renal tumours on final pathology [16].

The laparoscopic approach to NSS for localised RCC has been well documented [17,18]. However, there are still concerns about warm ischaemia time (WIT), risk of haemorrhage and urinary fistula and the technically demanding nature of the procedure.

The robotic platform has been incorporated into routine use at numerous urology centres. Initially, the advantages, including improved visibility, ergonomics and relative simplicity with suturing, led to the wide acceptance of robotic radical prostatectomy. However, the benefits of the robotic platform and their applicability to kidney surgery subsequently became apparent, and have been applied increasingly to kidney surgery including robotic pyeloplasty and robotic PN (RPN). Here we review the technique of RPN and the outcomes from large single-centre series of RPN.

Methods

We searched databases to identify original articles related to RPN, using several query terms, and all relevant English language papers were reviewed. Initially, we focus on the technical aspects of RPN, describing our technique and adding comments on articles describing other authors' techniques in general, with no systematic selection of articles.

To review the outcomes of RPN we defined formal criteria. To avoid analysing series that would represent mainly the initial learning curve of surgeons with RPN, we included only single-institution studies with at least 50 patients undergoing RPN. We also excluded any overlapping cohorts. We analysed patient characteristics before RPN, and the outcomes during and after RPN.

Surgical technique

The patient is placed in a 60° modified flank position, with the table flexed and a slight Trendelenburg tilt. With the patient secured to the table, the pressure points are padded and the abdomen is insufflated to 15 mmHg. We use the transperitoneal route, as do most of the RPN series reported. A retroperitoneal approach has also been described [19].

Port configuration can be modified according to the patient's anatomy and surgeon's preference. At the level of the 12th rib, a pararectal incision is made and a 12-mm port is placed for the endoscope. At ≈3 cm below the costal margin, an 8-mm port is placed at the lateral border of the ipsilateral rectus muscle. Then another 8 mm port is placed 5–7 cm cephalad to the anterior superior iliac spine. Along the lateral border of the rectus muscle, an assistant 12-mm port is placed in the lower abdominal quadrant. A 5-mm port is placed in the subxiphoid area for liver retraction for right-sided cases (Fig. 1). The robot is positioned over the patient's shoulder. Instruments used consist of a 30° down endoscope, a robotic grasper in the left arm, and a monopolar scissors or a hook in the right arm. We do not use the

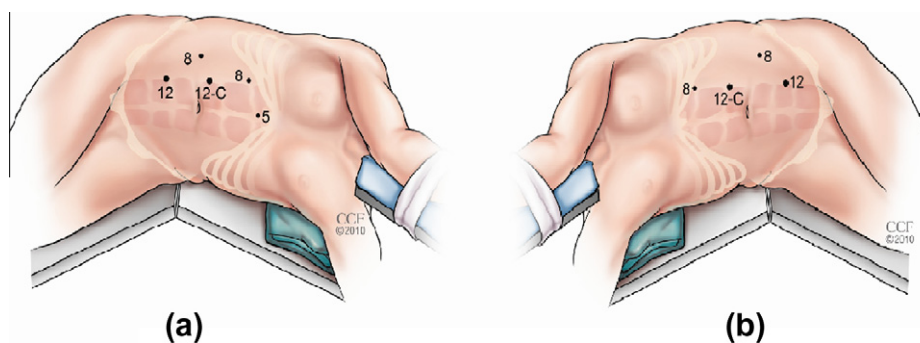


Figure 1 Positioning of the trocars for right (a) and left (b) RPN.

fourth robotic arm, but its use has been described for RPN [20].

For mobilisation of the bowel, a plane is developed between the mesocolon and the Gerota's fascia. After medial reflection of the colon, the dissection progresses cephalad to mobilise the spleen or liver.

For renal hilum dissection, the ureter and gonadal vein are elevated anteriorly and dissection continues cephalad until the renal hilum is identified. The hilar vessels are cautiously dissected to allow for occlusion with bulldog or Satinsky clamps.

Gerota's fascia is opened and the mass is identified and exposed. The tumour is de-fatted circumferentially around the mass to allow visualization of 2 cm of normal parenchyma, leaving the overlying Gerota's fascia atop the mass whenever possible for histopathological staging. It can also be used to aid retraction. Intraoperative ultrasonography is used to plan excision margins. The capsule is scored, delineating the limits for resection.

Before hilar occlusion, 12.5 g of mannitol is given intravenously. Usually, we clamp both the artery and vein individually with bulldog clamps. These have the advantage of not occupying an instrument port. Disadvantages include the requirement of an experienced assistant and optimal alignment. If a complex vascular anatomy is present with multiple arterial branches, or if dissection is exceedingly difficult, we then occlude the hilum en bloc with a Satinsky clamp. The disadvantages include port occupancy and the potential of vascular damage if a robot arm inadvertently hits the Satinsky externally. Ho et al. [21] described the use of a device consisting of a vascular loop and a rubber tube held in place by a Hem-o-Lok clip, avoiding the disadvantages of bulldogs and Satinsky clamps, while providing the advantage of maintaining vascular control with the console surgeon.

Tumour resection

Whenever possible, we resect exophytic tumours with minimal cortical involvement without hilar clamping,

using Hem-o-Lok clips to control bleeding vessels from the parenchyma. In 2009, we reported a RPN technique under renal perfusion conditions [22]. Although there was greater blood loss in the off-clamp group, it was not translated into significantly higher transfusion rates. In the same year, Nadler et al. [23] described a hybrid procedure, combining robotic surgery, intraoperative laparoscopic ultrasonography, and radiofrequency ablation to perform clamp-less PN. Moinzadeh et al. [24], in an animal model study, developed a technique of angiographic selective reversible occlusion of renal artery branches during RPN. The concept of selective occlusion of segmental renal arteries was previously described for laparoscopic and open PN [25,26]. In 2008, Nohara et al. [26] reported 18 PNs using selective clamping of the tumour's feeding artery, including two hilar tumours. In 2011, several reports from one institution focused on NSS with no overall renal ischaemia, including 21 RPNs, using pharmacologically-induced hypotension, selective clamping, or the combination of both techniques [27].

However, the notion that WIT must be shortened as much as possible, or even abolished, to preserve renal function was recently questioned. Lane et al. [28] evaluated the predictive factors of postoperative renal function after 660 PNs in patients with solitary kidneys. After including in the analysis the percentage of parenchyma preserved, neither ischaemia type, ischaemia time, the interaction between type and time, nor the propensity for cold ischaemia were significantly associated with early postoperative or latest GFR ($P = 0.08$). The strongest predictors of postoperative renal function were preoperative GFR and percentage of parenchyma preserved ($P < 0.001$). Another study from Simmons et al. [29] supports the idea that the percentage of functional volume preserved has a predominant role in late renal function outcomes. Using a new cylindrical volume-ratio method to estimate the percentage of functional volume preserved, they developed a model to predict postoperative GFR. The correlation between the predicted and the observed late GFR was 96%.

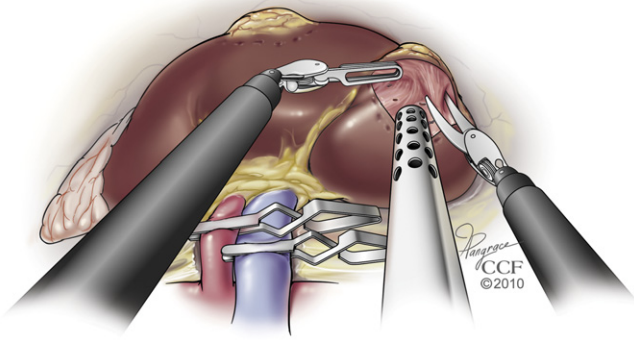


Figure 2 Tumour resection.

These studies suggest that WIT might simply be a surrogate endpoint associated with tumour complexity and proportion of kidney preserved, rather than the causative factor for renal functional decrease after NSS. If further studies confirm these findings, there might be another major change in the field of kidney surgery, without the ‘demonisation’ of transient ischaemia. Relieving the pressure to re-perfuse the kidney as quickly as possible would certainly be a welcome change in routine, although it is unlikely that surgeons would shift to the opposite extreme, making liberal use of prolonged ischaemia times.

The tumour is resected along the previously scored margin with cold scissors, while the bedside assistant

uses suction both to clear the resection bed and to apply slight counter retraction (Fig. 2). If two or more tumours are present in the same kidney and if there is an intersection between their resection margins, they are excised en bloc [30]. The overlying perinephric fat and a small margin of normal renal parenchyma are resected en bloc with the tumour. Mottrie et al. [31] were the first to describe a robotic tumour enucleoresection technique, identifying a plane 0.5 cm away of the tumour and dissecting almost exclusively bluntly. Later, Boris et al. [32] also reported a RPN enucleating technique for hereditary multiple tumours. RPN in the setting of complex tumours was first described by Rogers et al. [33] in eight complex cases, including hilar tumours, endophytic tumours and multiple tumours.

Reconstruction

We close the excision bed using a running 20 cm 2–0 polyglactin suture with a knot and Hem-o-Lok clip at the free end. This first layer of suture achieves haemostasis and closes the collecting system. The renal vessels are unclamped and the tumour bed is inspected for haemostasis. The main modification we made in our technique is related to the capsular closure. Previously, we used to place interrupted 0 polyglactin sutures over a cellulose bolster, with each suture being secured with two Hem-o-Lok clips. In our contemporary technique, we re-approximate the capsule with a continuous, horizontal

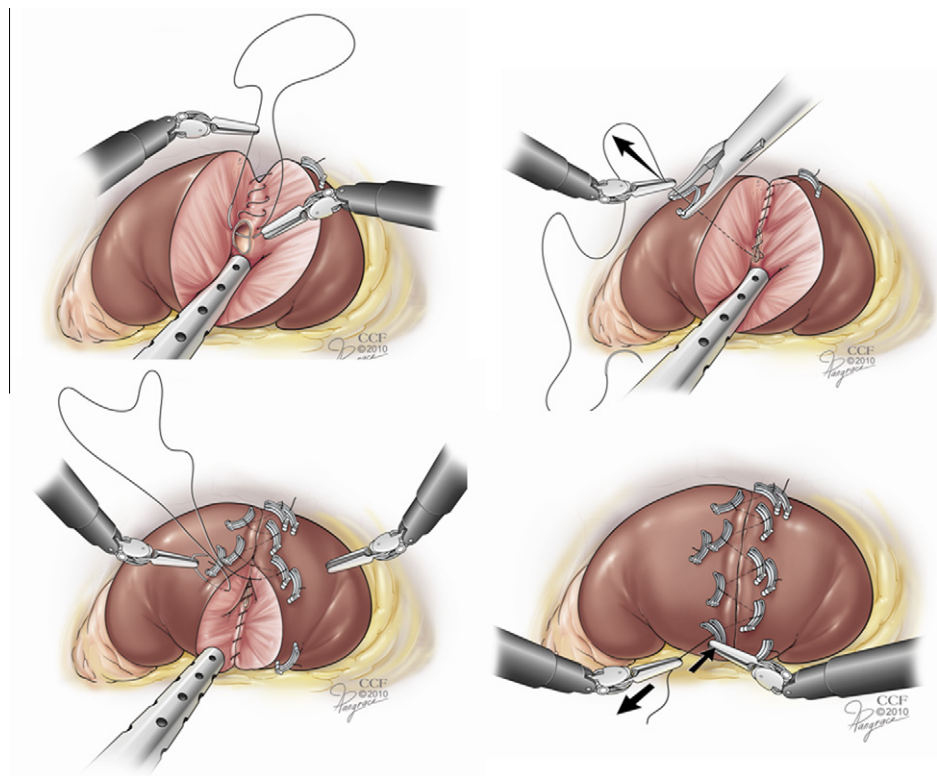


Figure 3 Our current renorrhaphy technique.

mattress 0 polyglactin suture, placing a sliding clip after each suture passed through the capsule, allowing a more uniform parenchymal compression (Fig. 3).

The specimen is removed from a lower quadrant port inside a laparoscopic sac. The incisions are closed using the Carter Thomason device with a 0 polyglactin suture. A Jackson-Pratt drain is placed.

Results

We found seven retrospective studies that met our criteria. Taken together, the studies included a total of 701 patients. The patients' demographics and the radiographic characteristics of the tumours are shown in Table 1 [34–40]. The mean tumour size was 2.8 cm, with an average RENAL score (Radius, tumour size as maximum diameter; Exophytic/endophytic properties of the tumour, Nearness of tumour deepest portion to the collecting system or sinus, Anterior, a/posterior, p, descriptor, and the Location relative to the polar line) of 6.8. The overall results are also detailed in Table 1. The mean WIT was 21 min, the mean operative duration 196 min, the mean estimated blood loss (EBL) 182 mL, with a 7.4% transfusion rate. Conversions were reported for 1.7% of the procedures and the postoperative complication rate was 13%, with a mean length of hospital stay (LOS) of 3.6 days. From a total of 93 postoperative complications, 69% were related to bleeding or other cardiovascular causes. Most of the complications (73%) were grade 1 and 2, according to the Clavien-Dindo classification [41]. Urological complications included urinary leak, urinary retention, pyelonephritis, and perinephric

collection. Most of these patients were managed conservatively, but a few required percutaneous drainage or urinary stenting. While most of the bleeding complications were managed successfully with blood transfusion, eight patients required either selective embolization of small renal vessels or re-intervention. There was one death due to acute myocardial infarction during closure. Other life-threatening complications included seven pulmonary embolisms, one nonfatal myocardial infarction, and four cases of acute renal failure requiring haemodialysis. Positive surgical margins were found in 1.7% of the cases and the mean decrease in renal function was 5.4%, with a mean follow-up of 8.4 months.

Discussion

NSS has increasingly gained acceptance in the management of small renal masses, and with similar oncological results to RN. With the advances in laparoscopic surgery, laparoscopic NSS has also been established as an appropriate treatment option. However, the technical difficulty of the procedure and the need for advanced laparoscopic skills limited the dissemination of the procedure primarily to tertiary-care centres.

The development of the robotic platform, and the resultant improved visibility, ergonomics and the ease of suturing, have permitted many urologists to attempt minimally invasive NSS. In 2004, Gettman et al. [42] reported their initial series of RPN, with 13 procedures performed. Since this first description, there has been an exponential growth in reported RPN series, as recently shown by Altunrende et al. [43].

Table 1 Large single-institution series of RPN; demographics and outcomes.

Variable	Reference							Total
	[34]	[35]	[36]	[37]	[38]	[39]	[40]	
Sample size, <i>n</i> (%)	50 (7)	100 (14)	62 (9)	71 (10)	69 (10)	97 (14)	252 (36)	701 (100)
Mean:								
Age, years	60	55	60.6	59.8	53.5	59.5	58.5	58.1
BMI, kg/m ²	29.6	NA	NA	30.9	25.5	31	30.5	29.9
Tumour size, cm	2.7	2.8	2.9	2.7	2.4	2.4	3.1	2.8
RENAL score	NA	6.8	NA	NA	NA	NA	6.8	6.8
WIT, min	18	25	20	22	23	24	18	21
Op duration, min	145	206	91	256	192	254	190	196
EBL, mL	140	127	95	100	229	125	267	182
Rate, <i>n</i> (%)								
Transfusion	2 (4)	3 (3)	2 (3.2)	2 (2.8)	3	NA	33 (13)	45 (7.4)
Conversion	2 (4)	2 (2)	NA	1 (1.4)	1	1	5 (2)	12 (1.7)
Postop complications	5 (10)	12 (12)	7 (11)	9 (13)	6 (9)	6 (6)	48 (19)	93 (13)
Mean LOS, days	2.5	3.2	5	2	6.2	2	3.9	3.6
PSM rate, <i>n</i> (%)	1 (2)	5 (5)	1 (1.6)	1 (1.4)	0	2	2 (0.8)	12 (1.7)
Estimated GFR or SCr, % change	0	−7.6	0	−2	−7.3	−7.2	−6.6	−5.4
Mean follow-up, months	NA	12.7	NA	6.8	NA	11.3	6.0	8.4

PSM, positive surgical margin.

eGFR, estimated GFR.

SCr, serum creatinine.

NA, not available.

In the present review, we opted to include only single-centre series with 50 or more RPNs. Although 50 patients might not necessarily represent the exact limit for a minimum learning curve, we chose it arbitrarily in an attempt to avoid the inclusion of studies that had exclusively immature results and overlapping series.

In 2009, Benway et al. [34] reported their sliding-clip renorrhaphy technique in 50 patients who underwent RPN. They concluded that the sliding-clip renorrhaphy provides an effective repair, minimizing operative times and WIT, with a relatively short learning curve.

Scoll et al. [35] evaluated their experience of 100 RPNs, with a mean tumour size of 2.8 cm and a mean RENAL nephrometry score of 6.8. Their results support the feasibility and safety of RPN. They called for increased adoption of objective reporting of tumour complexity, which would permit more meaningful comparisons between the different approaches for NSS.

Mottrie et al. [36] evaluated the learning curve in 62 consecutive RPNs at a non-academic teaching institution. They concluded that RPN requires a short learning curve to achieve acceptable results in the hands of an experienced robotic surgeon.

Patel et al. [37] evaluated 71 consecutive RPNs, comparing the outcomes between patients with tumours of >4 or ≤ 4 cm on preoperative imaging. Their overall results are also shown in Table 1. They found no significant differences between the groups for EBL, operative duration, complication rates, LOS, and percentage change in renal function. However, patients with tumours of >4 cm had longer WIT (25 vs. 20 min; $P = 0.011$). They concluded that RPN for tumours of >4 cm is safe and feasible, with results generally comparable to RPN for smaller tumours.

Lee et al. [38] retrospectively compared 69 RPNs and 234 open PNs; they found no significant differences in tumour size and EBL between the groups. The mean operative time and the mean WIT were longer in the RPN group ($P < 0.001$), with no significant changes in the estimated GFR ($P = 0.520$). The analgesic consumption and LOS favoured to the RPN group. The postoperative complication rate was similar between the groups ($P = 0.158$).

In another large study, Naheen et al. [39] evaluated 97 RPNs, comparing the outcomes between groups of non-obese and obese patients (body mass index, BMI, ≥ 30 kg/m²). The overall results are also shown in Table 1. The obese group had a higher EBL ($P = 0.027$). The operative duration, WIT and complication rates were not significantly different between the groups; the LOS was also similar. They concluded that RPN is feasible and safe in patients with a BMI of ≥ 30 kg/m², but with a larger EBL.

We recently reported our series with 252 consecutive RPNs, which is the largest single-centre experience of RPN to date [40]. We compared our early and late expe-

rience, after modifications in our renorrhaphy technique. The most important changes are represented by placing a running suture for the resection bed and a horizontal mattress to approximate the renal capsule, allowing a more uniform compression of the kidney parenchyma. This could possibly result in a safer sealing of the vascular and collecting systems. There was a lower EBL ($P = 0.04$) and a significant decrease from 24.6% to 9% in the blood transfusion rate ($P = 0.001$). The postoperative complication rate also decreased significantly from 33.8% to 14.4% ($P = 0.03$). The decrease in WIT was not statistically significant, but the mean operative duration decreased from 219 to 181 min ($P < 0.001$). LOS, postoperative complication and conversion rates also decreased significantly ($P = 0.02$, 0.03, and 0.01, respectively). The improvement in results probably reflects the synergism between increased experience and technical refinements.

The robotic platform has allowed increasingly complex renal masses to be excised via a minimally invasive approach. Despite the paucity of prospective randomised studies, the feasibility and safety of RPN has been confirmed, with many procedures reported and with outcomes similar to those obtained with more established techniques. A longer follow-up should also make available more robust data on oncological outcomes in the near future.

Conclusions

RPN has been shown to be feasible and safe for renal tumours with different levels of complexity, with perioperative outcomes similar to those reported for laparoscopic and open approaches. Future studies should prioritise prospective and randomised designs comparing PN for tumours of similar complexity through open, laparoscopic and robotic approaches.

Conflict of interest

Dr. Jihad H. Kaouk is consultant for Intuitive Surgical.

References

- [1] Murai M, Oya M. Renal cell carcinoma: etiology, incidence and epidemiology. *Curr Opin Urol* 2004;**14**:229–33.
- [2] Jayson M, Sanders H. Increased incidence of serendipitously discovered renal cell carcinoma. *Urology* 1998;**51**:203–5.
- [3] Falebita OA, Mancini S, Kiely E, Comber H. Rising incidence of renal cell carcinoma in Ireland. *Int Urol Nephrol* 2009;**41**:7–12.
- [4] Wunderlich H, Schumann S, Jantizky V, Moravek M, Podhola M, Kosmehl H, et al. Increase of renal

- cell carcinoma incidence in central Europe. *Eur Urol* 1998;**33**:538–41.
- [5] Huang WC, Elkin EB, Levey AS, Jang TL, Russo P. Partial nephrectomy versus radical nephrectomy in patients with small renal tumors – is there a difference in mortality and cardiovascular outcomes? *J Urol* 2009;**181**:55–61.
- [6] Weight CJ, Larson BT, Fergany AF, Gao T, Lane SC, Campbell SC, et al. Nephrectomy induced chronic renal insufficiency is associated with increased risk of cardiovascular death and death from any cause in patients with localized cT1b renal masses. *J Urol* 2010;**183**:1317–23.
- [7] Go AS, Chertow GM, Fan D, McCulloch CE, Hsu CY. Chronic kidney disease and the risks of death, cardiovascular events, and hospitalization. *N Engl J Med* 2004;**351**:1296–305.
- [8] Novick AC. Partial nephrectomy for renal cell carcinoma. *Urol Clin North Am* 1987;**14**:419–33.
- [9] Fergany AF, Saad IR, Woo L, Novick AC. Open partial nephrectomy for tumor in a solitary kidney: experience with 400 cases. *J Urol* 2006;**175**:1630–3.
- [10] Rini BI, Campbell SC, Escudier B. Renal cell carcinoma. *Lancet* 2009;**373**:1119–32.
- [11] Novick AC, Campbell SC, Belldegrun A, et al. American Urological Association Guideline for management of the clinical stage 1 renal mass. Panel consensus regarding treatment modalities. 2009 Available at <<http://www.auanet.org/content/guidelines-and-quality-care/clinical-guidelines/main-reports/renalmass09.pdf>> Accessed 30 September 2011.
- [12] Ljungberg B, Hanbury DC, Kuczyk MA, Merseburger AS, Mulders PF, Patard JJ, et al. European Association of Urology Guideline Group for renal cell carcinoma. *Eur Urol* 2007;**51**:1502–10.
- [13] Simmons MN, Weight CJ, Gill IS. Laparoscopic radical versus partial nephrectomy for tumors >4cm intermediate-term oncologic and functional outcomes. *Urology* 2009;**73**:1077–82.
- [14] Weight CJ, Larson BT, Gao T, Campbell SC, Lane JH, Kaouk JH, et al. Elective partial nephrectomy in patients with clinical T1b renal tumors is associated with improved overall survival. *Urology* 2010;**76**:631–7.
- [15] Weight CJ, Lythgoe C, Unnikrishnan R, Lane BR, Campbell SC, Fergany AF. Partial nephrectomy does not compromise survival in patients with pathologic upstaging to pT2/pT3 or high-grade renal tumors compared with radical nephrectomy. *Urology* 2011;**77**:1142–6.
- [16] Weight CJ, Lieser G, Larson BT, Gao T, Lane BR, Campbell SC, et al. Partial nephrectomy is associated with improved overall survival compared to radical nephrectomy in patients with unanticipated benign renal tumours. *Eur Urol* 2010;**58**:293–8.
- [17] Haber GP, Gill IS. Laparoscopic partial nephrectomy. Contemporary technique and outcomes. *Eur Urol* 2006;**49**:660–5.
- [18] Riggs SB, LaRochelle JC, Belldegrun AS. Partial nephrectomy: a contemporary review regarding outcomes and different techniques. *Cancer* 2008;**14**:302–7.
- [19] Patel MN, Kaul SA, Laungani R, Eun D, Bhandari M, Menon M, et al. Retroperitoneal robotic renal surgery. Technique and early results. *J Robotic Surg* 2009;**3**:1–5.
- [20] Gong Y, Du C, Josephson DY, Wilson TG, Nelson R. Four-arm robotic partial nephrectomy for complex renal cell carcinoma. *World J Urol* 2010;**28**:111–5.
- [21] Ho H, Peschel R, Neururer R, Steiner H, Schwentner C, Bartsch G. Another novel application of hem-o-lok clips for transient vascular occlusion in robot-assisted laparoscopic partial nephrectomy: an alternative to laparoscopic bulldog and Satinsky clamps. *J Endourol* 2008;**22**:1677–80.
- [22] White WM, Goel RK, Haber GP, Kaouk JH. Robotic partial nephrectomy without renal hilar occlusion. *BJU Int* 2010;**105**:1580–4.
- [23] Nadler RB, Perry K, Smith N. Hybrid laparoscopic and robotic ultrasound-guided radiofrequency ablation-assisted clampless partial nephrectomy. *Urology* 2009;**74**:202–5.
- [24] Moinzadeh A, Flacke S, Libertino JA, Merhige J, Vogel JM, Lyall K, et al. Temporary segmental renal artery occlusion using reverse phase polymer for bloodless robotic partial nephrectomy. *J Urol* 2009;**182**:1582–7.
- [25] Simone G, Papalia R, Guaglianone S, Carpanese L, Gallucci M. Zero ischemia laparoscopic partial nephrectomy after superselective transarterial tumor embolization for tumors with moderate nephrometry score long-term results of a single-center experience. *J Endourol* 2011;**25**:1443–6.
- [26] Nohara T, Fujita H, Yamamoto K, Kitagawa Y, Gabata T, Namiki M. Modified anastrophic partial nephrectomy with selective renal segmental artery clamping to preserve renal function: a preliminary report. *Int J Urol* 2008;**15**:961–6.
- [27] Abreu AL, Gill IS, Desai MM. Zero-ischaemia robotic partial nephrectomy (RPN) for hilar tumours. *BJU Int* 2011;**108**:948–54.
- [28] Lane BR, Russo P, Uzzo RG, Hernandez AV, Boorjian SA, Thompson RH, et al. Comparison of cold and warm ischemia during partial nephrectomy in 660 solitary kidneys reveals predominant role of nonmodifiable factors in determining ultimate renal function. *J Urol* 2011;**185**:421–7.
- [29] Simmons MN, Fergany AF, Campbell SC. Effect of parenchymal volume preservation on kidney

- function after partial nephrectomy. *J Urol* 2011;**186**:405–10.
- [30] Laydner H, Autorino R, Spana G, Altunrende F, Yang B, Khanna R, et al. Robot-assisted partial nephrectomy for sporadic ipsilateral multifocal renal tumours. *BJU Int* 2011. doi:10.1111/j.1464-410X.2011.10319 [Epub ahead of print].
- [31] Mottrie A, Koliakos N, DeNaeyer G, Willemsen P, Buffi N, Schatteman P, et al. Tumor enucleoresection in robot-assisted partial nephrectomy. *J Robotic Surg* 2009;**3**:65–9.
- [32] Boris R, Proano M, Linehan WM, Pinto PA, Bratslavsky G. Initial experience with robot assisted partial nephrectomy for multiple renal masses. *J Urol* 2009;**182**:1280–6.
- [33] Rogers CG, Singh A, Blatt AM, Linehan WM, Pinto PA. Robotic partial nephrectomy for complex renal tumors: surgical technique. *Eur Urol* 2008;**53**:514–23.
- [34] Benway BM, Wang AJ, Cabello JM, Bhayani SB. Robotic partial nephrectomy with slinding-clip renorrhaphy. Technique and outcomes. *Eur Urol* 2009;**55**:592–9.
- [35] Scoll BJ, Uzzo RG, Chen DY, Boorjian SA, Kutikov A, Manley BJ, et al. Robot-assisted partial nephrectomy: a large single-institutional experience. *Urology* 2010;**75**:1328–34.
- [36] Mottrie A, De Naeyer G, Schatteman P, Carpentier M, Sangalli M, Ficarra V. Impact of the learning curve on perioperative outcomes in patients who underwent robotic partial nephrectomy for parenchymal renal tumours. *Eur Urol* 2010;**58**:127–32.
- [37] Patel MN, Krane LS, Bhandari A, Laungani RG, Shrivastava A, Siddiqui SA, et al. Robotic partial nephrectomy for renal tumors larger than 4 cm. *Eur Urol* 2010;**57**:310–6.
- [38] Lee S, Oh J, Hong SK, Lee SE, Byun SS. Open versus robot-assisted partial nephrectomy: effect on clinical outcome. *J Endourol* 2011;**25**:1181–5.
- [39] Naeem N, Petros F, Sukumar S, Patel M, Bhandari S, Kaul S, et al. Robot-assisted partial nephrectomy in obese patients. *J Endourol* 2011;**25**:101–5.
- [40] Kaouk JH, Hillyer SP, Autorino R, Haber GP, Gao T, Altunrende F, et al. 250 robotic partial nephrectomies. Evolving technique and surgical outcomes at a single institution. *Urology* 2011. doi:10.1016/j.urology.2011.08.00.
- [41] Dindo D, Demartines N, Clavien PA. Classification of surgical complications: a new proposal with evaluation in a cohort of 6336 patients and results of a survey. *Ann Surg* 2004;**240**:205–13.
- [42] Gettman MT, Blute ML, Chow GK, Neururer R, Bartsch G, Peschel R. Robotic-assisted laparoscopic partial nephrectomy. technique and initial clinical experience with daVinci robotic system. *Urology* 2004;**64**:914–8.
- [43] Altunrende F, Autorino R, Laydner H, White MA, Yang B, Khanna R, et al. Robot assisted laparoscopic partial nephrectomy. techniques and outcomes. *Arch Esp Urol* 2011;**64**:325–36.