



Contents lists available at ScienceDirect

Gynecology and Minimally Invasive Therapy

journal homepage: www.e-gmit.com

Letter to the editor

A case of signet ring cell carcinoma of the ovary diagnosed after laparoscopic surgery

*To the Editor,*

Signet ring cell carcinomas (SRCCs) of the ovary are rare. In general, primary SRCCs of the ovary are extremely rare; most are metastatic neoplasms. The gastrointestinal tract is the most likely primary site. We describe a rare case of an ovarian tumor removed with laparoscopic surgery in which the postoperative pathological diagnosis was SRCC of the ovary.

The patient was a 39-year-old woman with a history of two vaginal deliveries. Her past medical and surgical histories were unremarkable. She complained of right lower abdominal pain. Transabdominal ultrasonography revealed a solid tumor of 9 cm in diameter adjacent to the right side of the uterus (Fig. 1A). A solid adnexal tumor was suspected. She was referred to our hospital for further evaluation and treatment. When uterine cervical cancer screening was performed 9 months previously, no abnormal cytology or tumors were detected. Magnetic resonance imaging (MRI) was also performed. T2-weighted imaging showed a solid tumor with uneven signal intensity adjacent to the body of the uterus (Fig. 1B). No ascites was detected by imaging. Consequently, a solid tumor arising from the right ovary such as a fibroma or thecoma was suspected. Tumor markers for epithelial ovarian cancer such as CA125, CA19-9, and CEA were all within normal range.

Primary laparoscopic surgery was performed using three port insertions. There were no severe peritoneal adhesions. A small volume of yellow serous ascites was pooled in the pouch of Douglas, which was collected and examined intraoperatively. Cytology of the ascites fluid was class IIIa with atypical cells. The tumor was solid and 10 cm in diameter. It originated from the right ovary with good movability (Fig. 1C). The uterus and left ovary were morphologically normal in size and shape. We performed right salpingo-oophorectomy using the LigaSure V™ energy-sealing device (COVIDIEN, Japan). To avoid direct contact between the tumor and the port site, the resected ovarian tumor was packed into a specimen bag in the peritoneal cavity and removed through the 12-mm port site after it was cut into small pieces inside the bag (Fig. 1D and E). Although inflammation-like changes were observed on the pelvic peritoneum, adhesiolysis and peritoneal biopsy were not performed because there were no obvious findings suggestive of tumor dissemination and we did not suspect malignancy at that time (Fig. 1F).

Subsequent histopathological examination confirmed the presence of SRCC in the right ovarian tumor. Immunohistological staining was positive for CEA and CK20 (Fig. 1G and H) and negative for CK7, ER, and PR. Thus, we suspected that the ovarian tumor was a metastasis from the gastrointestinal tract and extensive evaluation to determine the origin was performed. Contrast-enhanced computed tomography (CE-CT) revealed findings suspicious for dissemination to the omentum. PET-CT was also performed. Abnormal accumulations suspicious for dissemination were observed in the omentum and gastric region. Upper and lower gastrointestinal tract endoscopy revealed no abnormal findings. Abdominal ultrasonography revealed no abnormal findings in the liver, biliary system, or pancreas.

Because we could not identify an origin for SRCC other than the ovary, we performed curative open surgery based on the diagnosis of primary ovarian SRCC approximately one month after the laparoscopic procedure. There were numerous small disseminations on the surface of the peritoneum, intestines, mesenterium, omentum, and stomach. After total hysterectomy, left salpingo-oophorectomy, pelvic lymphadenectomy, and partial omentectomy, we incidentally found a hard tumor of approximately 2 cm in diameter in the portion of the appendix (Fig. 1I). Based on the surgical findings and preoperative evaluation, we hypothesized that the ovarian metastasis and disseminations originated from a primary tumor of the appendix. Because of widespread small disseminations on the surface of the intestines and mesenterium, curative surgery for appendiceal carcinoma was considered to be too risky given her postoperative condition and the risk of separation of the resulting intestinal anastomosis and was not performed.

Postoperative histopathological examination confirmed the presence of metastatic SRCC in the left ovary, omentum, and pelvic lymph nodes (bilateral external iliac and left obturator nodes). The cytology of the ascites fluid from the open surgery was positive for adenocarcinoma. The patient had an uneventful recovery from the second operation and was referred to the department of gastroenterology for advanced treatment of colorectal SRCC.

Primary SRCCs of the ovary are extremely rare. Only five cases could be identified in the international literature.^{1,2} Ovarian SRCCs are usually metastatic neoplasms, with the gastrointestinal tract as the most likely primary site.

In general, a Krukenberg tumor (KT) is clinically defined as any ovarian metastatic carcinoma derived from a primary malignancy, although it is diagnosed according to World Health Organization (WHO) diagnostic criteria based on the pathological description.³ It has been reported that KT is a rare tumor, with an incidence of

Conflicts of interest declaration: The authors have no conflicts of interest relevant to this article.

<http://dx.doi.org/10.1016/j.gmit.2017.04.002>

2213-3070/Copyright © 2017, The Asia-Pacific Association for Gynecologic Endoscopy and Minimally Invasive Therapy. Published by Elsevier Taiwan LLC. This is an open access article under the CC BY-NC-ND license (<http://creativecommons.org/licenses/by-nc-nd/4.0/>).

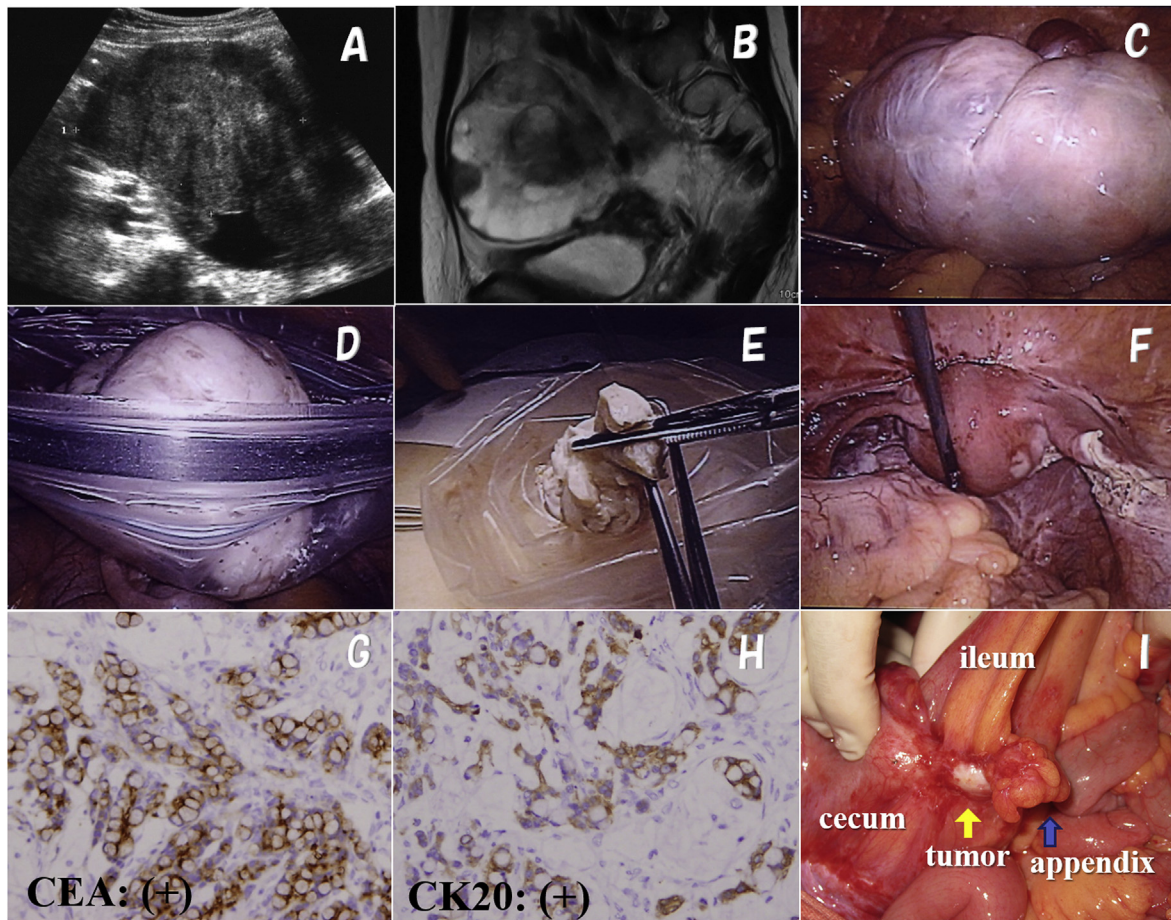


Fig. 1. Transabdominal ultrasonography (A) and MRI (B) revealed a solid tumor in the region of the right adnexa, which was diagnosed as a solid ovarian tumor (fibroma or thecoma of the ovary) or a subserosal leiomyoma based on imaging findings. During the first laparoscopic surgery, a solid right ovarian tumor was observed (C). Right salpingo-oophorectomy was performed using an energy-sealing device. The resected tumor was packed into a surgical bag in the peritoneal cavity and removed through the port site after it was cut into small pieces inside the bag (D, E). Histopathological examination showed the ovarian tumor consisted of signet ring cell carcinoma. The tumor had diffuse immunoreactivity against CEA and cytokeratin 20 (G, H) ($\times 400$). A hard tumor of approximately 2 cm in diameter (yellow arrow) was incidentally identified in a portion of the appendix during the second open surgery (I).

approximately 2% of all ovarian cancers.⁴ KT from primary colorectal cancer has an incidence of 1.57%.⁵ The prognosis of KT is always very poor since there is no standardized chemotherapy or radiotherapy; median survival ranges from 7.7 to 19.0 months.^{3,5} A literature review showed that the most common primary site of KT is the stomach, followed by the intestines. KT originating from the breast, biliary tract, small intestine, appendix, pancreas, uterine cervix, urinary bladder, and renal pelvis has been also reported.⁵ There have also been some cases of KT of uncertain origin. The primary tumor might have been too small or silent to detect despite exhaustive investigation.³ Regarding the mechanism of KT formation, three possible pathways of metastasis have been suggested: transcoelomic, lymphatic, and hematogenous.³ In premenopausal women, a functioning ovary is considered a relatively attractive site for hematogenous or transcoelomic metastasis due to its rich vascularity, blood flow, and ovulation.³

Primary carcinomas of the appendix are rare entities that constitute less than 0.5% of all gastrointestinal neoplasms. Smeenk et al reported that out of 16,744 patients who underwent appendectomy, only 0.3% had malignancies.⁶ Primary SRCC of the appendix is an exceedingly rare entity, with an incidence rate of 0.15 per million. Primary SRCC accounts for only 4% of all appendiceal malignancies.⁷ The prognosis of SRCC of the appendix is poor. The overall

five-year survival rate for appendiceal SRCC is 18%, whereas it ranges from 42% to 83% for other histological types.⁷

In our patient, the clinical course of SRCC progressed very rapidly, as evidenced by the extensive peritoneal dissemination. Although they were all very small lesions, they were formed or became obvious during the month between the two operations. Ideally, frozen section pathological diagnosis would have been performed during the first laparoscopic operation to avoid another curative operation. However, it was not performed because we did not suspect malignancy from the pelvic cavity findings at that time. With extensive postoperative evaluation and findings from the subsequent laparotomy, we hypothesized the patient's ovarian SRCC was metastasis originating from a primary tumor of the appendix, although pathological confirmation could not be obtained.

In conclusion, SRCCs of the ovary are very rare. They are mostly metastatic neoplasms, with the gastrointestinal tract as the most likely primary site. Although we could not diagnose KT during the first laparoscopic operation, gynecologists should be keep in mind the possibility of metastatic tumors and should examine the whole abdominal cavity, including the upper abdomen, during laparoscopic procedures, especially when tumors are solid or there are bilateral ovarian tumors.

References

1. El-Safadi S, Stahl U, Tinneberg HR, et al. Primary signet ring cell mucinous ovarian carcinoma: a case report and literature review. *Case Rep Oncol*. 2010;3:451–457.
2. Ganesh PJ, Chander RV, Kanchana MP, Narasimhan L. Primary ovarina mucinous carcinoma with signet ring cells – report of rare case. *J Clin Diagn Res*. 2014;8:FD12–FD13.
3. Qiu L, Yang T, Shan XH, et al. Metastatic factor for Kurkenberg tumor: a clinical study on 102 cases. *Med Oncol*. 2011;28:1514–1519.
4. Berek JS, Natarajan S. Ovarian and fallopian tube cancer. In: Berek JS, ed. *Berek and Novak's Gynecology*. 14th ed. Philadelphia: Lippincott Williams and Wilkins; 2007:1457–1554.
5. Tan KL, Tan WS, Lim JF, et al. Krukenberg tumors of colorectal origin: a dismal outcome—experience of a tertiary center. *Int J Colorectal Dis*. 2010;25:233–238.
6. Smeenk RM, van Velthuisen MI, Verwaal VJ, et al. Appendiceal neoplasms and pseudomyxoma peritonei: a population based study. *Eur J Surg Oncol*. 2008;34:196–201.
7. McGory ML, Maggard MA, Kang H, et al. Malignancies of the appendix: beyond case series reports. *Dis Colon Rectum*. 2005;48:2264–2271.

Hiroyuki Yazawa*, Fumihiro Ito
Department of Obstetrics and Gynecology, Fukushima Red Cross
Hospital, Fukushima, Japan

Tsuyoshi Hiraiwa, Keiya Fujimori
Department of Obstetrics and Gynecology, Fukushima Medical
University, Fukushima, Japan

* Corresponding author: Fukushima Red Cross Hospital, Irie-cyo,
11-31, Fukushima, 960-8530, Japan. Fax: +08 24 534 5205.
E-mail address: ikyoku12@fukushima-med-jrc.jp (H. Yazawa).

5 January 2017
Available online 5 July 2017