



An interesting case of whitish pleural effusion: think beyond the obvious

Shweta Anand, Dipti Gothi, Mahismita Patro and Ishani Deshmukh

Dept of Pulmonary Medicine, ESI-PGIMS, New Delhi, India.

Corresponding author: Dipti Gothi (diptigothi@gmail.com)



Shareable abstract (@ERSpublications)

A whitish pleural fluid calls for further biochemical and microbiological investigations beyond routine pleural fluid analysis as it decides the aetiology and management. <https://bit.ly/3GwGpzS>

Cite this article as: Anand S, Gothi D, Patro M, *et al.* An interesting case of whitish pleural effusion: think beyond the obvious. *Breathe* 2022; 18: 210214 [DOI: 10.1183/20734735.0214-2021].

Copyright ©ERS 2022

Breathe articles are open access and distributed under the terms of the Creative Commons Attribution Non-Commercial Licence 4.0.

Received: 7 Dec 2021
Accepted: 31 Jan 2022

A 66-year-old male, never-smoker, who was a labourer by occupation presented to the outpatient department with the chief complaints of right-sided chest pain and dyspnoea for the past 1 month. The pain was dull aching, gradually progressive, increasing with respiration and relieved with analgesics. The dyspnoea was exertional, and gradual in onset. It had progressively increased from modified Medical Research Council grade 1 to 3. He did not have fever, cough, expectoration or wheeze. He had a past history of right-sided pleural effusion 3 years ago, for which he took anti-tubercular treatment (ATT) for 6 months and was declared cured, although he had no medical records from that time. On further probing, the patient gave a history of blunt trauma 5 years ago. He was hit by a buffalo on the right side of the chest at that time. He did not have any serious illness and instrumentation like central line insertion in the recent past. There was no history of any comorbidities or surgery.

General examination of the patient revealed a pulse rate of 96 beats per min, respiratory rate of 25 breaths per min, blood pressure of 124/76 mmHg and oxygen saturation of 96% on ambient air. The respiratory system examination showed decreased movements in the right mammary, infra-axillary and infrascapular areas. The percussion note was dull and the breath sounds were decreased in the same areas. The routine

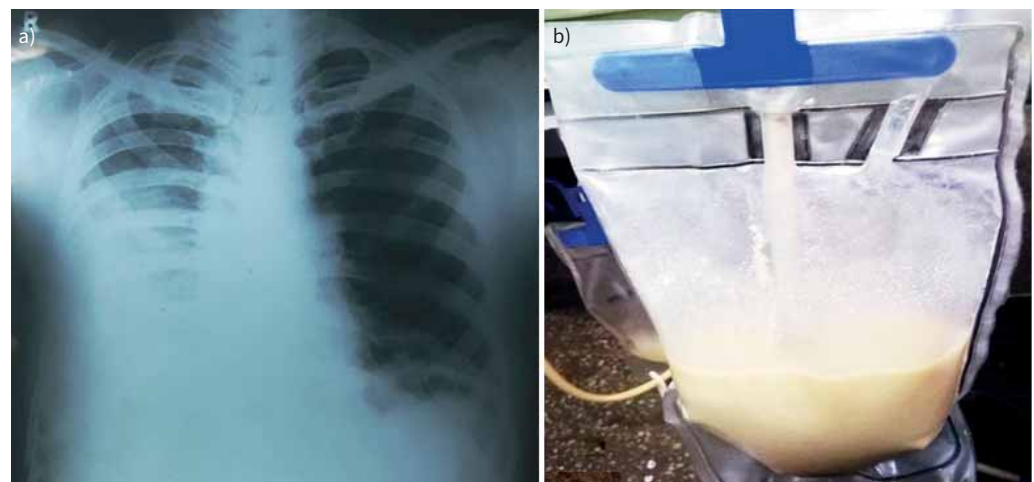


FIGURE 1 a) Chest radiograph in posteroanterior view at the time of presentation. b) Pale milky pleural fluid drained after intercostal tube insertion.



biochemical and haematological investigations were within normal limits. Blood sugar fasting was $85 \text{ mg}\cdot\text{dL}^{-1}$. The enzyme linked immunosorbent assay for HIV was negative. The chest radiograph in posteroanterior projection is shown in figure 1a. The ultrasound of the chest showed fluid collection in the right pleural cavity with thickened pleura.

A diagnostic thoracentesis was performed under ultrasound guidance and a thick whitish odourless pleural fluid was aspirated. The patient was admitted and intercostal chest tube insertion was carried out. Around 800 mL pale white pleural fluid was drained (figure 1b). The pleural fluid analysis revealed an exudative fluid with protein of $6.4 \text{ g}\cdot\text{dL}^{-1}$ (normal range: $6.0\text{--}8.0 \text{ g}\cdot\text{dL}^{-1}$), lactate dehydrogenase of $2755 \text{ U}\cdot\text{L}^{-1}$ (normal range: $80\text{--}285 \text{ U}\cdot\text{L}^{-1}$) and sugar of $88 \text{ mg}\cdot\text{dL}^{-1}$ (normal range: $70\text{--}140 \text{ mg}\cdot\text{dL}^{-1}$). The pleural fluid adenosine deaminase (ADA) level was $62.5 \text{ U}\cdot\text{L}^{-1}$ (normal range: $<24 \text{ U}\cdot\text{L}^{-1}$). There were no organisms on Gram stain. The pleural fluid aerobic bacterial culture yielded no growth. The microscopic examination showed presence of degenerated cells and total cell count was not possible. The contrast enhanced computed tomography (CT) of the chest showed the presence of right-sided hydropneumothorax with intercostal tube *in situ* (figure 2).

Task 1

Which of the following is the least likely cause of this pleural effusion?

- Anaerobic empyema
- Tuberculous empyema
- Chylous pleural effusion
- Pseudochylous pleural effusion
- Total parenteral nutrition leakage

[Go to Answers >>](#)

The pale white or opalescent or turbid appearance of the pleural fluid can be seen in empyema, chylous effusion, pseudochylous effusion and total parenteral nutrition (TPN) leakage [1, 2]. TPN leakage is the least likely cause as our patient had no history of serious illness and instrumentation in the recent past. The effusion due to TPN leakage has a milky appearance. The TPN composition is similar to that of chylothorax in terms of triglycerides and cholesterol, but has a high glucose content and electrolytes like potassium [3]. The milky appearance suggests a chylous or pseudochylous effusion and characteristically they are uniform and odourless [1]. The milky colour of the pleural fluid can also be sometimes mistaken for an empyema. The pleural fluid sugar was normal so empyema is less likely. Nonetheless, empyema still is a possibility as pleural fluid sugar may occasionally be normal in empyema [4]. The empyema usually appears pale yellow to white in colour and debris can be seen floating within the fluid. The empyema can result from bacterial or tubercular infection. Since pleural fluid aerobic culture was

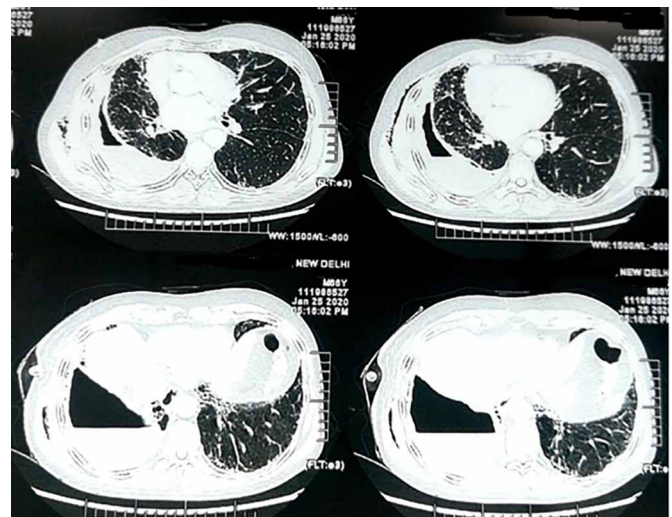


FIGURE 2 Contrast enhanced CT of the chest showing right pleural effusion with thickened pleura and intercostal tube *in situ*.

negative, there was a possibility of anaerobic or tuberculous empyema. Anaerobic bacterial infections usually impart a characteristic foul smell to the pleural fluid but the absence of a foul smell does not rule out anaerobic infections [5]. The diagnostic importance of pleural fluid ADA is still elusive. A cut-off of $40 \text{ U}\cdot\text{L}^{-1}$ of ADA is considered to be tuberculous in cases of lymphocytic and exudative fluid [6]. However, raised ADA levels can also be seen in empyema, malignancy and rheumatoid arthritis accounting for false positivity [7]. There is a lack of data about ADA level in chylothorax, whereas in pseudochylothorax it depends on the aetiology. The differentiation between empyema, chylous and pseudochylous effusion requires further investigations.

Task 2

What is the most appropriate next step to differentiate between empyema, chylous and pseudochylous effusion?

- Pleural fluid lipid studies
- Pleural fluid ultracentrifugation
- Blind pleural biopsy
- Thoracoscopy
- Lymphoscintigraphy

[Go to Answers >>](#)

The turbidity in the pleural fluid can result from either increased cellular content or increased lipid content. The increased cellular content can be caused by empyema, whereas the high lipid content can be due to chylous or pseudochylous effusion. To differentiate between empyema and chylothorax or pseudochylothorax, the pleural fluid needs to be centrifuged. If the supernatant is clear the fluid is empyema. Further, ether can be added to check if the turbidity persists. If the turbidity persists the fluid is likely to be chylothorax [8]. The biochemical and microbiological investigations of the pleural fluid can be useful in confirming the diagnosis. The pleural fluid lipid studies, *i.e.* triglyceride and cholesterol levels, help to differentiate between chylous and pseudochylous effusions. No instrumentation is required for finding out if the fluid is empyema, chylothorax or pseudochylothorax. In chylous pleural effusion there is a disruption of the lymphatic duct leading to accumulation of chyle in the pleural space. In our case, the patient had a history of blunt trauma in the past, so there was a possibility of chylothorax. Lymphoscintigraphy is useful in determining the site of disruption of the thoracic duct in cases of chylothorax. It demonstrates abnormal lymphatic drainage [9]. However, one needs to confirm chylothorax before lymphangioscintigraphy. To rule out this differential the pleural fluid was centrifuged, lipid studies and microbiological investigations were carried out.

Task 3

Which of the following is/are correct for the diagnosis of chylothorax?

- Pleural fluid triglyceride level $>110 \text{ mg}\cdot\text{dL}^{-1}$
- Pleural fluid triglyceride level $>50 \text{ mg}\cdot\text{dL}^{-1}$
- Ratio of the pleural fluid cholesterol to serum cholesterol of <1
- Pleural fluid cholesterol $<200 \text{ mg}\cdot\text{dL}^{-1}$
- Demonstration of chylomicrons in the pleural fluid

[Go to Answers >>](#)

Chylothorax is characterised by the presence of high triglyceride levels and chylomicrons in the pleural fluid. Whereas pseudochylous effusion results from the accumulation of large amounts of cholesterol or lecithin–globulin complexes. The pseudochylothoraces have been variously named as pseudochylous or chyloform pleural effusions or cholesterol effusions. The pleural fluid triglyceride level $>110 \text{ mg}\cdot\text{dL}^{-1}$ is diagnostic of chylous pleural effusion. However, the pleural triglyceride levels may be lower in chylothorax. If the level is between 50 and $110 \text{ mg}\cdot\text{dL}^{-1}$, chylomicrons need to be demonstrated to confirm the diagnosis of chylothorax [1, 2, 10]. The demonstration of chylomicrons requires pleural fluid lipoprotein electrophoresis, a gold standard for the diagnosis of chylothorax. But it is limited by the high cost and availability. In cases of chylothorax, the lipoprotein electrophoresis of pleural fluid shows a lack of electrophoretic mobility due to the presence of chylomicrons and absence of other lipoproteins [11].

A ratio of the pleural fluid to serum cholesterol of >1 suggests high pleural fluid cholesterol and thus pseudochylothorax [2, 8]. The most sensitive tests to establish the diagnosis of pseudochylothorax are the pleural fluid cholesterol/triglycerides ratio >1 , and the presence of cholesterol crystals with a sensitivity of 97.4% and 89.7%, respectively. The combination of pleural cholesterol/triglycerides ratio >1 and presence

TABLE 1 Differentiating features of chylothorax and pseudochylothorax

Parameter	Chylothorax	Pseudochylothorax
Pleural fluid triglyceride level, mg·dL ⁻¹	>110	<50
Pleural fluid cholesterol, mg·dL ⁻¹	<200	>200
Chylomicrons in the pleural fluid	Present	Absent
Cholesterol crystals in the pleural fluid	Not seen	Often seen
Ratio of pleural fluid triglyceride to serum triglyceride	>1	<1
Ratio of pleural fluid cholesterol to serum cholesterol	<1	>1
Ratio of pleural fluid cholesterol to pleural fluid triglyceride	<1	>1
Persistence of turbidity on addition of ethyl ether	Yes	No

of cholesterol crystals in pleural fluid has a 100% specificity for diagnosis of pseudochylothorax [12]. Table 1 summarises the findings of pleural fluid in chylous and pseudochylous pleural effusion.

The pleural fluid and serum lipid studies in our patient are shown in table 2. When the pleural fluid was subjected to further microbiological studies, the Ziehl–Neelsen (ZN) stain smear for acid-fast bacilli (AFB) was positive. Figure 3 shows a microscopic finding of our case.

Task 4

Identify the structure marked with the arrows in figure 3?

- Cholesterol crystals
- Chylomicrons
- Uric acid crystals
- AFB

[Go to Answers >>](#)

Table 2 shows that the pleural fluid triglyceride was <110 mg·dL⁻¹. The ratio of pleural fluid to serum cholesterol was >1 and pleural fluid cholesterol to triglyceride was also >1 suggestive of pseudochylous pleural effusion. The photomicrograph shows a cholesterol crystal confirming the diagnosis of pseudochylothorax. The cholesterol crystals on microscopy are seen as irregular polyhedral or rectangular shaped structures with a characteristic notched appearance. Rarely, the monohydrate forms of cholesterol can be seen as fine needle-shaped crystals and confused with uric acid crystals. The uric acid crystals show strongly negative birefringence whereas the cholesterol crystals show no birefringence on polarising microscopy [13]. The formation of cholesterol crystals is due to supersaturation and doesn't correlate with the level of cholesterol in the pleural fluid. Crystals may be seen with low levels of pleural cholesterol and may not be seen with cholesterol levels as high as 800 mg·dL⁻¹ [14, 15]. The cholesterol crystals are not seen in chylothorax [2, 8, 16].

Chylomicrons, a characteristic finding of chylous pleural effusion are not seen on the light microscopy. The photomicrograph does not show AFB, although the ZN stain was positive for AFB in this patient. The pleural fluid AFB positivity confirmed the aetiology of pseudochylothorax due to tuberculosis. The patient was started on ATT. He was discharged with the chest tube *in situ* and advice on home care of the intercostal tube. On follow up after 2 months of ATT, the pleural fluid became serous along with radiological resolution (figure 4a and b).

TABLE 2 Serum and pleural fluid lipid studies of the patient

Parameter	Result
Serum cholesterol, mg·dL ⁻¹	120
Pleural fluid cholesterol, mg·dL ⁻¹	330
Pleural fluid triglyceride, mg·dL ⁻¹	89
Ratio of pleural fluid to serum cholesterol	2.75
Ratio of pleural fluid cholesterol to triglyceride	3.7

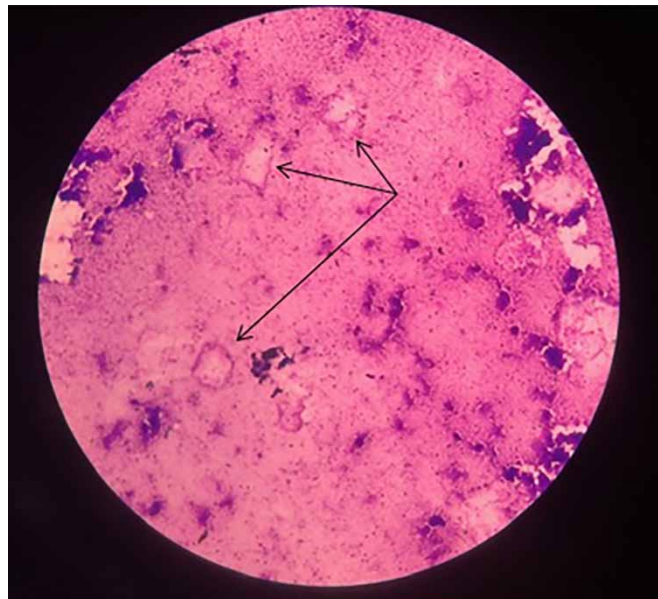


FIGURE 3 Cholesterol crystals 4× Giemsa stained pleural fluid sample.

Discussion

Pseudochylothorax and chylothorax both classically have a turbid or milky appearance due to their high lipid content. It is essential to differentiate between the two as their aetiology and treatment are entirely different. The most common cause of pseudochylothorax is tuberculosis followed by rheumatoid arthritis, both contributing to 88.5% of total cases [12]. The other rare causes include paragonimiasis, echinococcosis, malignancy and trauma [12, 17]. The malignant causes are mainly associated with haematological malignancies [17]. The pseudochylothorax usually appears in long standing effusions lasting for more than 5 years and is associated with pleural thickening. RIBAS SOLA *et al.* [18] described a patient with pleural effusion lasting over 20 years who developed pseudochylothorax due to *Mycobacterium tuberculosis*. The pathogenesis of pseudochylothorax is less completely understood. It was

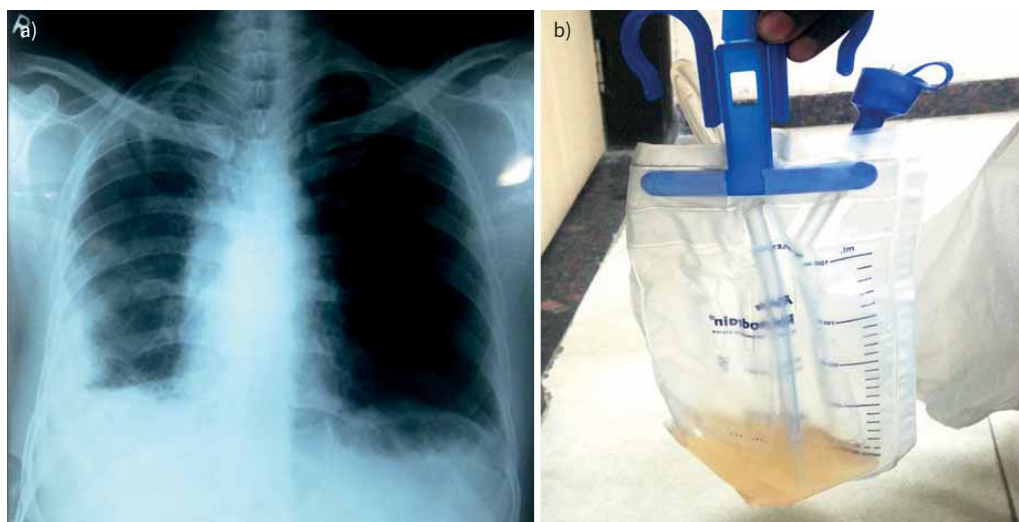


FIGURE 4 Follow-up after 2 months of ATT: a) chest radiograph showing resolution of pleural effusion, b) serous fluid drainage through intercostal tube.

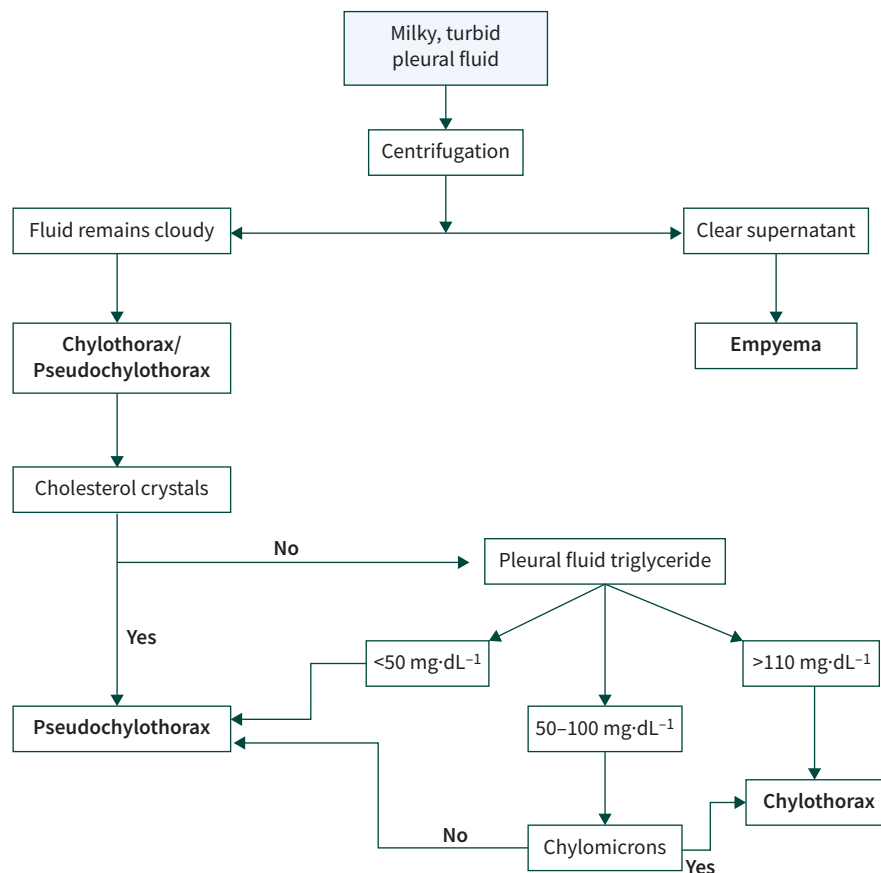


FIGURE 5 Flow chart showing the approach to diagnosis of milky pleural fluids.

initially believed to occur due to blockage of lymphatics in the thickened pleura in chronic effusions. This leads to accumulation of cells in the pleural fluid. The lysis of red cells and neutrophils liberates the cholesterol and lecithin–globulin complexes that become trapped in the pleural cavity resulting in pseudochylothorax. Some of the recent reports of pseudochylothorax have not demonstrated pleural thickening contradicting this theory. Authors believe that pseudochole formation might be due to different mechanisms in different diseases [12, 13, 19]. In our case, since there was a pleural thickening, the trapping mechanism was the possible pathogenesis.

The management of pseudochylothorax consists of treating the underlying cause. Pseudochylothorax is often associated with large pleural peels. Therapeutic thoracocentesis with or without other invasive procedures, such as decortication/pleurectomy, may be considered when there is symptomatic worsening or recurrent pleural effusion [10, 20]. Thoracocentesis is required not only to relieve symptoms but also to prevent complications, which can occur in untreated pseudochylothorax. The complications of pseudocholeous pleural effusion are reactivation of infection, and formation of bronchopleural fistula or pleurocutaneous fistula. There are reports of better outcomes in pseudochylothoraces with nonfibrotic pleura compared to those with dense pleural thickening [15]. The underlying cause in our case was active tuberculosis, which responded to ATT and intercostal tube drainage.

Conclusion

The differentials for turbid/milky pleural effusion include chylothorax, pseudochylothorax and empyema. On centrifugation of the fluid, the supernatant clears in empyema whereas the turbidity persists in chylothorax and pseudochylothorax. The chylothorax is diagnosed when pleural fluid triglyceride is $>110 \text{ mg}\cdot\text{dL}^{-1}$ and there is presence of chylomicrons. The pseudochylothorax is characterised by the presence of pleural cholesterol crystals and the ratio of pleural fluid cholesterol to triglyceride is >1 (figure 5). The management of pseudochylothorax is based on the underlying aetiology.

Answer 1

e. Total parenteral nutrition leakage

<< Go to Task 1

Answer 2

b. Pleural fluid ultracentrifugation

<< Go to Task 2

Answer 3a. The pleural fluid triglyceride level is above 110 mg·dL⁻¹ and e. Demonstration of chylomicrons in the pleural fluid

<< Go to Task 3

Answer 4

a. Cholesterol crystals

<< Go to Task 4

Conflict of interest: None declared.

References

- 1 Hillerdal G. Chylothorax and pseudochylothorax. *Eur Respir J* 1997; 10: 1157–1162.
- 2 Light RW. Pleural Diseases. 6th Edn. Alphen aan den Rijn, Wolters Kluwer Health, 2013.
- 3 Wolthuis A, Landewé RBM, Theunissen PHMH, et al. Chylothorax or leakage of total parenteral nutrition? *Eur Respir J* 1998; 12: 1233–1235.
- 4 Sahn S, Good J. In defense of low glucose level in pleural fluid. *Chest* 1980; 77: 242.
- 5 Cohen-Poradosu R, Kasper DL. 244 - Anaerobic infections: general concepts. In: Bennett JE, Dolin R, Blaser MJ, eds. Mandell, Douglas, and Bennett's Principles and Practice of Infectious Diseases. 8th Edn. Philadelphia, W.B. Saunders, 2015; pp. 2736–2743.e1.
- 6 Castro DJ, Nuevo GD, Pérez-Rodríguez E, et al. Diagnostic value of adenosine deaminase in nontuberculous lymphocytic pleural effusions. *Eur Respir J* 2003; 21: 220–224.
- 7 Porcel JM, Light RW. Diagnostic approach to pleural effusion in adults. *Am Fam Physician* 2006; 73: 1211–1220.
- 8 McGrath EE, Blades Z, Anderson PB. Chylothorax: aetiology, diagnosis and therapeutic options. *Respir Med* 2010; 104: 1–8.
- 9 Pui MH, Yueh TC. Lymphoscintigraphy in chyluria, chyloperitoneum and chylothorax. *J Nucl Med* 1998; 39: 1292–1296.
- 10 Sassoon CS, Light RW. Chylothorax and pseudochylothorax. *Clin Chest Med* 1985; 6: 163–171.
- 11 Senarathne UD, Rodrigo R, Dayanath BKTP. Milky pleural effusion in a neonate and approach to investigating chylothorax. *BMJ Case Rep* 2021; 14: e245576.
- 12 Lama A, Ferreiro L, Toubes ME, et al. Characteristics of patients with pseudochylothorax – a systematic review. *J Thorac Dis* 2016; 8: 2093–2101.
- 13 Bajaj D, Datta SK, Lingaiah R. Needle-shaped cholesterol crystals in pleural fluid: an unusual presentation. *J Appl Lab Med* 2019; 3: 899–902.
- 14 Agrawal V, Sahn SA. Lipid pleural effusions. *Am J Med Sci* 2008; 335: 16–20.
- 15 Chong SG, Chauhan Z, Di Nino E, et al. Effusion under the microscope. *Monaldi Arch Chest Dis* 2012; 77: 32–34.
- 16 Talwar A, Lee HJ. A contemporary review of chylothorax. *Indian J Chest Dis Allied Sci* 2008; 50: 343–351.
- 17 Streit A, Guerrero F, Kouki M, et al. Pseudochylothorax: an unusual mode of revelation of pleural metastasis from solid tumor. *Tumori* 2018; 104: NP46–NP49.
- 18 Ribas Sola J, Ruiz Manzano J, Gallego Díaz M, et al. Seudoquilotórax tuberculoso. Presentación de un caso con cultivo positivo para *Mycobacterium tuberculosis* y revisión de la literature [Tuberculous pseudochylothorax. Presentation of a case with positive *Mycobacterium tuberculosis* culture and review of the literature]. *Arch Bronconeumol* 1995; 31: 80–82.
- 19 Wrightson JM, Stanton AE, Maskell NA, et al. Pseudochylothorax without pleural thickening: time to reconsider pathogenesis? *Chest* 2009; 136: 1144–1147.
- 20 Ryu JH, Tomassetti S, Maldonado F. Update on uncommon pleural effusions. *Respirology* 2011; 16: 238–243.