

Successfully Managing Impending Skin Necrosis following Hyaluronic Acid Filler Injection, using High-Dose Pulsed Hyaluronidase

Kwok Thye David Loh, MBBS*
Yi Shan Phoon, MBBS, MMed*
Vanessa Phua, BMBS, MMed*
Krishan Mohan Kapoor, MS,
MCh, DNB†‡

Summary: Facial fillers are becoming increasingly popular as aesthetic procedures to temporarily reduce the depth of wrinkles or to contour faces. However, even in the hands of very experienced injectors, there is always a small possibility of vascular complications like intra-arterial injection of filler substance. We present a case report of a patient who developed features of vascular obstruction in right infra-orbital artery and tell-tale signs of impending skin necrosis, after hyaluronic acid filler injection by an experienced injector. The diagnosis of a vascular complication was made quickly with the help of clinical features like blanching, livedo reticularis, and poor capillary refill. Patient was treated promptly with “high-dose pulsed hyaluronidase protocol” comprising three 1,000-unit pulses of hyaluronidase, administered hourly. There was no further increase in size of the involved area after the first dose of hyaluronidase. All of the involved area, along with 1 cm overlapping in uninvolved skin area, was injected during each injection pulse, using a combination of cannula and needle. Complete reperfusion and good capillary filling were achieved after completion of 3 pulses, and these were taken as the end-point of high-dose pulsed hyaluronidase treatment. Immediate skin changes after filler injections, as well as after hyaluronidase injections and during the 3-week recovery period, were documented with photographs and clinical notes. Involved skin was found to have been fully recovered from this vascular episode, thus indicating that complete recovery of the ischemic skin changes secondary to possible intra-arterial injection could be achieved using high-dose pulsed hyaluronidase protocol. (*Plast Reconstr Surg Glob Open* 2018;6:e1639; doi: 10.1097/GOX.0000000000001639; Published online 9 February 2018.)

Intra-arterial injection of filler material has the potential to cause significant damage¹ and resulting blockage of cutaneous vascular supply may cause ischemic skin necrosis. Although prevention of vascular complications through detailed understanding of vascular anatomy is extremely important,² injecting physicians should also be able to recognize the features of such complications quickly for prompt action.³ We hereby report a case of intra-arterial filler injection, which was successfully managed with prompt diagnosis and using multiple pulses of high-dose hyaluronidase.⁴

From the *David Loh Surgery, Singapore; †Anticlock Clinic, Chandigarh, India; and ‡Department of Plastic Surgery, Fortis Hospital, Mohali, India.

Received for publication October 16, 2017; accepted November 29, 2017.

Copyright © 2018 The Authors. Published by Wolters Kluwer Health, Inc. on behalf of The American Society of Plastic Surgeons. This is an open-access article distributed under the terms of the Creative Commons Attribution-Non Commercial-No Derivatives License 4.0 (CCBY-NC-ND), where it is permissible to download and share the work provided it is properly cited. The work cannot be changed in any way or used commercially without permission from the journal.

DOI: 10.1097/GOX.0000000000001639

CASE REPORT

A 50-year-old woman was injected in a private clinic in Singapore for multiple areas on both right and left sides of the face. An experienced injector, with more than 7 years of injectable practice, performed the injections with a filler having hyaluronic acid (HA) concentration of 20 mg/mL and lignocaine, using a 27 G sharp needle. No preinjection local anesthesia was used, and the patient did not complain of any excessive pain or discomfort during or after the injection. After first completing the filler injections on the right side, the same points were injected on the left side. Blanching in the right malar area of the skin was first noticed 15 minutes after the completion of right face injection session. Using heat packs for 10 minutes did not improve the condition. Twenty-five minutes after completion of right side face injections, livedo reticularis pattern was noted on the right side of the face extending from the radix of the nose down to the tip, right nasal ala, and the right cheek. The area

Disclosure: The authors have no financial interest to declare in relation to the content of this article. The Article Processing Charge was paid for by the authors.

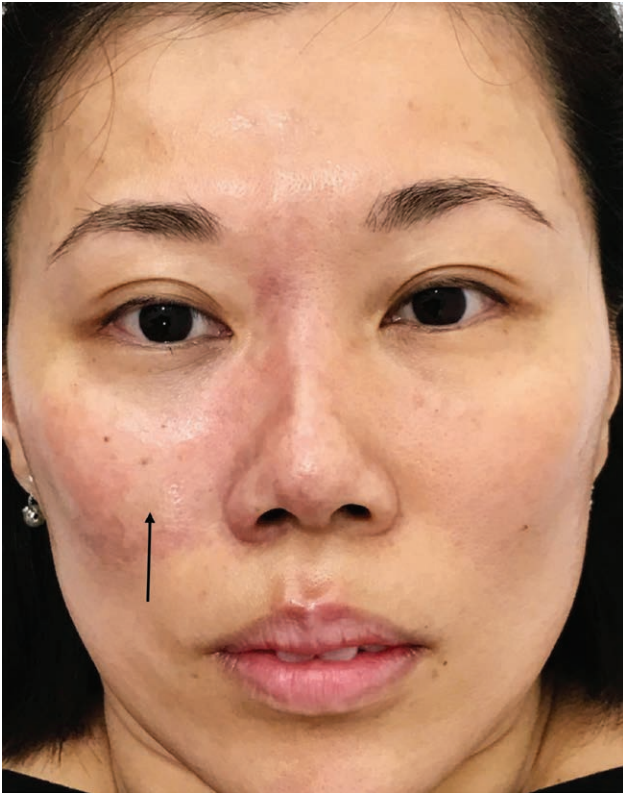


Fig. 1. Livedo reticularis, becoming more evident at 35 minutes after completing filler injections with blanching (shown by arrow) still showing in the right cheek.

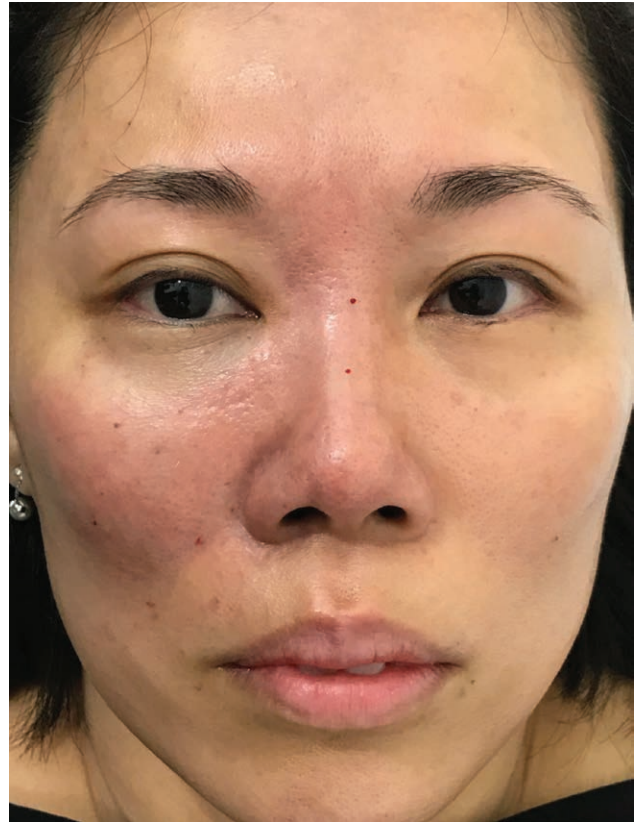


Fig. 2. Immediately after first hyaluronidase injection showing reperfusion of ischemic area and disappearance of blanching and livedo.

involved corresponded with the area of supply of the infraorbital artery and its communication with the facial artery. The discoloration extended across the midline to the left side at some points (Fig. 1). The decision was taken to dissolve the HA filler material using “high-dose pulsed hyaluronidase” technique. As two adjoining skin territories of cheek and nose were involved, 1,000 U of hyaluronidase, as per the guidelines,⁴ were injected in the involved areas, using a 25 G cannula. The injection area was extended by 1 cm beyond the area of livedo reticularis. Within seconds, reperfusion was noted in nearly the whole area (Fig. 2). After another 60 minutes, mottling was still present in some portions of previously affected areas, and a further 1,000 U of hyaluronidase was injected superficially into the cheeks using a cannula and in the dorsum of the nose using a 30 G needle. Immediate reperfusion in the remaining areas was noted. The patient was injected a third time with 1,000 U of hyaluronidase after another 60 minutes. The patient was observed for 5 hours after this, and persistence of good capillary refill was used as endpoint of high-dose pulsed hyaluronidase treatment. The patient was discharged with oral aspirin and antibiotic cover. On the fifth postinjection day, the patient was found to have a few tiny blisters in the lateral part of the right lower eyelid, and the alar-cheek junction. The patient reported slight pain and itch at the blisters. Twenty days after filler injection, the blisters had healed without any residual scarring (Fig. 3).

DISCUSSION

We present this case of intravascular filler injection so that other injector physicians can learn to recognize the early signs of ischemic skin necrosis and start its management promptly. Intra-arterial injection can be identified with blanching followed by livedo pattern. Although in most studies blanching is reported to be transient or lasting for a few seconds,¹ in the present case blanching persisted for more than half an hour in the central part of the affected portion. On careful examination, persistent blanching can provide an early diagnosis for vascular episode before more obvious livedo reticularis.⁵ Pain is an important identifying feature of intra-arterial filler injection but may not be appreciated by the patient due to local anesthetic mixed in most fillers these days.⁶ Identifying the possible arterial territory involved helps in treating the whole involved area with hyaluronidase. In this case, the infraorbital artery was involved and its communication with facial and angular arteries⁷ were the cause of nasal skin involvement along with cheek skin (Fig. 4). Hyaluronidase is an important modality for management of intra-vascular HA filler-related cutaneous complications. It is essential for every aesthetic physician having a practice in injectables.⁸ The estimated dose of hyaluronidase dose varies depending on the thickness of area involved as well as the number of areas involved. The cheek was the main area involved in this case along with the nose, so a higher dose of hyaluronidase was needed due to more thickness of cheek tissue and involvement of 2 areas.



Fig. 3. At 20 days, post-hyaluronidase, showing complete recovery with no scarring.

An estimate of 500 units for 1 vascular territory and 1,000 units for 2 areas has been suggested in high-dose pulsed hyaluronidase protocol and was followed in this case.⁴ The golden period of starting the treatment after intra-arterial filler injection is as early as the diagnosis is made, and it should not be later than 72 hours, to avoid skin necrosis and scarring. In an experimental study about free flap skin survival, more than 9 hours of warm ischemia was found to severely affect the survival of the skin component.⁹ Although most studies suggest injection of hyaluronidase, there is no unanimity on dosage and the interval between 2 doses.¹⁰ It can be injected on an hourly basis till the endpoint of treatment showing reperfusion of skin and correction of blanching/livedo. As the hyaluronidase concentration in the affected tissue goes down with time due to its degradation, dilution with extra-cellular fluid and diffusion into surrounding tissue, its replenishment at regular intervals is needed for maintaining its high concentration in affected tissue. This new modality of high-dose pulsed hyaluronidase works on the principle that an adequate amount of hyaluronidase at high concentration levels is needed for sufficiently long duration for it to dissolve the HA material present in that vascular territory.⁴

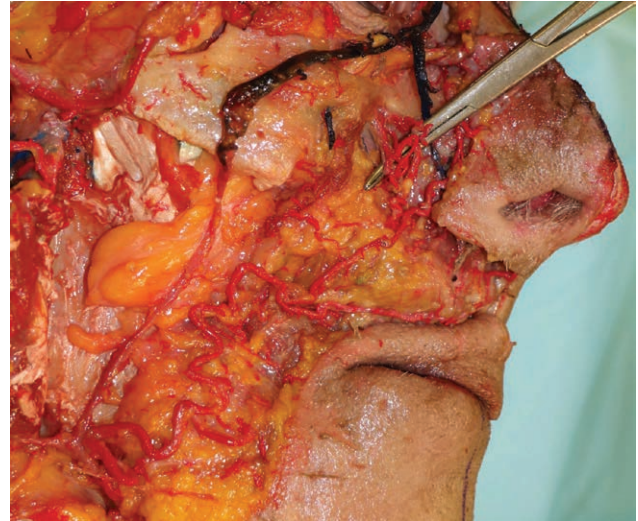

Fig. 4. Cadaveric dissection demonstrating anatomy of infraorbital artery and its communication with facial artery (picture credits: Dr. Krishan Mohan Kapoor).

Early diagnosis of intra-arterial HA filler obstruction can be made with the knowledge of clinical features and “high-dose pulsed hyaluronidase” protocol has been found effective in reversing ischemic skin changes.

Krishan Mohan Kapoor, MS, MCh, DNB

Anticlock Clinic

#1508, Sector 33 D

Chandigarh-160022, India

E-mail: kmkapoor@gmail.com

REFERENCES

- DeLorenzi C. Complications of injectable fillers, part 2: vascular complications. *Aesthet Surg J.* 2014;34:584–600.
- Signorini M, Liew S, Sundaram H, et al; Global Aesthetics Consensus Group. Global aesthetics consensus: avoidance and management of complications from hyaluronic acid fillers-evidence- and opinion-based review and consensus recommendations. *Plast Reconstr Surg.* 2016;137:961e–971e.
- Cohen JL, Biesman BS, Dayan SH, et al. Treatment of hyaluronic acid filler-induced impending necrosis with hyaluronidase: consensus recommendations. *Aesthet Surg J.* 2015;35:844–849.
- DeLorenzi C. New high dose pulsed hyaluronidase protocol for hyaluronic acid filler vascular adverse events. *Aesthetic Surg J.* 2017;37:1–12.
- Belezny K, Carruthers JD, Humphrey S, et al. Avoiding and treating blindness from fillers: a review of the world literature. *Dermatol Surg.* 2015;41:1097–1117.
- Andre P, Haneke E. Nicolau syndrome due to hyaluronic acid injections. *J Cosmet Laser Ther.* 2016;18:239–244.
- Kumar N, Rahman E. Effectiveness of teaching facial anatomy through cadaver dissection on aesthetic physicians' knowledge. *Adv Med Educ Pract.* 2017;4:475–480.
- de Almeida ART, Saliba AFN. Hyaluronidase in cosmiatry: what should we know? *Surg Cosmet Dermatology.* 2015;7:197–203.
- Hong JY, Seok J, Ahn GR, Jang YJ, Li K, Kim BJ. Impending skin necrosis after dermal filler injection: A ‘golden time’ for first-aid intervention. *Dermatologic Therapy.* 2017;30:e12440.
- De Bouille K, Heydenrych I. Patient factors influencing dermal filler complications: prevention, assessment, and treatment. *Clin Cosmet Investig Dermatol.* 2015;8:205–214.