

# Isolated lumbar intradural extra medullary spinal cysticercosis simulating tarlov cyst

Sumit Bansal, Ashish Suri, Mehar Chand Sharma<sup>1</sup>, Aanchal Kakkar<sup>1</sup>

Departments of Neurosurgery and <sup>1</sup>Neuropathology, All India Institute of Medical Sciences, New Delhi, India

## ABSTRACT

Spinal cysticercosis is a very uncommon manifestation of neurocysticercosis, which is caused by the larvae of *Taenia solium*. Here, we present a rare case of isolated lumbar intradural extramedullary neurocysticercosis, initially thought to be Tarlov cyst. A 40-year-old man, presented with low backache for 1-year with radiation of pain to right leg for 3 months. The patient was treated successfully with the surgical removal of the cyst, followed by medical treatment. Spinal neurocysticercosis should be considered in the differential diagnosis in high-risk populations, with new symptoms suggestive of a spinal mass lesion.

**Key words:** Cysticercosis, intradural extramedullary, neurocysticercosis, spinal cysticercosis, *Taenia solium*

## Introduction

Cysticercosis is the most common parasitic disease of the central nervous system and is caused by cysticercus cellulosae, the metacestode state of *Taenia solium*.<sup>[1-3]</sup> Spinal involvement of cysticercosis is very rare (incidence = 1-3%).<sup>[1,3,4]</sup> As per Colli *et al.*<sup>[5,6]</sup> spinal distribution of cysticerci is as follows: 34% in the cervical; 44.5% in the thoracic; 15.5% in the lumbar and 6% in the sacral region. It is an endemic condition to Brazil, Peru, Mexico, Korea, India, South America, Tropical African, and Southeast Asian countries.<sup>[7-9]</sup> In this report, we present a rare case of spinal intradural extramedullary cystic lesion at L5 level, which was treated by surgical excision, followed by medical treatment.

## Case Report

### Presentation

A 40-year-old male suffered from severe low backache for 1-year and pain in right leg for 3 months. Neurological examination showed no motor deficit.

## Imaging

Contrast-enhanced magnetic resonance imaging (MRI) of the lumbar spine revealed well-defined intradural extramedullary cystic lesion, which was isointense on T1-weighted and hypointense on T2-weighted images at the L5-S1 level, with intense contrast enhancement [Figure 1], initially thought to be Tarlov cyst.

## Operative procedure

We performed L5 laminectomy. Intraoperatively, there was no extradural lesion, on opening dura at L5 level, we performed longitudinal durotomy to identify the intradural extramedullary lesion. At first, we detected moderate, severe adhesion of cauda equina and did not expect anything such as hematoma or cystic lesion. After a more dissection of the cauda equina, a well-capsulated cysts adherent to sacral roots and adjacent dura was noted. After the careful incision of the cystic wall under the microsurgical techniques, clear cystic fluid was gushed out, and it was sucked out by the suction. The grape-like multiple whitish small masses within the cyst were found and removed in a piecemeal fashion. Duroplasty with fascia done and wound closed after copious irrigation with saline.

Access this article online	
Quick Response Code:	Website: www.asianjns.org
	DOI: 10.4103/1793-5482.150225

### Address for correspondence:

Dr. Ashish Suri, Department of Neurosurgery, Room No. 712, Neurosciences Center, All India Institute of Medical Sciences, New Delhi - 110 029, India.  
E-mail: surineuro@gmail.com

This is an open access article distributed under the terms of the Creative Commons Attribution-NonCommercial-ShareAlike 3.0 License, which allows others to remix, tweak, and build upon the work non-commercially, as long as the author is credited and the new creations are licensed under the identical terms.

**For reprints contact:** reprints@medknow.com

**How to cite this article:** Bansal S, Suri A, Sharma MC, Kakkar A. Isolated lumbar intradural extra medullary spinal cysticercosis simulating tarlov cyst. Asian J Neurosurg 2017;12:279-82.

Immediately after the operation, the patient showed improvement of his low backache and right leg pain. He was discharged 4 days after surgery. MRI after surgery showed total excision of the cystic mass [Figure 2].

### Histopathology

Histopathological examination revealed the presence of larval forms of cysticercus with a fibrous pseudocapsule [Figure 3].

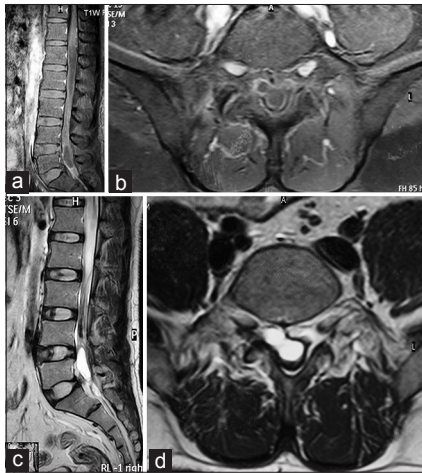
### Follow-up

Subsequently, he was treated with albendazole (15 mg/kg/day) for 4 weeks to prevent recurrence. Corticosteroid treatment was also added to reduce the inflammatory reaction during the early postoperative period.

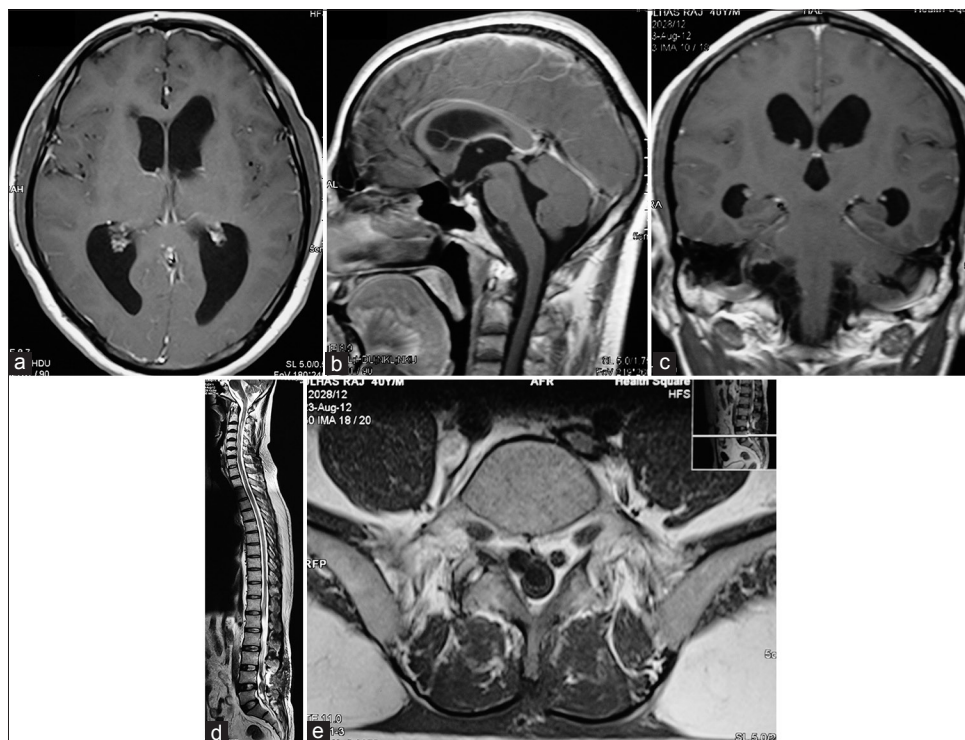
### Discussion

Cysticercosis is the most common parasitic infection of the central nervous system and results from direct ingestion of cysticercal eggs contaminated by human or porcine feces. The incidence of the spinal cysticercosis ranges from 1% to 3% compared with intracranial cysticercosis.<sup>[3,10]</sup> Colli *et al.* suggested the hypothesis of “sieve effect” at the transition level between intracranial and intraspinal subarachnoid space to account for the relatively lower incidence of the spinal cysticercosis.<sup>[11]</sup>

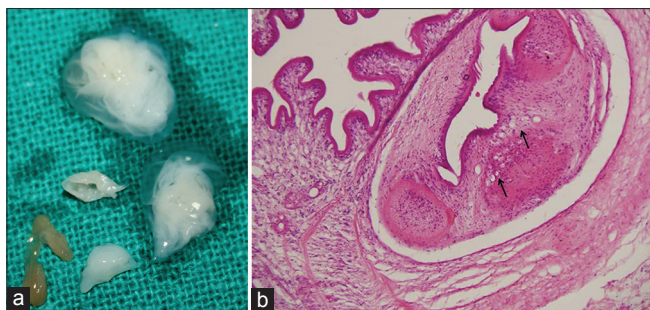
Spinal cysticercosis can occur in either the subarachnoid space or the spinal cord. Subarachnoid location of the spinal cysticercosis occurs most frequently in approximately 80% of cases.<sup>[1,12]</sup> There are several routes for disseminating parasite to spinal subarachnoid space. The most reliable route is the cerebrospinal fluid (CSF). It is thought to result from larval migration through the ventricular system into the spinal subarachnoid space.<sup>[11]</sup> Intramedullary cysticercosis is considered, as a result, from the hematogenous spread, but Paterakis *et al.* suggested that, as well as CSF dissemination, hematogenous migration is also possible in cases of extramedullary cysticercosis.<sup>[1,4,11]</sup>



**Figure 1:** Magnetic resonance imaging of the lumbo-sacral spine. Contrast sagittal and axial T1-weighted images showing one cystic structures with an avid ring of enhancement at L5 level with displacement of the roots peripherally (a and b). T2-weighted images showing hyper intense lesion at L5 level (c and d)



**Figure 2:** Contrast magnetic resonance imaging of brain showing no intracranial lesion (a-c), Postoperative T2-weighted sagittal image (d) and axial contrast T1-weighted image (e) Complete excision of lesion at L5 level with no evidence of concurrent lesion on screening of whole spine



**Figure 3:** Resected gross specimen, (a) and photomicrograph of hematoxylin and eosin stained section, (b) cysticercus cellulosae with an undulating bladder wall and scolex. Three suckers along with rows of hooklets (arrow) can be identified on the scolex ( $\times 200$ , original magnification)

More detailed evaluations for the spinal cysticercosis are usually necessary before treatment for the following patients:<sup>[13]</sup> (1) The patient with a history of the intermittent neurologic symptoms including, typical back pain, radicular leg pain with progressive motor weakness; (2) the patients showing inflammatory reaction such as diffuse leptomeningeal enhancement with cystic lesion on MRI; (3) those who came from endemic areas.

According to some authors, nearly 50% of patients who underwent spinal surgery for the spinal cysticercosis have experienced continued, or recurrent symptoms attributed to arachnoidal inflammation.<sup>[11,14,15]</sup>

MRI is the diagnostic study of choice for evaluating the spinal cysticercosis because it provides noninvasive images of a large area of the spinal cord, cauda equina and any potential intraspinal pathological entity.<sup>[9]</sup> Because MRI can demonstrate the various pathophysiological stages of the spinal cysticercosis, there are no unique radiological features.<sup>[7,8,15]</sup> Furthermore, other pathologies, such as arachnoid cysts, dermoid cysts, hydatid cysts, tuberculosis, sarcoidosis and forms of subarachnoid neoplasia, have similar radiologic findings.<sup>[2,3]</sup> Furthermore, the complete assessments of entire neuraxis are mandatory in cases of the spinal cysticercosis, because solitary lesion is extremely rare. In our case, there was no other lesion on screening whole cranio-spinal axis [Figure 2].

As surgical excision can give a definite diagnosis and alleviate compressive symptoms, majority considered surgery as first-line treatment.<sup>[3,11,16]</sup> According to the American Society for Microbiology Current Consensus Guidelines for Treatment of Neurocysticercosis,<sup>[17]</sup> the treatment of the spinal cysticercosis, intra- or extramedullary, is primarily surgical. Hamed and El-Metaal.<sup>[18]</sup> suggest that surgical treatment of the spinal cysticercosis is appropriate for the exact diagnosis and efficient treatment due to nonavailability of immunologic tests and short mean period of medical observation in

the developing country that is an endemic area. Surgical treatment, nevertheless, is not always a guarantee for a good prognosis. In addition, as surgery related high mortality and morbidity rate (15 and 85%, respectively) have been reported, medical treatment with cysticidal drugs may be tried.<sup>[2,10]</sup> Albendazole and praziquantel are still the most commonly used cysticidal drugs that are able to destroy most of the spinal and intracranial parasites. However, very high doses of albendazole for viable cyst may increase the inflammatory reaction around the cysticerci during its degeneration, and could result in neurological worsening.<sup>[11]</sup> Simultaneous administration of steroid is necessary for prevention of neurological deterioration due to inflammatory reaction.

## Conclusion

Spinal cysticercosis is extremely rare and it is very difficult to make accurate diagnosis only by observing the neurologic symptoms or radiologic findings. Spinal neurocysticercosis should be considered in the differential diagnosis in high-risk populations with radicular pain without motor deficit with spinal cystic lesion in endemic area.

## Financial support and sponsorship

Nil.

## Conflicts of interest

There are no conflicts of interest.

## References

1. Alsina GA, Johnson JP, McBride DQ, Rhoten PR, Mehringer CM, Stokes JK. Spinal neurocysticercosis. *Neurosurg Focus* 2002;12:e8.
2. Chang KH, Han MH. MRI of CNS parasitic diseases. *J Magn Reson Imaging* 1998;8:297-307.
3. Ciftçi E, Diaz-Marchan PJ, Hayman LA. Intradural-extramedullary spinal cysticercosis: MR imaging findings. *Comput Med Imaging Graph* 1999;23:161-4.
4. Paterakis KN, Kapsalaki E, Hadjigeorgiou GM, Barbanis S, Fezoulidis I, Kourtopoulos H. Primary spinal intradural extramedullary cysticercosis. *Surg Neurol* 2007;68:309-11.
5. Colli BO, Assirati JA Jr, Machado HR, dos Santos F, Takayanagi OM. Cysticercosis of the central nervous system. II. Spinal cysticercosis. *Arq Neuropsiquiatr* 1994;52:187-99.
6. Kishore LT, Gayatri K, Naidu MR, Mateen MA, Dinakar I, Ratnakar KS. Intermedullary spinal cord cysticercosis – A case report and literature review. *Indian J Pathol Microbiol* 1991;34:219-21.
7. do Amaral LL, Ferreira RM, da Rocha AJ, Ferreira NP. Neurocysticercosis: Evaluation with advanced magnetic resonance techniques and atypical forms. *Top Magn Reson Imaging* 2005;16:127-44.
8. García HH, Del Brutto OH. Imaging findings in neurocysticercosis. *Acta Trop* 2003;87:71-8.
9. Garcia E, Sotelo J. A new complement fixation test for the diagnosis of neurocysticercosis in cerebrospinal fluid. *J Neurol* 1991;238:379-82.
10. Torabi AM, Quiceno M, Mendelsohn DB, Powell CM. Multilevel intramedullary spinal neurocysticercosis with eosinophilic meningitis. *Arch Neurol* 2004;61:770-2.
11. Colli BO, Valença MM, Carlotti CG Jr, Machado HR, Assirati JA Jr. Spinal cord cysticercosis: Neurosurgical aspects. *Neurosurg Focus* 2002;12:e9.
12. Leite CC, Jinkins JR, Escobar BE, Magalhães AC, Gomes GC, Dib G,

- et al.* MR imaging of intramedullary and intradural-extramedullary spinal cysticercosis. *AJR Am J Roentgenol* 1997;169:1713-7.
13. Choi KB, Hwang BW, Choi WG, Lee SH. Herniated lumbar disc combined with spinal intradural extramedullary cysticercosis. *J Korean Neurosurg Soc* 2010;48:547-50.
  14. Mohanty A, Venkatrama SK, Das S, Das BS, Rao BR, Vasudev MK. Spinal intramedullary cysticercosis. *Neurosurgery* 1997;40:82-7.
  15. Rahalkar MD, Shetty DD, Kelkar AB, Kelkar AA, Kinare AS, Ambardekar ST. The many faces of cysticercosis. *Clin Radiol* 2000;55:668-74.
  16. Colli BO, Martelli N, Assirati JA Jr, Machado HR, de Vergueiro Forjaz S. Results of surgical treatment of neurocysticercosis in 69 cases. *J Neurosurg* 1986;65:309-15.
  17. García HH, Evans CA, Nash TE, Takayanagui OM, White AC Jr, Botero D, *et al.* Current consensus guidelines for treatment of neurocysticercosis. *Clin Microbiol Rev* 2002;15:747-56.
  18. Hamed SA, El-Metaal HE. Unusual presentations of neurocysticercosis. *Acta Neurol Scand* 2007;115:192-8.