

[CASE REPORT]

Intermittent Purpura Development Associated with Leukocytoclastic Vasculitis Induced by Infliximab for Crohn's Disease

Kenichi Kishimoto¹, Kousaku Kawashima¹, Mai Fukunaga¹, Satoshi Kotani¹, Hiroki Sonoyama¹, Akihiko Oka¹, Yoshiyuki Mishima¹, Naoki Oshima¹, Norihisa Ishimura¹, Noriyoshi Ishikawa², Riruke Maruyama² and Shunji Ishihara¹

Abstract:

Anti-tumor necrosis factor (TNF) α agents, widely used for the treatment of Crohn's disease (CD), can sometimes induce skin-associated adverse events, which mainly include psoriasis-like eruptions, eczema, and cutaneous infections. In contrast, purpura caused by vasculitis is rarely seen. We herein report a unique case of leukocytoclastic vasculitis induced by infliximab administered for CD in which intermittent purpura development was noted. Fluorescent immunostaining showed no immunoglobulin A deposition on the vessel walls. No purpura was initially seen after starting infliximab, but it appeared approximately 10 months later; however, administration did not have to be discontinued, and the condition was later resolved. The present findings provide important details regarding vasculitis induced by anti-tumor necrosis factor- α agent administration.

Key words: leukocytoclastic vasculitis, Crohn's disease, infliximab, purpura

(Intern Med 60: 385-389, 2021)

(DOI: 10.2169/internalmedicine.5340-20)

Introduction

Anti-tumor necrosis factor- α (TNF α) agents, such as infliximab and adalimumab, have revolutionized the management of Crohn's disease (CD). Although these drugs are generally well tolerated, adverse reactions will inevitably occur more frequently as increasing numbers of patients receive this treatment.

A previous report of adverse events noted infections, an increased risk of cancer and lymphoma, demyelinating disorders, cardiovascular disease, and autoimmune disorder (1). Furthermore, the proportion of skin-related adverse events has been reported to range from 20.5-29% in inflammatory bowel disease (IBD) patients treated with anti-TNF α therapy (2, 3). Cutaneous complications mainly include psoriasis-like or papulopustular eruptions, cutaneous infec-

tion, and injection site reactions. However, few reports regarding the development of purpura caused by vasculitis have been presented (4-6).

We herein report a patient with CD who developed intermittent purpura associated with leukocytoclastic vasculitis induced by infliximab.

Case Report

A 16-year-old boy had suffered from abdominal pain and diarrhea for 1 month. Colonoscopy findings obtained at a local clinic revealed multiple ulcers in the terminal ileum and entire colon, and he was referred to our hospital under suspicion of CD.

At our initial examination, the patient had a high-grade fever of 38.8 °C, while lower abdominal tenderness was noted, and erythema nodosum was observed on the front of

¹Department of Internal Medicine II, Shimane University Faculty of Medicine, Japan and ²Department of Pathology, Shimane University Faculty of Medicine, Japan

Received: May 14, 2020; Accepted: July 6, 2020; Advance Publication by J-STAGE: August 29, 2020

Correspondence to Dr. Kousaku Kawashima, kk461223@med.shimane-u.ac.jp

the lower legs (Fig. 1). Laboratory tests showed an elevated C-reactive protein (CRP) level of 7.78 mg/dL and an erythrocyte sedimentation rate (ESR) of 68 mm/h. Double-balloon enteroscopy revealed longitudinal ulcers and cobblestone lesions in the ileum as well as throughout the entire colon (Fig. 2). Mucosal biopsy specimens were obtained, and histological findings showed infiltration of lymphocytes in the stroma and evidence indicating granuloma. Based on the above findings, we made a diagnosis of ileocolic CD.

The patient had a large number of affected lesions in the small intestine and deep ulcerations, as well as a CD activity index (CDAI) of 286 points, so infliximab at 5 mg/kg (300 mg) was started in addition to daily oral mesalazine at 3000 mg (7). The time course of symptoms and treatments after the introduction of infliximab is shown in Fig. 3. After starting therapy, clinical remission was rapidly achieved, laboratory data such as CRP were normalized, and erythema nodosum disappeared. However, at the time of the sixth ad-

ministration of infliximab, the number of liquid stools was noted to be increased, the CRP level was slightly elevated, and the CDAI had increased to 158. No evidence of pathogenic bacteria was noted in stool sample cultures, and *Clostridioides difficile* toxin and cytomegalovirus antigenemia tests were negative. The patient was considered to have secondary failure to infliximab, and the dose was increased to 10 mg/kg (600 mg) from the seventh administration, following the receipt of patient approval. On the day following the eighth administration (10 months after starting therapy), rice-sized sporadic purple spots appeared on both sides of the lower legs and feet but then spontaneously disappeared approximately 1 week later (Fig. 4). Similar eruptions were again observed following the ninth administration, so a skin biopsy was performed 3 days after the 10th administration.

The histopathological findings of those specimens revealed lymphocyte infiltration and erythrocyte leakage around blood vessels in the upper layer of the dermis, consistent with leukocytoclastic vasculitis (Fig. 5). Fluorescent immunostaining showed no deposition of immunoglobulin or complement on vessel walls, including IgA, IgG, IgM, C3, C1q, and fibrinogen (Fig. 5). Laboratory results obtained at the time of purpura appearance showed normal liver and renal functions, no anemia, and a normal white blood cell count, and the CRP level was also within normal limits. IgE was elevated to 1,305 mg/dL, whereas the IgG, IgM, and IgA levels were not increased. Antinuclear antibodies, myeloperoxidase-anti-neutrophil cytoplasmic antibody (MPO-ANCA), and proteinase-3-ANCA (PR3-ANCA) were negative. A urinalysis was negative for proteinuria and microscopic hematuria.

Purpura appeared again following the next administration of infliximab. IgA deposition in the vascular wall was not detected, so we diagnosed the purpura as infliximab-induced vasculitis. Accordingly, the dose of infliximab was reduced to 8 mg/kg (500 mg), and the severity and extent of purpura were gradually reduced, although intermittent appearances were noted after each administration. Finally, at approxi-

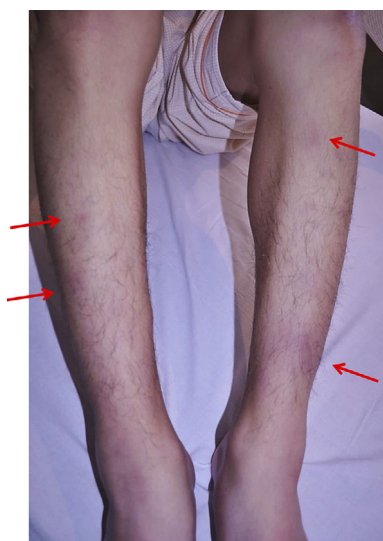

Figure 1. Erythema nodosum on the front of the lower legs (red arrows).

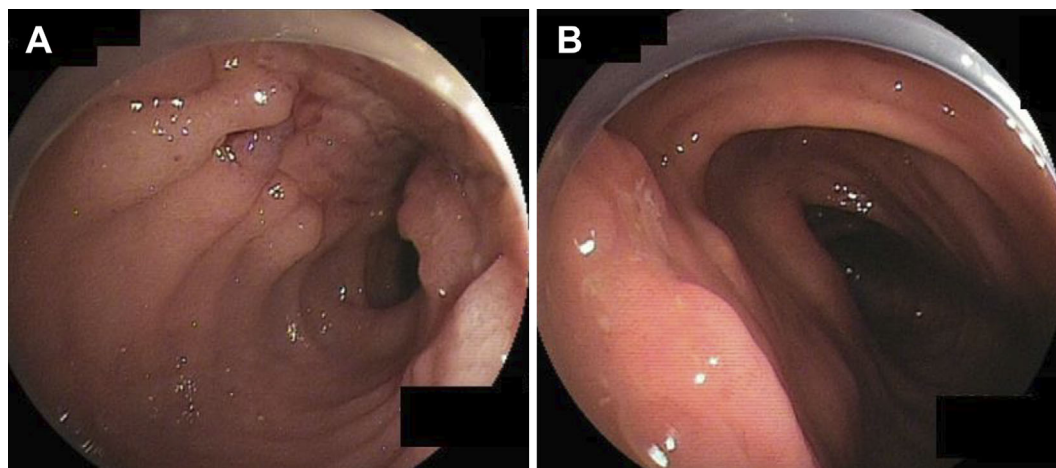


Figure 2. Double-balloon enteroscopy findings. (A) Longitudinal ulcer on ileum located 25 cm from the ileocecal valve. (B) Ulcer at the ascending colon.

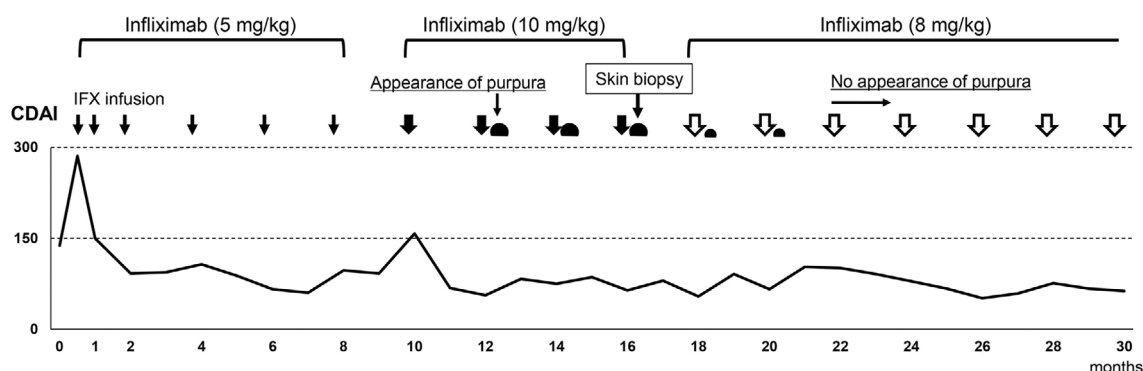


Figure 3. Clinical course following infliximab introduction. The vertical axis shows the Crohn's disease activity index (CDAI), while the horizontal axis shows the time in months. Infliximab administration is indicated by arrows, and the semicircles indicate the appearance of purpura.

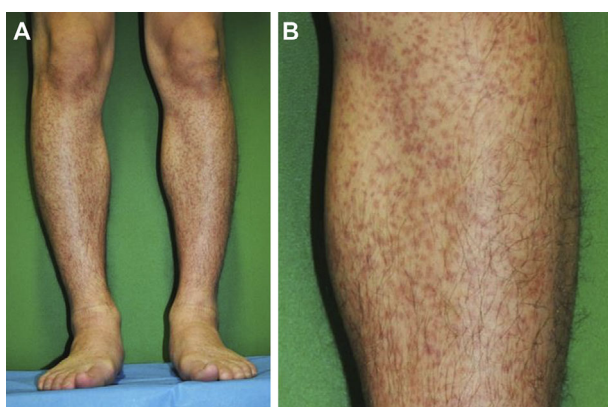


Figure 4. (A) Rice-sized sporadic purple spots on both sides of the lower legs. (B) Enlargement of the image shown in A.

mately 10 months after the first appearance, purpura was no longer seen, and the administration of infliximab continued. At the time of writing, there has been no reappearance of purpura in the patient.

Discussion

TNF- α is a cytokine that plays a crucial role in development of inflammation, mainly by causing T-cell-mediated tissue damage (8). Infliximab, a chimeric anti-TNF α agent composed of 75% human-derived and 25% mouse-derived protein, is commonly used for the induction of remission and maintenance thereafter in patients with refractory, steroid-dependent, or fistulizing CD.

Previous studies have found that use of anti-TNF α agents can occasionally induce autoimmune diseases as adverse effects, such as vasculitis, lupus-like symptoms, and interstitial lung diseases, as well as others. In a review of previously reported cases ($n=113$) of vasculitis that developed after receiving anti-TNF α therapy (1), the underlying disease was rheumatoid arthritis (RA) in 84%, CD in 6%, juvenile RA in 4%, and others in 6%. The causative drug was etanercept in 52%, infliximab in 42%, adalimumab in 4%, and others in 2%, and cutaneous involvement included palpable purpura

in 57%, ulcerated lesions in 9%, nodular lesions in 9%, erythematous punctuate lesions in 6%, erythematous papules/macules in 5%, and was not specified in 12%. Regarding the treatment of vasculitis, 89% of patients required withdrawal of anti-TNF α therapy, while therapy was continued in the remaining 11% (12 of 113), with the conditions resolved in 9 patients. Similarly, a report of 39 cases of vasculitis induced by a TNF α antagonist in France (9) noted that the administration was stopped in 33, while 6 patients were able to continue therapy, with abnormalities resolved in each of those 6 cases. Of those six who were able to continue therapy, two had peripheral nervous system lesions complicated with skin lesions. However, there was no renal involvement reported in those cases. Regarding treatment for vasculitis, three patients received antimalarial treatment for immunomodulatory effects, although the details regarding the dosage of the TNF α antagonists were not described. These results indicate that some patients affected by vasculitis induced by anti-TNF α agents do not require discontinuation of therapy.

Three cases of Henoch-Schönlein purpura, currently defined as IgA vasculitis, induced by anti-TNF α agents for the treatment of IBD have been reported in which discontinuation of the agents was required (10, 11) or the patient switched to another anti-TNF α agent (12). Each case was diagnosed based on the combination of symptoms and pathologically proven leukocytoclastic vasculitis using Michel's diagnostic criteria (13) and those defined by the American College of Rheumatology (14). However, IgA fluorescent immunostaining of skin biopsy specimens was not performed in any of those cases. An important finding of the present investigation is that IgA deposition was not detected by fluorescent immunostaining of skin biopsy specimens. The conditions in our patient were not considered to be IgA-mediated, so the diagnosis was drug-induced leukocytoclastic vasculitis. Previous case reports regarding Henoch-Schönlein purpura complicating anti-TNF α therapy for IBD may have included cases with conditions not fully consistent with etiological IgA vasculitis.

Several studies have speculated regarding the occurrence

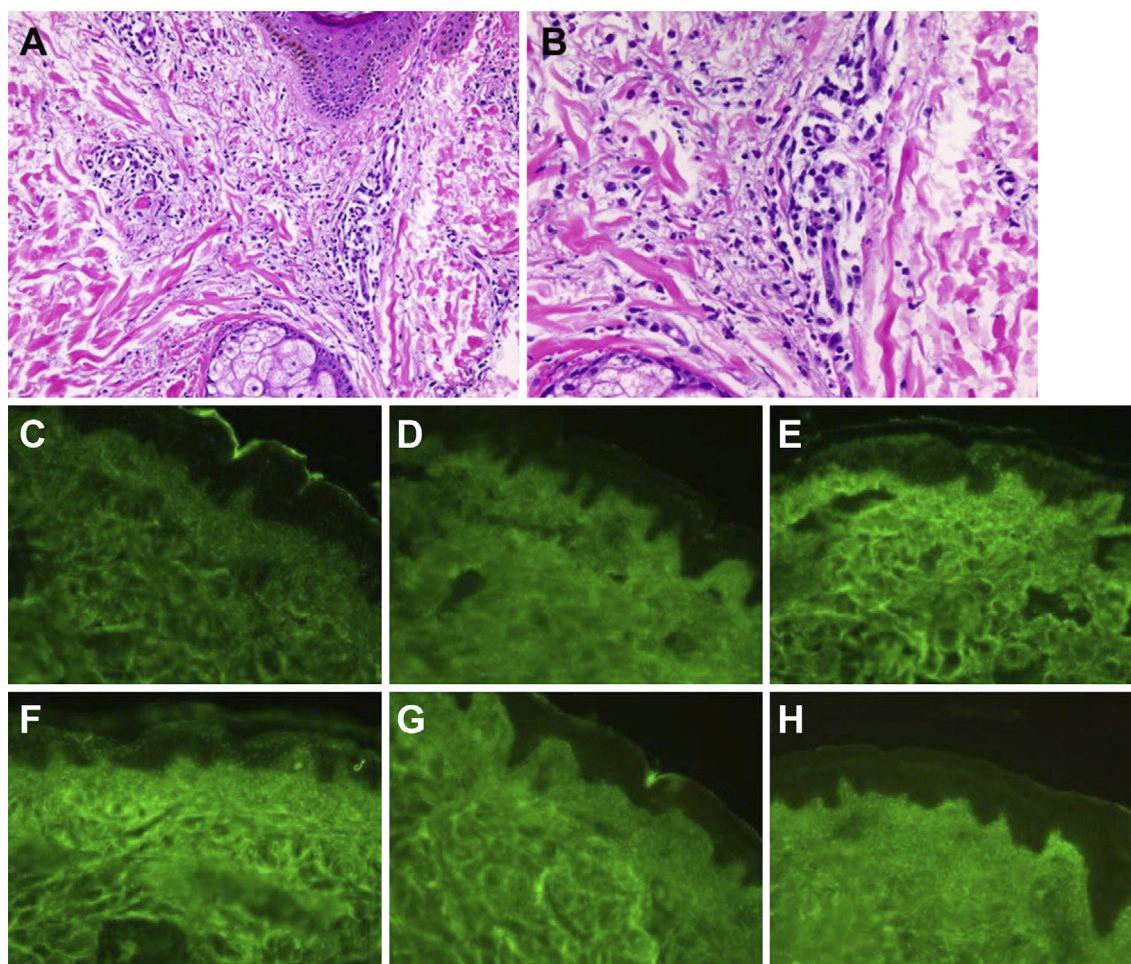


Figure 5. Skin biopsy histopathological findings. (A) Hematoxylin and Eosin staining showing lymphocyte infiltration and erythrocyte leakage around blood vessels. (B) Enlargement of the image shown in A. (C-H) Fluorescent immunostaining of same specimen showing (C) fibrinogen, (D) C3, (E) IgG, (F) IgA, (G) IgM, and (H) C1q. No deposition of immunoglobulin or complement was found in the vessel walls.

of vasculitis in association with anti-TNF α therapy. One of those mentioned depositions of anti-TNF/TNF immune complexes in small capillaries on vessel walls that induce local activation of the complement system (type III hypersensitivity reaction) (9), while another considered that suppression of TNF α alters cytokine balance, leading to Th2 predominance (15). Furthermore, direct drug toxicity may have an influence on vessel walls (12). Nevertheless, the detailed mechanisms of vasculitis have yet to be clarified. In the present patient, skin lesions gradually disappeared after dose reduction of infliximab, although whether or not that contributed to purpura improvement remains unclear.

In clinical practice, it is important to be aware of vasculitis associated with anti-TNF α agent administration when purpura is encountered in a patient receiving such therapy. Following a confirmed diagnosis of vasculitis, the attending physician should pay careful attention to renal failure as a complication, as that can be life-threatening. Renal involvement was reported in 13% of the 113 cases noted above (1). Patients with polyarteritis nodosa are also reported to have a high risk of mortality from multiple organ failure and strict

caution is required (9). In our case, we were able to observe the clinical course of vasculitis without discontinuation of anti-TNF α agent therapy, because no complications were detected in other organs and vasculitis gradually improved. However, if renal dysfunction is presented, the anti-TNF α agent should be discontinued, and steroid administration will likely be necessary.

In conclusion, we encountered a unique case of a patient with CD who developed intermittent purpura associated with leukocytoclastic vasculitis induced by infliximab. Our diagnosis was drug-induced vasculitis, which is not consistent with IgA vasculitis etiologically. The present findings provide important details regarding vasculitis induced by anti-TNF α agent administration.

The authors state that they have no Conflict of Interest (COI).

References

1. Ramos-Casals M, Brito-Zerón P, Muñoz S, et al. Autoimmune diseases induced by TNF-targeted therapies: analysis of 233 cases.

- Medicine (Baltimore) **86**: 242-251, 2007.
2. Fréling E, Baumann C, Cuny JF, et al. Cumulative incidence of, risk factors for, and outcome of dermatological complications of anti-TNF therapy in inflammatory bowel disease: a 14-year experience. *Am J Gastroenterol* **110**: 1186-1196, 2015.
 3. Cleyneen I, Van Moerkercke W, Billiet T, et al. Characteristics of skin lesions associated with anti-tumor necrosis factor therapy in patients with inflammatory bowel disease: a cohort study. *Ann Intern Med* **164**: 11-22, 2016.
 4. Moustou AE, Matekovits A, Dessinioti C, Antoniou C, Sfrikakis PP, Stratigos AJ. Cutaneous side effects of anti-tumor necrosis factor biologic therapy: a clinical review. *J Am Acad Dermatol* **61**: 486-504, 2009.
 5. Moran GW, Lim AW, Bailey JL, et al. Review article: dermatological complications of immunosuppressive and anti-TNF therapy in inflammatory bowel disease. *Aliment Pharmacol Ther* **38**: 1002-1024, 2013.
 6. Mocci G, Marzo M, Papa A, Armuzzi A, Guidi L. Dermatological adverse reactions during anti-TNF treatments: focus on inflammatory bowel disease. *J Crohns Colitis* **7**: 769-779, 2013.
 7. Torres J, Bonovas S, Doherty G, et al. ECCO guidelines on therapeutics in Crohn's disease: medical treatment. *J Crohns Colitis* **14**: 4-22, 2020.
 8. Colombel JF, Sandborn WJ, Rutgeerts P, et al. Adalimumab for maintenance of clinical response and remission in patients with Crohn's disease: the CHARM trial. *Gastroenterology* **132**: 52-65, 2007.
 9. Saint Marcoux B, De Bandt M. Vasculitides induced by TNF α antagonists: a study in 39 patients in France. *Joint Bone Spine* **73**: 710-713, 2006.
 10. Song Y, Shi YH, He C, et al. Severe Henoch-Schönlein purpura with infliximab for ulcerative colitis. *World J Gastroenterol* **21**: 6082-6087, 2015.
 11. Rahman FZ, Takhar GK, Roy O, Shepherd A, Bloom SL, McCartney SA. Henoch-Schönlein purpura complicating adalimumab therapy for Crohn's disease. *World J Gastrointest Pharmacol Ther* **1**: 119-122, 2010.
 12. Marques I, Lagos A, Reis J, Pinto A, Neves B. Reversible Henoch-Schönlein purpura complicating adalimumab therapy. *J Crohns Colitis* **6**: 796-799, 2012.
 13. Michel BA, Hunder GG, Bloch DA, Calabrese LH. Hypersensitivity vasculitis and Henoch-Schönlein purpura: a comparison between the 2 disorders. *J Rheumatol* **19**: 721-728, 1992.
 14. Mills JA, Michel BA, Bloch DA, et al. The American College of Rheumatology 1990 criteria for the classification of Henoch-Schönlein purpura. *Arthritis Rheum* **33**: 1114-1121, 1990.
 15. Rolle AS, Zimmermann B, Poon SH. Etanercept-induced Henoch-Schönlein purpura in a patient with ankylosing spondylitis. *J Clin Rheumatol* **19**: 90-93, 2013.
- The Internal Medicine is an Open Access journal distributed under the Creative Commons Attribution-NonCommercial-NoDerivatives 4.0 International License. To view the details of this license, please visit (<https://creativecommons.org/licenses/by-nc-nd/4.0/>).