



Potential importance of early treatment of SARS-CoV-2 infection in intestinal transplant patient: A case report

Mathias Clarysse, Laurens J Ceulemans, Lucas Wauters, Nicholas Gilbo, Viktor Capiou, Gert De Hertogh, Wim Laleman, Chris Verslype, Diethard Monbaliu, Jacques Pirenne, Tim Vanuytsel

Specialty type: Transplantation

Provenance and peer review:

Unsolicited article; Externally peer reviewed.

Peer-review model: Single blind

Peer-review report's scientific quality classification

Grade A (Excellent): 0

Grade B (Very good): 0

Grade C (Good): 0

Grade D (Fair): 0

Grade E (Poor): 0

P-Reviewer: Oltean M, Sweden

Received: June 1, 2021

Peer-review started: June 1, 2021

First decision: September 2, 2021

Revised: September 13, 2021

Accepted: March 16, 2022

Article in press: March 16, 2022

Published online: April 18, 2022



Mathias Clarysse, Nicholas Gilbo, Diethard Monbaliu, Jacques Pirenne, Department of Abdominal Transplant Surgery & Transplant Coordination, University Hospitals Leuven, Leuven 3000, Vlaams-Brabant, Belgium

Mathias Clarysse, Laurens J Ceulemans, Lucas Wauters, Nicholas Gilbo, Diethard Monbaliu, Jacques Pirenne, Tim Vanuytsel, Leuven Intestinal Failure and Transplantation Center (LIFT), University Hospitals Leuven, Leuven 3000, Vlaams-Brabant, Belgium

Mathias Clarysse, Nicholas Gilbo, Diethard Monbaliu, Jacques Pirenne, Laboratory of Abdominal Transplant Surgery, Department of Microbiology, Immunology and Transplantation, KU Leuven, Leuven 3000, Vlaams-Brabant, Belgium

Laurens J Ceulemans, Department of Thoracic Surgery, University Hospitals Leuven, Leuven 3000, Vlaams-Brabant, Belgium

Laurens J Ceulemans, Laboratory of Respiratory Diseases and Thoracic Surgery (BREATHE), Department of Chronic Diseases and Metabolism (CHROMETA), KU Leuven, Leuven 3000, Vlaams-Brabant, Belgium

Lucas Wauters, Wim Laleman, Chris Verslype, Tim Vanuytsel, Department of Gastroenterology and Hepatology, University Hospitals Leuven, Leuven 3000, Vlaams-Brabant, Belgium

Lucas Wauters, Tim Vanuytsel, Translational Research Center for Gastrointestinal Disorders (TARGID), Department Chronic Diseases and Metabolism (CHROMETA), KU Leuven, Leuven 3000, Vlaams-Brabant, Belgium

Viktor Capiou, Gert De Hertogh, Department of Pathology, University Hospitals Leuven, Leuven 3000, Vlaams-Brabant, Belgium

Gert De Hertogh, Laboratory of Translational Cell & Tissue Research, KU Leuven, Leuven 3000, Vlaams-Brabant, Belgium

Chris Verslype, Laboratory of Clinical Digestive Oncology, Department of Digestive Oncology, KU Leuven, Leuven 3000, Vlaams-Brabant, Belgium

Corresponding author: Tim Vanuytsel, MD, MSc, PhD, Associate Professor, Doctor, Senior Researcher, Leuven Intestinal Failure and Transplantation Center (LIFT), University Hospitals Leuven, Herestraat 49, Leuven 3000, Vlaams-Brabant, Belgium. tim.vanuytsel@uzleuven.be

Abstract

BACKGROUND

Predispositions for severe coronavirus disease 2019 (COVID-19) are age, immunosuppression, and co-morbidity. High levels of maintenance immunosuppression render intestinal transplant (ITx) patients vulnerable for severe COVID-19. COVID-19 also provokes several gastroenterological pathologies which have not been discussed in ITx, so far.

CASE SUMMARY

During the second European COVID-19 wave in November 2020, an ITx recipient was admitted to the hospital because of electrolyte disturbances due to dehydration. Immunosuppression consisted of tacrolimus, azathioprine, and low-dose corticosteroids. During hospitalization, she tested positive on screening COVID-19 nasopharyngeal polymerase chain reaction swab, while her initial test was negative. She was initially asymptomatic and had normal inflammatory markers. Tacrolimus levels were slightly raised, as Azathioprine was temporarily halted. Due to elevated D-dimers at that time, prophylactic low-molecular weight heparin was started. Seven days after the positive test, dyspnea, anosmia, and C-reactive protein increase (25 mg/L) were noted. Remdesivir was administered during 5 d in total. High stomal output was noted in two consecutive days and several days thereafter. To exclude infection or rejection, an ileoscopy and biopsy were performed and excluded these. Four weeks later, she was discharged from the hospital and remains in good health since then.

CONCLUSION

Early eradication of severe acute respiratory syndrome coronavirus 2 in ITx recipients may be warranted to prevent acute rejection provocation by it.

Key Words: COVID-19; Intestinal transplantation; Outcome; SARS-CoV-2; Treatment; Case report

©The Author(s) 2022. Published by Baishideng Publishing Group Inc. All rights reserved.

Core Tip: Acute rejection is often seen in intestinal transplant (ITx) recipients due to the high immunogenicity of the intestinal graft. However, it might also be provoked by latent presence of viruses, due to the high immunosuppression needs. Recently, chronic latency of severe acute respiratory syndrome coronavirus 2 (SARS-CoV-2) in the intestine has been shown. Hence, early recognition, eradication, and follow-up on intestinal biopsies in ITx recipients might be warranted to prevent the potential acute rejection provocation of the intestinal graft by SARS-CoV-2.

Citation: Clarysse M, Ceulemans LJ, Wauters L, Gilbo N, Capiou V, De Hertogh G, Laleman W, Verslype C, Monbaliu D, Pirenne J, Vanuytsel T. Potential importance of early treatment of SARS-CoV-2 infection in intestinal transplant patient: A case report. *World J Transplant* 2022; 12(4): 72-78

URL: <https://www.wjgnet.com/2220-3230/full/v12/i4/72.htm>

DOI: <https://dx.doi.org/10.5500/wjt.v12.i4.72>

INTRODUCTION

Coronavirus disease 2019 (COVID-19), provoked by severe acute respiratory syndrome coronavirus 2 (SARS-CoV-2), poses a major challenge in intestinal transplantation (ITx) due to the high immunogenicity of the graft, requiring high levels of immunosuppression. In the early phase of the pandemic, patients were treated with hydroxychloroquine[1]. The treatment of SARS-CoV-2 in transplant patients was altered over time in favor of dexamethasone, antivirals, or only supportive therapy[2-4]. Next to this, it is known that SARS-CoV-2 provokes gastroenterological manifestations, due to its invasion of the enterocytes[5]. It has recently been shown that SARS-CoV-2 remained latent present in the upper gastrointestinal tract, as well as in the small intestine, until at least 3 mo post-COVID-19 positivity[6]. Several other latent gastrointestinal tract viruses are known to be able to provoke acute rejection of the intestinal graft, due to the high immunosuppression needs in these ITx recipients[7,8]. To our knowledge, the influence of SARS-CoV-2-related gastroenterological manifestations in ITx patients or the provoked risk for rejection have not been elucidated so far.

CASE PRESENTATION

Chief complaints

We recently encountered a SARS-CoV-2 infection in a 41-year-old female ITx-recipient, acquired during hospitalization for dehydration and electrolyte disturbances, during the second European COVID-19 wave in November 2020.

History of present illness

She underwent an isolated intestinal re-transplantation, combined with a kidney, in August 2019 for chronic allograft enteropathy. After her re-ITx, she underwent a conversion of her terminal ileostomy to a low ileorectal anastomosis with protective loopileostomy on September 29, 2020.

History of past illness

Her first isolated ITx was in December 2004 for chronic intestinal pseudo-obstruction with recurrent catheter sepsis. In between the two ITx procedures, she was in good health and never encountered an acute rejection, until she developed chronic allograft enteropathy for which she was back on parenteral nutrition since February 2019.

Personal and family history

Negative.

Physical examination

On admission, on October 28, 2020, she was on tacrolimus (3.5 mg bidaily, target trough level: 7-8 µg/L), azathioprine (50 mg/d), and methylprednisolone (4 mg/d). She had no fever, respiratory issues, nor recent contact with a potential COVID-19 positive patient.

Laboratory examinations

She tested negative on SARS-CoV-2 on a nasopharyngeal polymerase chain reaction (PCR)-test (Figure 1). Her lab values revealed an acute deterioration of kidney function and electrolyte disturbances. Six days after admission, on November 3, 2020, she tested positive for SARS-CoV-2 on a screening PCR-test.

Imaging examinations

There were no clinical nor biochemical signs of infection or chest X-ray alterations.

FINAL DIAGNOSIS

The final diagnosis of this presented case is mild COVID-19.

TREATMENT

Azathioprine was temporarily halted, and tacrolimus levels slightly raised towards target trough levels of 8-9 µg/L. Prophylactic low-molecular weight heparin was started as D-dimers measured 4110 ng/mL (normal ≤ 500 ng/mL). She was transferred to the COVID-19 low-care ward of our hospital. Five days later, on November 8, 2020, her stomal output increased with 227% up to 2830 mL/24 h. As rejection was suspected, ileoscopy *via* the stoma was performed on November 9, 2020, and ileal biopsies were taken (Figure 2). These excluded inflammation or rejection. That same day, anosmia and mild dyspnea with normal oxygen saturation developed. Body temperature increased until 37.8 °C and C-reactive protein level was 25 mg/L (normal < 5 mg/L). Remdesivir was intravenously administered for 5 d with 200 mg as loading dose and 100 mg daily thereafter. After the remdesivir treatment was finished, azathioprine was restarted, and tacrolimus trough levels lowered to standard levels.

OUTCOME AND FOLLOW-UP

Weekly SARS-CoV-2 PCR remained positive, until a cycle threshold (Ct)-value of 39.22 was found, 4 wk after her first positive test, on November 30, 2020, and she was removed from the COVID-19 ward as the internal hospital protocol states when the Ct-value is > 29. Stomal output kept fluctuating for 1 mo, with several days of high output (> 1200 mL/24 h). With adequate fluid replacement, renal function remained stable, and the patient could be discharged on December 2, 2020 remaining in good health since then. SARS-CoV-2 PCR remained negative since then, and 3 mo after discharge from the hospital

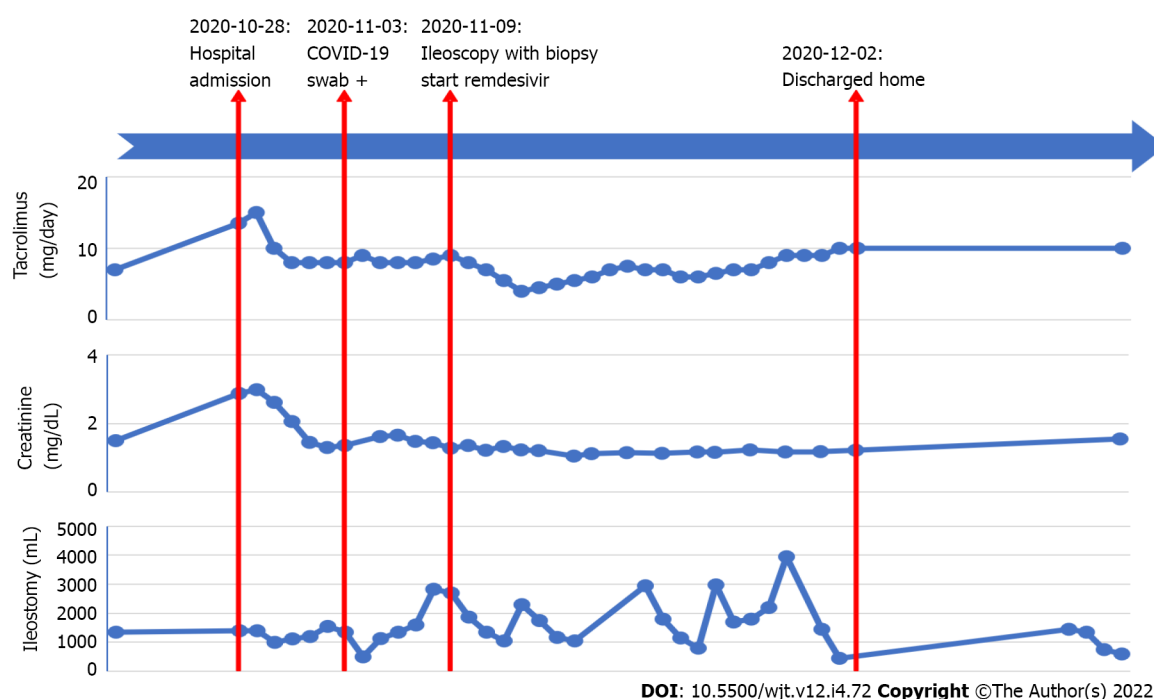


Figure 1 Timeline of case report, with immunosuppressive regimen (total daily tacrolimus dosage; bidaily administration), serum creatinine (kidney function), and stomal output evolution. COVID-19: Coronavirus disease 2019.

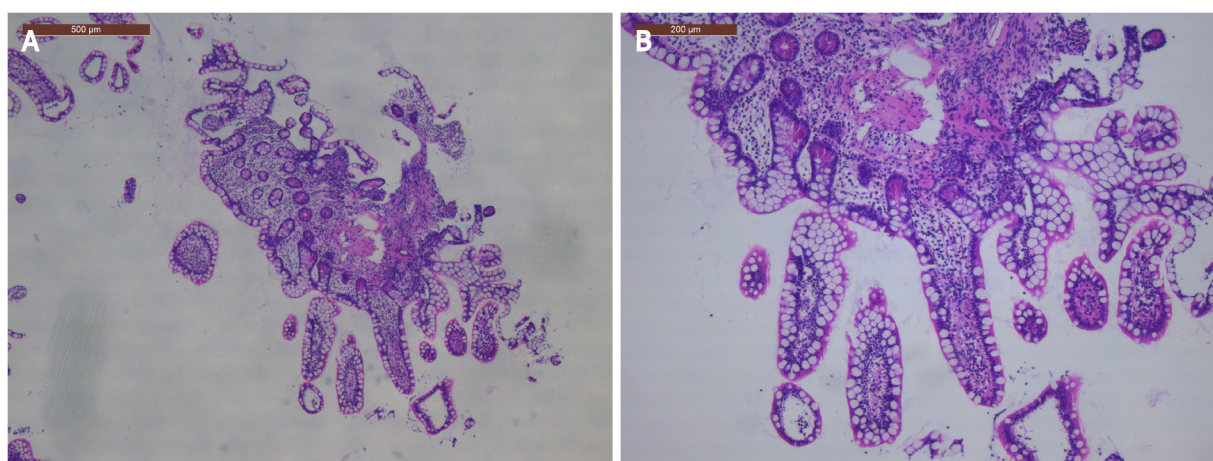


Figure 2 Histology of the intestinal transplant biopsy showing normal intestinal mucosa, without arguments for rejection or infection. A: 500 µm; B: 200 µm.

SARS-CoV-2 immunoglobulin G (IgG) nucleocapsid antigen was negative. The patient gave informed consent, and ethical approval from the institutional review board was obtained (S64844).

DISCUSSION

We present the first report, to our knowledge, of mild COVID-19 in an ITx-patient treated with remdesivir, prophylactic low-molecular weight heparin, and temporary interruption of azathioprine. As according to the currently available evidence in transplant recipients, azathioprine was halted and tacrolimus slightly raised in return[9,10]. However, it has recently been shown that solid organ transplant recipients can also be successfully treated without adjustment of immunosuppressive therapy and without any antiviral treatment[4]. Our patient was preemptively treated with remdesivir as antiviral treatment. Up till now, there is not much yet known about remdesivir treatment in solid organ transplant recipients[11]. Recent reports have shown its tolerability and safety in kidney

transplant recipients, without effects on kidney or liver function[12,13]. However, it is strongly advised to monitor regularly liver biochemistry in patients treated with remdesivir, as hepatotoxic side effects have been described[11,14].

Although gastroenterological manifestations, including diarrhea, nausea, vomiting, and loss of appetite, are commonly seen in COVID-19 patients, symptomatology was mild in our case and limited to high stomal output[5,15,16]. These clinical symptoms might also be suggestive for an acute rejection in ITx recipients, which should be treated with an increase of immunosuppression or pulse corticosteroids, which is opposite in the case of an gastroenterological infectious process[8]. This symptomatic overlap renders the cause of the gastroenterological manifestations more difficult and hence influences the treatment strategy. If not treated promptly, acute rejection might eventually lead to intestinal graft loss[17]. Only endoscopic evaluation with histopathologic confirmation of acute rejection on biopsy can make a clear differentiation. A recent study showed that D-dimers > 1850 ng/mL, which was the case in our patient (up to 4110 ng/mL), is the best discriminator to find major intestinal mucosal abnormalities at endoscopy in COVID-19 positive patients[18].

It is known that viral entrance of SARS-CoV-2, by the angiotensin-converting enzyme 2 receptor, which is abundantly present in the enterocytes of the gastrointestinal tract, plays a major role[5,6,18]. This viral entrance provokes an acute inflammatory response, which coincides with ischemic damage due to the procoagulant state and endothelialitis, which has also been observed in ITx rejection[17,18]. Several other viruses have already been shown to mimic intestinal graft rejection by crypt apoptosis, such as cytomegalovirus, Epstein-Barr virus, adenovirus, and norovirus[7,8]. Close monitoring, during the postinfectious period of these viruses, is also important as the infection might provoke acute rejection of the intestinal graft[8]. For SARS-CoV-2, such a correlation has not been shown so far. However, as shown by Gaebler *et al*[6], SARS-CoV-2 can remain latent present in even asymptomatic patients at least 3 mo post-COVID-19[6]. As SARS-CoV-2 is able to enter the enterocytes by the angiotensin-converting enzyme 2-receptor and provoke an acute inflammatory response, it is hypothetically possible that SARS-CoV-2 might mimic or provoke acute rejection of the intestinal graft in ITx recipients as well. As such, follow-up of SARS-CoV-2 antigen on routine or screening, re-rejection/infection suspicion, biopsies of the intestinal allograft might be performed in previous, current or suspected COVID-19 positive ITx recipients, as is currently the case for cytomegalovirus[7]. Early treatment and eradication of intestinal SARS-CoV-2 may be warranted to prevent the potential acute rejection mimicry or provocation.

SARS-CoV-2 nucleocapsid (N) antibodies assay, on the Abbott Architect system, was negative in our patient, despite SARS-CoV-2 positive PCR 3 mo earlier. However, it has been shown that SARS-CoV-2 IgG anti-N are positive in only 62% of SARS-CoV-2 PCR positive transplant recipients 1-2 mo post-infection, whilst these are decreasing towards only 55% at 3-4 mo and even 38% at 5-7 mo post-infection. This decline in anti-N is mainly seen in mild disease form[19]. SARS-CoV-2 spike (S) antibodies, on the contrary, are more durable with IgG anti-S present in 92% at 1-2 mo, 84% at 3-4 mo, and even 76% at 6-7 mo post-infection in transplant recipients[4]. Next to this, the analysis was run on the Abbott Architect system, of which it has been shown that it is less sensitive in transplant recipients, in comparison to non-transplant recipients and in comparison to other assets, due to a different targeting antigen[20]. It is proposed that the spike antigen is more immunogenic than the nucleocapsid antigen in immunosuppressed patients[20]. On top of that, there is evidence that spike antibodies may provide functional immunity information, as there is a correlation between spike antibodies and neutralizing antibodies[21, 22]. As such, analyzing the anti-S might be clinically more relevant than the anti-N in immunosuppressed patients[20].

CONCLUSION

Early treatment of SARS-CoV-2 should be considered in ITx recipients in order to eradicate the virus and to prevent acute rejection mimicry or provocation and potential graft loss. SARS-CoV-2 antigen determination on ileal biopsies of ITx recipients might be routinely performed to screen for the hypothesis of SARS-CoV-2 acute rejection mimicry or provocation.

FOOTNOTES

Author contributions: Clarysse M contributed review of the clinical case, review of literature, and drafting of the article; Ceulemans LJ contributed critical review of literature and the article; Wauters L, Gilbo N, Capiu V, and De Hertogh G contributed review of clinical case and critical review of article; Verslype C, Laleman W, Monbaliu D, and Pirenne J contributed critical review of the article; Vanuytsel T contributed review of the clinical case, review of literature, and review of the article; All authors issued final approval for the version to be submitted.

Informed consent statement: Study participant provided informed written consent, prior to study enrollment, and after ethical approval from the University Hospitals Leuven institutional review board (S64844).

Conflict-of-interest statement: None of the authors have any conflict of interest to disclose in relation to this study.

CARE Checklist (2016) statement: The authors have read the CARE Checklist (2016), and the manuscript was prepared and revised according to the CARE Checklist (2016).

Open-Access: This article is an open-access article that was selected by an in-house editor and fully peer-reviewed by external reviewers. It is distributed in accordance with the Creative Commons Attribution NonCommercial (CC BY-NC 4.0) license, which permits others to distribute, remix, adapt, build upon this work non-commercially, and license their derivative works on different terms, provided the original work is properly cited and the use is non-commercial. See: <https://creativecommons.org/licenses/by-nc/4.0/>

Country/Territory of origin: Belgium

ORCID number: Mathias Clarysse 0000-0002-2875-9516; Laurens J Ceulemans 0000-0002-4261-7100; Lucas Wauters 0000-0002-3195-4996; Nicholas Gilbo 0000-0001-6456-7071; Viktor Capiu 0000-0002-3116-1742; Gert De Hertogh 0000-0001-8494-7725; Wim Laleman 0000-0002-0842-7813; Chris Verslype 0000-0003-3857-466X; Diethard Monbaliu 0000-0002-0506-1609; Jacques Pirenne 0000-0002-8147-8801; Tim Vanuytsel 0000-0001-8728-0903.

Corresponding Author's Membership in Professional Societies: The Transplantation Society, No. 27551; Intestinal Rehabilitation and Transplant Association, No. 27551; International Pediatric Transplant Association, No. 27551; The International Society of Experimental Microsurgery; The European Society for Organ Transplantation, No. 12825.

S-Editor: Fan JR

L-Editor: Filipodia

P-Editor: Fan JR

REFERENCES

- 1 **Papa-Gobbi R**, Bueno A, Serradilla J, Talayero P, Stringa P, Pascual-Miguel B, Alcolea-Sánchez A, González-Sacristan R, Andrés AM, López-Santamaría M, Rumbo M, Ramos-Boluda E, Hernández-Oliveros F. Novel coronavirus (SARS-CoV-2) infection in a patient with multivisceral transplant. *Transpl Infect Dis* 2021; **23**: e13430 [PMID: 32741047 DOI: 10.1111/tid.13430]
- 2 **Sharma P**, Chen V, Fung CM, Troost JP, Patel VN, Combs M, Norman S, Garg P, Colvin M, Aaronson K, Sonnenday CJ, Golob JL, Somers EC, Doshi MM. COVID-19 Outcomes Among Solid Organ Transplant Recipients: A Case-control Study. *Transplantation* 2021; **105**: 128-137 [PMID: 32890139 DOI: 10.1097/TP.0000000000003447]
- 3 **Avery RK**. COVID-19 Therapeutics for Solid Organ Transplant Recipients; 6 Months Into the Pandemic: Where Are We Now? *Transplantation* 2021; **105**: 56-60 [PMID: 33141805 DOI: 10.1097/TP.0000000000003519]
- 4 **Softeland JM**, Friman G, von Zur-Mühlen B, Ericzon BG, Wallquist C, Karason K, Friman V, Ekelund J, Felldin M, Magnusson J, Haugen Löfman I, Schult A, de Coursey E, Leach S, Jacobsson H, Liljeqvist JÅ, Biglarnia AR, Lindnér P, Oltean M. COVID-19 in solid organ transplant recipients: A national cohort study from Sweden. *Am J Transplant* 2021; **21**: 2762-2773 [PMID: 33811777 DOI: 10.1111/ajt.16596]
- 5 **Tian Y**, Rong L, Nian W, He Y. Review article: gastrointestinal features in COVID-19 and the possibility of faecal transmission. *Aliment Pharmacol Ther* 2020; **51**: 843-851 [PMID: 32222988 DOI: 10.1111/apt.15731]
- 6 **Gaebler C**, Wang Z, Lorenzi JCC, Muecksch F, Finkin S, Tokuyama M, Cho A, Jankovic M, Schaefer-Babajew D, Oliveira TY, Cipolla M, Viant C, Barnes CO, Bram Y, Breton G, Hägglöf T, Mendoza P, Hurley A, Turroja M, Gordon K, Millard KG, Ramos V, Schmidt F, Weisblum Y, Jha D, Tankelevich M, Martinez-Delgado G, Yee J, Patel R, Dizon J, Unson-O'Brien C, Shimeliovich I, Robbiani DF, Zhao Z, Gazumyan A, Schwartz RE, Hatzioannou T, Bjorkman PJ, Mehndru S, Bieniasz PD, Caskey M, Nussenzweig MC. Evolution of antibody immunity to SARS-CoV-2. *Nature* 2021; **591**: 639-644 [PMID: 33461210 DOI: 10.1038/s41586-021-03207-w]
- 7 **Talmon GA**. Histologic features of cytomegalovirus enteritis in small bowel allografts. *Transplant Proc* 2010; **42**: 2671-2675 [PMID: 20832567 DOI: 10.1016/j.transproceed.2010.04.059]
- 8 **Soltys KA**, Reyes JD, Green M. Risks and epidemiology of infections after intestinal transplantation. In: *Transplant Infections*. 4th edition. Ljungman P, Snyderman D, Boeckh M, editors. Cham: Springer International Publishing, 2016: 235-248
- 9 **Yi SG**, Rogers AW, Saharia A, Aoun M, Faour R, Abdelrahim M, Knight RJ, Grimes K, Bullock S, Hobeika M, McMillan R, Mobley C, Moaddab M, Huang HJ, Bhimaraj A, Ghobrial RM, Gaber AO. Early Experience With COVID-19 and Solid Organ Transplantation at a US High-volume Transplant Center. *Transplantation* 2020; **104**: 2208-2214 [PMID: 32496357 DOI: 10.1097/TP.0000000000003339]
- 10 **Azzi Y**, Bartash R, Scalea J, Loarte-Campos P, Akalin E. COVID-19 and Solid Organ Transplantation: A Review Article. *Transplantation* 2021; **105**: 37-55 [PMID: 33148977 DOI: 10.1097/TP.0000000000003523]
- 11 **Elens L**, Langman LJ, Hesselink DA, Bergan S, Moes DJAR, Molinaro M, Venkataramanan R, Lemaitre F. Pharmacologic Treatment of Transplant Recipients Infected With SARS-CoV-2: Considerations Regarding Therapeutic Drug Monitoring and Drug-Drug Interactions. *Ther Drug Monit* 2020; **42**: 360-368 [PMID: 32304488 DOI: 10.1097/FTD.0000000000000761]
- 12 **Elec AD**, Oltean M, Goldis P, Cismaru C, Lupse M, Muntean A, Elec FI. COVID-19 after kidney transplantation: Early outcomes and renal function following antiviral treatment. *Int J Infect Dis* 2021; **104**: 426-432 [PMID: 33453396 DOI: 10.1016/j.ijid.2021.04.044]

- 10.1016/j.ijid.2021.01.023]
- 13 **Buxeda A**, Arias-Cabrales C, Pérez-Sáez MJ, Cacho J, Cabello Pelegrin S, Melilli E, Aladrén MJ, Galeano C, Lorenzo I, Mazuecos A, Saura IM, Franco A, Ruiz-Fuentes MDC, Sánchez-Cámara LA, Siverio O, Martín ML, González-García E, López V, Martín-Moreno PL, Moína I, Moral Berrio E, Moreso F, Portolés JM, Santana-Estupiñán R, Zárraga S, Canal C, Sánchez-Álvarez E, Pascual J, Crespo M. Use and Safety of Remdesivir in Kidney Transplant Recipients With COVID-19. *Kidney Int Rep* 2021; **6**: 2305-2315 [PMID: 34250317 DOI: 10.1016/j.ekir.2021.06.023]
- 14 **Fix OK**, Hameed B, Fontana RJ, Kwok RM, McGuire BM, Mulligan DC, Pratt DS, Russo MW, Schilsky ML, Verna EC, Loomba R, Cohen DE, Bezerra JA, Reddy KR, Chung RT. Clinical Best Practice Advice for Hepatology and Liver Transplant Providers During the COVID-19 Pandemic: AASLD Expert Panel Consensus Statement. *Hepatology* 2020; **72**: 287-304 [PMID: 32298473 DOI: 10.1002/hep.31281]
- 15 **Zhong P**, Xu J, Yang D, Shen Y, Wang L, Feng Y, Du C, Song Y, Wu C, Hu X, Sun Y. COVID-19-associated gastrointestinal and liver injury: clinical features and potential mechanisms. *Signal Transduct Target Ther* 2020; **5**: 256 [PMID: 33139693 DOI: 10.1038/s41392-020-00373-7]
- 16 **Lei HY**, Ding YH, Nie K, Dong YM, Xu JH, Yang ML, Liu MQ, Wei L, Nasser MI, Xu LY, Zhu P, Zhao MY. Potential effects of SARS-CoV-2 on the gastrointestinal tract and liver. *Biomed Pharmacother* 2021; **133**: 111064 [PMID: 33378966 DOI: 10.1016/j.biopha.2020.111064]
- 17 **Rabant M**, Racapé M, Petit LM, Taupin JL, Aubert O, Bruneau J, Barbet P, Goulet O, Chardot C, Suberbielle C, Lacaille F, Canioni D, Duong Van Huyen JP. Antibody-mediated rejection in pediatric small bowel transplantation: Capillaritis is a major determinant of C4d positivity in intestinal transplant biopsies. *Am J Transplant* 2018; **18**: 2250-2260 [PMID: 29397036 DOI: 10.1111/ajt.14685]
- 18 **Vanella G**, Capurso G, Burti C, Fanti L, Ricciardiello L, Souza Lino A, Boskoski I, Bronswijk M, Tyberg A, Krishna Kumar Nair G, Angeletti S, Mauro A, Zingone F, Oppong KW, de la Iglesia-Garcia D, Pouillon L, Papanikolaou IS, Fracasso P, Ciceri F, Rovere-Querini P, Tomba C, Viale E, Eusebi LH, Riccioni ME, van der Merwe S, Shahid H, Sarkar A, Yoo JW, Dilaghi E, Speight RA, Azzolini F, Buttitta F, Porcari S, Petrone MC, Iglesias-Garcia J, Savarino EV, Di Sabatino A, Di Giulio E, Farrell JJ, Kahaleh M, Roelandt P, Costamagna G, Artifon ELA, Bazzoli F, Testoni PA, Greco S, Arcidiacono PG. Gastrointestinal mucosal damage in patients with COVID-19 undergoing endoscopy: an international multicentre study. *BMJ Open Gastroenterol* 2021; **8** [PMID: 33627313 DOI: 10.1136/bmjgast-2020-000578]
- 19 **Chavarot N**, Leruez-Ville M, Scemla A, Burger C, Amrouche L, Rouzaud C, Lebreton X, Martinez F, Sberro-Soussan R, Legendre C, Zuber J, Anglicheau D. Decline and loss of anti-SARS-CoV-2 antibodies in kidney transplant recipients in the 6 mo following SARS-CoV-2 infection. *Kidney Int* 2021; **99**: 486-488 [PMID: 33509358 DOI: 10.1016/j.kint.2020.12.001]
- 20 **Predecki M**, Clarke C, Gleeson S, Greathead L, Santos E, McLean A, Randell P, Moore LSP, Mughal N, Guckian M, Kelleher P, Mcadoo SP, Willicombe M. Detection of SARS-CoV-2 Antibodies in Kidney Transplant Recipients. *J Am Soc Nephrol* 2020; **31**: 2753-2756 [PMID: 33122285 DOI: 10.1681/ASN.2020081152]
- 21 **Amanat F**, Stadlbauer D, Strohmeier S, Nguyen THO, Chromikova V, McMahon M, Jiang K, Arunkumar GA, Jurczyszak D, Polanco J, Bermudez-Gonzalez M, Kleiner G, Aydillo T, Miorin L, Fierer DS, Lugo LA, Kojic EM, Stoeber J, Liu STH, Cunningham-Rundles C, Felgner PL, Moran T, García-Sastre A, Caplivski D, Cheng AC, Kedzierska K, Vapalahti O, Hepojoki JM, Simon V, Krammer F. A serological assay to detect SARS-CoV-2 seroconversion in humans. *Nat Med* 2020; **26**: 1033-1036 [PMID: 32398876 DOI: 10.1038/s41591-020-0913-5]
- 22 **Premkumar L**, Segovia-Chumbez B, Jadi R, Martinez DR, Raut R, Markmann A, Cornaby C, Bartelt L, Weiss S, Park Y, Edwards CE, Weimer E, Scherer EM, Roupheal N, Edupuganti S, Weiskopf D, Tse LV, Hou YJ, Margolis D, Sette A, Collins MH, Schmitz J, Baric RS, de Silva AM. The receptor binding domain of the viral spike protein is an immunodominant and highly specific target of antibodies in SARS-CoV-2 patients. *Sci Immunol* 2020; **5** [PMID: 32527802 DOI: 10.1126/sciimmunol.abc8413]



Published by **Baishideng Publishing Group Inc**
7041 Koll Center Parkway, Suite 160, Pleasanton, CA 94566, USA

Telephone: +1-925-3991568

E-mail: bpgoffice@wjgnet.com

Help Desk: <https://www.f6publishing.com/helpdesk>

<https://www.wjgnet.com>

