

Myocardial CT perfusion imaging for pre- and postoperative evaluation of myocardial ischemia in a patient with myocardial bridging

A case report

Jae Woong Lim, MD^a, Heon Lee, MD, PhD^{b,*}, Keun Her, MD, PhD^a, Hyun Woo Park, MD^c, Kyung Eun Shin, MD, PhD^a

Abstract

Rationale: Although myocardial bridging (MB) is usually considered as benign, initial medical therapy and following surgical treatment in drug-refractory cases has been widely accepted for managing symptomatic MB. Before the patient proceeds to percutaneous or surgical intervention, however, the presence of objective ischemia in the corresponding myocardial territory should be documented.

Patient concern and intervention: We herein report a 43-year-old male complaining of chest pain in whom cardiac CT with myocardial perfusion (cCTP) showed an MB of left anterior descending artery (LAD) with preoperative perfusion defect in corresponding myocardium and normalization of perfusion after supra-arterial myotomy.

Diagnosis: Myocardial bridging-induced ischemia.

Lessons: This case illustrates the potential utility of cCTP for the simultaneous assessment of MB and its hemodynamic significance for treatment planning and post-therapeutic evaluation although further research is needed to establish the clinical usefulness of this technique.

Abbreviations: CAD = coronary artery disease, cCT = cardiac CT, cCTP = cardiac CT with myocardial perfusion, CTP = CT with myocardial perfusion, LAD = left anterior descending artery, MB = myocardial bridging.

Keywords: computed tomography, myocardial bridging, myocardial ischemia, myocardial perfusion imaging

1. Introduction

Myocardial bridging (MB) occurs when a segment of epicardial coronary artery is covered by a muscle bridge. MB is the most common congenital coronary abnormality, with a prevalence of 0.5% to 11.8% on coronary angiography and 5.7% to 58% on CT,^[1,2] and is associated with hypertrophic cardiomyopathy with a prevalence as high as 30%.^[1] Although MB may cause myocardial ischemia, infarction, arrhythmia, and sudden death,^[1–3] considering overall benign nature of MB, therapeutic

intervention is not necessary in asymptomatic cases.^[4] However, patients may require treatment when their symptom may be attributable to MB. In drug-refractory cases, before the patient proceeds to percutaneous or surgical intervention, the presence of objective ischemia in the corresponding myocardial territory should be documented by diagnostic modalities such as isotope stress testing.^[5] It is, therefore, important to evaluate its hemodynamics to determine management strategy, particularly in symptomatic patients without concomitant coronary artery disease (CAD).

Recently, we performed a combination (cCTP) of cardiac CT (cCT) with myocardial perfusion imaging (CTP) in a symptomatic young male with an MB and coexisting hypertrophic cardiomyopathy. We herein describe the cCTP findings which enabled the simultaneous assessment of morphologic abnormalities and their hemodynamic significance to guide therapeutic strategies and post-treatment assessments. To the best of our knowledge, this is the first report to illustrate the potential utility of cCTP in the evaluation of this “not uncommon” vascular anomaly to provide objective evidence of MB-induced ischemia and evaluate therapeutic effectiveness.

2. Case presentation

A 43-year-old man presented with acute chest pain refractory to medication. He had a history of MB and septal hypertrophy identified during a previous admission to investigate intermittent chest discomfort and right precordial T-wave inversion. As the initial treadmill test was negative at that time, the patient then

Editor: Salvatore Patané.

This work is supported by Soonchunhyang Research Fund.

The authors have declared no conflicts of interest.

^a Department of Thoracic and Cardiovascular Surgery, ^b Division of Cardiovascular and Thoracic Imaging, Department of Radiology, ^c Department of Cardiology, Soonchunhyang University Hospital, Bucheon, Republic of Korea.

* Correspondence: Heon Lee, Division of Cardiovascular Imaging, Department of Radiology, Soonchunhyang University Hospital Bucheon, 170 Jomaru-ro, Bucheon 14584 Republic of Korea (e-mail: acarad@naver.com).

Copyright © 2017 the Author(s). Published by Wolters Kluwer Health, Inc. This is an open access article distributed under the terms of the Creative Commons Attribution-Non Commercial-No Derivatives License 4.0 (CCBY-NC-ND), where it is permissible to download and share the work provided it is properly cited. The work cannot be changed in any way or used commercially without permission from the journal.

Medicine (2017) 96:42(e8277)

Received: 28 June 2017 / Received in final form: 12 September 2017 /

Accepted: 16 September 2017

<http://dx.doi.org/10.1097/MD.00000000000008277>

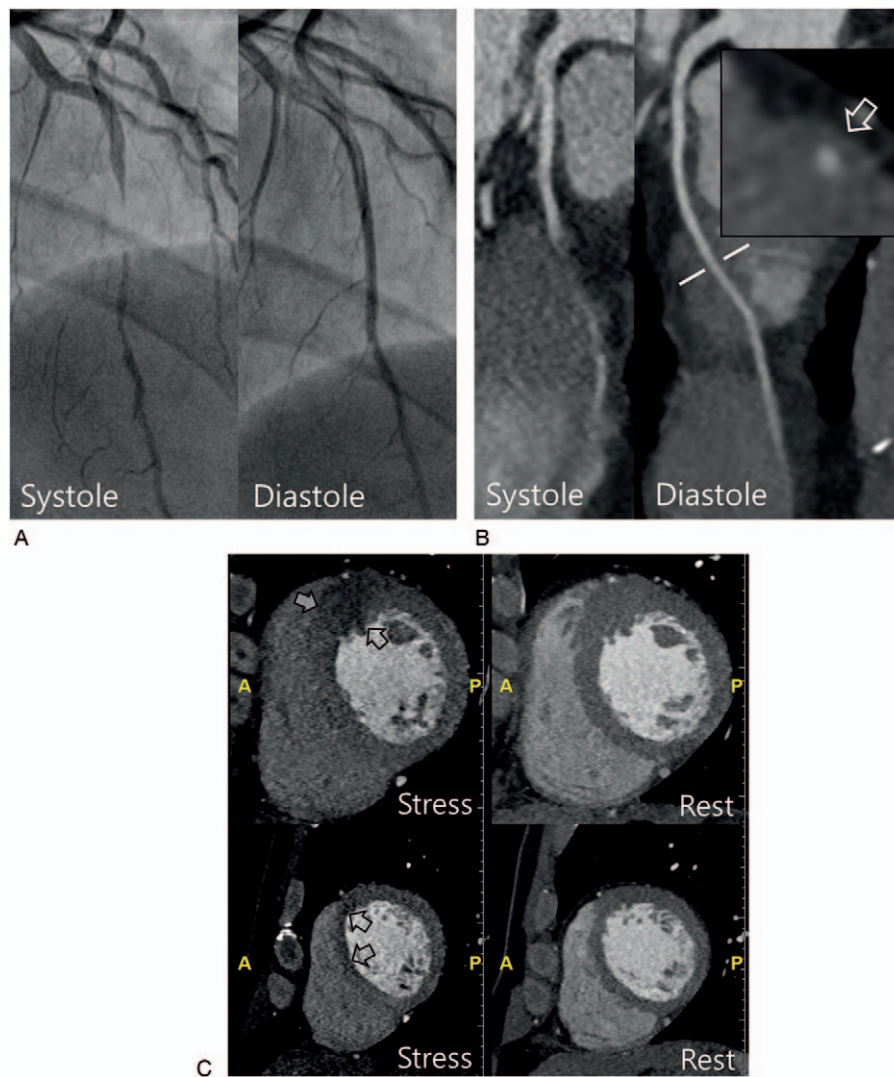


Figure 1. (A) Preoperative coronary catheter angiography demonstrated a 4-cm long segment of dynamic compression showing systolic milking of the LAD and diastolic opening of the LAD. (B) Coronary CT angiographic images showed diffuse segmental myocardial bridging with systolic compression of the mid-LAD. The cross-sectional image (box) of LAD shows the tunneled segment of the LAD with overlying hypertrophied myocardium (arrow) at the level of broken line in curved multiplanar reformatted image of LAD. (C) Myocardial stress and rest CT perfusion images in the short-axis view showed a reversible perfusion defect (arrows) in the corresponding myocardium of the anterior wall of mid (upper column) and apical (lower column) segment of the left ventricle. LAD = left anterior descending artery.

received medical treatment with a β -blocker and calcium antagonist, and he was responsive to those medications. At this visit, however, the patient was refractory to intensified medical treatment and thus underwent cCTP, which showed MB with systolic compression of the mid-left anterior descending coronary artery, and a reversible perfusion defect in the corresponding hypertrophied myocardium at the anteroseptal wall (Fig. 1). The patient had a complete type of isolated MB without other obstructive CAD, in the intramural portion with a length and depth of 24 and 1.4 mm, respectively.

The myocardial CT perfusion were performed with a 128-slice dual source CT scanner (Somatom Definition Flash, Siemens Healthcare, Germany) with the following settings: gantry rotation time, 280 ms; slice acquisition, $2 \times 128 \times 0.6$ mm; tube potential, 120 kV; and tube current-time product, 320 mA/rotation. The CT scan protocol consisted of 2 steps. First, stress CT perfusion was performed. A retrospectively gated scan with tube current modulation and pitch adaptation was obtained 3

minutes after the initiation of intravenous adenosine infusion at a dose of $140 \mu\text{g}/\text{kg}/\text{min}$. Second, after a delay of 8 minutes, rest myocardial CT perfusion/coronary CT angiography was performed using a second iodine contrast bolus injection with the same contrast bolus volume of 70 mL, followed by 40 mL saline at a flow rate of 4 mL/s as for stress CT. Based on clinical and imaging findings, surgical correction was decided and a supra-arterial myotomy was performed under the guidance of intraoperative angiography. Follow-up cCTP imaging after surgery showed successful unroofing of the intramyocardial coronary segment and normalized perfusion of the corresponding myocardium on stress test (Fig. 2). He was discharged and is currently without chest pain.

3. Discussion

Although MB is usually considered as benign, initial medical therapy and following surgical intervention in drug-refractory

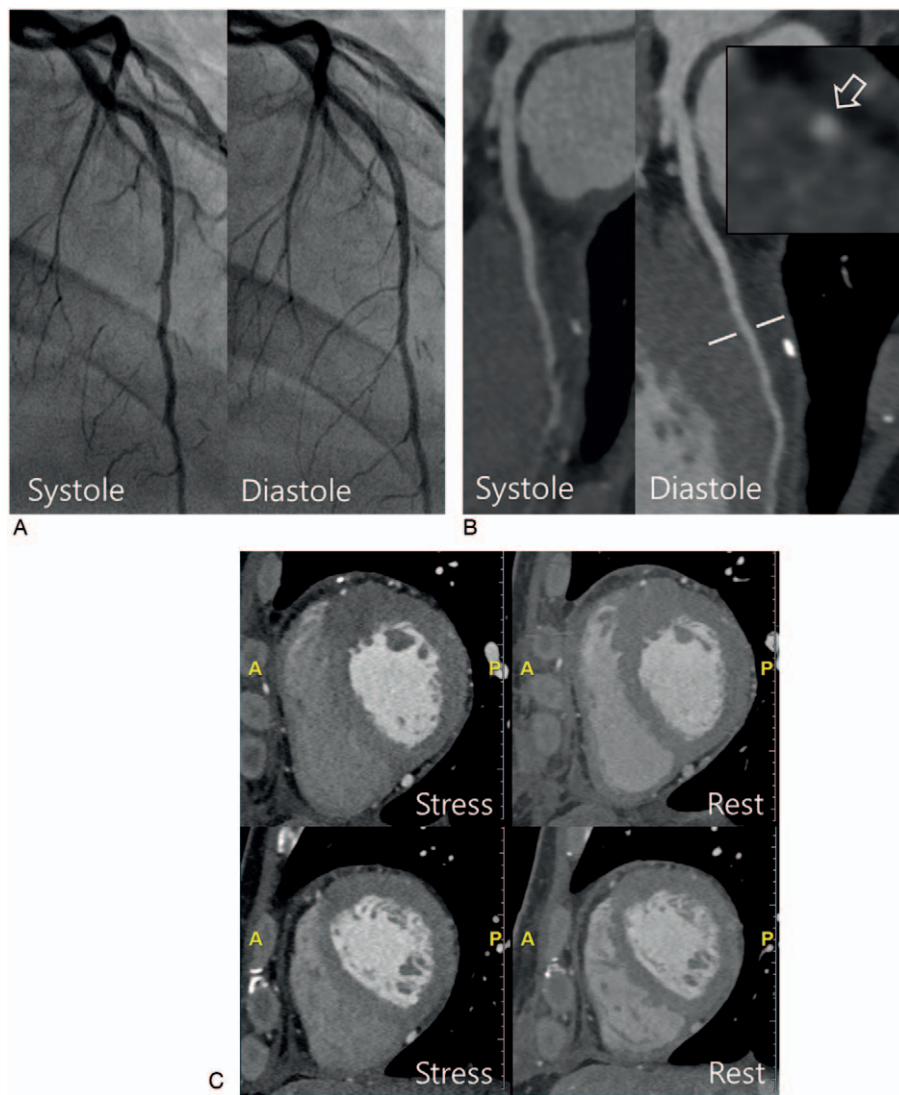


Figure 2. (A, B) Postoperative coronary catheter angiography (A) and CT (B) demonstrated complete relief of the dynamic compression of the LAD during systole. The cross-sectional image (box) shows successful myocardial unroofing of the tunneled coronary segment (arrow) at the level of broken line in curved multiplanar reformatted image of LAD. (C) Postoperative CT perfusion images show normal myocardial perfusion of the anteroseptal wall of the left ventricle. LAD = left anterior descending artery.

cases have been widely accepted for managing symptomatic cases. Before the patient proceeds to percutaneous or surgical intervention, however, the presence of ischemia in the corresponding myocardial territory should be documented by objective measurement.^[3,5] In clinical practice, the combination of morphological and functional findings helps guide the treatment of symptomatic patients^[2] although functional tests may yield inconclusive results if MB is associated with other obstructive CAD.^[5] Currently, myocardial scintigraphy is frequently used to evaluate myocardial ischemia in patients with MB.^[3,5] However, there is no consensus as to which patients need further functional testing for ischemia after the detection of MB, and therefore, the frequency of inducible ischemia in symptomatic or asymptomatic patients is not yet well investigated.^[2] Nevertheless, most investigators agreed that those tests should be reserved for symptomatic patients on the basis of current understanding that most bridges are incidental and associated with a good prognosis, although the value of stress tests as a

screening tool for inducible or silent ischemia may need further investigation.^[1-4]

With the recent developments in CT techniques, cCT has been widely accepted as a noninvasive diagnostic tool for the evaluation of CAD.^[6] However, it is a morphological imaging test and therefore cannot define the hemodynamic significance of any identified coronary stenosis. To address this concern, CT evaluation of myocardial perfusion during vasodilator stress has been introduced, which provides information about corresponding myocardial ischemia.^[7] Currently, several reports have shown that adding stress perfusion with cCT improves the diagnostic accuracy of CAD compared to cCT alone, and furthermore it has comparable diagnostic accuracy to SPECT in the detection of significant CAD.^[7,8] However, the yield of a cCTP in identifying the functional relevance of symptomatic MB has not yet been described. Furthermore, no imaging studies showed normalization of myocardial perfusion when perfusion defect was present before treatment whereas there have been

several previous studies demonstrating that stenting and surgical treatment can abolish hemodynamic disturbances and improve symptom.^[1,9] In this patient, we performed stress perfusion imaging in combination with cCT. As described, pre- and postoperative cCTP successfully revealed the isolated MB without CAD, its hemodynamic significance, and the effectiveness of the surgical correction in this case. Although cCTP also demonstrated that this patient has asymmetric septal hypertrophy, which might contribute to patient's symptom,^[11] considering the disappearance of chest pain and perfusion defect after successful myotomy, we believe MB was the primary cause of the patient's symptom.

In the last decade, increasing numbers of MB have been detected by cCT performed in the patients referred for the suspicion of CAD. Since then, it has reawakened our interest in this anomaly. However, there have been no reports describing combination of cCT/CTP for the evaluation of patients with symptomatic MB, and as expected, clinical benefits of cCTP protocol at the cost of higher radiation has not been determined yet in this clinical scenario. We thus acknowledge that it may be a subject of controversy and discussion^[10,11] and we believe further research is needed to establish the clinical usefulness of this technique also in MB compared with scintigraphy in larger population

4. Conclusion

We hereby describe MB-induced ischemia in a patient with hypertrophic cardiomyopathy. In this patient, cCTP enabled for simultaneous assessment of MB and their hemodynamic significance, aiding in treatment planning and evaluation of therapeutic effectiveness.

References

- [1] Alegria JR, Herrmann J, Holmes DR Jr, et al. Myocardial bridging. *Eur Heart J* 2005;26:1159–68.
- [2] Nakanishi R, Rajani R, Ishikawa Y, et al. Myocardial bridging on coronary CTA: an innocent bystander or a culprit in myocardial infarction? *J Cardiovasc Comput Tomogr* 2012;6:3–13.
- [3] Gomberg-Maitland M, Kim MC, Fuster V. A stratified approach to the treatment of a symptomatic myocardial bridge. *Clin Cardiol* 2002;25:484–6.
- [4] Tarantini G, Migliore F, Cademartiri F, et al. Left anterior descending artery myocardial bridging: a clinical approach. *J Am Coll Cardiol* 2016;68:2887–99.
- [5] Bruschke AV, Veltman CE, de Graaf MA, et al. Myocardial bridging: what have we learned in the past and will new diagnostic modalities provide new insights? *Neth Heart J* 2013;21:6–13.
- [6] Schoepf UJ, Zwerner PL, Savino G, et al. Coronary CT angiography. *Radiology* 2007;244:48–63.
- [7] Danad I, Szymonifka J, Schulman-Marcus J, et al. Static and dynamic assessment of myocardial perfusion by computed tomography. *Eur Heart J Cardiovasc Imaging* 2016;17:836–44.
- [8] Blankstein R, Shturman LD, Rogers IS, et al. Adenosine-induced stress myocardial perfusion imaging using dual-source cardiac computed tomography. *J Am Coll Cardiol* 2009;54:1072–84.
- [9] Klues HG, Schwarz ER, vom Dahl J, et al. Disturbed intracoronary hemodynamics in myocardial bridging: early normalization by intracoronary stent placement. *Circulation* 1997;96:2905–13.
- [10] Taylor AJ, Cerqueira M, Hodgson JM, et al. ACCF/SCCT/ACR/AHA/ASE/ASNC/NASCI/SCAI/SCMR 2010 Appropriate Use Criteria for Cardiac Computed Tomography. A Report of the American College of Cardiology Foundation Appropriate Use Criteria Task Force, the Society of Cardiovascular Computed Tomography, the American College of Radiology, the American Heart Association, the American Society of Echocardiography, the American Society of Nuclear Cardiology, the North American Society for Cardiovascular Imaging, the Society for Cardiovascular Angiography and Interventions, and the Society for Cardiovascular Magnetic Resonance. *J Cardiovasc Comput Tomogr* 2010;4:407.e1–33.e1.
- [11] Kim YJ, Yong HS, Kim SM, et al. Korean guidelines for the appropriate use of cardiac CT. *Korean J Radiol* 2015;16:251–85.