

Contents lists available at [ScienceDirect](https://www.sciencedirect.com)

International Journal of Surgery Case Reports

journal homepage: www.casereports.com

Laparoscopic assisted ERCP in patient with Roux-en-Y gastric bypass. A case report

Carmelo Mazzeo^a, Giorgio Badessi^{a,*}, Socrate Pallio^b, Francesca Viscosi^a,
Eugenio Cucinotta^a

^a Department of General and Emergency Surgery, Policlinico G. Martino, University of Messina, Italy

^b Digestive Endoscopy Unit, Policlinico G. Martino, University of Messina, Italy

ARTICLE INFO

Article history:

Received 11 March 2021

Received in revised form 21 March 2021

Accepted 22 March 2021

Available online 26 March 2021

Keywords:

Cholelithiasis

Laparoscopic assisted ERCP

Roux-en-Y-Gastric bypass

Case report

ABSTRACT

INTRODUCTION: Cholelithiasis in Roux-en-Y patients is a therapeutic challenge for both surgeons and endoscopists. In fact, typical procedures, such as ERCP, can't be performed due to the altered anatomy of the patient. Nowadays, procedures on this kind of patient are performed not only in specialized bariatric centers, but, due to the increasing number of patients undergoing bariatric surgery, are starting to become more common even in smaller and non-specialized centers that don't possess the same expertise and technology.

CASE PRESENTATION: We present the case of a 33-year-old patient, who had already undergone bariatric surgery, and presented to our department with a diagnosis of cholelithiasis. Due to the altered anatomy the patient was treated through a laparoscopic assisted ERCP.

DISCUSSION: A review of the need and proper timing for a cholecystectomy in this kind of patient, in order to prevent cholelithiasis, is discussed. Moreover, a review of the literature regarding the possible treatments of this pathology in bariatric patients underlines the presence of other treatments, beyond the one performed in our department, that can be performed even in small non-specialized centers.

CONCLUSIONS: Prophylactic cholecystectomy is not recommended in bariatric surgery. Laparoscopic assisted-ERCP is a safe and feasible intervention which is to be preferred, even if B-ERCP and EDGE are two valid alternatives.

© 2021 The Authors. Published by Elsevier Ltd on behalf of IJS Publishing Group Ltd. This is an open access article under the CC BY-NC-ND license (<http://creativecommons.org/licenses/by-nc-nd/4.0/>).

1. Introduction

Patients who have undergone bariatric procedures, 80% represented by Roux-en-Y gastric bypass (RYGB) and sleeve gastrectomy (SG) [1], are more at risk for developing cholelithiasis and choledocholithiasis, mainly due to the increased presence of stones caused by an important weight loss and long fasting [2,3]. For Weiss et al. incidence of gallbladder disease after RYGB was 15.2% 5 years after surgery [4]. Mishra et al. reported that RYGB patients had a 13.4% and 1% chance of developing symptomatic cholelithiasis and choledocholithiasis [5]. Furthermore, a retrospective multicenter analysis found that the 2 most common reasons for hospital readmission in patients after RYGB and SG were symptomatic cholelithiasis and abdominal pain of unknown origin [6]. Choledocholithiasis in patients who underwent RYGB represents a problem

when it comes to treatment. In fact, normal endoscopic retrograde cholangiopancreatography (ERCP) procedure can't be performed due to the loss of the normal anatomy of the upper gastrointestinal tract. Over the years, several techniques have been proposed and confronted, such as balloon enteroscopy-assisted ERCP (B-ERCP), laparoscopic assisted ERCP and EUS-directed transgastric ERCP (EDGE) [7]. However, a treatment for this kind of patient still represents a challenge requiring a multidisciplinary approach. We present here a case report of a young patient, already treated in another hospital for morbid obesity with a RYGB, who came to our emergency department for abdominal pain and jaundice. This case report has been reported following the SCARE 2020 criteria [8].

2. Presentation of case

A Caucasian 33-year-old man with a history of laparoscopic RYGB performed in 2014 presented to the emergency department with a two-month colic abdominal pain in right hypochondrium and epigastrium that had worsened in recent days. Weeks before, he had performed an abdominal MRI due to this pain, that reported the presence of microlithiasis both in common bile duct and gallbladder. The patient was a non-smoker, without a history of alcohol

Abbreviations: ERCP, endoscopic retrograde cholangiopancreatography; RYGB, Roux-en-Y gastric bypass; SG, sleeve gastrectomy; B-ERCP, balloon ERCP; EUS, endoscopic ultrasound; EDGE, EUS-directed transgastric ERCP; WBC, white blood cells; MRI, magnetic resonance imaging; POD, post operative day.

* Corresponding author at: Via Cesare Baronio 187, Rome, Italy.

E-mail address: giorgio.badessi@gmail.com (G. Badessi).

<https://doi.org/10.1016/j.ijscr.2021.105837>

2210-2612/© 2021 The Authors. Published by Elsevier Ltd on behalf of IJS Publishing Group Ltd. This is an open access article under the CC BY-NC-ND license (<http://creativecommons.org/licenses/by-nc-nd/4.0/>).

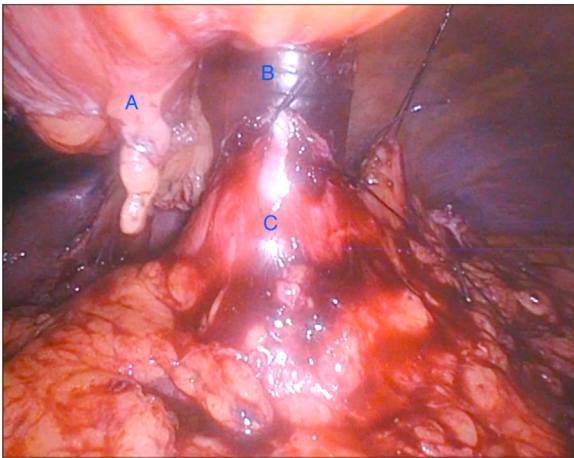


Fig. 1. intraoperative view of the laparoscopic time; Laparoscopic image displaying the falciform ligament (A), the 15 mm port (B), the gastric remnant (C).

abuse, and didn't take any type of medication. Family history was negative for cholelithiasis or choledocholithiasis. At admission the physical examination revealed tenderness in epigastric and right hypochondrium without signs of peritonism. Lab values showed increased bilirubin (total 3.16 mg/dl, direct 2.49 mg/dl) and hepatic enzymes (got 358 U/l, gpt 409 U/l, ggt 1399 U/l). Amylase, lipase, pcr and white blood cells were in the normal range. However, routine exams were performed in the following days, which highlighted an increase in WBC (20800 mmc) together with amylase (1309 U/l) and lipase (2179 U/l). An MRI was performed, which confirmed the presence of choledocholithiasis and cholelithiasis. A diagnosis of biliary pancreatitis was determined and the need of surgical therapy became necessary for the patient, in order to prevent other pancreatic complications. A multidisciplinary team made up of surgeons, endoscopists and gastroenterologists decided that the best treatment for this kind of patient was a laparoscopic cholecystectomy with a subsequent laparoscopic assisted-ERCP through a gastrotomy; this type of intervention was indicated as the most efficient, respect to EDGE technique, in order to avoid multiple procedures on the patient. Pneumoperitoneum was performed through open technique by locating a 12mm port over in supraumbilical area. Successively, under vision, we positioned 4 ports: a 5mm port in right flank, a 15mm port in epigastrium, a 5 mm in left periumbilical area and a 10mm port in left flank. During explorative laparoscopy the gastric remnant, the jejunum-jejunal anastomosis and gallbladder were visualized. Cystic duct and cystic artery were isolated and ligated on their distal end; through the cystic duct a small section was performed in order to introduce a guidewire which was inserted inside the duodenum. Successively, a 1.5 cm gastrotomy was performed on the anterior wall of the gastric remnant, 7cm away from the pylorus. Two Vycril 0 stiches were placed near the gastrotomy in order to maintain apposition of the 15 mm port which was inserted through the gastrotomy (Fig. 1). The duodenoscope was introduced through the port and arrived to the duodenum thanks to common endoscopic procedures. The former guidewire was visualized and used as a rendezvous for cannulation of the papilla. Cholangiography of the biliary tract was performed, which confirmed the presence of multiple biliary stones and mild dilatation of the common bile duct. Biliary sphincterotomy and extraction of stones through balloon catheter were conducted, obtaining a good bile flow at the conclusion of the procedure (Fig. 2). Another cholangiography was performed to confirm the absence of filling defects. At the end of the endoscopic procedures the gastrotomy was closed through a double layer suture via laparoscopic technique and a retrograde cholecystectomy was performed. One

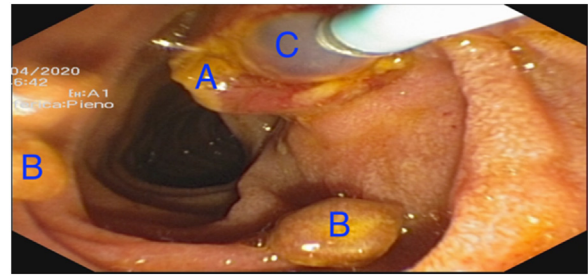


Fig. 2. intraoperative view of the endoscopic time; Endoscopic image displaying the papilla (A), the biliary stones (B) and the balloon catheter (C).

abdominal drainage was positioned before closure. Both the surgical and endoscopic time were performed by an expert surgeon and endoscopist. The patient didn't suffer any post-operative complications with decreasing lab values of bilirubin, amylase, lipase, hepatic enzymes and white blood cells. On 1st POD the drainages were removed. On 3rd POD the patient was discharged. Follow-up visit 1 week from discharge showed no particular abnormalities at physical examination and normal lab values. At 12-month follow-up no kind of long-term complication was reported. The patient was pleased by the treatment, due to its low invasiveness, the safety and the small number of days spent in the hospital after the procedure. Post-intervention considerations were that this treatment has been the most effective for this kind of patient, especially considering the satisfying short and long-term outcomes.

3. Discussion

Choledocholithiasis in gastric-bypass patients gives us several points for reflection. The first consideration concerns if a prophylactic cholecystectomy should be carried out, since there is a higher risk of developing gallbladder stones after a bariatric surgery, and consequently greater difficulty in managing complications related to cholelithiasis in patients with previous gastric bypass. Tsirlina et al. [9] sustains that prophylactic cholecystectomy in bariatric patients should not be routinely performed due to the low rate of post-RYGB cholecystectomy rate. Moreover, Altieri et al. [10] concluded that just 9.7% of patients that underwent RYGB needed a cholecystectomy and that a concurrent cholecystectomy during bariatric surgery is not justified. Most papers agree that cholecystectomy should be performed only in patients who already had biliary symptoms in the past or at time of bariatric surgery [10,9,11,12]. As far as concerns the matter of whether to perform a prophylactic laparoscopic cholecystectomy during the bypass procedure, in order to prevent biliary stones in the biliary tree, literature is divided. Some authors state that it should be performed due to its safety [4]. On the other hand, we believe that the cholecystectomy procedure could be postponed until after the patient loses weight thanks to the bypass, which would allow us to operate with less surrounding visceral fat and with a standard position of the ports for cholecystectomy and not a sub-optimal placement as when the patient is undergoing a gastric bypass, which could be technically difficult [13]. A systematic review and meta-analysis by Tustumi [12] give clear data on this matter, in fact concomitant cholecystectomy during a RYGB procedure increased both operative time and post-operative complications; however, when confronting concomitant cholecystectomy and cholecystectomy post-RYGB the former was found to have a lower rate of reoperation and post-operative complications. This clearly indicates that, if at time of the bariatric procedure the patient already presents with biliary symptoms, he should undergo cholecystectomy during the bypass operation. The other topic of discussion is how to treat patients with choledocholithiasis and concomitant

gastric bypass. Since biliary symptoms and choledocholithiasis are the most common indications for ERCP in RYGB patients one of the goals of the report was to understand which procedure was most efficient. The treatment for choledocholithiasis in RYGB patients described in our case is not the only feasible one. Many types of treatments for post-RYGB patients affected by choledocholithiasis have been described. From an efficiency point of view, B-ERCP has the lowest success rates respect to laparoscopic assisted ERCP and EUS-directed transgastric ERCP (70% vs. > 95%) [7]. Moreover, incannulation of the papilla has showed to be more challenging due to the tangential view given by this type of instrument [14]. Bukhari et al. [15] concluded that EDGE is superior to B-ERCP in terms of technical success and shorter procedural time. Ayoub et al. [16] compared laparoscopic assisted ERCP and B-ERCP, underlining the superior effectiveness of the former, considering it as a first-line approach, even though it is associated with longer procedural time and a higher risk of adverse events. Another point to consider, besides effectiveness, is the feasibility of these procedures in all hospitals. While B-ERCP and EDGE require an endoscopic reference center, laparoscopic assisted-ERCP is a procedure that presents the endoscopic difficulties of a simple ERCP, not requiring particular expertise. Furthermore, in presence of a patient not already cholecystectomized, the choice between the existing techniques is directed towards laparoscopic assisted-ERCP [17] because the patient can have both procedures performed at one time. In order to reduce invasiveness, one article proposed using a single-port surgery in order to perform cholecystectomy and transgastric ERCP [18]. Further, a systematic review and meta-analysis by Aiolfi et al. [19], which compared 13 studies, concluded that the transgastric approach through gastrotomy can be considered a safe and effective therapeutic choice in patients with choledocholithiasis, which was also found to be the most common indication for this type of procedure in RYGB patients (49% of cases), together with papillary stenosis (21%) and sphincter of Oddi dysfunction (12%). Nevertheless, EDGE technique is starting to become increasingly used in patients who have already undergone cholecystectomy, due to the decreased invasiveness, similar safety and success rate respect to laparoscopic-assisted ERCP [7,15]. Beyond the already discussed techniques, which are considered the most known and used ones, others can be found in literature; one work reported access to the left biliary tree by the gastric pouch [20], while another suggested a percutaneous approach to the gastric remnant in order to perform an ERCP [7]. However, even if no comparative studies have been done, these procedures resulted more technically challenging and hence presented an increased risk.

4. Conclusions

Prophylactic cholecystectomy is not recommended in bariatric surgery, due to the low frequency of cholecystectomy in post-RYGB patients. Cholecystectomy is to be considered only in symptomatic patients and can be realized either during the bariatric procedure or separately. Choledocholithiasis in RYGB patients can be a challenging type of procedure, which should be based on the patient's anatomy, clinical status and expertise of the surgeon/endoscopist. Laparoscopic assisted-ERCP can be considered a safe and feasible intervention to be preferred especially if the patient needs to undergo cholecystectomy. B-ERCP and EDGE are two valid alternatives, but require an important endoscopic expertise not present in the majority of centers.

Declaration of Competing Interest

All the authors declare to have any kind of conflicts of interest.

Sources of funding

Any kind of funding was received by the authors for this work.

Ethical approval

Ethical approval was not required.

Consent

Written informed consent was obtained from the patient for publication of this case report and accompanying images. A copy of the written consent is available for review by the Editor-in-Chief of this journal on request.

Author contribution

All the authors have contributed equally.

Registration of research studies

Not Applicable.

Guarantor

Giorgio Badessi.

Provenance and peer review

Not commissioned, externally peer-reviewed.

References

- [1] L. Angrisani, A. Santonicola, P. Iovino, et al., IFSO worldwide survey 2016: primary, endoluminal, and revisional procedures. *Obes. Surg.* 28 (2018) 12.
- [2] S. Erlinger, Gallstones in obesity and weight loss, *Eur. J. Gastroenterol. Hepatol.* 12 (2000) 12.
- [3] J.E. Everhart, Contributions of obesity and weight loss to gallstone disease, *Ann. Intern. Med.* 119 (10) (1993).
- [4] A.C. Weiss, T. Inui, R. Parina, et al., Concomitant cholecystectomy should be routinely performed with laparoscopic Roux-en-Y gastric bypass, *Surg. Endosc.* 29 (2015) 11.
- [5] T. Mishra, K.K. Lakshmi, K.K. Peddi, Prevalence of cholelithiasis and choledocholithiasis in morbidly obese South Indian patients and the further development of biliary Calculus disease after sleeve gastrectomy, gastric bypass and mini gastric bypass, *Obes. Surg.* 26 (2016) 10.
- [6] D. Gero, D.A. Raptis, W. Vleeschouwers, et al., Defining global benchmarks in bariatric surgery: a retrospective multicenter analysis of minimally invasive Roux-en-Y gastric bypass and sleeve gastrectomy, *Ann. Surg.* 270 (2019) 5.
- [7] E. Forster, B.J. Elmunzer, Endoscopic retrograde cholangiopancreatography in patients with Roux-en-Y gastric bypass, *Am. J. Gastroenterol.* 115 (2020) 2.
- [8] R.A. Agha, T. Franchi, C. Sohrabi, G. Mathew, for the SCARE Group, The SCARE 2020 guideline: updating consensus Surgical CAse REport (SCARE) guidelines, *Int. J. Surg.* 84 (2020) 226–230.
- [9] V.B. Tsirlina, Z.M. Keilani, S. El Djouzi, et al., How frequently and when do patients undergo cholecystectomy after bariatric surgery? *Surg. Obes. Relat. Dis.* 10 (2014) 2.
- [10] M.S. Altieri, J. Yang, L. Nie, S. Docimo, M. Talamini, A.D. Pryor, Incidence of cholecystectomy after bariatric surgery, *Surg. Obes. Relat. Dis.* 14 (2018) 7.
- [11] D.D. Portenier, J.P. Grant, H.S. Blackwood, A. Pryor, R.L. McMahon, E. DeMaria, Expectant management of the asymptomatic gallbladder at Roux-en-Y gastric bypass, *Surg. Obes. Relat. Dis.* 3 (2007) 4.
- [12] F. Tustumi, W.M. Bernardo, M.A. Santo, I. Ceconello, Cholecystectomy in patients submitted to bariatric procedure: a systematic review and meta-analysis, *Obes. Surg.* 28 (2018) 10.
- [13] C. Iglézias Brandão de Oliveira, E. Adami Chaim, B.B. da Silva, Impact of rapid weight reduction on risk of cholelithiasis after bariatric surgery, *Obes. Surg.* 13 (2003) 4.
- [14] B. Abu Dayyeh, Single-balloon enteroscopy-assisted ERCP in patients with surgically altered GI anatomy: getting there, *Gastrointest. Endosc.* 82 (2015) 1.
- [15] M. Bukhari, T. Kowalski, J. Nieto, et al., An international, multicenter, comparative trial of EUS-guided gastrostomy-assisted ERCP versus enteroscopy-assisted ERCP in patients with Roux-en-Y gastric bypass anatomy, *Gastrointest. Endosc.* 88 (2018) 3.
- [16] F. Ayoub, T.S. Brar, D. Banerjee, et al., Laparoscopy-assisted versus enteroscopy-assisted endoscopic retrograde cholangiopancreatography

- (ERCP) in Roux-en-Y gastric bypass: a meta-analysis, *Endosc. Int. Open* 8 (2020) 3.
- [17] T.H. Baron, Approaches to ERCP in patients with Roux-en-Y gastric bypass anatomy, *Gastroenterol. Hepatol. (N. Y.)* 15 (2019) 11.
- [18] C. Bures, P. Seika, W. Veltzke-Schliecker, A. Adler, D. Kröll, R. Zorron, Intra-gastric single-port surgery (IGS) accesses the gastric remnant and allows ERCP for common bile duct stones after RYGB: a simple solution for a difficult problem, *Surg. Obes. Relat. Dis.* 15 (2019) 8.
- [19] A. Aiolfi, E. Asti, E. Rausa, D. Bernardi, G. Bonitta, L. Bonavina, Trans-gastric ERCP after Roux-en-Y gastric bypass: systematic review and meta-analysis, *Obes. Surg.* 28 (2018) 9.
- [20] A. Martin, C.A. Kistler, P. Wrobel, J.F. Yang, A.A. Siddiqui, Endoscopic ultrasound-guided pancreaticobiliary intervention in patients with surgically altered anatomy and inaccessible papillae: a review of current literature, *Endosc. Ultrasound* 5 (2016) 3.

Open Access

This article is published Open Access at [sciencedirect.com](https://www.sciencedirect.com). It is distributed under the [IJSCR Supplemental terms and conditions](#), which permits unrestricted non commercial use, distribution, and reproduction in any medium, provided the original authors and source are credited.