

Preliminary Study of Hiatal Hernia Repair Using Polyglycolic Acid: Trimethylene Carbonate Mesh

James M. Massullo, MD, Tejinder P. Singh, MD, Ward J. Dunnican, MD, Brian R. Binetti, MD

ABSTRACT

Background: Repairing large hiatal hernias using mesh has been shown to reduce recurrence. Drawbacks to mesh include added time to place and secure the prosthesis as well as complications such as esophageal erosion. We used a laparoscopic technique for repair of hiatal hernias (HH) >5cm, incorporating primary crural repair with onlay fixation of a synthetic polyglycolic acid:trimethylene carbonate (PGA:TMC) absorbable tissue reinforcement. The purpose of this report is to present short-term follow-up data.

Methods: Patients with hiatal hernia types I-III and defects >5cm were included. Primary closure of the hernia defect was performed using interrupted nonpledgeted sutures, followed by PGA:TMC mesh onlay fixed with absorbable tacks. A fundoplication was then performed. Evaluation of patients was carried out at routine follow-up visits. Outcomes measured were symptoms of gastroesophageal reflux disease (GERD), or other symptoms suspicious for recurrence. Patients exhibiting these complaints underwent further evaluation including radiographic imaging and endoscopy.

Results: Follow-up data were analyzed on 11 patients. Two patients were male; 9 were female. The mean age was 60 years. The mean length of follow-up was 13 months. There were no complications related to the mesh. One patient suffered from respiratory failure, one from gas bloat syndrome, and another had a superficial port-site infection. One patient developed a recurrent hiatal hernia.

Conclusions: In this small series, laparoscopic repair of hiatal hernias >5cm with onlay fixation of PGA:TMC tissue reinforcement has short-term outcomes with a reason-

ably low recurrence rate. However, due to the preliminary and nonrandomized nature of the data, no strong comparison can be made with other types of mesh repairs. Additional data collection is warranted.

Key Words: Hiatal hernia, Paraesophageal hernia, Bio-A, Laparoscopic repair.

INTRODUCTION

Large hiatal hernias (HH) are a challenging entity for practicing surgeons. Although the association of GERD and HH is well known, many HH are asymptomatic. Large paraesophageal hernias (PEH) are frequently associated with symptomatology, leading patients to seek surgical treatment. Elective repair has been proposed due to the poor outcomes associated with emergent surgery, as well as the complications associated with the diagnosis.¹

The standard of care for repairing hiatal hernias remains a controversy. Literature suggests a higher rate of recurrence with laparoscopic repair compared to an open repair, with recurrence rates ranging from 1.9% to 42%.^{2,3} In 2007, Rathore et al⁴ published results of a meta-analysis of 13 studies involving 965 patients undergoing laparoscopic HH repair. The incidence of true recurrence was reported as 25.5%.⁴ Regardless of the approach, there is no consensus on the use of pledgets, gastroplasty, gastric fixation, or esophageal lengthening procedures. Repair of large hernia defects is technically challenging for most experienced surgeons. High recurrence rates have led to the use of mesh reinforcement. In 2006, Johnson and colleagues⁵ published a meta-analysis of the literature supporting the use of prosthetic materials for the repair of large PEH. Different synthetic and biologic mesh types have been used, resulting in various outcomes.⁵ In 2008, Gore introduced BIO-A tissue reinforcement (W. L. Gore, Flagstaff, AZ). This material consists of a unique Polyglycolic acid:Trimethylene carbonate (PGA:TMC) absorbable synthetic polymer. It has an open matrix structure that acts as a scaffold for native tissue in-growth.⁶ To date, no data have been published regarding the use of this product for the repair of hiatal hernias. Our series presents short-term

Department of General Surgery, Albany Medical Center, Albany, New York, USA (all authors).

Dr. Tejinder P. Singh is a speaker for Covidien and Ethicon. Dr. Ward Dunnican was a grant recipient from Covidien, Ethicon, and NOSCAR and consultant to the Cowen Group. Drs. Massullo and Binetti have no conflicts of interest or financial ties to disclose.

Address correspondence to: James M. Massullo, MD, 5131 Beacon Hill Rd, Suite 230, Columbus, OH 43228, Telephone: (614) 544-1880, Fax: (614) 544-1087, E-mail: jmdm34@gmail.com

DOI: 10.4293/108680812X13291597715943

© 2012 by JSLS, *Journal of the Society of Laparoendoscopic Surgeons*. Published by the Society of Laparoendoscopic Surgeons, Inc.

outcomes for patients who have undergone laparoscopic hiatal hernia repair using BIO-A mesh.

MATERIALS AND METHODS

Under IRB-approved guidelines, patients were consented for surgery. Data were collected in a retrospective fashion. Patients with type I-III hiatal hernias and hiatal defects >5cm, determined at the time of surgery, were included in the analysis. Patients who were undergoing concomitant procedures (eg, sleeve gastrectomy) were excluded.

All patients had been evaluated preoperatively in clinic. Each patient underwent a complete history and physical examination. Objective testing was either performed at our institution or the referring institution and confirmed by us. At a minimum, patients underwent esophagography, upper endoscopic evaluation, and manometry. A number of patients had ambulatory pH testing as part of their GERD evaluation.

The laparoscopic technique for performing a hiatal hernia repair has been described elsewhere.⁷ In all cases, adequate intraabdominal esophageal length, measuring at least 2.5cm without tension or recoil was ascertained. Primary cruroplasty was then performed using interrupted 0-TiCron (Tyco Healthcare Group LP, Norwalk, CT) nonabsorbable suture material without pledgets. A 7cm x 10cm BIO-A mesh was trimmed appropriately and arranged in an on-lay fashion against the primary repair and around the distal esophagus. It was then fixed to both crural pillars using absorbable tacks (Davol SorbaFix™ or Covidien AbsorbaTack™). Two to 3 tacks were placed through the mesh into each pillar. **Figure 1** shows the mesh immedi-

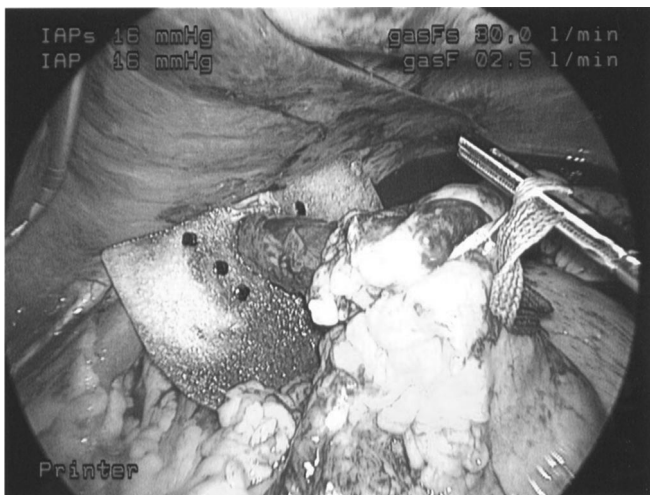


Figure 1. PGA:TMC mesh after fixation to crural pillars.

ately after fixation. A complete (Nissen) or partial (Toupet) fundoplication was performed based on preoperative manometric testing. Patients with esophageal dysmotility received a partial fundoplication. All wraps were constructed to 3cm in length around a 52Fr to 56Fr dilator, using 0-TiCron suture material. The same surgeon performed all cases.

Postoperatively, patients were placed on a clear liquid diet and discharged home on a soft diet. Patients were evaluated at follow-up visits scheduled approximately 2, 6, 12 weeks, 6 months then 1 year after surgery. Outcomes measured were symptoms of GERD, epigastric/chest pain, or other symptoms suspicious for recurrence. Patients with these complaints underwent further evaluation including esophagography followed by endoscopy if warranted.

RESULTS

Between March and September of 2008, 11 patients were enrolled in this study. Two patients were male, 9 were female. Of these 11 patients, 2 presented with symptomatic type III hiatal hernias, and 9 presented with GERD. The mean age was 60 years (range, 42 to 85). The mean length of follow-up was 13 months (range, 11.6 to 15.7). BMIs ranged from 21.9 to 42.5, with an average of 30.7. No esophageal lengthening procedures were needed (eg, Collis gastroplasty). Hospital stay averaged 1 day. There were no complications related to the mesh itself, including infection, erosion into adjacent structures, or fistula formation.

Three patients (27%) developed postoperative complications. The first patient failed to wean from the ventilator after surgery, requiring 24 hours of care in the ICU before extubation. A second patient developed gas bloat, which resolved under observation. The upper GI series in this case showed no abnormalities. A third patient developed a superficial infection at the umbilical trocar site. This resolved with antibiotics and local wound care.

One patient returned with symptoms of GERD at 14 months and was found to have a recurrent HH. Relevant information on this patient is outlined in **Table 1**. Thus, the HH recurrence rate was 9% (1/11). Of the 2 patients with symptomatic Type III HH, neither had developed GERD or recurrent HH at 1 year.

DISCUSSION

The first elective hiatal hernia repair was reported in 1919 by Soresi.⁸ As interest grew through the mid part of the twentieth century, the anatomy and physiology of this disease was elucidated. Surgeons developed the tenets of

Table 1.

Characteristics of Patient with Recurrent Symptoms of Reflux and HH

Age	55 yrs
Sex	F
BMI	29.3 kg/m ²
Comorbidities	FM, HLD, IBS, chronic constipation, hypothyroidism, depression, allergic rhinitis
Tobacco use	No
Steroid use	No
Revisional Surgery	No
Procedure	HH repair, Nissen fundoplication
HH Type	I
Perioperative complications	none

FM=fibromyalgia, HLD=hyperlipidemia, IBS=irritable bowel syndrome.

hiatal hernia repair that are still in use today. However, high recurrence rates after hiatal hernia repair led to modifications of the original techniques to reduce the incidence of this complication.⁸ Before the development of prosthetic mesh, primary repair was considered the standard of care. Foreshortened esophagus, particularly in large paraesophageal hernias plays a recognized role in recurrence if not addressed.⁹ Hernia sac resection and gastropexy have also been shown to be important in the prevention of recurrence.¹⁰

With the development of prosthetic and biologic meshes and their use in hiatal hernia repairs, recurrence rates have improved. Current literature favors the use of mesh for the repair of hiatal hernias to lower recurrence rates.²⁻⁵ However, the use of mesh is not without complications, which may include erosion into the esophagus, aorta, diaphragm, and esophageal stenosis.¹¹⁻¹³ These events, although rare, can cause significant morbidity.

In 2008, GORE introduced BIO-A tissue reinforcement, an absorbable mesh that acts as a scaffold for cells to lay down new matrix material as it is absorbed.⁶ This may be advantageous in avoiding complications such as erosion and infection by minimizing foreign body presence. As the mesh is slowly absorbed, cells associated with the inflammatory response migrate into the interstices of the mesh. Over approximately a 6 month period, the mesh is completely absorbed and replaced with the patient's own connective tissue. Fix-

ation of the mesh with absorbable tacks allows the complete absence of foreign material after one year.

It has been shown that patients with hiatal hernia have ultra structural abnormalities of the muscular tissue of the crura that are not present in patients with a normal gastroesophageal junction.¹⁴ This may explain why repair with mesh is associated with lower hernia recurrence. The relationship between collagen and formation of hernias has been studied for some time. However, there are no data on the possible relationship between collagen metabolism and the formation of hiatal hernia.¹⁵ It is hoped that as more research is done in this area, better treatment techniques will evolve and operations could be tailored based on a patient's risk for recurrence.

One limitation of this retrospective review is the evaluation of patients based on symptoms alone, as some patients may have a clinically silent recurrent hernia. Other limitations are the small number of patients in our study group, as well as the short duration of follow-up.

The follow-up data included 1 patient with a recurrent hiatal hernia. Preoperatively, she presented with de novo symptoms of GERD, including heartburn and laryngopharyngeal reflux. The patient had been followed for years by a gastroenterologist while her symptoms became worse and refractory to medical management, which included twice-daily proton pump inhibitors. Esophagram showed reflux into the upper one-third of the esophagus. Endoscopy revealed the presence of a hiatal hernia. Esophageal manometry was normal with a mean lower esophageal sphincter (LES) resting pressure of 19.5mm Hg and normal LES relaxation. Esophageal peristalsis and upper esophageal sphincter function was normal as well. She underwent laparoscopic hiatal hernia repair with BIO-A mesh and Nissen fundoplication over a 54-Fr dilator. In this case, the mesh was fixed using the Covidien AbsorbaTack. She suffered no perioperative complications and had an uneventful course until 14 months later, when she reported intermittent episodes of reflux. Barium esophagram revealed spontaneous reflux with unwrapping of the Nissen and widening of the hiatus. Endoscopy confirmed unwrapping of the fundoplication and the presence of a recurrent hiatal hernia.

Inadequacy of the HH repair and fundoplication must be the first area scrutinized as contributing to failure in this patient. In the presence of technical uniformity among the group, an argument can be made against this. Although their contribution in this case is uncertain, the patient with recurrence had a couple of predisposing factors that can

be attributed to failure, including preoperative resistance to PPI therapy and HH >3cm.¹⁶ So far, the patient has not been symptomatic enough to desire another surgery.

The most common types of mesh used for HH repair today are PTFE, polypropylene, and biomaterial.¹⁷ It is difficult to determine what the actual recurrence and complication rate is for each type of mesh. A review of recent literature regarding the most common types of mesh in use is outlined in **Table 2**.¹⁸⁻³⁰ Inclusion criteria for the table were reports <10 years old with at least 10 patients where the laparoscopic approach had been used and at least 6 months of follow-up took place.

The technical approach to HH repair, as well as the types and sizes of hernias, varies among the studies in **Table 2**.¹⁸⁻³⁰ That noted, recurrence rates in the group of studies range from 0% to 14%. This speaks to the improvement in outcomes of laparoscopic HH repair compared to past reports.³⁻⁵ The short-term results with PGA:TMC

mesh fall within this range. Mesh complications in this group of studies is also a rare event.

More longitudinal data collection is needed to further define the role of mesh repair and optimal material to reduce the rate of recurrence for this disease. Large randomized controlled studies are lacking and would be a beneficial pursuit.

CONCLUSION

In this small series, laparoscopic repair of hiatal hernias >5cm with onlay fixation of PGA:TMC tissue reinforcement has short-term outcomes with a reasonably low recurrence rate. However, due to the preliminary, nonrandomized nature of the data, no strong comparison can be made with other types of mesh repairs. Additional data collection is warranted.

Table 2.
Recently Published Recurrence Rates for Laparoscopic HH Repair with Various Mesh Types

Author	Year	Mesh Type	n	Mean Follow-up (mo)	Recurrence (%)	Mesh Complication
Hazebroek ¹⁸	2008	TiMesh	18	24	5.6	0
Soricelli ¹⁹	2009	Polypropylene	91†	69	1.1	nc
Kepenekci ²⁰	2007	Polypropylene	164	24	1.8	0
Granderath ²¹	2005	Polypropylene	50	12	8	0
Leeder ²²	2003	Polypropylene	14	46	14	0
Gryska ²³	2005	PTFE	130	64	0.8	0
Frantzides ²⁴	2002	PTFE	36	40	0	0
Casaccia ²⁵	2005	Polypropylene/ePTFE	27	27	3.7	0
Jacobs ²⁶	2007	SIS	92	36	3.3	0
Oelschlager ²⁷	2006	SIS	51	6	9	0
Strange ²⁸	2003	SIS	12	11	0	0
Lee ²⁹	2008	HADM	52	16	3.8	0
Wisbach ³⁰	2006	HADM	11	12	9	0

TiMesh=lightweight titanium-coated polypropylene mesh; PTFE=polytetrafluoroethylene.

ePTFE=expanded polytetrafluoroethylene; SIS = small intestine submucosa; HADM=human acellular dermal matrix.

†Group C from study, mesh onlay over primary cruroplasty.

nc: esophageal erosion occurred in one case, but it was not clear whether this happened in the group of interest.

References:

1. Low DE, Unger T. Open Repair of Paraesophageal Hernia: Reassessment of Subjective and Objective Outcomes. *Ann Thorac Surg.* 2005;80:287–294.
2. Champion JK, Rock D. Laparoscopic mesh cruroplasty for large paraesophageal hernias. *Surg Endosc.* 2003;17:551–553.
3. Hashemi M, Peters JH, DeMeester TR, et al. Laparoscopic repair of large type III hiatal hernia: objective follow-up reveals high recurrence rate. *J Am Coll Surg.* 2000;190(5):553–560.
4. Rathore MA, Andrabi SIH, Bhatti MI, Najfi SMH, McMurray A. Meta-analysis of recurrence after laparoscopic repair of paraesophageal hernia. *JLS.* 2007;11:456–460.
5. Johnson JM, Carbonell AM, Carmody BJ, et al. Laparoscopic mesh hiatoplasty for paraesophageal hernias and funduplications. *Surg Endosc.* 2006;20:362–366.
6. W. L. Gore & Associates, Inc. (2008) “GORE BIO-A Tissue Reinforcement” [Brochure] AL2973-EN2 June 2008.
7. Jones DB, Maithel SK, Schneider BE. *Atlas of Minimally Invasive Surgery.* Woodbury, CT: Cine-Med, Inc; 2006.
8. Stylopoulos N, Rattner DW. The history of hiatal hernia surgery From Bowditch to Laparoscopy. *Ann Surg.* 2005;241(1):185–193.
9. Nason KS, Luketich JD, Qureshi I, et al. Laparoscopic repair of giant paraesophageal hernia results in long-term patient satisfaction and a durable repair. *J Gastrointest Surg.* 2008;12:2066–2077.
10. van der Peet DL, Klinkenberg-Knol EC, Alonso Poza A, Sietes C, Eijsbouts QA, Cuesta MA. Laparoscopic treatment of large paraesophageal hernias: both excision of the sac and gastropexy are imperative for adequate surgical treatment. *Surg Endosc.* 2000;14:1015–1018.
11. Zugel N, Lang RA, Kox M, Huttl TP. Severe complication of laparoscopic mesh hiatoplasty for paraesophageal hernia. *Surg Endosc.* 2009;23:2563–2567. Epub 2009 May 14.
12. Hazebroek EJ, Leibman S, Smith GS. Erosion of a composite PTFE/ePTFE mesh after hiatal hernia repair. *Surg Laparosc Endosc Percutan Tech.* 2009;19(2):175–177.
13. Stadlhuber RJ, El Sherif A, Mittal SK, et al. Mesh complications after prosthetic reinforcement of hiatal closure: a 28-case series. *Surg Endosc.* 2009;23:1219–1226. Epub 2008 Dec 6.
14. Fei L, delGenio G, Rossetti G, et al. Hiatal hernia recurrence: surgical complication or disease? Electron microscope findings of the diaphragmatic pillars. *J Gastrointest Surg.* 2009;13:459–464.
15. El Sherif A, Yano F, Mittal S, Filipi CJ. Collagen metabolism and recurrent hiatal hernia: cause and effect? *Hernia.* 2006;10:511–520.
16. Power C, Maguire D, McAnena O. Factors contributing to failure of laparoscopic Nissen fundoplication and the predictive value of preoperative assessment. *Am J Surg.* 2004;187:457–463.
17. Frantzides CT, Carlson MA, Loizides S, et al. Hiatal hernia repair with mesh: a survey of SAGES members. *Surg Endosc.* 2010;24:1017–1024. Epub 2009 Dec 8.
18. Hazebroek EJ, Ng A, Yong DHK, Berry H, Leibman S, Smith GS. Evaluation of lightweight titanium-coated polypropylene mesh (TiMesh) for laparoscopic repair of large hiatal hernias. *Surg Endosc.* 2008;22:2428–2432.
19. Soricelli E, Basso N, Genco A, Cipriano M. Long-term results of hiatal hernia mesh repair and antireflux laparoscopic surgery. *Surg Endosc.* 2009;23:2499–2504. Epub 2009 Apr 3.
20. Turkcapar A, Kepenekci I, Mahmoud H, Tuzuner A. Laparoscopic fundoplication with prosthetic hiatal closure. *World J Surg.* 2007;31:2169–2176.
21. Granderath FA, Schweiger UM, Kamolz T, Asche KU, Pointner R. Laparoscopic Nissen fundoplication with prosthetic hiatal closure reduces postoperative intrathoracic wrap herniation: preliminary results of a prospective randomized functional and clinical study. *Arch Surg.* 2005;140:40–48.
22. Leeder PC, Smith G, Dehn TCB. Laparoscopic management of large paraesophageal hiatal hernia. *Surg Endosc.* 2003;17:1372–1375.
23. Gyska PV, Vernon JK. Tension-free repair of hiatal hernia during laparoscopic fundoplication: a ten-year experience. *Hernia.* 2005;9:150–155.
24. Frantzides CT, Madan AK, Carlson MA, et al. A prospective, randomized trial of laparoscopic polytetrafluoroethylene (PTFE) patch repair vs. simple cruroplasty for large hiatal hernia. *Arch Surg.* 2002;137:649–653.
25. Casaccia M, Torelli P, Panaro F, et al. Laparoscopic tension-free repair of large paraesophageal hiatal hernias with a composite A-shaped mesh: two-year follow-up. *J Laparoendosc Adv Surg Tech A.* 2005;15(3):279–284.
26. Jacobs M, Gomez E, Plasencia G, et al. Use of Surgisis mesh in laparoscopic repair of hiatal hernias. *Surg Laparosc Endosc Percutan Tech.* 2007;17:365–368.
27. Oelschlager BK, Pellegrini CA, Hunter J, et al. Biologic prosthesis reduces recurrence after laparoscopic paraesophageal hernia repair: a multicenter, prospective, randomized trial. *Ann Surg.* 2006;244:481–490.
28. Strange PS. Small intestinal submucosa for laparoscopic repair of large paraesophageal hiatal hernias: a preliminary report. *Surg Technol Int.* 2003;11:141–143.
29. Lee YK, James E, Bochkarev V, Vitamvas M, Oleynikov D. Long-term outcome of cruroplasty reinforcement with human acellular dermal matrix in large paraesophageal hiatal hernia. *J Gastrointest Surg.* 2008;12:811–815.
30. Wisbach G, Peterson T, Thoman D. Early results of the use of acellular dermal allograft in type III paraesophageal hernia repair. *JLS.* 2006;10:184–187.