

Unusual Double Dislocation of Both Joints in a Same Finger: A Case Report

Pankaj Kumar Mishra ^{1,*}, Anuj Gupta ¹, Suresh Chandra Gaur ¹

¹Orthopedics Department, Kanpur University, Allahabad, India

*Corresponding Author: Pankaj Kumar Mishra, Orthopedics Department, Kanpur University, Allahabad, India. Tel: +91-8127325395, E-mail: drpankajv@yahoo.com.

Received: January 2, 2013; Revised: March 19, 2013; Accepted: October 10, 2013

Simultaneous dislocation of both interphalangeal (IP) joints of same finger is a highly uncommon finding. And dislocation of metacarpophalangeal (MCP) joint along with interphalangeal joints of thumb are reported in literatures if, scarcely. Here we are reporting the three cases, comprising of double dislocation of IP joints in little finger in two patients and simultaneous MCP and IP joint dislocation in thumb in another third patients as a perusal of rare entity from the northern India.

Keywords: IP Joints; MCP Joints; Dislocation; Finger

1. Introduction

First case of double dislocation in a finger was documented in 1874 by Bartel (1). Dislocation of two joints in same finger is a rare event. Simultaneous dislocation of both interphalangeal (IP) joints of same finger is a highly uncommon finding. And dislocation of metacarpophalangeal (MCP) joint along with interphalangeal joints of thumb are reported in literatures if, scarcely. In various literatures till now, only sixty five cases of double dislocation of both IP joints in same finger and five cases of simultaneous MCP and IP joint dislocation in thumb have been previously reported.

2. Case Presentation

Here we are reporting the three cases (Table 1), comprising of double dislocation of IP joints in little finger in two patients and simultaneous MCP and IP joint dislocation in thumb in another third patient as a case of rare entity. All three cases were encountered between 12 years from 1999 to 2011 in M.L.N Medical College (city Allahabad) of INDIA.

Table 1. General Data of Three Reported Cases

Sample no	Age, y	Sex	Diagnosis	Management
1	21	M	Dorsal dislocation of both I.P joints of right little finger	Closed reduction and splinting
2	28	M	Dorsal dislocation of both I.P joints of right little finger	Open reduction and K-wire fixation
3	25	M	Dorsal dislocation of MCP and IP joints of left thumb	Closed reduction and splinting

Our two cases of IP joints dislocation were adult male of 21 years and 28 years old. Younger one got injured (in June 1999) during cricket playing and revealed that mechanism of injury was hyperextension type. He presented to emergency department within two hours after injury. Radio graphically dorsal dislocation of both interphalangeal joints of little finger in dominant hand was confirmed. We used ring block anaesthesia and reduced by giving longitudinal traction and pressure over base of caudal phalanx. First done at distal and then at proximal interphalangeal joint and immobilized in intrinsic plus position for three weeks and then physiotherapy done. Second one presented (in January 2006) to us after seven days of trauma in his little finger. He was laborer by occupation, and injured during fall on the ground by keeping his right hand on the edge of wall for protecting himself. On radiography there was undisplaced condylar fracture of proximal phalanx along with dorsal dislocation of both interphalangeal joints. Close reduction tried for two times but failed then open reduction and Kirschner wire fixation done and immobilized (Figure 1 and 2).




Figure 1. Showing Double Dislocation of IP Joints in Little Finger

Implication for health policy/practice/research/medical education:

The further addition of this rarer type of injury entails more understanding the nature of injury and better management. For best management it needs immediate management, delay in diagnosis and treatment compromise the result.

Copyright © 2013, Kowsar Corp.; Published by Kowsar Corp. This is an open-access article distributed under the terms of the Creative Commons Attribution License, which permits unrestricted use, distribution, and reproduction in any medium, provided the original work is properly cited.

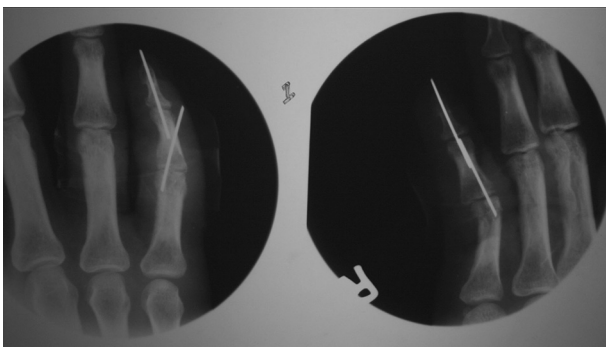


Figure 2. Open Reduction and Kirschner Wire Fixation of Both Joints

Our third case (in march 2011) of dislocation of MCP and IP joints of left thumb was present in twenty five year soccer player, who got injured during playing and visited to emergency department immediately. It was dorsal dislocation of both joints along with minor intraarticular fracture of base of distal phalanx (Figure 3). Reduction done in ring block anaesthesia, first IP joint reduced, then at MCP reduced. MCP joint got reduced by adducting to the metacarpal and hyperextending the joint, while proximal end of proximal phalanx is pushed against and over the metacarpal head with keeping flexion on IP joint to overcome action of flexor pollicis longus. Both joints splinted in 20-degree flexion for four week and then mobilized.

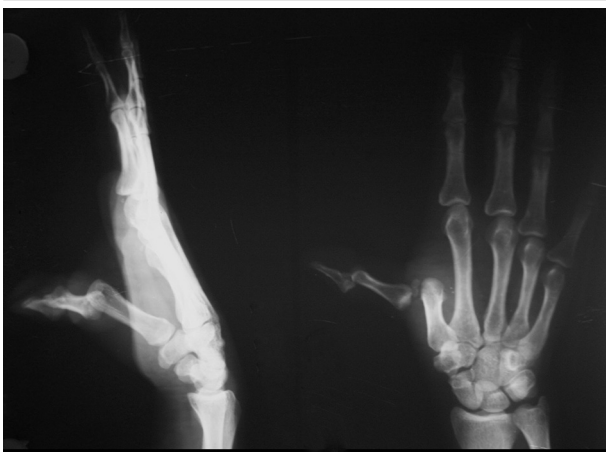

Figure 3. Showing Dislocation of MCP and IP Joints in Thumb

After one year of trauma in all cases of IP joints dislocation, there was residual swelling in distal interphalangeal joint. Flexion movement was within normal limit at proximal and distal interphalangeal joints but extension lag of 15-degree was present at distal interphalangeal joints. In thumb dislocation the arc of motion was from 10-degree hyperextension to 60-degree flexion at IP joint and at MCP joint from zero degree to 30-degree flexion. All patients were gone through ethical consideration, and informed consent. Clinical variables were measured clinical and radiological.

3. Discussion

Review literature of Anderson et al. and study of Hutchison et al., and along with case report of Jahangiri SA et al. are the endorsements of rareness of this injury (2-4). In ten year Nakago et al. enumerated the sixteen cases of double dislocation of proximal and distal interphalangeal joints in same finger, while Edinburg hospital of hand surgery only reported eight cases of such type of injury in ten years, so these were published as a case report for the rarity (3, 5). As a rare case report, triple joints dislocations in a same finger also has been reported (6). Dorsal and lateral type of dislocation is most common type because of the nature of injury, which is hyperextension type and weak radial collateral ligament than ulnar ligament. Dislocation of finger occurs first at distal interphalangeal joints and if the magnitude of injury is more severe then, dislocation of proximal interphalangeal joints occurs. But the double dislocation in opposing direction, in same finger also has been reported (7). Mostly these injuries occur during sport activity like volleyball, baseball and football etc. Little finger followed by ring finger of dominant hand is most commonly involved. This is due to its weak ligaments and unsupported environment from surrounding (8-10). It may be associated with volar plate fracture of middle phalanx in distal interphalangeal dislocation and buttonholing through extensor aponeurosis by condyle of proximal phalanx in proximal interphalangeal joint dislocation, which may cause difficulty in reduction and entails open reduction. Double luxation of MCP and IP joints in thumb has been reported in very few number (11-16). Anteroposterior and true lateral radiograph are necessary to rule out possible appearance on radiograph and even clinically too until obscured by gross swelling. Reduction is obtained by applying longitudinal traction and pressure over dorsum of base of distal phalanx and, in the same way the proximal interphalangeal joint is reduced. Since it is quick but painful for short duration the reduction can be done even without the anaesthesia. Local digital anaesthesia can also be used, because it allows more accurate clinical examination and ligament laxity is checked. In previously reported cases closed reduction have been achieved easily with or without the anaesthesia (17). In late presenting cases open reduction is needed but it compromises the result. Nasviaser et al. and Chan et al. have reported good results in their cases, but there are few reports, which ultimately needed fusion of joint due to pain (18, 19). For immobilization we avoided functional position because, in the deficiency of additional soft tissue stabilizer there is attendant loss of joint congruity, which can leads to secondary volar dislocation (20). Intrinsic plus position with 90 degree flexion at metacarpophalangeal joint and 15 degree flexion at interphalangeal joint was used for three week according to Kuczynski and Sprague recommendation followed by adequate physiotherapy.

Acknowledgements

None declared.

Authors' Contribution

Pankaj Kumar Mishra: surgeon and main manuscript writer. Anuj Gupta: data collector and assistant surgeon. Suresh Chandra Gaur: manuscript writing assistant moderator and guide.

Financial Disclosure

Author declare there is no conflict of interests.

Funding and Support

No financial support

References

1. Bartels Maximilian Carl August. *Traumatische luxationen.*; 1874.
2. Andersen MB, Johannsen H. Double dislocation of the interphalangeal joints in the finger. Case report and review of publications. *Scand J Plast Reconstr Surg Hand Surg.* 1993;**27**(3):233-6.
3. Hutchison JD, Hooper G, Robb JE. Double dislocations of digits. *J Hand Surg Br.* 1991;**16**(1):114-5.
4. Jahangiri SaqibAziz, Mestha Prabhakar, McNally Scarlett. Double dislocation of finger interphalangeal joints. *BMJ Case Reports.* 2012;**2012**.
5. Nakago K, Hashizume H, Senda M, Nishida K, Masaoka S, Inoue H. Simultaneous fracture-dislocations of the distal and proximal interphalangeal joints. *J Hand Surg Br.* 1999;**24**(6):699-702.
6. Morohashi A, Takase K. Triple joint injuries of the same digit. *Orthopedics.* 2009;**32**(4).
7. Panchal AP, Bamberger HB. Dorsal dislocation of the distal interphalangeal joint and volar dislocation of the metacarpophalangeal joint in the same finger: a case report. *Hand (N Y).* 2010;**5**(2):200-2.
8. Freitag P, Hirasuna SM, Milgram JW. Double dislocation of the finger. A rare occurrence. *Phys Sports Med.* 1977;**5**:83-4.
9. NATHAN FREDF, SCHLEIN ALLENP. Multiple Dislocations of a Single Finger. *Hand.* 1973;**5**(1):52-4.
10. Curran AJ, McKiernan MV, McCann J. Double interphalangeal joint dislocation in a little finger. *Injury.* 1993;**24**(2):138.
11. Catalan-Amigo S, Pedemonte-Jansana J, Navarro-Quilis A. Simultaneous dislocation of both joints of the thumb with a fracture involving the interphalangeal joint. A case report and a review of the literature. *Acta Chir Belg.* 2007;**107**(6):728-30.
12. CLEAK DK. Simultaneous Dislocation of the Interphalangeal and Metacarpo-phalangeal Joints in a Thumb. *Hand.* 1981;**05-13**(2):167-8.
13. Levy IMartin, Liberty Shimon. Simultaneous dislocation of the interphalangeal and metacarpophalangeal joints of the thumb: A case report. *J Hand Surg.* 1979;**4**(5):489-90.
14. Meriaux JL, Leviet D, Djermaq Y, Vilain R. [A case of simultaneous luxation of the metacarpophalangeal and interphalangeal joints of the thumb]. *Rev Chir Orthop Reparatrice Appar Mot.* 1983;**69**(6):481-2.
15. Tabib William, Sayegh Samir. Simultaneous Dislocation of the Metacarpophalangeal and Interphalangeal Joints of the Thumb. *Scandinavi J of Plastic Reconstruct Surg Hand Surg.* 2002;**36**(6):376-8.
16. Singh VK, Singh PK, Kalairajah Y. Open simultaneous double dislocation of the metacarpophalangeal and interphalangeal joints of the thumb with ulnar collateral ligament avulsion. *Singapore Med J.* 2009;**50**(6):e206-10.
17. Bayne O, Chabot JM, Carr JP, Evans EF. Simultaneous dorsal dislocation of interphalangeal joints in a finger. *Clin Orthop Relat Res.* 1990(257):104-6.
18. Chan DY. Management of simple finger injuries: the splinting regime. *Hand Surg.* 2002;**7**(2):223-30.
19. Inoue G, Kino Y, Kondo K. Simultaneous dorsal dislocation of both interphalangeal joints in a finger. *Am J Sports Med.* 1993;**21**(2):323-5.
20. Hindley CJ. Triple dislocations in the index finger. *J Trauma.* 1989;**29**(1):122-4.