

## Artificial intelligence integrated smartphone fundus camera for screening the glaucomatous optic disc

Dear Editor,

In the absence of more definite signs, an increase in vertical cup disc ratio (VCDR) or its asymmetry is used to screen suspected glaucoma cases. However, due to its subjective nature, VCDR estimation on fundus photography has an inherent disadvantage of interobserver variability, especially when assessment is done by inexperienced observers. Due to these reasons, nonmydriatic monoscopic fundus photography (NMFP) of the optic disc has shown a wide range of sensitivity and specificity for detection of glaucomatous cupping, varying from 41% to 97%.<sup>[1-3]</sup> Automated estimation of VCDR by artificial intelligence (AI) can be a solution to this problem.

While there are software and algorithms for VCDR assessment from the photographs obtained by the currently available handheld fundus cameras, none have an inbuilt VCDR measurement integrated into the device.<sup>[4-6]</sup> In this study, we aimed to determine the efficacy of a smartphone-based fundus camera with an integrated offline cloud-synced AI-based assessment for VCDR (Remidio's Fundus on phone {FOP} NM-10, Bengaluru, India).<sup>[7]</sup>

The study was approved by our institutional ethics committee and followed the tenets of the Declaration of Helsinki. Fifty eyes of 25 consecutive subjects (either normal, glaucoma suspects, or previously diagnosed glaucoma patients) presenting to a glaucoma clinic were evaluated by a single examiner using 90D Slit-lamp biomicroscopy (SLB).

Eyes with media opacities were excluded. VCDR was assessed on the slit-lamp biomicroscopy with the help of the inbuilt reticule by a single (blinded) glaucomatologist by integrated AI using nonmydriatic fundus photos taken on the FOP device and with inbuilt software of a tabletop SS-OCT device (Topcon DRI OCT Triton, Topcon Corporation, Tokyo, Japan). The VCDR measurements were compared using a Bland–Altman analysis and intraclass correlation coefficient (ICC). All analyses were performed using a statistical software package (SPSS for Windows, v. 26.0. SPSS, Inc, Chicago, IL).

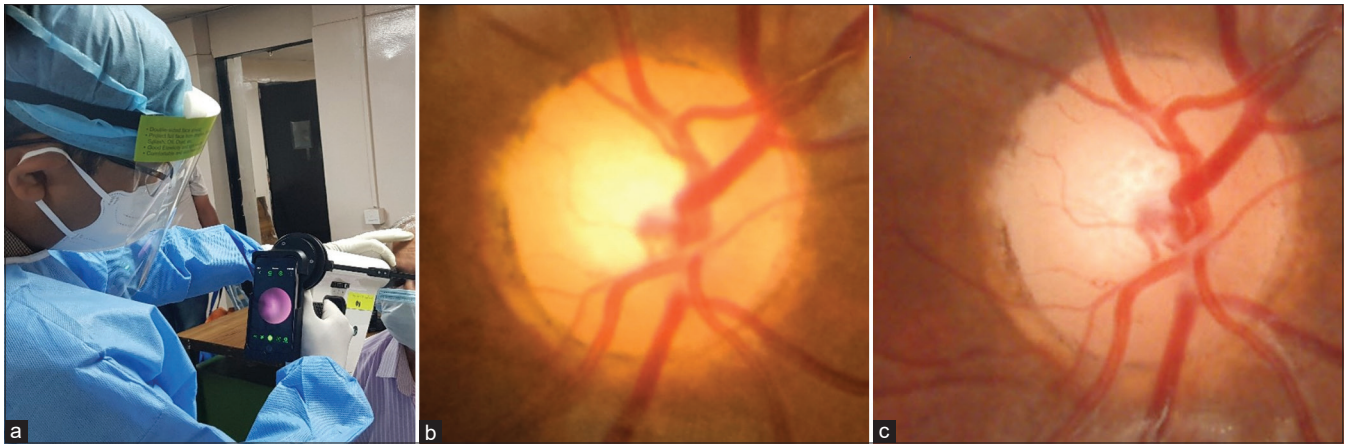
Out of the subjects, seven were healthy, four were glaucoma suspects, and 14 were confirmed glaucoma patients. Adequate distancing was maintained between the examiner and patients during the procedure in view of the ongoing social distancing norms of the COVID-19 pandemic [Fig. 1a]. The FOP device produced a fundus field of view of 40° and generated the VCDR report in less than 10 seconds. The resolution of images (3024 × 4032 pixels) obtained was higher than the currently used handheld fundus cameras and comparable to those obtained from the OCT device [Fig. 1b and c].<sup>[2,3]</sup> There was a good correlation between the two devices with an ICC of 0.86 (Pearson's correlation coefficient 0.76;  $P < 0.001$ ); however, the OCT estimations of the VCDR were on an average higher by a factor of 0.14; CI: 0.04 to -0.32 [Table 1 and Fig. 2].

In studies by Snyder *et al.*<sup>[4]</sup> and Muramatsu *et al.*,<sup>[6]</sup> automated estimation of VCDR using fundus photographs had a moderate agreement with reference VCDR as assessed by expert ophthalmologists. Further, in areas of peripapillary atrophy, the disc margins were overestimated by the automated method. In contrast, we found the AI-mediated VCDR assessment to be more accurate and showed a good agreement

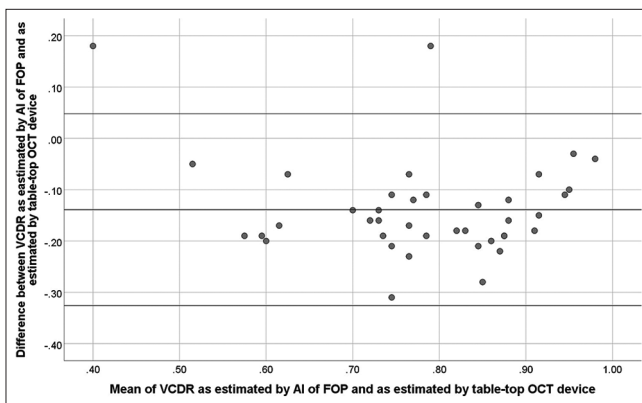
**Table 1: Comparison of Mean VCDR as assessed by different modalities**

Assessment modality	VCDR in healthy eyes (n=14)	VCDR in Glaucoma suspects and confirmed glaucoma eyes (n=36)
90D slit-lamp biomicroscopy by single blinded glaucomatologist	0.35±0.1	0.72±0.1
Integrated AI in FOP device	0.38±0.05	0.78±0.09
SS-OCT device (Topcon DRI OCT Triton)	0.51±0.1	0.92±0.04

Mean ± Standard Deviation. VCDR - Vertical Cup Disc Ratio, AI - Artificial Intelligence, FOP - Fundus on phone, SS-OCT - Swept-Source Optical Coherence Tomography



**Figure 1:** (a) Remidio FOP NM-10, nonmydriatic, smartphone-based fundus camera with integrated Medios AI being used in glaucoma screening. An optic disc image obtained by (b) FOP and (c) Topcon OCT



**Figure 2:** Bland–Altman plot of VCDR measurements obtained from FOP and Topcon OCT

with OCT-estimated VCDR. The OCT devices are known to provide a higher estimation of the CDR, probably because they utilize Bruch's membrane opening to define the border of the optic disc margin.<sup>[8]</sup> However, the FOP device correlated better with the VCDR assessment made clinically, with an ICC of 0.93 [Table 1].

The use of AI-based VCDR assessment, integrated within the FOP device, obviates the need for external image-based software. Further, being an offline system, this device can be used in remote areas for screening where an active Internet connection is unavailable, especially in developing countries. The presence of a cloud syncing feature allows the device to update its database as and when connected to the Internet. Apart from being relatively cheaper, other advantages of the device are the examination of children under anesthesia, instant digital transfer of patient's disc photographs for record-keeping, teleconsultation, and usage as a tool for teaching. Limitations of this pilot study were the small sample size and a lack of direct comparison with other handheld fundus cameras. Notwithstanding these, we believe this particular handheld fundus camera can be used for evaluation of the disc for glaucoma in outpatient clinics, especially in pandemic situations.

### Financial support and sponsorship

Dr. Divya Rao is being funded by the Remidio Innovative Solutions Pvt Ltd.

### Conflicts of interest

There are no conflicts of interest.

*Toshit Varshney, Divya R Parthasarathy<sup>1</sup>,  
Viney Gupta*

Dr. Rajendra Prasad Centre for Ophthalmic Sciences, All India Institute of Medical Sciences, New Delhi, <sup>1</sup>Remidio Innovative Solutions Pvt Ltd, Bengaluru, Karnataka, India

**Correspondence to:** Dr. Toshit Varshney,

Dr. Rajendra Prasad Centre for Ophthalmic Sciences, All India Institute of Medical Sciences, New Delhi, Delhi - 110 029, India.

E-mail: t1varshney@gmail.com

### References

- Almazroa A, Alodhayb S, Osman E, Ramadan E, Hummadi M, Dlaim M, *et al.* Agreement among ophthalmologists in marking the optic disc and optic cup in fundus images. *Int Ophthalmol* 2017;37:701-17.
- Upadhyaya S, Agarwal A, Rengaraj V, Srinivasan K, Newman Casey PA, Schehlein E. Validation of a portable, non-mydriatic fundus camera compared to gold standard dilated fundus examination using slit lamp biomicroscopy for assessing the optic disc for glaucoma. *Eye (Lond)* 2021;1-7. doi: 10.1038/s41433-021-01485-2.
- Miller SE, Thapa S, Robin AL, Niziol LM, Ramulu PY, Woodward MA, *et al.* Glaucoma screening in Nepal: Cup-to-disc estimate with standard mydriatic fundus camera compared to portable nonmydriatic camera. *Am J Ophthalmol* 2017;182:99-106.
- Snyder BM, Nam SM, Khunsongkiet P, Ausayakhun S, Leeungurasatien T, Leiter MR, *et al.* Accuracy of computer-assisted vertical cup-to-disk ratio grading for glaucoma screening. *PLoS One* 2019;14:e0220362.
- Almazroa A, Alodhayb S, Raahemifar K, Lakshminarayanan V. An automatic image processing system for glaucoma screening. *Int J Biomed Imaging* 2017;2017:e4826385.
- Muramatsu C, Nakagawa T, Sawada A, Hatanaka Y, Yamamoto T, Fujita H. Automated determination of cup-to-disc ratio for

classification of glaucomatous and normal eyes on stereo retinal fundus images. *J Biomed Opt* 2011;16:096009.

7. Sengupta S, Sindal MD, Baskaran P, Pan U, Venkatesh R. Sensitivity and specificity of smartphone-based retinal imaging for diabetic retinopathy: A comparative study. *Oph Retina* 2019;3:146-53.
8. Chauhan BC, Burgoyne CF. From clinical examination of the optic disc to clinical assessment of the optic nerve head: A paradigm change. *Am J Ophthalmol* 2013;156:218-27.e2.

---

This is an open access journal, and articles are distributed under the terms of the Creative Commons Attribution-NonCommercial-ShareAlike 4.0 License, which allows others to remix, tweak, and build upon the work non-commercially, as long as appropriate credit is given and the new creations are licensed under the identical terms.

Access this article online	
<b>Quick Response Code:</b>	<b>Website:</b> www.ijo.in
	<b>DOI:</b> 10.4103/ijo.IJO_1831_21

**Cite this article as:** Varshney T, Parthasarathy DR, Gupta V. Artificial intelligence integrated smartphone fundus camera for screening the glaucomatous optic disc. *Indian J Ophthalmol* 2021;69:3787-9.

© 2021 Indian Journal of Ophthalmology | Published by Wolters Kluwer - Medknow