

**LETTER TO THE EDITOR**

A Case of Delayed Oculo-Palato-Brachial Tremor after Pontine Infarction

Ho-Sung Ryu, Minsub Cho, Daeun Shin, Yang-Ha Hwang

Department of Neurology, Kyungpook National University Hospital, Daegu, Korea

Dear Editor,

Oculo-palatal tremor (OPT) is characterized by a low-frequency tremor of the eyes and soft palate. It is mainly observed in patients with hypertrophic degeneration of the inferior olivary nucleus. In this syndrome, the muscles that originate from the branchial arches may be involved, such as those of the face, tongue, floor of the mouth, pharynx, larynx, and diaphragm.¹ However, the involvement of skeletal muscle has rarely been reported. Herein, we report the case of a patient with delayed oculo-palato-brachial tremor (OPBT) who showed distinct involuntary movement on a video, as well as inferior olivary nucleus hypertrophy after pontine infarction by brain magnetic resonance imaging (MRI). Additionally, this case contributes to widening the clinical spectrum of OPT.

A 63-year-old right-handed man presented with sudden-onset altered mental status. At the time of admission to our hospital, stupor mental status, bilateral Babinski sign, and abnormal posturing of four limbs were observed upon neurological examination. His vital signs were normal, and he had no hypertension, diabetes mellitus, dyslipidemia, coronary artery disease, atrial fibrillation, or peripheral arterial obstructive disease. He had been a smoker for forty years and currently smoked 0.5 packs of cigarettes per day, but he had stopped drinking alcohol ten years ago. He had no family history of stroke. The diffusion-weighted images obtained by brain MRI showed an acute infarction on the right paramedian pons, and the angiography of the brain obtained via computed tomography revealed a basilar artery occlusion. Although he was successfully treated with intra-arterial mechanical thrombectomy, multiple ischemic posterior circula-

tion strokes occurred, including bilateral cerebellar and right paramedian pons infarcts (Figure 1A). At the time of hospital discharge, he showed conjugate gaze deviation to the left side, severe dysarthria, left hemibody weakness, and bilateral limb and gait ataxia. The patient could not ambulate independently and had a severe functional disability (modified Rankin Scale score 4). Fifteen months later, the patient was admitted to our hospital again for involuntary movements experienced for 2 months. Upon neurological examination, abnormal movements of the eyes, soft palate, and left upper extremity were observed. Rhythmic, involuntary, horizontal ocular oscillation concomitant with symmetrical palatal and left brachial tremor consistent with OPBT (Supplementary Video 1 in the online-only Data Supplement) was observed. The patient denied any ear-clicking sound. T2-weighted images obtained by MRI of the brain showed multiple old infarctions within the dentato-rubro-olivary pathway (Figure 1B and C), along with the hypertrophy of the right inferior olivary nucleus (Figure 1D). The abnormal movements were not improved despite many medication trials, including clonazepam and gabapentin.

The ischemic multiple posterior circulation stroke in this patient resulted in conjugate gaze deviation to the left side, left hemibody weakness, and cerebellar ataxia involving the right paramedian pontine reticular formation, pyramidal tract, and bilateral cerebellum. These infarcts also caused central tegmental tract interruption, which caused right inferior olivary nucleus deafferentation. The central tegmental tract is a part of the dentato-rubro-olivary pathway or the Guillain-Mollaret triangle, which provides inhibitory afferent input to the inferior olivary nucleus

Received: June 11, 2020 Revised: July 15, 2020 Accepted: August 5, 2020

Corresponding author: Ho-Sung Ryu, MD, PhD

Department of Neurology, Kyungpook National University Hospital, 130 Dongdeok-ro, Jung-gu, Daegu 41944, Korea / Tel: +82-53-200-5765 / Fax: +82-53-422-4265 / E-mail: ryuhosung138@gmail.com

© This is an Open Access article distributed under the terms of the Creative Commons Attribution Non-Commercial License (<https://creativecommons.org/licenses/by-nc/4.0>) which permits unrestricted non-commercial use, distribution, and reproduction in any medium, provided the original work is properly cited.

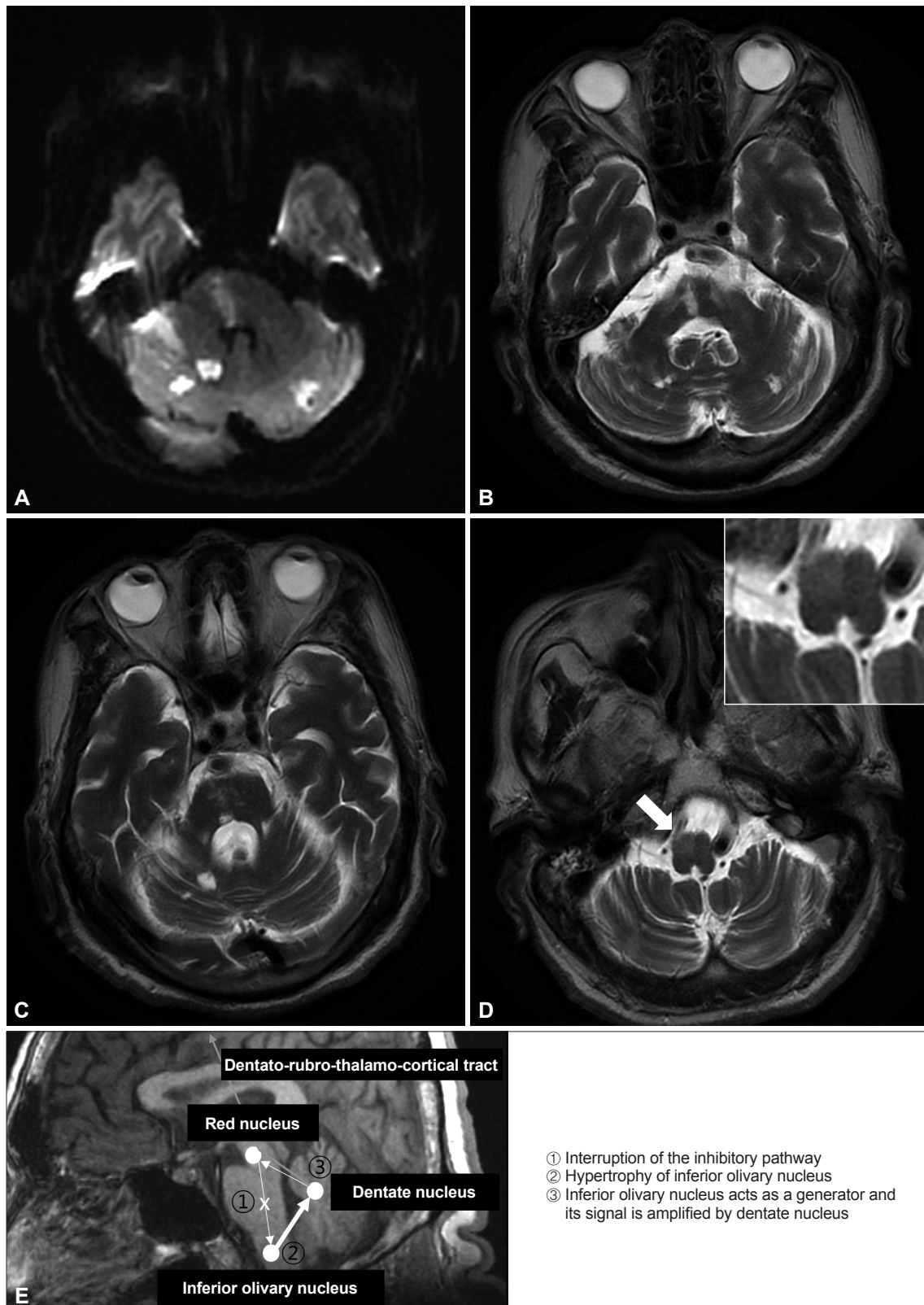


Figure 1. Brain magnetic resonance imaging of the patient. A: Diffusion-weighted image shows ischemic multiple posterior circulation stroke in both the cerebellum and right paramedian pons. T2-weighted images show old lesions due to previous ischemic strokes (B, C) and the hypertrophy of the right inferior olivary nucleus (arrow, D). E: The Guillain-Mollaret triangle is shown, formed by connections between the ipsilateral dentate nucleus, contralateral red nucleus, and contralateral inferior olivary nucleus.

from the contralateral dentate nucleus. Structural damage within the dentato-rubro-olivary pathway would have triggered a process of transsynaptic hypertrophic degeneration of the nucleus that would end in the generation of abnormal oscillatory activity, which would eventually be transmitted to the extraocular and levator veli palatini muscles.¹

Isolated palatal tremor and OPT have been recognized as a common presentation of symptomatic palatal tremor. Other involvement of the face, tongue, floor of the mouth, pharynx, larynx, and diaphragm muscles of branchial arch origin has been reported.¹ In the current case, the left brachial tremor was notable. This low-frequency tremor involved both the proximal and distal portions of the left upper extremity and appeared at rest and during action; therefore, this tremor could be classified as Holmes tremor. Additionally, the low-frequency semirhythmic movements of the left fingers were present at rest and worsened during action, which could be classified as myorhythmia. Both Holmes tremor and myorhythmia are frequently attributed to the involvement of the common anatomical components of the dentato-rubro-olivary pathway.^{2,3} Furthermore, there is evidence of inferior olivary nucleus hypertrophy in both Holmes tremor and myorhythmia, as well as OPT.³ Therefore, the left brachial tremor, as well as the OPT, in this case may be explained by a common anatomical lesion due to a right paramedian pontine infarction. Skeletal muscle tremor, mainly of the upper limbs, may rarely be associated with palatal tremor.⁴ Similar to that of OPT, the left brachial tremor could be explained by abnormal oscillatory activity transmission to the skeletal muscles of the left brachium through the efferent pathways from the dentate nucleus.

The pathogenesis involved in the occurrence of this form of tremor is not fully understood. However, synchronous discharge from the hypertrophied inferior olivary nucleus is generally suggested as the pathogenesis.⁵ Oscillatory activity that originated from the inferior olivary nucleus was amplified in the cerebellum (Figure 1E). Moreover, the reason for the variable involvement of muscles is not well known. A lesion associated with selectivity in the interrupted fibers of the central tegmental tract could perhaps explain these differences.

In conclusion, we report the case of a patient with delayed OPBT with inferior olivary hypertrophy after pontine ischemic stroke, which suggested that OPBT can be a clinical spectrum of OPT based on the common shared pathogenesis.

Supplementary Video Legends

Video 1. Phenomenology of the involuntary movements of the patient.

The low-frequency, rhythmic, palatal tremor, with horizontal, pendular nystagmus and conjugate gaze deviation to the left side (which was thought to be a sequelae of stroke), as well as left brachial tremor at rest and during action, are shown.

Supplementary Materials

The online-only Data Supplement is available with this article at <https://doi.org/10.14802/jmd.20077>.

Conflicts of Interest

The authors have no financial conflicts of interest.

Acknowledgments

We would like to thank the patient and his family, who are the focus of this report.

Ethical Standard

All procedures performed in studies involving human participants were in accordance with the ethical standards of the institutional and/or national research committee and with the 1964 Declaration of Helsinki and its later amendments or comparable ethical standards.

Informed consent was obtained from all individual participants included in the study.

Author Contributions

Conceptualization: Ho-Sung Ryu, Yang-Ha Hwang. Data curation: all authors. Formal analysis: Ho-Sung Ryu, Yang-Ha Hwang. Methodology: all authors. Project administration: all authors. Resources: Ho-Sung Ryu, Yang-Ha Hwang. Software: Ho-Sung Ryu, Yang-Ha Hwang. Supervision: Ho-Sung Ryu, Yang-Ha Hwang. Validation: Ho-Sung Ryu, Yang-Ha Hwang. Visualization: Ho-Sung Ryu, Yang-Ha Hwang. Writing—original draft: Ho-Sung Ryu. Writing—review & editing: all authors. Approval of final manuscript: all authors.

ORCID iDs

Ho-Sung Ryu	https://orcid.org/0000-0001-7582-4731
Minsub Cho	https://orcid.org/0000-0002-3327-2411
Daeun Shin	https://orcid.org/0000-0003-4834-1026
Yang-Ha Hwang	https://orcid.org/0000-0002-6665-7481

REFERENCES

- Borruat FX. Oculopalatal tremor: current concepts and new observations. *Curr Opin Neurol* 2013;26:67-73.
- Raina GB, Cersosimo MG, Folgar SS, Giugni JC, Calandra C, Paviolo JP, et al. Holmes tremor: clinical description, lesion localization, and treatment in a series of 29 cases. *Neurology* 2016;86:931-938.
- Baizabal-Carvallo JF, Cardoso F, Jankovic J. Myorhythmia: phenomenology, etiology, and treatment. *Mov Disord* 2015;30:171-179.
- Alstadhaug KB. Oculopalatal and cerebellar limb tremor due to hypertrophic olivary degeneration. *Eur J Neurol* 2007;14:e6-e7.
- Shaikh AG, Hong S, Liao K, Tian J, Solomon D, Zee DS, et al. Oculopalatal tremor explained by a model of inferior olivary hypertrophy and cerebellar plasticity. *Brain* 2010;133(Pt 3):923-940.