

CLINICAL ARTICLE

CAD/CAM: Applications for transitional bonding to restore occlusal vertical dimension

Brian P. LeSage DDS, FAACD

Beverly Hills Institute of Dental Esthetics, Beverly Hills, California

Correspondence

Brian P. LeSage, Beverly Hills Institute of Dental Esthetics, 436 N. Roxbury Dr. Suite 100, Beverly Hills, CA 90210.
Email: brian@cosmetic-dentistry.com

Abstract

Objective: Explore the best technique for achieving stable and comfortable occlusion. This is critical for long-term oral health and the foundation of durable esthetic, restorative, periodontal, and prosthodontic treatments.

Clinical considerations: Various techniques and therapies have been proposed for establishing, determining, and restoring ideal centric relation (CR) and vertical dimension of occlusion (VDO) in patients who require restorations and/or full-mouth rehabilitation. An interim prosthesis phase can help establish and stabilize an enhanced esthetics and/or functional outcome for a limited period of time before the definitive dental restorations are placed. Transitional direct composite bonding and its additive nature have provided clinicians and patients with advantages when establishing a physiologic CR and VDO in interim restorations. However, it is time consuming, tedious, and challenging chairside. The author has been using additive CAD/CAM designed and milled restorations for over 10 years to make transitional bonding more efficient, manageable, and predictable.

Conclusion: Transitional bonded prostheses are significantly important to providing patients with an interim therapy to determine if the proposed esthetic outcome and occlusal scheme will function as expected, or if adjustments are needed prior to the delivery of the definitive long-term restorations. CR and VDO are essential for establishing a functional and healthy occlusion, ideal restoration proportions and smile design, and treatment planning esthetic and prosthodontic restorations for long-term durability.

Clinical significance: This article reviews CR, VDO, and the characteristics of a CAD/CAM transitional bonding technique in reversing the signs and symptoms of a compromised dentition and reestablishing an ideal esthetic and functional occlusal outcome. Transitional bonded prostheses are significantly important to providing patients with an interim therapy to determine if the proposed esthetic outcome and occlusal scheme will function as expected, or if adjustments are needed prior to the delivery of the definitive long term restorations.

This article was published online on 11 Dec 2019. An error was subsequently identified. This notice is included in the online and print versions to indicate that both have been corrected 20 Dec 2019.

This is an open access article under the terms of the Creative Commons Attribution-NonCommercial License, which permits use, distribution and reproduction in any medium, provided the original work is properly cited and is not used for commercial purposes.

© 2019 The Author. *Journal of Esthetic and Restorative Dentistry* published by Wiley Periodicals, Inc.

KEYWORDS

determining centric relation, restoring occlusal vertical dimension, transitional bonding, transitional CAD/CAM restorations, transitional occlusal restorations

1 | INTRODUCTION

A stable and comfortable occlusion is a cornerstone of long-term oral health and the foundation of durable esthetic, restorative, periodontal, and prosthodontic treatments. Loosely defined as the contact between the opposing surfaces of the maxillary and mandibular teeth, occlusion can also be described as the act or process of closure or of being closed or shut off; the static relationship between the incising or masticating surfaces of the maxillary or mandibular teeth or tooth analogues.¹ When rehabilitating a patient to correct the effects of tooth wear, attrition, and/or erosion, decay, structural damage, alignment issues, and/or temporomandibular joint (TMJ) disorders, determining the ideal centric relation (CR) position and vertical dimension of occlusion (VDO) is critical to restoring occlusal balance. In particular, CR and VDO are essential for establishing a functional and healthy occlusion, ideal restoration proportions and smile design, and treatment planning esthetic and prosthodontic restorations for long-term durability.²⁻⁶ Transitional bonding is an interim prototype or provisional phase, that uses direct composite or indirect restorations to trial function and esthetics prior to the fabrication of the definitive restorations.

CR has been defined and described in the literature in several ways based on condylar/disc relationship, TMJ mechanics, terminal hinge axis, jaw muscle relaxation and loading, and tooth position/contact characteristics. According to the Glossary of Prosthodontic Terms (GPT-9) in 2017, CR is a maxillomandibular relationship, independent of tooth contact, in which the condyles articulate in the anterior-superior position against the posterior slopes of the articular eminences; in this position, the mandible is restricted to a purely rotary movement; from this un-strained, physiologic, maxillomandibular relationship, the patient can make vertical, lateral or protrusive movements; it is a clinically useful, repeatable reference position.¹

Dawson suggests we acquire CR with proper alignment of the disk on the condyles in intact TMJs, the condyle-disk assemblies are pulled up the eminentiae by the triad of strong elevator muscles during jaw closure to the most superior position.⁷ The inferior lateral pterygoid muscles must be released completely, with the condyle-disk assemblies braced medially.^{7,8} This is the only condylar position that permits an interference-free occlusion.⁷ A properly aligned condyle-disk assembly in CR can resist maximum loading by the elevator muscles, with no sign of discomfort.⁷

To determine and record CR in patients presenting without pain or derangement in the TMJ, both condyles must be placed into their anterior uppermost position.^{3,4} Specifically, Ash has stated that CR is clinically determined when the condyle disk assemblies are positioned in their most superior position in the glenoid fossae and against the

distal slope of the articular eminence,¹ when the jaw can hinge on a fixed terminal axis (ie, up to 25 mm), and irrespective of vertical dimension or tooth position.⁹ However, in the presence of masticatory system dysfunction due to muscle instability, condyle condition, and retro-discal impingement, the relation of the mandible to the maxillae when the condyles are in the uppermost and rearmost position in the glenoid fossae may not be a predictable, repeatable recorded position.^{3,4}

Despite the significant emphasis placed on the position of the condyle in relationship to the disc, glenoid fossa, and muscles, it is also crucial to determine the *condition* of the joint prior to any complex restorative case. Therefore, as McKee and Piper have documented, it is important to visualize the condition of the joint,¹⁰ and clinicians should consider CBCT scans—which are included in today's arsenal of digital analysis tools—for this purpose. For Piper Classification I, II A and B, and III A and B, CR is the suitable position to restore the case.

VDO has been defined and determined in various ways due to a lack of consensus within the literature. There is no singular VDO that is better than another, nor a completely accurate method for determining it. A reasonable approach for determining VDO is using clinical judgment based on comparing and even combining different techniques.^{5,6,11-15}

VDO has been described in the context of contact between occluding members (ie, occlusal VD) and the physiologic rest position (ie, resting VD). VDO is defined as the distance between two selected anatomic or marked points (usually one on the tip of the nose and the other on the chin) when in maximal intercuspal position and is synonymous with the term occlusal vertical dimension (GPT-9). It is a three-dimensional (3D) space encompassing the infero-superior (cranio-caudal), medio-lateral, and antero-posterior functional vectors of mandibular positioning resulting from the many interlocking components of the craniofacial complex.^{14,15}

Alternatively, resting VDO is the distance between two selected points (eg, one of which is in the middle of the face or nose and the other on the lower face or chin) measured when the mandible is in the physiologic rest position. Highly variable with a range of between 2 and 4 mm, resting VDO is influenced by such factors as cranial-cervical posture (ie, head position and angle), stress, medications, speech, removable prosthesis, and the natural dentition, with or without occlusal pathology.^{5,6,14} Characterized by a considerable range of adaptability, the postural rest position range of comfort varies considerably among individuals and even within a single individual under different conditions.^{16,17}

Regardless of the manner in which it is determined (eg, cephalometry, sound of "M" in speech, appearance, diagnostic wax-ups, or set-ups), proper VDO positioning affects speech, breathing, eating, and

appearance.¹⁵⁻¹⁷ Additionally, both VDO and CR are significant to restorative and prosthodontic success by affecting esthetics, patient comfort when chewing, ideal tooth proportions, and functional longevity (ie, likelihood of withstanding mastication forces), all of which can translate to a better quality of life for patients.

Considerations for altering a patient's VDO are establishing space for restoring short or worn dentition (incisors less than 3 mm), enhancing the occlusal relationship, and improving esthetics by altering the facial form and/or tooth and gingival display. The clinician by implementing an outcome-based approach to restoring and/or establishing a patient's ideal VDO and CR must satisfy both the patient's esthetic goals and the clinician's functional requirements.

2 | RESTORING CR AND VDO

Numerous techniques and therapies have been proposed over the years to restore, establish, determine, and create the ideal CR and VDO in patients with masticatory dysfunction and/or worn, eroded, and/or otherwise compromised teeth who require restorations and/or full-mouth rehabilitation. Traditionally, the most practical and reliable method for determining and restoring a dentition to CR begins by taking analog polyvinyl siloxane (PVS) impressions, pouring and mounting study models on an articulator, using a CR bite and facebow transfer, and recording the guided position to develop a reconstructed dentition.^{15,18} The accuracy provided by PVS makes it preferred over polyether and plaster impressions.¹⁹

CR mounting and bite capturing can easiest be performed by deprogramming the patient's jaw's muscles over time with a Lucia Jig, e-Tab, or Kois deprogrammer. With the lateral pterygoid muscle relaxed, the clinician can additionally use the Kois deprogrammer or bimanual manipulation in conjunction with bite registration material to capture this joint based starting position. The face-bow transfer illustrates the antero-posterior and media-lateral occlusal plane inclinations, providing a reasonably accurate relationship between the maxillary arch and the rotational axis of the condyles.¹⁸ When carefully mounted on a semi-adjustable articulator using jaw relation records, these study casts are also the basis for restoring VD.^{10,16,17,20} Additional or duplicated mounted diagnostic wax-ups represent occlusal adjustments and are prudent for accurately assessing the status of the structural occlusion in conjunction with the dynamics of the functional occlusion.^{16,17}

This type of information contributes to better understanding and addressing the patient's adaptive capacity for occlusal changes and rehabilitation. Among the methods used initially to undertake such adaptations are splints, deprogrammers, and provisional or interim restorations. Additionally, many have suggested that after stabilizing the occlusion in a provisional/prototype phase, placement of definitive restorations can then be divided into affordable, efficient, and manageable phases or quadrants.

The interim prosthesis phase, in particular, is designed to enhance esthetics, stabilization, and/or function for a limited period of time—as well as enable a trial of the proposed treatment—after which the

definitive dental prosthesis is placed. Most importantly in terms of CR and VDO, interim prostheses assist in determining the therapeutic effectiveness of the form and function of the planned definitive restorations.^{21,22}

Typically during and after three or more months,²² the interim restorations (provisionals/prototypes) are assessed, monitored, modified, and/or altered to ensure harmonious and bilateral (ie, even distribution on both sides) contact of the dentition and maintain balanced occlusal function (eg, eating, speech, breathing).¹⁵ Esthetics are also evaluated, as well as patient comfort, after which the interim restorations serve as the blueprint for the definitive prosthesis.¹⁵

3 | THE ROLE OF TRANSITIONAL BONDING

The author defines transitional bonding as the use of bonded interim prostheses or prototype restorations—executed using either direct composites or indirectly fabricated provisionals—to reestablish esthetics, speech, functional stability (eg, eating, breathing), and occlusion that are sequentially transitioned into the definitive restorations. Not only do transitionally bonded prototypes/prostheses create a stable occlusion in CR with anterior coupling, but also they enable verification of the patient's desired outcomes, which can then be sequentially transitioned into the definitive restorations.

Overall, the additive nature of transitional bonding for establishing CR and VDO presents several advantages for clinicians and patients.²³ These include easier and simpler procedures, more manageable and predictable results, and greater cost-effectiveness. Today's direct composites demonstrate significant improvements over previous products (ie, strength, handling characteristics, durability, lower polymerization shrinkage rates) and are considered among the most versatile restorative materials available.²⁴⁻²⁶ Additionally, their minimally invasive nature allows greater preservation of sound tooth structure.²³

Unfortunately, direct restorative techniques have traditionally presented clinical challenges.^{27,28} These have included isolation, contamination, and individual patient characteristics and clinician abilities that have affected predictability of the restorative protocol.^{27,28} Likewise, transitional indirect restorations may also cause significant issues, including chipped, broken, or lost temporaries when trial therapy ranges from 3 to 6 months.

3.1 | Transitional bonding using CAD/CAM

Computer-aided-design and computer-aided-manufacturing (CAD/CAM) can make transitional bonding easier, more efficient, more manageable, and more predictable.

Additionally, the technologies and the materials available in a digital restorative workflow facilitate stabilization of complex functional and esthetic issues. In fact, today's dental CAD/CAM systems (eg, CEREC AC Omnicam or CEREC Primescan AC, Sirona Dental

Systems, Charlotte, NC) and millable composite blocks (eg, Lava Ultimate and Paradigm MZ100 by 3M ESPE; Telio and Tetric CAD by Ivoclar Vivadent; CeraSmart by GC; Enamic by VITA) enable dentists to deliver predictable interim prostheses in one appointment. All blocks have the physical properties to meet the short term (3-12 months) requirements of CAD/CAM transitional bonding. These highly esthetic and functional provisional/prototype restorations—which can withstand mastication forces—can help to establish ideal occlusion.²⁷⁻²⁹

Highly accurate, efficient, and predictable for fabricating well-fitting frameworks in fewer steps than traditional laboratory processes,³⁰⁻³² CAD/CAM systems can be used to design transitionally bonded prostheses in several ways (eg, biogeneric copy, biogeneric reference, and biogeneric individual are proprietary CEREC design software options).³³ When definitive restorations are CAD/CAM fabricated, they have demonstrated survival rates comparable to traditional hand-fabricated restorations.³⁴

In recent years, the literature has increasingly cited the utility of CAD/CAM fabricated transitional bonding composite restorations for reconstructing or redefining VDO.³⁵⁻³⁸ CAD/CAM transitional bonding interim prototypes/prostheses are highly homogeneous compared to direct restorations, which increases long-term stability, biocompatibility, and wear resistance.³⁵ Because these restorations can be milled extremely thin for placement on occlusal surfaces, little to no tooth preparation is required, contributing to a minimally invasive and additive rehabilitation approach.³⁵⁻³⁹

3.1.1 | Procedure overview

All necessary diagnostic information—including a proper series of photographs, radiographs, full-arch/full mouth PVS impressions, CR bite registration, face-bow transfer, and models—are obtained. Given the additive nature of CAD/CAM transitional bonding, only aprismatic enamel, which has been shown to lower bond strengths, can be removed using a MicroEtcher II (Zest Dental Solutions) or a coarse diamond (Brasseler, Savannah, GA). Once this minimally invasive preparation is completed, impressions can be taken either conventionally with PVS material, or digitally (see Tables 1 or 2).

TABLE 1 CAD/CAM analog, indirect transitional bonding steps

1	Scan the mounted models
2	Evaluate the opening
3	Scan the buccal bite on the articulator that was mounted in CR
4	Draw margins to establish the transitionally bonded onlay
5	Design the onlay and preview
6	Mill the transitional bonded onlay (eg, LAVA Ultimate, 3M ESPE; Telio CAD, Ivoclar Vivadent, Enamic, VITA)
7	Finish and polish milled composite onlay
8	Cement and adjust

In the analog, conventional technique (Table 1), PVS impressions are inspected for voids and defects, and models are poured and articulated on a semi-adjustable articulator using a face-bow transfer and CR bite registration. A diagnostic mock-up/wax-up is made, but is not necessary, as the CAD/CAM software can digitally mock-up the occlusion.

Either diagnostic mock-up, laboratory fabricated with wax or CAD/CAM digitally created, can then be digitally scanned for use in designing the indirect transitional bonded prosthesis. The CEREC software can then be used in biogeneric copy mode to fully design and then mill a transitionally bonded onlay restoration that will help establish the occlusion at the ideal CR and VDO as determined from the diagnostic mounting. When naturally shaped CAD designed occlusal inlay/onlay surfaces have been studied, they have been found to be as good as conventional wax-ups created by laboratory technicians.³⁹

Alternatively, instead of taking conventional analog impressions, the teeth and preparations can be scanned intraorally (Table 2) with a digital impression scanner (CEREC AC Omnicam or CEREC Primescan AC, Sirona Dental Systems). Additionally, an intraoral buccal bite registration scan is taken to capture the occlusal relationship of the maxilla to the mandible while in CR and at the proper VDO.⁴⁰ After scanning, the digital impressions are used to create a digitally articulated model in the CEREC software. This subsequently forms the basis for developing a virtual—or digital—diagnostic mock-up.

Whether the single or quadrant onlay prototypes are designed in an analog fashion or purely digital fashion, the interim restoration/prototypes can be milled in the clinician's material of choice.

The CAD/CAM transitional bonding restoration is then tried in the patient's mouth to confirm fit, function, and esthetics, then, adhesively bonded into place. Any necessary adjustments are made at this time and over a 3-to-6-months trial time frame for most cases.

3.2 | Case example

A 43-year-old female presented with the chief complaint that the crown on her upper left tooth (#14) came out the previous week, and she was not happy with her veneers (Figures 1 and 2). A frequent

TABLE 2 CAD/CAM digital, direct transitional bonding steps

1	Scan the patient's dentition
2	Using a Lucia Jig or eTab to attain CR position, then establish the VDO
3	Scan the buccal bite in the patient's mouth in CR at the determined VDO
4	Draw margins to establish the transitionally bonded onlay
5	Design the onlay and preview
6	Mill the transitional bonded onlay (eg, LAVA Ultimate, 3M ESPE; Telio CAD, Ivoclar Vivadent, Enamic, VITA)
7	Polish milled composite onlay
8	Cement and adjust

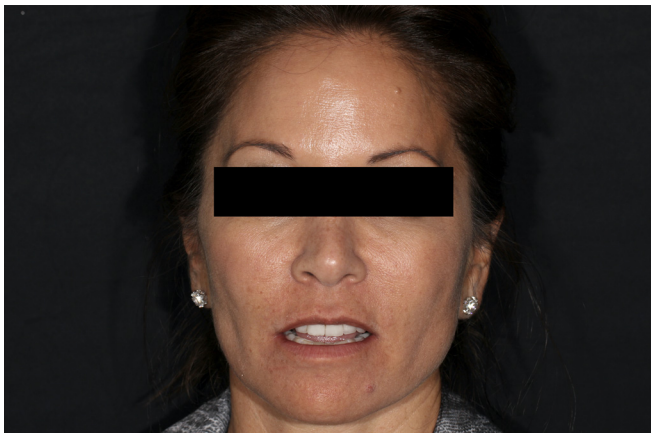

FIGURE 1 Full facial preoperative view of the patient in the relaxed lip position, demonstrating her excessive incisal reveal

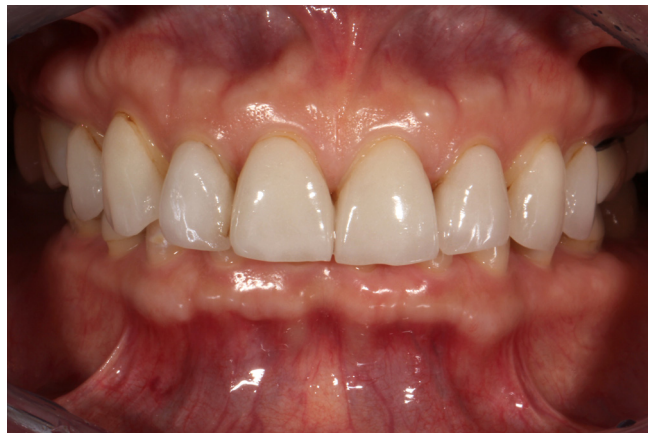

FIGURE 3 Close-up retracted view of the patient in maximum intercuspitation, showing 100% vertical overlap/overbite

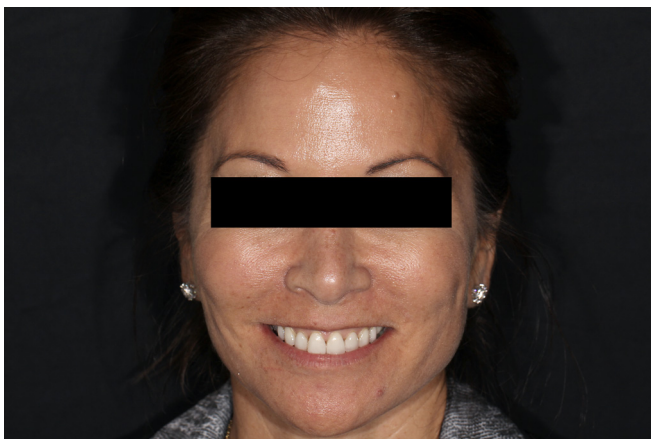

FIGURE 2 Although her smile was pleasing, the patient disliked her maxillary teeth embedding into her lower lip, and she wanted a fuller, broader smile

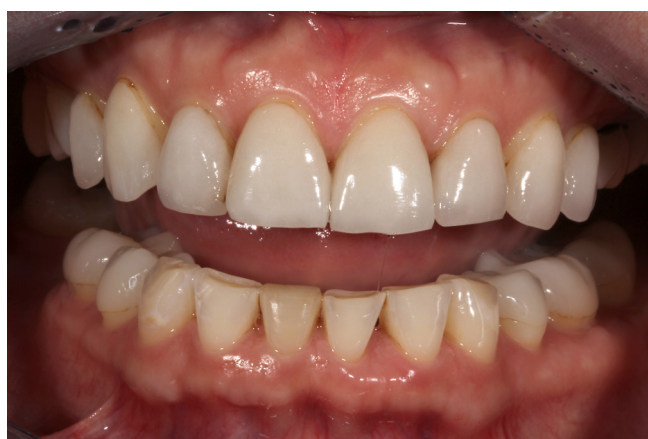

FIGURE 4 Retracted view showing attrition and wear that exposed dentin on the unrestored mandibular teeth

business traveler, the patient admitted she might not be consistent in her ability to keep scheduled appointments.

Esthetically, the existing veneers on teeth #5 through #12 exhibited compensatory eruption with mildly excessive tooth display. Restoratively, the veneer margins showed moderate breakdown and associated gingival recession. The patient was not happy with their color, indicating that tooth #25 was dark. The patient demonstrated 100% vertical overlap or overbite (Figure 3). Functionally, excessive wear was noted on the lower teeth with moderate dentin exposure due to porcelain on the opposing maxillary teeth and parafunctional grinding, and there was generalized, mild attrition on the remaining teeth (Figure 4). Radiographically, the patient was missing tooth #31, tooth #14 had decay in the roof of the furcation leading to a poor prognosis and eventual extraction, and there were signs of generalized, early bone loss.

Models mounted in CR on a SAM3 (Great Lakes Dental Technologies, Tonawanda, NY) articulator confirmed all clinical findings (Figure 5). To record CR, the author likes to use a modified Lucia Jig

made directly in the mouth with composite. The patient is asked to slide forward, backward, and squeeze on the flat composite plane to assist with physiologic and anatomic positioning of the condyles into the glenoid fossae. Bimanual manipulation as taught by Dr. Peter Dawson using Blu-Mousse (Parkell, Edgewood NY) bite registration allows for consistent, repeatable attained CR position.

Esthetically and functionally, the patient had lost VDO as seen in the mounted models and full-face images. Analyzing the mounted models demonstrated that it would be possible to wax-up teeth #3 through #15 and teeth #21 through #28 to reestablish a proper VDO in CR, guided by the esthetic outcome the patient desired and the functional requirements for a long-term stable dentition (Figures 6 and 7). A CBCT scan was done of the patient to assess the condition of the joint and implant site #14. The joint was free of pathosis and the implant site #14 was insufficient in a vertical dimension for routine implant placement. The patient opted for a bridge to replace extracted tooth #14 since the adjacent teeth were restored already and she did not want sinus surgery.

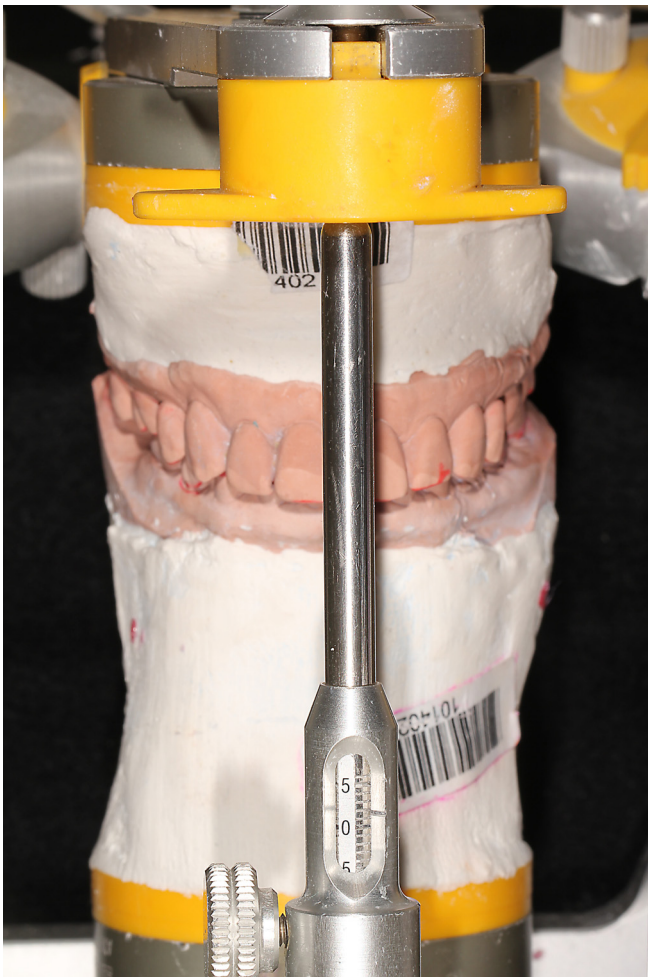

FIGURE 5 Study models of the original dentition were mounted with facebow and CR bite registration on SAM3 articulator, with pin at 2.5 mm

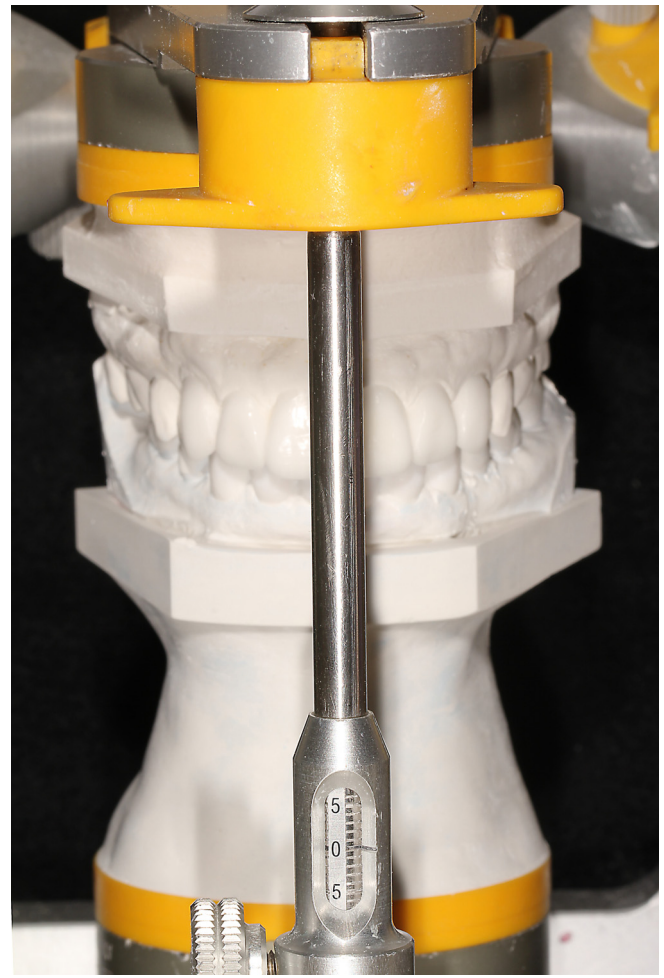


FIGURE 6 An esthetic wax-up was created to increase the patient's VDO to meet the esthetic demands of the patient and the functional parameters of the clinician. The pin was at slightly below 0

Using the CEREC system, digital scans of the esthetic diagnostic wax-up and the original models were made. By using the Biogeneric Copy function (Figures 8 and 9), composite veneer and onlay restorations (Lava Ultimate, 3M ESPE for single units; TeliCAD-Temp, Ivoclar Vivadent for multiple units on posterior teeth) were fabricated individually for teeth #21 through #28, #3, #5, and splinted for bridge #13 through #15.

After milling, a coarse diamond wheel is used to remove the sprue. The milled restorations are polished with diamond wheels (Dialite, Brasseler), starting with pink and then followed by grey, to remove the remnants of the sprue and create a smooth, well contoured restoration. The internal surfaces of the transitional prototypes/prostheses are checked for contaminants from the milling process and polishing, and placed in alcohol filled ultra-sonic for 1 minute to remove residue and prepare the restoration from adhesive bonding.

For the mandibular teeth #22 through 27 that are in the esthetic zone, composite layered veneers, as described by this author,^{41,42} were fabricated. This technique involves cutting back and layering in translucency and maverick coloring (Creative Color Tint, Cosmedent,

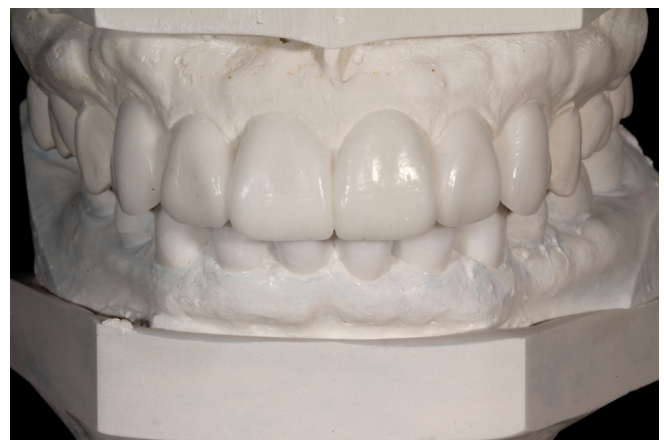

FIGURE 7 Close-up view of the esthetic wax-up showing the new VDO

Chicago, Illinois), to allow the patient the benefit of a preview of the polychromicity, translucency, incisal halo, and so on of the definitive restorations in addition to working out function.

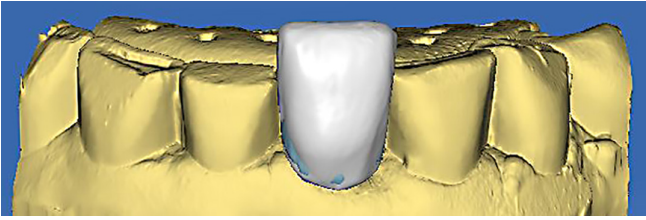


FIGURE 8 View of the digital design of the veneer for tooth #24 using the CEREC Biogeneric Copy




FIGURE 9 Digital scan of the diagnostic wax-up of teeth #22-27 used in biogeneric copy to merge with the pre-op scan to assist in designing the prototype/provisional restorations

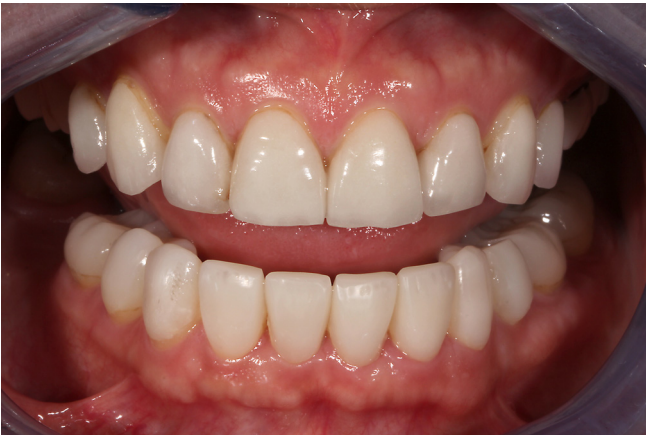

FIGURE 10 View of the composite layered veneers on teeth #21 through #28

Further polishing can occur with diamond polishing paste (Enamelize, Cosmedent) placed on a pad and thinned. Using a wet goat hair brush incorporating a chamois, pressure is applied as the polisher is moved back and forth over the restorations surface. The electric handpiece (NSK, Brasseler) is then set on 24 in the 1:1000 mode, and the interim restoration is polished with a dry goat hair brush with chamois (Brasseler), slight pressure, and the diamond polishing paste (Enamelize). During polishing, care should be taken to finish back to the margins. The adhesive bonding protocol for Lava Ultimate restorations is to lightly air abrade (30 psi) the intaglio surface of the restorations with the MicroEtcherII, silanate, and adhesively bond with a light cured or dual cured cement (DuoLink, Bisco, Schaumburg, Illinois).

To maximize the ease and efficiency of fabrication, and esthetics, the maxillary anterior teeth were completed with a direct mock-up from the wax-up, and the maxillary posterior teeth and the mandibular

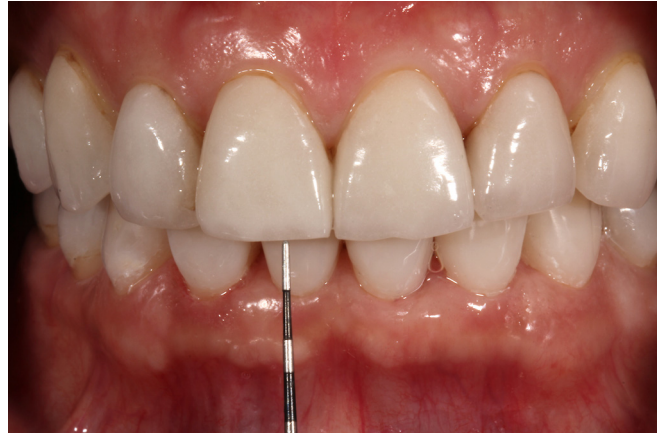

FIGURE 11 View of the new VDO in CR

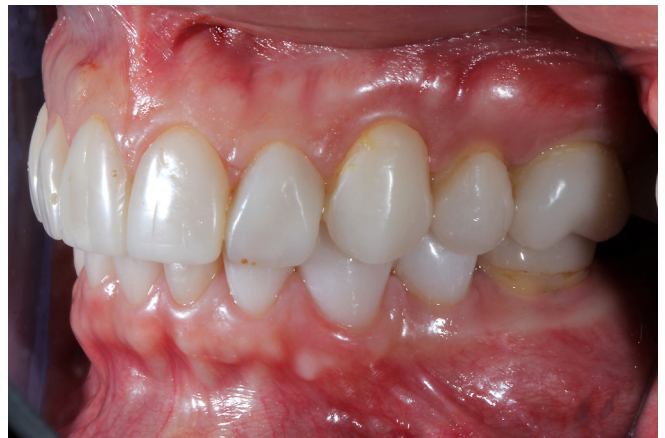

FIGURE 12 Right lateral retracted view of the patient in CR coinciding with MIP, with the long-term prototypes bonded into place

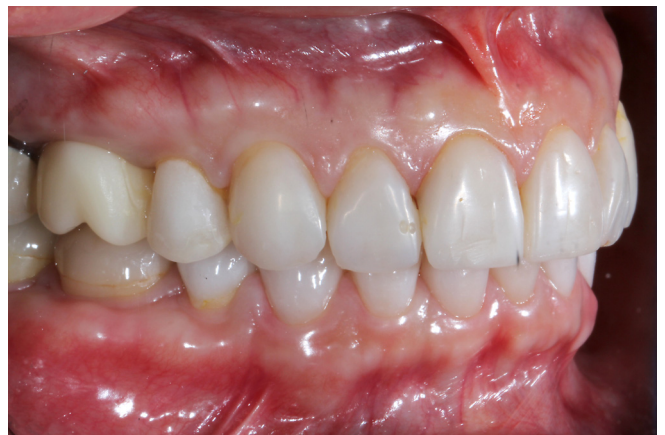

FIGURE 13 Left lateral retracted view of the patient in CR coinciding with MIP, with the long-term prototypes bonded into place

teeth were completed with CAD/CAM using CEREC. The maxillary anterior ceramic veneers were cut back, and according to routine porcelain bonding, overlaid with composite (Reveal, Bisco).

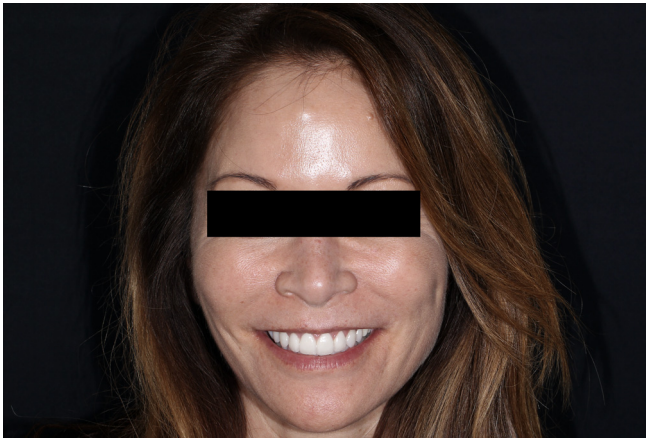

FIGURE 14 Full-facial view of the patient following placement of the final restorations, without any issues. Note that the smile is in harmony and balance with her face

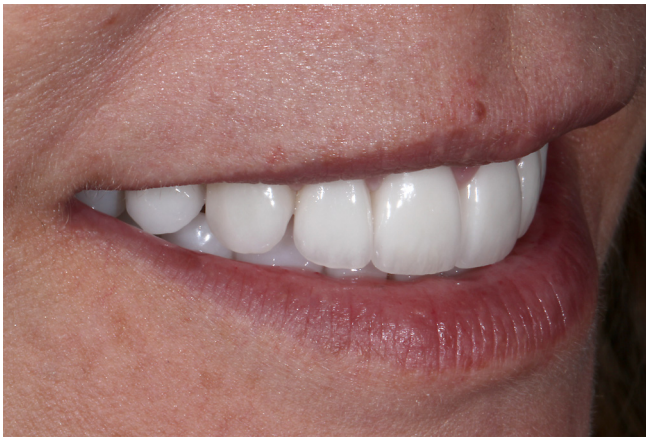

FIGURE 15 Right lateral smile view of the definitive restorations

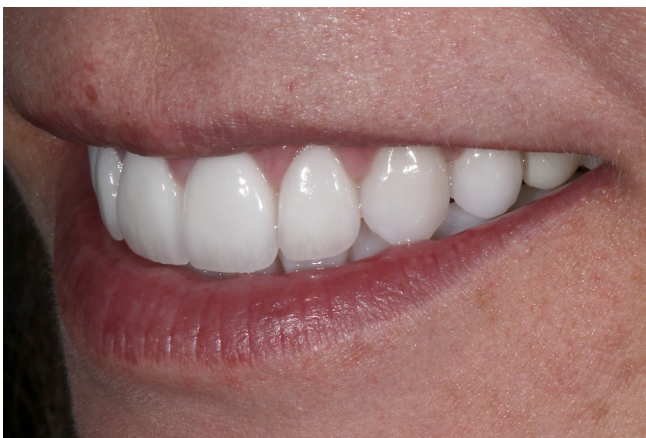

FIGURE 16 Left lateral smile view of the definitive restorations

The patient was able to observe and confirm comfort and mastication (Figures 10–13). Having experienced no failures during a 3-to-12-month period with little to no attrition (Figure 14), the prototype restorations were replaced with the definitive restorations in a

timeline that was convenient for the patient (Figures 15 and 16). This transformation spanned more than 2-and-a-half years due to the patient's busy work and travel schedule.

In the conventional “analog” world, having a patient in temporaries for 2+ years would require an unimaginable number of visits for repair and replacement. In this case, no additional appointments were required for repairs or recementing of the interim prototype restorations. This case demonstrates the manner in which CAD/CAM fabricated prototypes can be predictably and easily used to help manage and simplify the transition when the VDO is lost and must be reestablished in wear cases.

4 | CONCLUSION

Transitional bonding with CAD/CAM fabricated composite restorations represents the application of innovative, scientifically proven systems, methods, and knowledge to the challenges of predictably establishing and restoring a patient's CR and VDO. It can aid with sequencing, and for many, making it financially feasible to undergo full mouth rehabilitation. Transitional bonded prostheses are significantly important to providing patients with an interim therapy to determine if the proposed esthetic outcome and occlusal scheme will function as expected, or if adjustments are needed prior to the delivery of the definitive long-term restorations.

ACKNOWLEDGMENT

The author acknowledges ceramist YiYuan Chang and Domenico Cascion for performing the laboratory work involved with completing the case presented in this article.

DISCLOSURE

The author does not have any financial interest in the companies whose materials are included in this article.

REFERENCES

1. The glossary of prosthodontic terms. *J Prosthet Dent.* 2017;117(55): 1-105.
2. Boucher CO. Complete denture prosthodontics—the state of the art. *J Prosthet Dent.* 1975;34(4):372-383.
3. Lucchini JP, Lavigne J, Spirgi M, Meyer JM. The centric relation. IV. Variations in condylar positions according to the methods of measuring centric relation and to the patient's clinical type. *SSO Schweiz Monatsschr Zahnheilkd.* 1978;88(1):1-12.
4. Ash MM Jr, Ramfjord SP. Reflections on the Michigan splint and other intraocclusal devices. *J Mich Dent Assoc.* 1998;80(8):32-35. 41-6.
5. Gattozzi JG, Nicol BR, Somes GW, Ellinger CW. Variations in mandibular rest positions with and without dentures in place. *J Prosthet Dent.* 1976;36(2):159-163.
6. Pound E. Controlling anomalies of vertical dimension and speech. *J Prosthet Dent.* 1976;36(2):124-135.
7. Dawson PE. *Evaluation, Diagnosis, and Treatment of Occlusal Problems.* 2nd ed. St Louis: Mosby; 1989.
8. Spear F. *Mastering the Art of Treatment Planning and Treating Anterior Esthetic Dilemmas.* UCLA Aesthetic Continuum program. UCLA Dental School; 2005.

9. Timm TA, Herremans EL, Ash MM Jr. Occlusion and orthodontics. *Am J Orthod*. 1976;70(2):138-145.
10. McKee J, Piper M, et al. Interdisciplinary treatment of the foundationally compromised patient. 60th Annual AES Meeting; 2015; Chicago.
11. Fayz F, Eslami A, Graser GN. Use of anterior teeth measurements in determining occlusal vertical dimension. *J Prosthet Dent*. 1987;58(3):317-322.
12. Harper RP. Clinical indications for altering vertical dimension of occlusion. Functional and biologic considerations for reconstruction of the dental occlusion. *Quintessence Int*. 2000;31(4):275-280.
13. Rugh JD, Johnson RW. Vertical dimension discrepancies and masticatory pain/dysfunction. *Abnormal Jaw Mechanics*. Chicago: Quintessence; 1984:117-133.
14. Chapman R, Mehta N. The craniofacial complex and vertical dimension: proper positioning improves speech, breathing, eating and appearance. *Inside Dentistry*. 2013;54-78.
15. Rivera-Morales WC, Mohl ND. Restoration of the vertical dimension of occlusion in the severely worn dentition. *Dent Clin N Am*. 1992;36(3):651-664.
16. Rivera-Morales WC, Mohl ND. Relationship of occlusal vertical dimension to the health of the masticatory system. *J Prosthet Dent*. 1991;65(4):547-553.
17. Ferrario VF, Sforza C, Serrao G, Schmitz JH. Three-dimensional assessment of the reliability of a postural face-bow transfer. *J Prosthet Dent*. 2002;87(2):210-215.
18. Dawson PE. New definition for relating occlusion to varying conditions of the temporomandibular joint. *J Prosthet Dent*. 1995;74(6):619-627.
19. Hoods-Moonsammy VJ, Owen P, Howes DG. A comparison of the accuracy of polyether, polyvinyl siloxane, and plaster impressions for long-span implant-supported prostheses. *Int J Prosthodont*. 2014;27(5):433-438.
20. Fayz F, Eslami A. Determination of occlusal vertical dimension: a literature review. *J Prosthet Dent*. 1988;59(3):321-323.
21. Nanda A, Jain V, Manak K, Verma M. An alternative adhesive based technique of raising the occlusal vertical dimension. *Indian J Dent Res*. 2014;25(4):505-508.
22. Nanda A, Jain V, Srivastava A. An electromyographic study to assess the minimal time duration for using the splint to raise the vertical dimension in patients with generalized attrition of teeth. *Indian J Dent Res*. 2011;22(2):303-308.
23. Palmer KM. Use of additive dentistry decreases risk by minimizing reduction. *Compend Contin Educ Dent*. 2012;33(5):346-350.
24. LeSage BP. Aesthetic anterior composite restorations: a guide to direct placement. *Dent Clin N Am*. 2007;51(2):359-378.
25. Sensi LG, Strassler HE, Webley W. Direct composite resins. *Inside Dent*. 2007;3:76.
26. Fortin D, Vargas MA. The spectrum of composites: new techniques and materials. *J Am Dent Assoc*. 2000;131:265-305.
27. Fasbinder DJ. Restorative material options for CAD/CAM restorations. *Compend Contin Educ Dent*. 2002;23(10):911-916. 918,920.
28. Christensen GJ. Is now the time to purchase an in-office cad/cam device? *J Am Dent Assoc*. 2006;137(2):235-238.
29. McLaren E. Personal communication.
30. Fasbinder DJ. Materials for chairside CAD/CAM restorations. *Compend Contin Educ Dent*. 2010;31(9):702-4-708-9.
31. Abduo J, Bennani V, Waddell N, Lyons K, Swain M. Assessing the fit of implant fixed prostheses: a critical review. *Int J Oral Maxillofac Implants*. 2010;25(3):506-515.
32. Lin WS, Harris BT, Zandinejad A, Morton D. Use of digital data acquisition and CAD/CAM technology for the fabrication of a fixed complete dental prosthesis on dental implants. *J Prosthet Dent*. 2014;111(1):1-5.
33. Patel N. Contemporary dental CAD/CAM: modern chairside/lab applications and the future of computerized dentistry. *Compend Contin Educ Dent*. 2014;35(10):739-746.
34. Wittneben JG, Wright RF, Weber HP, Gallucci GO. A systematic review of the clinical performance of CAD/CAM single-tooth restorations. *Int J Prosthodont*. 2009;22(5):466-471.
35. Edelhoff D, Beuer F, Schweiger J, Brix O, Stimmelmayer M, Guth JFCAD. CAM-generated high-density polymer restorations for the pretreatment of complex cases: a case report. *Quintessence Int*. 2012;43(6):457-467.
36. Stumbaum M, Konec D, Schweiger J, Gernet W. Reconstruction of the vertical jaw relation using CAD/CAM. *Int J Comput Dent*. 2010;13(1):9-25.
37. Vailati F, Carciofo S. CAD/CAM monolithic restorations and full-mouth adhesive rehabilitation to restore a patient with a past history of bulimia: the modified three-step technique. *Int J Esthet Dent*. 2016;11(1):36-56.
38. Schlichting LH, Resende TH, Reis KR, Magne P. Simplified treatment of severe dental erosion with ultrathin CAD/CAM composite occlusal veneers and anterior bilaminar veneers. *J Prosthet Dent*. 2016;116:474-482.
39. Litzemberger AP, Hickel R, Richter MJ, Mehl AC, Probst FA. Fully automatic CAD design of the occlusal morphology of partial crowns compared to dental technicians' design. *Clin Oral Investig*. 2013;17(2):491-496.
40. Fritzsche G. Efficient quadrant restoration with the new Cerec software. *Int J Comput Dent*. 2010;13(3):275-281.
41. LeSage B. Direct composite resin layering techniques for creating life-like CAD/CAM-fabricated composite resin veneers and crowns. *J Prosthet Dent*. 2014;112(1):5-8.
42. LeSage B. Composites in a three-dimensional world. *Dent Today*. 2011;30(10):106-111.

How to cite this article: LeSage BP. CAD/CAM: Applications for transitional bonding to restore occlusal vertical dimension. *J Esthet Restor Dent*. 2020;32:132-140. <https://doi.org/10.1111/jerd.12554>