



ELSEVIER

Contents lists available at ScienceDirect

## IJID Regions

journal homepage: [www.elsevier.com/locate/ijregi](http://www.elsevier.com/locate/ijregi)

## Case Report

## Pseudotumoural pulmonary tuberculosis: a case series

S. Zayet\*, A. Berriche, L. Ammari, F. Kanoun, B. Kilani, H. Tiouiri Benaissa

Infectious Diseases Department, La Ranta Hospital, 1007, Tunis, Tunisia



## ARTICLE INFO

## Keywords:

Tuberculosis  
Pseudotumoural  
Pulmonary mass  
Lung carcinoma  
Human immunodeficiency virus  
Efavirenz

## ABSTRACT

This report describes three cases of tumour-like pulmonary tuberculosis: two patients had stage C3 human immunodeficiency virus (HIV) infection (with uncontrolled HIV-1 in one case) and one patient was immunocompetent. All patients initially presented with general and respiratory symptoms, with radiological findings simulating lung carcinoma. Tuberculosis was diagnosed from microbiological testing and/or histological examination results. A disseminated form was described in one case. All patients were treated successfully with antimycobacterial therapy, with control of HIV infection in both cases.

## Introduction

Worldwide, tuberculosis (TB) remains an important public health problem and one of the main causes of death, with a total of 1.4 million deaths in 2019 [including 208,000 people with human immunodeficiency virus (HIV) infection] (Harding, 2020). Pulmonary TB accounts for more than 50% of cases. Several unusual radiographic features of pulmonary TB are well known, including lymphadenopathy without infiltrates, lower lobe infiltrates and solitary tuberculoma. Parenchymal masses are distinctly rare in TB, and few cases have been reported in the medical literature (Cherian et al., 1998; Agarwal et al., 2008; Snene et al., 2018; Kabiri et al., 2020). Pseudotumoural pulmonary TB (PTPT) is a rare radiological manifestation of pulmonary TB, mimicking lung carcinoma. Thus, the diagnosis can be delayed and lead to surgical resection. To highlight the clinical challenges of PTPT, this report describes three retrospective cases in two patients with HIV infection (one with uncontrolled HIV-1) and one immunocompetent patient in Tunisia, a high-endemicity region.

## Observation 1, 2017

A 26-year-old male with HIV infection (stage C3, Centers for Disease Control and Prevention) presented with fever, fatigue and respiratory symptoms including haemoptysis, non-productive cough and shortness of breath. He had been experiencing symptoms for 4 weeks. The patient was treated with amoxicillin/clavulanate (3 g/day orally for 7 days) as an outpatient with mild community-acquired pneumonia, but showed no clinical response. He was also receiving efavirenz 600 mg/tenofovir

disoproxil fumarate 200 mg/emtricitabine 245 mg (EFV/TDF/FTC), but showed poor compliance and had a detectable HIV viral load (VL).

On admission, physical examination revealed blood pressure of 110/65 mmHg, regular heartbeat (110 beats/min), fever (39°C), stomatitis with oral candidiasis, and normal pulmonary auscultation. Laboratory findings revealed an elevated white cell count of 12.4 Giga/L (normal range 4–10 Giga/L) with lymphopenia of 310/mm<sup>3</sup> (normal range 1500–4000/mm<sup>3</sup>). C-reactive protein was high at 210 mg/L (normal range <5 mg/L), and renal and liver function tests were normal (Table 1). Chest computed tomography (CT) scan showed a right posterior mediastinal mass associated with mediastinal necrotic lymphadenopathy (Figure 1). Supportive treatment commenced (oxygen support and analgesics). Tuberculin skin test (Mantoux) and microscopic examination of sputum for acid-fast bacilli (AFB) were negative. The patient underwent bronchoscopy with bronchoalveolar lavage (BAL) culture, which was positive for *Mycobacterium tuberculosis*. Positive colonies were observed on Lowenstein–Jensen (LJ) glycerated egg-based medium 3 weeks after BAL culture. BAL cytology did not show the presence of malignant cells.

Pulmonary TB was diagnosed from the results of microbiological testing. Oral antimycobacterial therapy (AMT) consisting of isoniazid (INH), rifampicin (RIF), pyrazinamid and ethambutol was commenced, and antiretroviral therapy (ART; EFV/TDF/FTC) was stopped. The patient's general condition improved progressively, respiratory symptoms regressed, and he was discharged on the same oral treatment for 2 months followed by a regimen containing INH and RIF for 4 months, leading to complete recovery. The ART regimen was re-introduced 2 weeks after starting AMT, with good compliance and undetectable VL.

\* Corresponding author. Infectious Diseases Department, La Rabta Hospital, Tunisia. Tel.: +21622576624.

E-mail address: [souhail.zayet@gmail.com](mailto:souhail.zayet@gmail.com) (S. Zayet).

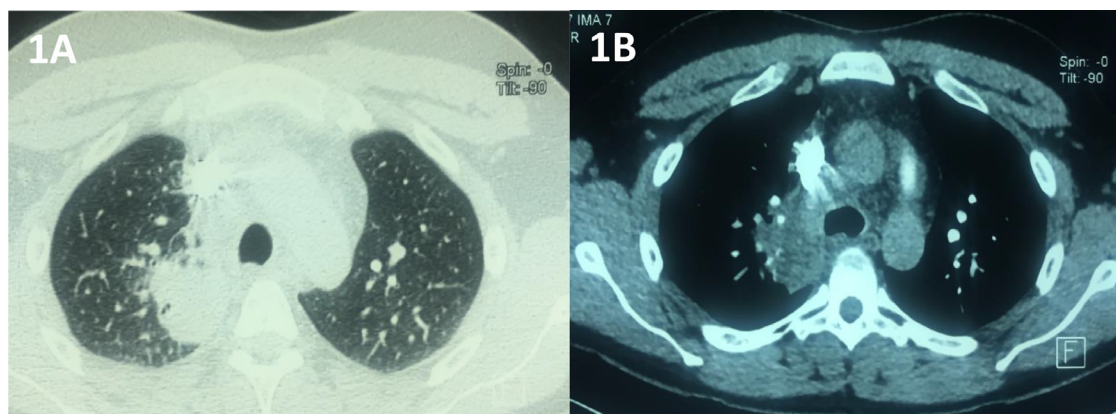
**Table 1**

Demographic and clinical characteristics, and laboratory and imaging findings in patients with pseudotumoral pulmonary tuberculosis, University la Rabta Hospital, Tunis, Tunisia

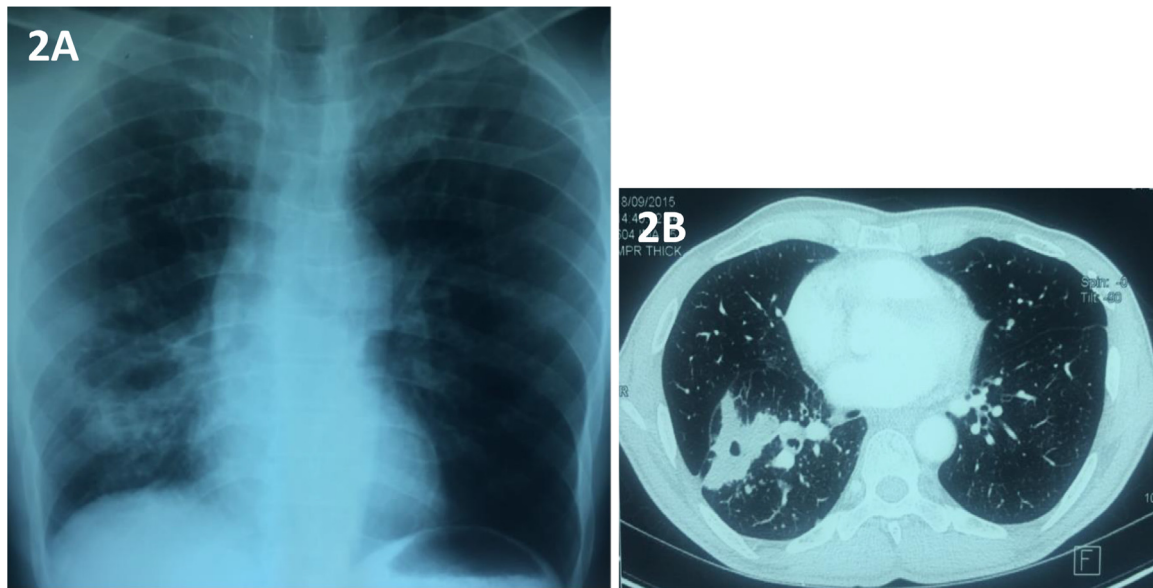
	Patient 1	Patient 2	Patient 3
<b>Demographic and sociobehavioural characteristics</b>			
Age (years)/sex	26/M	54/M	38/M
Recent travel/past history of pulmonary TB	No/no	No/yes	No/no
Social behaviours/addiction	Smoke tobacco and electronic cigarettes, drink alcohol and use illicit drugs	PWID	-
<b>HIV status</b>			
HIV status/CDC stage	Positive/C3	Positive/C3	Negative
HIV transmission	Heterosexual	Injection drug use	-
CD4 cell counts (/mm <sup>3</sup> )	14/mm <sup>3</sup>	600/mm <sup>3</sup>	-
CD4 nadir (/mm <sup>3</sup> )	14/mm <sup>3</sup>	1/mm <sup>3</sup>	-
Viral load (cells/mL)	130,000	<50	-
HIV regimen (ART)	EFV/TDF/FTC	3TC/AZT/LPVr	-
<b>Clinical characteristics, and laboratory and imaging findings</b>			
Clinical presentation	Fever, fatigue haemoptysis, cough and polypnoea	Fever, fatigue, weight loss, haemoptysis and chest pain	Fever, weight loss, diarrhoea and abdominal pain
Duration of symptoms (days)	30	55	90
<b>Laboratory data (on admission)</b>			
White cell count/mm <sup>3</sup> (4000–10,000/mm <sup>3</sup> )	12400	7510	17800
Lymphocytes/mm <sup>3</sup> (1500–4000/mm <sup>3</sup> )	310	940	510
Haemoglobin, g/dL (13.5–17.5 g/dL)	10.8	11.6	12
Alanine aminotransferase, U/L (8–45 U/L)	21	13	145
Aspartate aminotransferase, U/L (10–40 U/L)	34	38	178
C-reactive protein, mg/L (<5 mg/L)	210	93	178
<b>ABG (on admission)</b>			
pH	7.3	7.39	-
PaO <sub>2</sub> /PaCO <sub>2</sub> (mmHg)	49/33.7	93/38.9	-
SaO <sub>2</sub> (%)	91	97	-
<b>Tuberculin skin test (Mantoux)</b>			
QuantIFERON-TB Gold	Negative (4 mm)	Negative	Positive (18 mm)
AFB direct examination (specimen)	ND	ND	ND
<i>Mycobacterium tuberculosis</i> culture <sup>a</sup> (specimen)	Negative (sputum/BAL)	Negative (sputum/BAL)	Positive (sputum)
Negative culture (under treatment)/delay (weeks)	Positive (BAL)	Positive (BAL)	Positive (sputum)
Histological examination	Yes (3)	Yes (3)	Yes (4)
	-	-	Granulomas with (+) Ziehl–Neelsen staining
<b>Radiologic data (imaging features)</b>			
	Thoracic CT showing right mediastinal mass	Thoracic CT showing right lower lobe mass	Thoracic and abdominal CT showing left upper lobe mass with enlarged lymph nodes and spleen

3TC, lamivudine; ABG, arterial blood gases; AFB, acid-fast bacilli; ART, antiretroviral therapy; AZT, zidovudine; BAL, bronchoalveolar lavage; CDC, Centers for Disease Control and Prevention; CT, computed tomography; EFV, efavirenz; FTC, emtricitabine; HIV, human immunodeficiency virus; LPVr, lopinavir/ritonavir; ND, not determined; PWID, people/person who injected drugs; TB, tuberculosis; TDF, tenofovir disoproxil fumarate.

<sup>a</sup> Lowenstein–Jensen glycerated egg-based medium was used as the gold standard medium for *M. tuberculosis* culture.



**Figure 1.** Chest computed tomography image [axial lung window (1A) and axial mediastinal window (1B)] showing a large right posterior mediastinal mass with coarse boundary, associated with mediastinal necrotic lymphadenopathy, without peripheral consolidation or pleural effusion.



**Figure 2.** Posteroanterior chest radiograph (2A) showing irregular opacity projecting over the right lower lobe, and confirmed in the chest computed tomography axial parenchymal window (2B). This showed the presence of a right lower lobe pulmonary mass with central excavation associated with multiple bilateral nodules.

at week 36. Six-month follow-up chest CT showed disappearance of the mediastinal mass and lymph nodes.

#### Observation 2, 2017

A 54-year-old male with well-controlled HIV-1 infection (CD4 count  $600/\mu\text{L}$  and undetectable VL on lamivudine/zidovudine 150 mg/300 mg and lopinavir/ritonavir 200 mg/50 mg) presented to the emergency room with a 2-month history of respiratory symptoms of haemoptysis and chest pain associated with fever and weight loss. He reported a history of pulmonary TB treated successfully in 2010. On admission, clinical examination revealed unilateral crackling sounds on pulmonary auscultation and fever ( $39.4^{\circ}\text{C}$ ). All laboratory investigations are detailed in Table 1. Chest radiography showed an irregular opacity in the right lower lobe (Figure 2A), and this was confirmed by CT scan (Figure 2B). Bronchial fibroscopy with BAL and bronchial biopsies were normal. Finally, BAL culture identified *M. tuberculosis* in LJ solid medium. AMT was started and ART was discontinued for 2 weeks then switched to EFV/TDF/FTC. The patient was discharged free of general and respiratory symptoms, and TB treatment was successful after 6 months, with a significant reduction in the size of the pulmonary lesion and nodules without any fibrosis.

#### Observation 3, 2018

A 38-year-old male with no past history presented with gastrointestinal symptoms, including intermittent diarrhoea without mucous and abdominal pain, fever and weight loss. He had been experiencing symptoms for 3 months. He was febrile ( $38.3^{\circ}\text{C}$ ) and had crackling sounds on pulmonary auscultation. All laboratory findings are detailed in Table 1. AFB sputum smear was positive. Direct examination and culture of stool sample were negative. Peripheral blood cultures were negative. Thoracic and abdominal CT scans showed a left upper lobe pulmonary mass (Figure 3A); multiple intra-abdominal enlarged hypodense lymph nodes, especially in the terminal ileum; hepatomegaly; and an enlarged spleen (Figure 3B). Targeted biopsies were performed during colonoscopy. On histological examination, light microscopy showed granulomas composed of aggregates of epithelioid histiocytes, with necrosis and positive Ziehl–Neelsen staining. Pulmonary and abdominal TB was diagnosed from microbiological testing and histological study. First-line anti-TB agents were prescribed and maintained

for 12 months, with no evidence of relapse. Follow-up CT scans obtained within 1 year of treatment onset were normal. The current decline is 37 months and the patient is free of symptoms.

#### Discussion

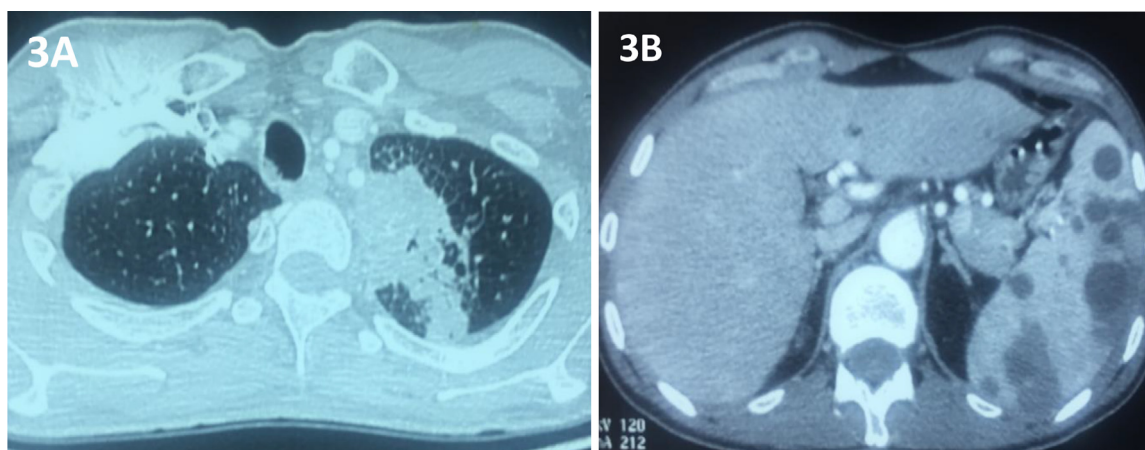
This paper reports a case series of male patients in Tunisia with typical pulmonary TB symptoms but with radiological findings compatible with lung carcinoma.

PTPT is a particular form of TB which is infrequent and not specific (Agarwal et al., 2008). In a large cohort of approximately 600 confirmed cases of pulmonary TB, Cherian et al. (1998) reported that mass-like densities were only described in 11 patients (4.3%). The masses were predominantly in the lower lobes and were not usually associated with fibro-productive satellite lesions, calcification or cavitation (Cherian et al., 1998).

PTPT has been observed previously in patients with HIV infection (Coulibaly et al., 1992; Saadoun et al., 1998). A causal link has never been established, except an epidemiological link. This may be explained by the high incidence of both diseases and their co-infection in these countries (Harding, 2020). Mechanistically, tubercular pseudotumoural masses may be due to conglomerate nodes (lymph nodal pseudotumour) or parenchymal granulomatous masses (Agarwal et al., 2008).

The symptoms of PTPT are not specific; the most prevalent are cough, chest pain and haemoptysis (Agarwal et al., 2008). Due to clinical and radiological findings showing parenchymal masses, several aetiologies such as polyangiitis with granulomatosis (GPA) and lymphoma are often suspected at first. Immunological investigations such as negative antineutrophil cytoplasmic antibodies can rule out GPA with pulmonary manifestations. However, only microbiological and/or histological testing can confirm a diagnosis of TB and exclude neoplastic diseases.

Concerning microbiological confirmation, *M. tuberculosis* culture was positive in BAL specimens but not in sputum specimens in two of the three cases in this series. In another case series, Agarwal et al. (2008) concluded that sputum specimens were positive for AFB in 25% of patients with parenchymal PTPT. This can be explained by the solid and poorly oxygenated nature of the lesions. Fibroscopy (with bronchial aspiration and/or BAL) specimens seem to be the gold standard examination for this TB entity. With high culture sensitivity, this procedure can identify smear-negative patients and re-



**Figure 3.** Chest computed tomography (3A) showing a spiculated left upper lobe pulmonary mass with ground-glass opacities, alveolar consolidation in linear atelectasis and multiple nodules. Abdominal computed tomography (3B) showed hepatomegaly (17 cm) with an enlarged spleen (13 cm) and multiple low-density nodules.

duce time to diagnosis (Gressens et al., 2021). It can also identify the neoplastic-like presence of a bud or lung infiltration, leading to diagnosis from biopsy results (Snene et al., 2018; Kabiri et al., 2020).

Finally, therapy and treatment duration are the same for PTPT as for common forms of TB. In the case of TB–HIV co-infection, ART should ideally be initiated within the first 2 weeks of TB treatment for patients with CD4 cell counts  $<50/\text{mm}^3$  to avoid a paradoxical reaction or immune reconstitution inflammatory syndrome (Meintjes et al., 2019). Managing drug interactions in the treatment of HIV-related TB in developing countries can be problematic (Meintjes et al., 2019). In the two HIV patients in this series, EFV/TDF/FTC was used as ART with no dose adjustment for two reasons: (i) rifabutin, which has fewer drug interactions than RIF, may be used as an alternative in HIV-infected patients but this formulation is not available in Tunisia; and (ii) integrase inhibitors, such as dolutegravir and raltegravir, which are being used increasingly in ART regimens in TB-endemic settings have limited availability at the study facility, which severely limits the options for co-treatment of TB and HIV.

### Conclusion

Pulmonary TB can rarely present as a pseudotumour mass. This case series highlights PTPT as a rare presentation, mainly in smear-negative patients, and discusses therapeutic options in patients with HIV–TB co-infection in low-to-middle-income countries.

### Conflict of interest statement

None declared.

### Funding

None.

### Ethical approval

Due to the retrospective nature of the study, the Ethics and Scientific Committee of La Rabta Hospital determined that patient consent was not required, and the study was approved by the Ethical Board.

### Author contributions

SZ and AB wrote the clinical reports. BK described the radiological data and reviewed the report. All authors revised the final manuscript.

### References

- Agarwal R, Srinivas R, Aggarwal AN. Parenchymal pseudotumoral tuberculosis: case series and systematic review of literature. *Respir Med* 2008;102:382–9.
- Cherian MJ, Dahniya MH, Al-Marzouk NF, Abel A, Bader S, Buerki K, et al. Pulmonary tuberculosis presenting as mass lesions and simulating neoplasms in adults. *Australas Radiol* 1998;42:303–8.
- Coulibaly G, N'Dhartz M, Domoua K, Traore F, Quattara B, Vincent A, et al. [Tuberculosis of bronchi and lymph nodes mimicking cancer in a patient with HIV-infection]. *Rev Pneumol Clin* 1992;48:282–4.
- Gressens SB, Billard-Pomares T, Leboité H, Cruaud P, Bouchaud O, Carboneille E, et al. Pulmonary tuberculosis: evaluation of current diagnostic strategy. *Infect Dis Now* 2021;51:273–8.
- Harding E. WHO global progress report on tuberculosis elimination. *Lancet Respir Med* 2020;8:19.
- Kabiri EH, Alassane EA, Kamdem MK, Bhairis M, Amraoui M, El Oueriachi F, et al. Tuberculous cold abscess of the chest wall: a clinical and surgical experience. Report of 16 cases (case series). *Ann Med Surg* 2020;51:54–8.
- Meintjes G, Brust JCM, Nuttall J, Maartens G. Management of active tuberculosis in adults with HIV. *Lancet HIV* 2019;6:463–74.
- Saadoun R, Débat Zoguéréh D, Niang M, Moreau J. [Endobronchial tuberculosis presenting as an obstructive tumor in an HIV-1-positive patient. Apropos of a case and review of the literature]. *Rev Med Interne* 1998;19:344–7.
- Snene H, Ben Mansour A, Toujani S, Ben Salah N, Mjid M, Ouahchi Y, et al. [Tuberculous pseudotumour, a challenging diagnosis]. *Rev Mal Respir* 2018;35:295–304.