

Bilateral Inferiorly Based Labia Majora Flaps: A Simple Technique for Post Episiotomy Dehiscence Coverage

Deepak Krishna^{1*}, Gaurav Chaturvedi¹, Manal M Khan¹, Rahul Dubepuria²

1. Department of Burns and Plastic Surgery, All India Institute of Medical Sciences, Bhopal, India
2. Department of Trauma and Emergency, All India Institute of Medical Sciences, Bhopal, India

ABSTRACT

Episiotomy dehiscence because of infection is a cause of major physical, psychological and social problems. Management depends on the degree of injury. The loco-regional flap can be considered in recurrent dehiscence with loss of tissue. We report a case of a 26-year-old female who presented with a post episiotomy wound in the perineal region extending from the posterior fourchette to the anal opening. She gave the history of resuturing of dehiscence twice but the result was the same. On examination, there was a loss of skin and subcutaneous tissue between vaginal and anal opening with pouting of the anal and vaginal mucosa. Per rectal examination, the anal tone was normal. Her wound was covered with bilateral inferiorly based labia majora flaps with a good outcome. So, an inferiorly based labia majora flap can be a useful option in coverage of recurrent perineal dehiscence.

KEYWORDS

Inferiorly based Labia Majora Flap; Episiotomy Dehiscence

Please cite this paper as:

Krishna D, Chaturvedi G, M Khan M, Dubepuria R. Bilateral Inferiorly Based Labia Majora Flaps: A Simple Technique for Post Episiotomy Dehiscence Coverage. *World J Plast Surg.* 2022;11(3):78-83.

doi: 10.52547/wjps.11.3.78

INTRODUCTION

Childbirth-related perineal trauma usually requires suturing of spontaneous tear or episiotomy incision. Perineal wound dehiscence often occurs because of infection. The reported rate of perineal wound infection varies from 0.3% to 10%¹⁻³ and may as high as 39%-79% when associated with perineal wound dehiscence resuturing³. Wound dehiscence in open episiotomy was reported up to 1.07%, while in 4th-degree tears it may further rise to 4.6%⁴.

The wound in a perineovulvar region can be closed primarily or with local tissue repositioning if small. Reconstruction with a split-thickness or full-thickness skin graft is not a good option in perineal wound coverage and has a high rate of graft loss, and secondary contracture results in distortion of introitus, with resultant functional and aesthetic sequelae^{5,6}. Larger defects require local or regional flap from the groin or thigh, furthermore flap viability may be compromised due to mobilization of the legs and stretching of the pedicle^{5,7}. Another option that may be tried is inferiorly based labia minora flap but the quality of skin does not match with the recipient site⁸. The benefits of

*Corresponding Author:

Deepak Krishna

Department of Burns and Plastic Surgery, All India Institute of Medical Sciences, Bhopal, India

Tel.: +91 8802119962

Email:

deepak.plasticsurg@aiimsbhopal.edu.in

Received: 05 Apr 2022

Accepted: 06 Jun 2022



This work is licensed under a Creative Commons Attribution-NonCommercial 4.0 International license (<https://creativecommons.org/licenses/by-nc/4.0/>). Non-commercial uses of the work are permitted, provided the original work is properly cited.

labia majora flaps are that it has consistent vascular anatomy based on the posterior labial artery, which is a continuation of the internal pudendal artery⁵.

CASE PRESENTATION

A 26-year-old female presented at All India Institute of Medical Sciences, Bhopal, India in 2019 with complaints of a wound in the perineal region extending from posterior fourchette to anal opening, burning sensation, and fecal soiling of the introitus. The patient gave a history of episiotomy 1 month back following which the suture line was infected leading to its dehiscence. After that wound was re-sutured twice after control of infection but the result was the same. On examination, there was a loss of skin and subcutaneous tissue between vaginal and anal opening with pouting of both vaginal and anal mucosa due to wound contraction (Figure 1). The

anal tone was normal. The patient was also getting worried about achieving normal sexual intercourse in the future.

She was planned for wound coverage with bilateral inferiorly based labia majora flaps once the wound got ready.

The patient was operated in the lithotomy position and the urinary bladder was catheterized. After the recreation of the wound, the defect size became 2 x 3 cm muscle deep. 4 x 1.5 cm sized inferiorly based flaps marked on both sides of the labia majora. Flaps containing skin and subcutaneous tissue were elevated (Figure 2) and transposed at the defect site in a side-to-side fashion (Figure. 3). The Donor site defects were closed primarily. The patient was kept on a liquid diet for 5 days with bed rest and later on, she was allowed to ambulate. The postoperative period was uneventful and flaps were healthy. Sutures were removed after two weeks. On

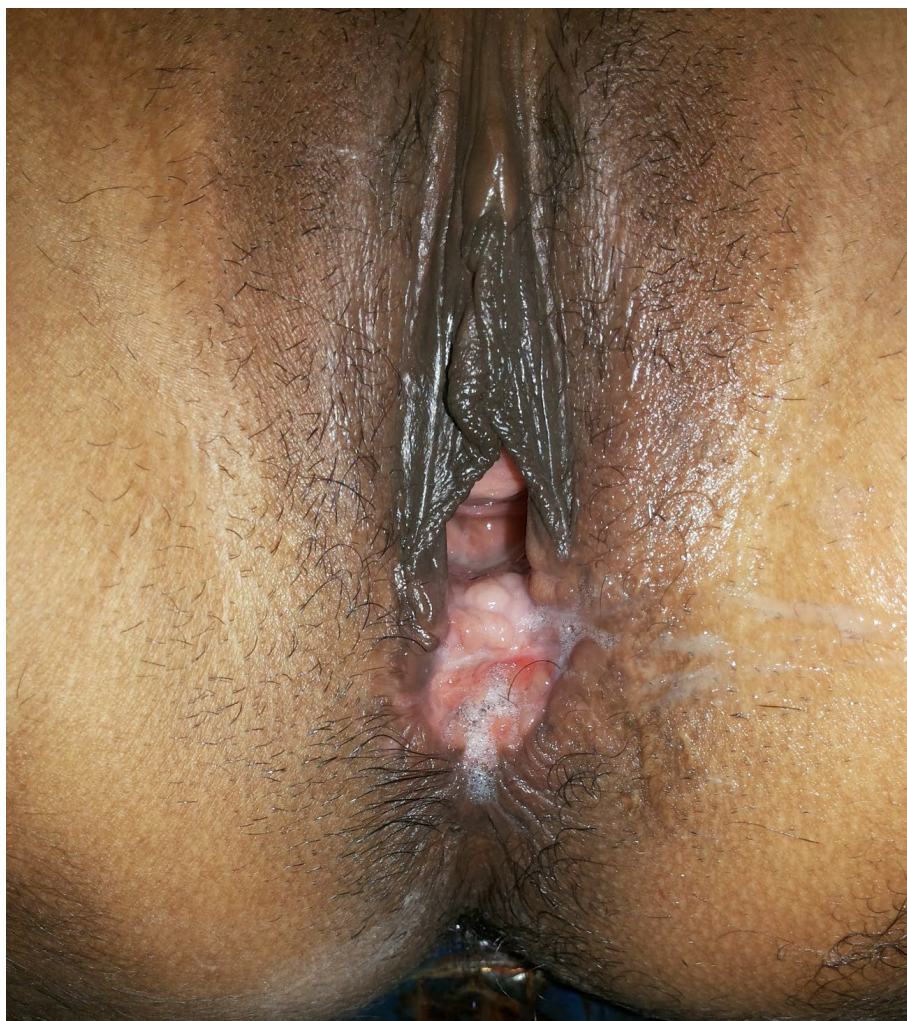

Fig. 1: Post Episiotomy dehiscence with pouting of vaginal and anal mucosa

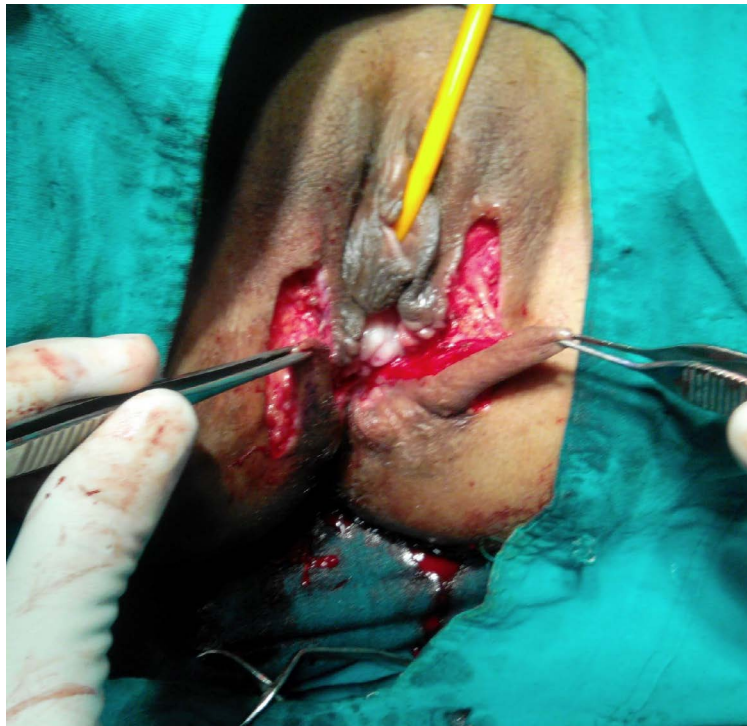


Fig. 2: Elevated flaps containing skin and subcutaneous tissue

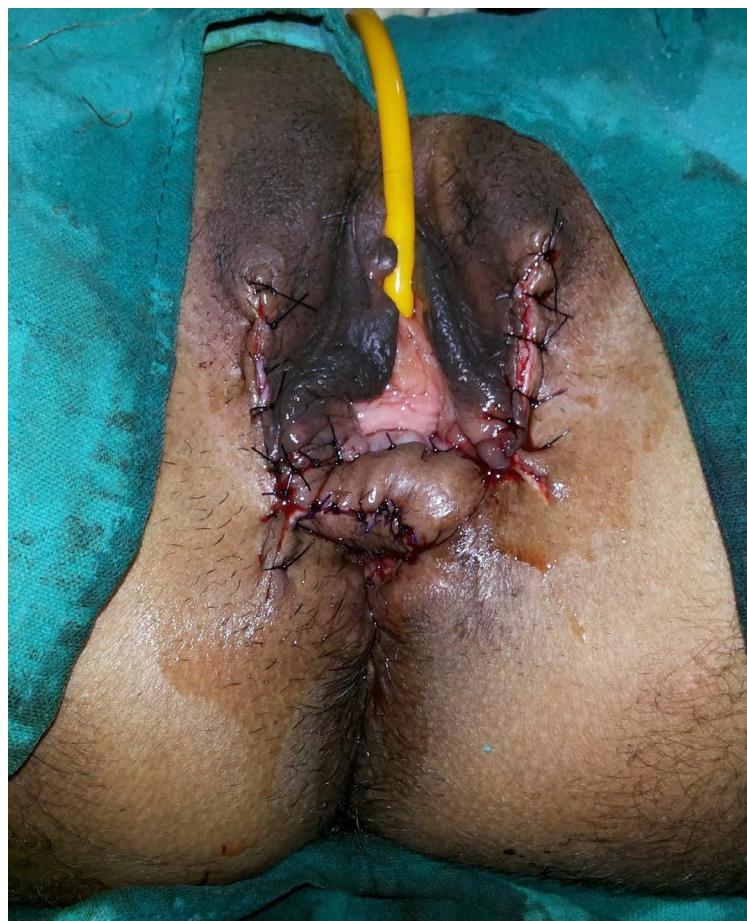

Fig. 3: Flaps transposed at defect in side-to-side manner




Fig. 4: Six months follow-up

six months follow up the flaps were healthy and aesthetically appealing (Figure. 4). The patient was also happy with her sex life as well.

Declaration of patient consent

The authors certify that they have obtained all appropriate patient consent forms. The patient has given her consent for her images and other clinical information to be reported in the journal. The patient understands that her name and initial will not be published and due efforts will be made to conceal her identity, but anonymity cannot be guaranteed. Guidelines of the declaration of Helsinki statement were followed during this study.

DISCUSSION

The traditional conservative approach to episiotomy dehiscence is allowing it to heal by secondary intention^{9,10}. This approach of conservative management with associated morbidity poses a serious threat to a woman's general well-being and

quality of life due to persistent pain, discomfort, fecal soiling at the perineal wound site, and dyspareunia, psychological and psychosexual issues from embarrassment, and altered body image^{3,9,10}.

Re-suturing is associated with reduced duration to wound healing and improved women's satisfaction with the outcome at 3 months³. In contrast, other groups of clinicians who are in favor of expectant management argue that re-suturing is an additional surgical procedure that carries the risk of recurrence of wound infection and breakdown⁹. The available evidence on surgical management of episiotomy dehiscence is limited.

Vacuum-assisted closure technique can be applied in the preparation of complex and large perineal wounds before closure or fastening the secondary healing process but it takes multiple applications of VAC therapy and immobilization for a long period. Application of vacuum-assisted closure therapy in episiotomy dehiscence is very challenging due to natural openings and creases resulting in air leaks, which require frequent changes of vacuum

dressing¹¹. The resultant scar is cosmetically not good and may require revision.

Fecal diversion is advisable to manage infected complex perineal soft tissue injuries to prevent further fecal contamination^{12,13}. A case of fecal diversion with loop ileostomy was described in a case of episiotomy dehiscence with rectal injury to permit healing before repair of the anal sphincter¹⁴. Obstetric anal sphincter injuries (OASI) must be assessed in perineal dehiscence. Primary or secondary reconstruction of the anal sphincter is necessary to improve quality of life¹⁵⁻¹⁸.

Transposition of local skin flaps may prevent recurrent wound dehiscence resulting from undue tension of secondary suturing in the inflamed area and distortion of the introitus, or anus because of wound contraction⁷. An ideal reconstructive option should have the following characteristics (1) bring desired amount of well-vascularized skin and subcutaneous tissue, (2) reestablish the function and sensibility of the perineovulvar area, (3) single-stage procedure with minimal donor site morbidity, (4) minimal problem in both walking and sitting^{6,7}. V-Y advancement flap has been described after excision of episiotomy scar, which can be utilized for coverage of perineal defect but advancement flap has its own limitation in terms of movement¹⁹. Pedicled gracilis myocutaneous flap, perforator flaps based on the internal pudendal artery and gluteal artery perforators, and Singapore fasciocutaneous flap have been described to cover acquired perineal and vaginal defects but these flaps usually require for coverage of larger defect and bulky in nature²⁰⁻²⁴. Labia majora flap has been described to reconstruct opposite side labia defects^{5,25}. The benefits of inferior-based labia majora flap is that it retains the characteristic soft pliable nature and hair-bearing quality of perineal skin, is not bulky, sensory in nature, and has no additional donor site management is required. Leg movement and patient position do not cause tension on the labia majora flap⁵. We used inferiorly based labia majora flap because it has a consistent vascular supply from the internal pudendal artery, is locally available, and has less operative time, no significant donor site morbidity. However, this flap causes some degree of decreased volume in the lower part of labia majora and exposure to labia minora, so we opted for a bilateral flap for reconstruction to maintain symmetry. This option also leaves other local and regional flap options spared for the future.

CONCLUSION

The labia majora flap is shown to be an elegant single-stage option for perineal reconstruction, providing the best match in terms of tissue consistency, pigmented skin colour, hair-bearing characteristics, and contour with minimal donor site morbidity.

FUNDING

None

CONFLICT OF INTEREST

The authors declare that there is no conflict of interests.

REFERENCES

1. Johnson A, Thakar R, Sultan AH. Obstetric perineal wound infection: is there underreporting? *Br J Nurs* 2012;**21**(5): S28-S35. doi: 10.12968/bjon.2012.21.Sup5.S28.
2. Jones K, Webb S, Manresa M, Hodgetts-Morton V, Morris RK. The incidence of wound infection and dehiscence following childbirth-related perineal trauma: A systematic review of the evidence. *Eur J Obstet Gynecol Reprod Biol* 2019; **240**:1-8. doi: 10.1016/j.ejogrb.2019.05.038.
3. Dudley L, Kettle C, Thomas PW, Ismail KM. Perineal resuturing versus expectant management following vaginal delivery complicated by a dehisced wound (PREVIEW): a pilot and feasibility randomised controlled trial [published correction appears in *BMJ Open* 2017 Mar 7;7(3): e012766corr1]. *BMJ Open*. 2017;7(2): e012766. Published 2017 Feb 10. doi:10.1136/bmjopen-2016-012766.
4. Kamel A, Khaled M. Episiotomy and obstetric perineal wound dehiscence: beyond soreness. *J Obstet Gynaecol* 2014;**34**(3):215-7. doi:10.3109/01443615.2013.866080.
5. Lee H, Yap YL, Low JJ, Lim J. Labia Majora Share. *Arch Plast Surg* 2017;**44**(1):80-4. doi:10.5999/aps.2017.44.1.80.
6. Hage JJ, Beurden Mv. Reconstruction of acquired perineovulvar defects: a proposal of sequence. *Semin Plast Surg* 2011;**25**(2):148-54. doi:10.1055/s-0031-1281484.
7. Salgarello M, Farallo E, Barone-Adesi L, et al. Flap algorithm in vulvar reconstruction after radical, extensive vulvectomy. *Ann Plast Surg* 2005;**54**(2):184-90. doi: 10.1097/01.sap.0000141381.77762.07.
8. Nguyen AT, Ramsden AJ, Corrigan BE, Ritz M. Labial reconstruction with a cross-labial flap. *J Plast Reconstr*

- Aesthet Surg* 2011;**64**(10):1383-85. doi: 10.1016/j.bjps.2011.02.015.
9. Webb S, Sherburn M, Ismail KM. Managing perineal trauma after childbirth. *BMJ* 2014;**349**: g6829. Published 2014 Nov 25. doi:10.1136/bmj.g6829.
 10. Ramin SM, Ramus RM, Little BB, Gilstrap LC 3rd. Early repair of episiotomy dehiscence associated with infection. *Am J Obstet Gynecol* 1992;**167**(4 Pt 1):1104-7. doi:10.1016/s0002-9378(12)80047-0.
 11. Yadav S, Rawal G, Baxi M. Vacuum assisted closure technique: a short review. *Pan Afr Med J* 2017; **28**:246. Published 2017 Nov 21. doi:10.11604/pamj.2017.28.246.9606.
 12. Kudsk KA, Hanna MK. Management of complex perineal injuries. *World J Surg* 2003;**27**(8):895-900. doi:10.1007/s00268-003-6719-z.
 13. Kudsk KA, McQueen MA, Voeller GR, Fox MA, Mangiante EC Jr, Fabian TC. Management of complex perineal soft-tissue injuries. *J Trauma* 1990;**30**(9):1155-60. doi:10.1097/00005373-199009000-00012.
 14. Rose CH, Blessitt KL, Araghizadeh F, Morrison JC. Episiotomy dehiscence that required intestinal diversion. *Am J Obstet Gynecol* 2005;**193**(5):1759-60. doi: 10.1016/j.ajog.2005.08.037.
 15. Harvey MA, Pierce M, Alter JE, et al. Obstetrical Anal Sphincter Injuries (OASIS): Prevention, Recognition, and Repair [published correction appears in *J Obstet Gynaecol Can* 2016 Apr;**38**(4):421] [published correction appears in *J Obstet Gynaecol Can*. 2016 Apr;**38**(4):421]. *J Obstet Gynaecol Can*. 2015;**37**(12):1131-48. doi:10.1016/s1701-2163(16)30081-0.
 16. Meister MR, Rosenbloom JI, Lowder JL, Cahill AG. Techniques for Repair of Obstetric Anal Sphincter Injuries. *Obstet Gynecol Surv* 2018;**73**(1):33-9. doi:10.1097/OGX.0000000000000521.
 17. Viannay P, de la Codre F, Brochard C, et al. Management and consequences of obstetrical anal sphincter injuries: Review. *J Visc Surg* 2021;**158**(3):231-41. doi: 10.1016/j.jvisc.2020.10.010.
 18. Chase S, Mittal R, Jesudason MR, Nayak S, Perakath B. Anal sphincter repair for fecal incontinence: experience from a tertiary care centre. *Indian J Gastroenterol* 2010;**29**(4):162-5. doi:10.1007/s12664-010-0037-9.
 19. Lenoir P, Lallemand M, Vilchez M, Ramanah R. V-Y advancement flap to correct a perineal defect after an episiotomy dehiscence. *Int Urogynecol J* 2021;**32**(7):1935-37. doi:10.1007/s00192-020-04658-x.
 20. Weinstein B, King KS, Triggs W, Harrington MA, Pribaz J. Bilobed Gracilis Flap: A Novel Alternative for Pelvic and Perineal Reconstruction. *Plast Reconstr Surg* 2020;**145**(1):231-4. doi:10.1097/PRS.0000000000006341.
 21. Ducic I, Dayan JH, Attinger CE, Curry P. Complex perineal and groin wound reconstruction using the extended dissection technique of the gracilis flap. *Plast Reconstr Surg* 2008;**122**(2):472-8. doi:10.1097/PRS.0b013e31817d607d.
 22. Moura FS, Chasapi M, Mitchell P, Dalal MD. Perineal Turn over Perforator Flap: A Novel Surgical Technique for Combined Perineal and Posterior Vaginal Wall Reconstruction. *World J Plast Surg* 2021;**10**(1):114-8. doi:10.29252/wjps.10.1.114.
 23. Wagstaff MJ, Rozen WM, Whitaker IS, Enajat M, Audolfsson T, Acosta R. Perineal and posterior vaginal wall reconstruction with superior and inferior gluteal artery perforator flaps. *Microsurgery* 2009;**29**(8):626-9. doi:10.1002/micr.20663.
 24. Pope RJ, Brown RH, Chipungu E, Hollier LH Jr, Wilkinson JP. The use of Singapore flaps for vaginal reconstruction in women with vaginal stenosis with obstetric fistula: a surgical technique. *BJOG* 2018;**125**(6):751-6. doi:10.1111/1471-0528.14952.
 25. Yamamoto S, Yano T, Furubayashi G, Sawaizumi M. A Labia Majora Sharing Perforator Flap for Labial Defect Reconstruction. *Plast Reconstr Surg Glob Open* 2020;**8**(6):e2931. Published 2020 Jun 25. doi:10.1097/GOX.0000000000002931.