

Complete splenic infarction in association with COVID-19

Graham Prentice,¹ Stephen Wilson,¹ Alexander Coupland,² Stephen Bicknell¹

¹Respiratory Department, Queen Elizabeth University Hospital, NHS Greater Glasgow and Clyde, Glasgow, UK

²Radiology Department, Queen Elizabeth University Hospital, NHS Greater Glasgow and Clyde, Glasgow, UK

Correspondence to

Dr Graham Prentice;
graham_prentice@hotmail.com

Accepted 14 November 2021

SUMMARY

COVID-19 predominantly affects the respiratory system. As a novel disease, understanding of its management and complications continues to grow. Herein, we present a case of almost complete splenic infarction in a patient with COVID-19 pneumonia. This case highlights the need to maintain diagnostic vigilance whilst investigating secondary complications of COVID-19. It is also important to stress the high incidence of thromboembolic complications in patients with COVID-19, which may occur anywhere in the vasculature.

BACKGROUND

COVID-19 infection results in a spectrum of disease, from asymptomatic, to life-threatening and often fatal severe acute respiratory syndrome. The triad of fever, persistent cough and fatigue are the most prevalent symptoms.¹

Associated complications are constantly evolving, and thromboembolic complications of COVID-19 are now well recognised.² A case of complete splenic infarction secondary to COVID-19 is presented. It highlights the need to maintain diagnostic vigilance and a high index of suspicion for significant thromboembolic disease in patients with COVID-19 infection.

CASE PRESENTATION

A 50-year-old man presented to the emergency department of a large teaching hospital in the UK with an acute exacerbation of epigastric pain during the COVID-19 pandemic. Fourteen days prior to admission, the patient had developed a dry cough and fever and had tested positive for SARS-CoV-2 RNA in the community. During self-isolation, he developed mild shortness of breath and anosmia. Twelve days into his illness, he developed mild epigastric pain associated with constipation.

On the morning of his admission, 14 days from index symptoms, he experienced an acute exacerbation of epigastric pain. On assessment in the emergency department, initial observations showed oxygen saturations of 96% on room air, heart rate of 95 beats per minute, blood pressure of 145/80 mm Hg, temperature 36.5°C and blood glucose of 8.1 mmol/L. His body mass index was 23.0 kg/m². He described epigastric and left hypochondrial pain radiating through to his back, which he scored as 10/10 on a subjective pain score. He had a persistent cough and mild shortness of breath, but no other respiratory symptoms. He had no significant medical history and took no regular medications. He was of South Asian origin, worked as an

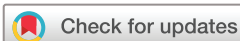engineer, and lived with his partner and children. He had never smoked cigarettes, drank alcohol occasionally and had no known drug allergies.

On examination, the patient appeared mildly uncomfortable at rest. He had dry mucous membranes and the clinical impression was one of dehydration. Respiratory effort and breath sounds were equal bilaterally with bilateral basal crackles on auscultation. Abdominal examination revealed a non-distended abdomen with mild epigastric and left hypochondrial tenderness but no peritonism or masses. Bowel sounds were present. The rest of the physical examination was normal. An ECG showed sinus tachycardia. Chest radiography revealed extensive bilateral pulmonary infiltrates in keeping with COVID-19 pneumonia (figure 1).

Intravenous opioid analgesia was administered in the emergency department and the patient was admitted to the medical admissions unit for further assessment and investigation. Admission blood tests (table 1) demonstrated a strong inflammatory response, lymphopenia and a D-dimer incalculable by the hospital's normal laboratory methods. After discussion with our radiology colleagues, a decision was made to undertake CT angiography of the chest and abdomen with contrast. This demonstrated near complete infarction of the splenic artery (figure 2) along with poor perfusion of lower pole of the right kidney, in keeping with a renal cortical infarct. There was significant bilateral peripheral ground glass opacification throughout both lungs in keeping with COVID-19 pneumonia (figure 3). After conversations with the hospital haematology laboratory technicians, a D-dimer result obtained by serial dilution of the sample sent was: 85 216 ng/mL.

A diagnosis of near complete splenic infarction secondary to known thrombotic complications of SARS-CoV-2 infection was made. A discussion with colleagues in both vascular and general surgery concluded that intervention was not indicated. Haematology advised commencing the patient on an unfractionated heparin infusion, which was commenced as per the local guideline.³ There was no requirement for dexamethasone because the patient did not have an oxygen requirement. The use of interleukin-6 (IL-6) receptor antagonists was not licenced at the time of the patient's presentation.

The patient was transferred to the medical high-dependency unit. He remained clinically stable, although the severe epigastric pain persisted. A transthoracic echocardiogram demonstrated a non-dilated left ventricle with good systolic function and no thrombus, a non-dilated right ventricle with mild dysfunction and no significant valvular



© BMJ Publishing Group Limited 2021. No commercial re-use. See rights and permissions. Published by BMJ.

To cite: Prentice G, Wilson S, Coupland A, *et al.* *BMJ Case Rep* 2021;**14**:e246274. doi:10.1136/bcr-2021-246274

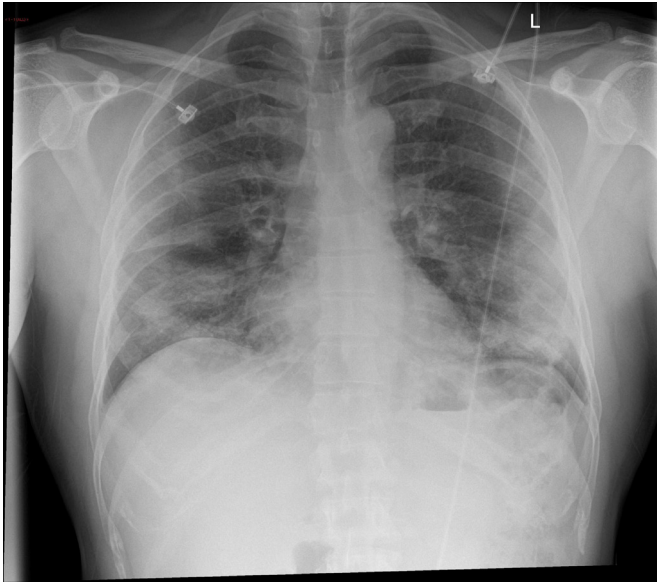


Figure 1 Posteroanterior chest radiograph on admission. Bilateral predominantly peripheral and basal pulmonary infiltrates in keeping with COVID-19 pneumonia.

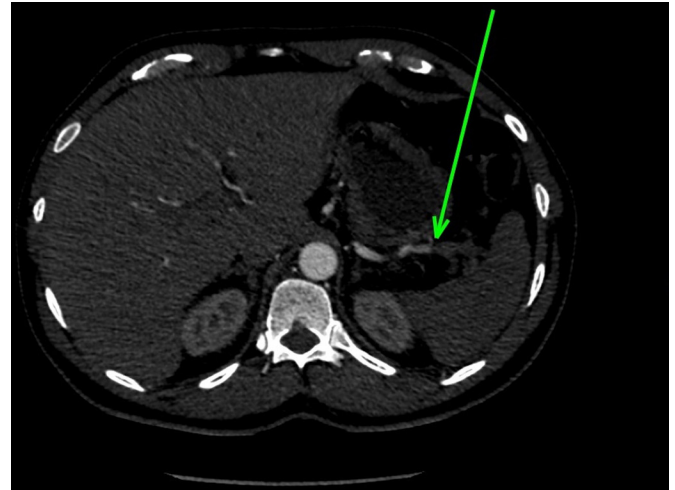


Figure 2 CT abdomen arterial phase imaging demonstrates thromboembolic material within the splenic artery (indicated by arrow) causing near complete splenic infarction.

dysfunction. After 48 hours of unfractionated heparin, anticoagulation was switched to twice daily subcutaneous enoxaparin injections dosed at 1 mg/kg. The patient stepped down to ward level care.

DIFFERENTIAL DIAGNOSIS

Initial differential diagnoses included pancreatitis, peptic perforation, myocardial infarction, gastritis, aortic dissection, pulmonary embolism, mesenteric ischaemia and bowel obstruction. Mild respiratory symptoms secondary to COVID-19 pneumonia did not correlate with elevated inflammatory markers. A non-distended abdomen and the predominantly epigastric and hypochondrial tenderness did not corroborate an obstruction. A normal serum amylase reduced the clinical suspicion of acute pancreatitis, and serial troponin-Is within the normal reference range excluded myocardial infarction. As a rare pathology, a diagnosis of splenic infarct had not initially been considered, however, an unspecified abdominal pathology secondary to COVID-19 given the severity of epigastric and hypochondrial pain was one of the primary indications for requesting the CT scan.

OUTCOME AND FOLLOW-UP

The patient's remaining hospital admission was complicated by ongoing abdominal pain, requiring significant doses of opiate analgesia. Genetic hypercoagulability screening was negative.

Table 1 Admission blood investigations

	Result on admission	Reference range	Unit
Na+	128	133–146	mmol/L
K+	3.9	3.3–5.3	mmol/L
Cl-	96	95–108	mmol/L
Urea	3.2	2.5–7.8	mmol/L
Creatinine	50	40–130	micromol/L
Estimated glomerular filtration rate	>60	>60	mL/min
Bicarbonate	20	22–29	mmol/L
Adjusted calcium	2.24	2.20–2.60	mmol/L
Phosphate	1.02	0.80–1.50	mmol/L
Magnesium	1.08	0.70–1.00	mmol/L
C-reactive protein	274	<10	mg/L
White cell count	10.9	4.0–10.0	$\times 10^9/L$
Haemoglobin	145	130–180	g/L
Mean cell volume	83.1	83.0–101.0	fl
Platelets	387	150–410	$\times 10^9/L$
Neutrophils	9.7	2.0–9.7	$\times 10^9/L$
Lymphocytes	0.6	1.1–5.0	$\times 10^9/L$
Bilirubin	11	<20	micromol/L
Alanine aminotransferase	37	<50	U/L
Aspartate aminotransferase	26	<40	U/L
Alkaline phosphatase	73	30–130	U/L
Albumin	24	35–50	g/L
Amylase	80	<100	U/L
Glucose	6.4	3.5–6.0	mmol/L
Troponin I	5	0–34	ng/L
Prothrombin time	16	9–13	Seconds
Activated partial thromboplastin time	31	27–36	Seconds
Thrombin time	11	11–15	Seconds
D-Dimer	Incalculable	<200	ng/mL
Ferritin	2610	15–300	$\mu\text{g/L}$

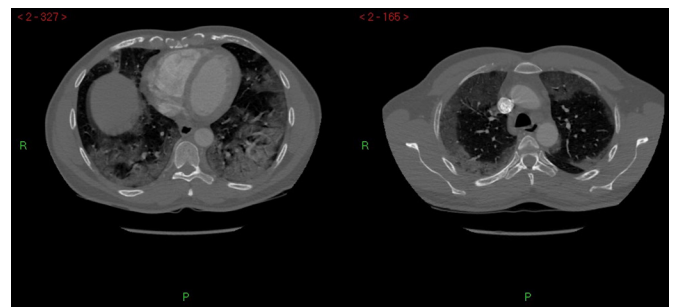


Figure 3 CT chest demonstrating bibasal and peripheral ground glass opacification and patchy more confluent consolidation in keeping with COVID-19 pneumonia.

Patient's perspective

Initial Illness

I had been working business as usual (as I provide an essential service) and felt perfectly well with no clue as to what was about to transpire. Later that evening I started to feel quite unwell. I felt feverish and tired, so I headed off to bed. The next morning, I developed a chesty sounding cough and assumed I was having a chest infection. I became more unwell as the day progressed and as it was a Sunday, I thought all that was needed was to contact my GP the following morning to obtain an antibiotic.

Day 3: GP recommended I book myself for a COVID-19 test as she felt that my symptoms may indicate COVID-19. I felt quite shocked by this news and immediately booked my test.

Day 4: My result was positive! At this stage I was already experiencing breathlessness along with the coughing, high temperature, and lethargy and was self-medicating with paracetamol.

Day 5: I then started to develop abdominal pain.

Day 6: All my symptoms were becoming more severe and so on this day I contacted NHS24 where I was advised to attend a COVID-19 clinic. The duty doctor checked my oxygen levels, temperature, blood pressure, and took some bloods. I was then given an ECG. At this point all the checks carried out were within acceptable limits, however I was advised that my vitamin D levels were low. I was advised to take the maximum dose paracetamol and daily vitamin D.

In the days following I was in constant pain along with the other ongoing symptoms. To add to my misery, I developed what felt like constipation which further affected my appetite and energy levels.

Day 10: and there is no improvement and in fact the abdominal pain was intensifying, my coughing was increased, and my breathing was deteriorating.

I called an ambulance. The paramedics carried out the vital checks. My oxygen levels at that point although below normal did not warrant hospital admission. Instead, I was advised to take paracetamol as COVID-19 usually lasts 2 to 3 weeks. Hoping for the best and with good faith, I followed the advice but sadly I continued to deteriorate. Due to the pain, weakness, and laboured breathing I could barely walk, speak or even lift my phone! I had also come to realise that I had lost my sense of smell and any food which I had managed to eat tasted bitter and so I had also stopped eating.

Early hours of Day 14 I raised the alarm. I had unbearable pain on the left side of my abdomen just below my rib cage. I could bear it no longer and the paramedics duly arrived. The journey by ambulance to hospital seemed to take forever.

After some tests and strong pain relief I had a long wait in A & E until I was admitted into the respiratory admissions ward. After a chest X-ray and CT scan, the respiratory consultant explained to me that my spleen was full of blood clots and that my blood was thickening. The lower column of my right kidney was also affected with clots, however, was functioning as it should be. I was advised that the treatment to remove the clots could be of some considerable discomfort. And that unfortunately, the damage caused to my spleen itself was untreatable. At this point I was afraid that I would not make it!

Plan of action

I was transferred to the High Dependency Unit where I was monitored very closely, I was put on oxygen, given steroids,

Continued

Patient's perspective Continued

morphine and paracetamol. I must comment that my treatment here was first class! I was referred to the medical registrar to have a line placed in my artery. After a few attempts, with my oxygen levels dropping, and in unbearable pain, the heparin infusion was commenced.

I had become very weak and fragile, had lost a significant amount of weight, I was drowsy, and struggling to speak and walk due to the severe pain and the effects of the medication.

2 days later I needed physical assistance to walk to the bathroom as I was so breathless and weak. I attempted to shower myself. I had a fear of becoming even more breathless and weak while in the shower. Halfway through I had to pull the chord for assistance, I was supported to sit and was given oxygen.

I was transferred from the HDU 3 days later to the ward, where the nursing staff continued to monitor, observe, and administer medication several times each day. I continued to be reviewed daily by doctors/consultants and it was there that nursing staff also taught me how to inject my own heparin. This was essential for me to be able to leave hospital.

My consultant attended and explained to me what would happen after discharge. And that he would be reviewing my case as an outpatient in 3 months' time. He made me aware that my case is very rare in terms of how COVID-19 has affected me.

One of the junior doctors also spoke to me about my unique case, asking me about my progress, and if I could recall my hospital admission day? He then reminded me what I was like in terms of my dazed expression, my comprehension and delayed response. He mentioned that my walking was very unstable and staggered and that I was gasping for breath.

I feel I owe a debt of gratitude to the nurses and doctors for their expertise, their caring attitude and dedication. I especially owe this to the staff of High Dependency Unit without whose help I feared I may no longer be here.

At the time of discharge, I was prescribed 2 weeks Heparin (for abdominal injection), morphine, penicillin, and paracetamol. I am pleased to say that the morphine has since been discontinued, and the abdominal injections have been replaced with tablet form. I have also had a follow-up chest x-ray, a pulmonary rehab assessment along with physio exercises. To protect my damaged spleen, I have also had a series of 3 vaccinations and my first COVID-19 vaccination.

I am currently back to my usual body weight however I still experience some adverse symptoms which I believe may be as a result of COVID-19. I have general body aches, pains, and stiffness which particularly affect my knees, ongoing tiredness, weakness and restless sleep with body twitching. I also find occasions where I have difficulty finding the correct words to express myself along with some forgetfulness. In due time I hope to recover and feel better and get back to work.

Renal function remained stable and the renal infarct observed was not deemed to be of clinical significance. Sixteen days after presentation to the emergency department he was medically fit for discharge. Twice daily subcutaneous enoxaparin injections continued for 4 weeks before switching to apixaban. Duration of treatment was reviewed 3 months after discharge and continued pending subsequent review.

Owing to the complete splenic infarction he was presumed to become functionally asplenic. Meningococcal and haemophilus

influenza vaccines were administered 2 weeks after the splenic injury and prophylactic lifelong penicillin V therapy was commenced. The patient received a COVID-19 vaccination 2 months after discharge. Discussion with radiology concluded that follow-up imaging was not indicated.

DISCUSSION

The link between COVID-19 infection and concurrent thromboembolic events is becoming increasingly well established, with a recent meta-analysis suggesting that they occur in 21% of hospitalised patients.² Arterial thromboembolism is significantly less common than venous, accounting for around one in ten of thromboembolic complications.² The pathophysiology underlying this is not fully understood, however it is hypothesised that the significant inflammatory response seen in COVID-19 creates a prothrombotic state.⁴ Fibrinogen and IL-6 levels have been seen to rise proportionally, indicating a link between COVID-19 and hypercoagulation.³ The cytokine storm seen in COVID-19 is thought to trigger activation of monocytes, neutrophils and endothelium, all contributing to a prothrombotic state.⁵ In the 'Recovery' trial, tocilizumab, a monoclonal antibody primarily used in the management of rheumatological disease, has been shown to reduce duration of critical care admission and mortality from COVID-19.⁶ Tocilizumab results in inhibition of the pro-inflammatory effects of IL-6 and is thought to decrease the effects of the cytokine storm.⁶

Furthermore, it is thought that COVID-19 may cause endothelial injury and dysfunction by direct viral effects as well as perivascular inflammation.⁷ COVID-19 is not the first virus to be implicated as a causative factor in splenic infarction, with cases also reported with Epstein-Barr virus, acute cytomegalovirus and parvovirus B19.⁸⁻¹⁰ The most common sites for arterial thrombosis in association with COVID-19 in retrospective cohort studies include ischaemic intracerebral strokes, aortoiliac, limb and mesenteric.¹¹ It is thought that splenic infarction secondary to COVID-19 is underdiagnosed given that abdominal imaging does not form part of the mainstay of investigation.¹²

Splenic infarction is a rare cause of abdominal pain. The annual incidence rate of splenic infarction is around 1 in 100 000 in the general population.¹³ An underlying haematological condition such as sickle cell disease, leukaemia, myelofibrosis or lymphoma, is seen to coexist in 10%–59% of cases reported in the literature.¹³⁻¹⁵ Other risk factors include cardiovascular disease, hypercoagulability, hypertension, diabetes mellitus and infection.¹⁵ The most commonly identified signs and symptoms are left upper quadrant pain and tenderness, fevers, and nausea and vomiting.¹⁵ Constipation is seen in just 6% of cases.¹⁵ The best imaging modality for diagnosing splenic infarct is contrast-enhanced CT.¹⁵

Splenic infarction secondary to COVID-19 has seldom been reported. A recent literature review by Ramanathan *et al* discussed the published case reports.¹⁶ This literature review had been prompted by a case of a male in his fifties with known COVID-19 pneumonia with no other significant past medical history, who had similarly presented with severe abdominal pain, nausea and vomiting, and subsequently diagnosed with a splenic and renal infarct.¹⁶ Seventeen cases of splenic and/or renal infarction were found, with the age range of patients between 46 and 72 and the mean period between COVID-19 diagnosis and identification of infarct being 17 days.¹⁶ Patients were managed for 3 weeks with low-molecular-weight heparin (LMWH) on average, and two patients commenced on Apixaban for 3 months on discharge from hospital.¹⁶

The haematology team based their recommendation for commencing unfractionated heparin on a case report presented by Qasim Agha *et al* from the USA.¹⁷ A man in his 60s with a background of morbid obesity, hypertension and asthma was admitted with dyspnoea for 2 weeks with associated fevers, cough and diarrhoea.¹⁸ He had been taking hydroxychloroquine prescribed in primary care for 1 week prior to admission, and was commenced on prophylactic LMWH on admission.¹⁷ On day 7 of admission, he developed moderate left sided abdominal pain requiring opioid analgesia, and a contrast-enhanced CT scan confirmed acute splenic artery thrombosis with infarction of greater than 50% of the splenic volume.¹⁷ His anticoagulation was switched from 40 mg two times a day of enoxaparin, to an unfractionated heparin infusion for 24 hours at diagnosis.¹⁷ His heparin was changed back to enoxaparin, but at a higher dose of 1 mg/kg two times a day daily, and after 3 weeks in hospital he was fit to be discharged on oral rivaroxaban.¹⁷

The most common pathogens posing risk to asplenic and hyposplenic patients are encapsulated bacteria, including *Streptococcus pneumoniae*, *Haemophilus influenzae B* and *Neisseria meningitidis*.^{18 19} Those at greatest risk of sepsis are children under the age of 16 and adults over the age of 50.⁷ As well as vaccination, penicillin V prophylaxis has been recommended since 1996 by the British Committee for Standards in Haematology, with the benefits of preventing overwhelming sepsis outweighing the perceived risk of antimicrobial resistance.¹⁸ Vigilance to animal and insect bites is also advocated due to their increased susceptibility to infection.¹⁸

Management of our patient was challenging. Part of the difficulty arose from a paucity of evidence to guide the management of patients with splenic infarcts. This was compounded by the novel COVID-19 aetiology. The extent of the infarction and resultant asplenia required consideration to ensure appropriate preventative measures were taken. Interestingly, the extremely high D-dimer result appears to be in keeping with other case reports of splenic infarction. Several of these studies have highlighted the need to further elucidate the link between D-dimer and splenic infarction.¹⁶

Learning points

- ▶ Splenic infarction is a rare cause of abdominal pain, but should be considered as a differential diagnosis.
- ▶ As COVID-19 is a novel disease, all suspected COVID-19 patients should be assessed with an open mind for possible complications.
- ▶ Thromboembolic complications occur in around one-fifth of hospitalised patients with COVID-19.

Contributors Supervised by SB. Patient was under the care of SB. Report was written by GP, SW and AC.

Funding The authors have not declared a specific grant for this research from any funding agency in the public, commercial or not-for-profit sectors.

Competing interests None declared.

Patient consent for publication Consent obtained directly from patient(s).

Provenance and peer review Not commissioned; externally peer reviewed.

This article is made freely available for use in accordance with BMJ's website terms and conditions for the duration of the covid-19 pandemic or until otherwise determined by BMJ. You may use, download and print the article for any lawful, non-commercial purpose (including text and data mining) provided that all copyright notices and trade marks are retained.

Case reports provide a valuable learning resource for the scientific community and can indicate areas of interest for future research. They should not be used in isolation to guide treatment choices or public health policy.

REFERENCES

- Grant MC, Geoghegan L, Arbyn M, *et al*. The prevalence of symptoms in 24,410 adults infected by the novel coronavirus (SARS-CoV-2; COVID-19): a systematic review and meta-analysis of 148 studies from 9 countries. *PLoS One* 2020;15:e0234765. doi:10.1371/journal.pone.0234765
- Malas MB, Naazie IN, Elsayed N, *et al*. Thromboembolism risk of COVID-19 is high and associated with a higher risk of mortality: a systematic review and meta-analysis. *EClinicalMedicine* 2020;29:100639–30.
- et al Bagot C, Miles B, Chalmers G. Prevention of thrombosis in COVID-19 +ve adult inpatients (pregnant and non-pregnant) undergoing renal replacement therapy (RRT) on critical care wards. NHS greater Glasgow and Clyde Staffnet. Available: http://www.staffnet.ggc.scot.nhs.uk/Acute/Surgery%20Anaesthetics/Critical%20Care/QEUIH_CCU/Documents/Thrombosis%20prevention%20for%20RRT%20patients%20in%20critical%20care%20Covid-19%20GGC%2016.04.20.pdf [Accessed 17 Feb 2021].
- Marietta M, Coluccio V, Luppi M. COVID-19, coagulopathy and venous thromboembolism: more questions than answers. *Intern Emerg Med* 2020;15:1375–87.
- Abou-Ismaïl MY, Diamond A, Kapoor S, *et al*. The hypercoagulable state in COVID-19: incidence, pathophysiology, and management. *Thromb Res* 2020;194:101–15.
- Horby PW, Campbell M, Staplin N, *et al*. Tocilizumab in patients admitted to hospital with COVID-19 (recovery): a randomised, controlled, open-label, platform trial. *Lancet* 2021;397:1637–45.
- Ackermann M, Verleden SE, Kuehnel M, *et al*. Pulmonary vascular Endothelialitis, thrombosis, and angiogenesis in Covid-19. *N Engl J Med* 2020;383:120–8.
- Machado C, Melo Salgado J, Monjardino L. The unexpected finding of a splenic infarction in a patient with infectious mononucleosis due to Epstein-Barr virus. *BMJ Case Rep* 2015;2015:bcr201512428.
- Harada T, Sueda Y, Okada K, *et al*. Splenic infarction in acute cytomegalovirus and human parvovirus concomitant infection. *Case Rep Infect Dis* 2018;2018:1–5.
- Kranidiotis G, Efstratiadis E, Kapsalakis G, *et al*. Splenic infarcts as a rare manifestation of parvovirus B19 infection. *IDCases* 2016;4:62–4.
- Levolger S, Bokkers RPH, Wille J, *et al*. Arterial thrombotic complications in COVID-19 patients. *J Vasc Surg Cases and Innovative Techniques* 2020;6:454–9.
- Santos Leite Pessoa M, Franco Costa Lima C, Farias Pimentel AC, *et al*. Multisystemic infarctions in COVID-19: focus on the spleen. *Eur J Case Rep Intern Med* 2020;7:001747.
- Pak S, Askaroglu AS Y. Splenic infarct presenting as acute chest pain. *Vascul Dis Ther* 2017;2:1–2.
- Ozakin E, Cetinkaya O, Baloglu Kaya F, *et al*. A rare cause of acute abdominal pain: splenic infarct (case series). *Turk J Emerg Med* 2015;15:96–9.
- Antopolsky M, Hiller N, Salameh S, *et al*. Splenic infarction: 10 years of experience. *Am J Emerg Med* 2009;27:262–5.
- Ramanathan M, Chueng T, Fernandez E, *et al*. Concomitant renal and splenic infarction as a complication of COVID-19: a case report and literature review. *Infez Med* 2020;28:611–5.
- Qasim Agha O, Berryman R. Acute splenic artery thrombosis and infarction associated with COVID-19 disease. *Case Rep Crit Care* 2020;2020:8880143.
- Davies JM, Lewis MPN, Wimperis J, *et al*. Review of guidelines for the prevention and treatment of infection in patients with an absent or dysfunctional spleen: prepared on behalf of the British Committee for standards in haematology by a working Party of the Haemato-Oncology Task force. *Br J Haematol* 2011;155:308–17.
- Bonanni P, Grazzini M, Nicolai G, *et al*. Recommended vaccinations for asplenic and hyposplenic adult patients. *Hum Vaccin Immunother* 2017;13:359–68.

Copyright 2021 BMJ Publishing Group. All rights reserved. For permission to reuse any of this content visit <https://www.bmj.com/company/products-services/rights-and-licensing/permissions/>
BMJ Case Report Fellows may re-use this article for personal use and teaching without any further permission.

Become a Fellow of BMJ Case Reports today and you can:

- ▶ Submit as many cases as you like
- ▶ Enjoy fast sympathetic peer review and rapid publication of accepted articles
- ▶ Access all the published articles
- ▶ Re-use any of the published material for personal use and teaching without further permission

Customer Service

If you have any further queries about your subscription, please contact our customer services team on +44 (0) 207111 1105 or via email at support@bmj.com.

Visit casereports.bmj.com for more articles like this and to become a Fellow