

# Anomalous Origin of Coronary Arteries Arising from the Right Coronary Cusp: A Rare Presentation

Rizwan Ali <sup>1</sup>, Arooj Tahir <sup>1</sup>, Mohammed I. Shakhathreh <sup>1</sup>, Kanna V. Posina <sup>2</sup>

1. Internal Medicine, Rapides Regional Hospital, Alexandria, La 2. Cardiology, Rapides Regional Hospital, Alexandria, La

✉ **Corresponding author:** Rizwan Ali, rizwan\_ali1113@yahoo.com

Disclosures can be found in Additional Information at the end of the article

---

## Abstract

The anomalous origin of coronaries is rare. The purpose of this case report is to show a rare anomalous origin of coronaries.

A 64-year-old female presented with chest pain that was typical in nature. The patient had left heart catheterization that showed an anomalous origin of coronaries, where all the coronaries were arising from the right coronary cusp. The patient had a significant disease in the distal left anterior descending artery, but it was a small vessel. Medical management was chosen.

This is a rare presentation of the coronary anatomy.

---

**Categories:** Cardiology, Internal Medicine

**Keywords:** coronary anatomy, chest pain, anomalous coronary artery

## Introduction

The anomalous origin of coronaries is rare [1]. According to the literature, coronary artery anomalies (CAAs) affect around 1% of the general population, ranging from 0.3%-5.6% in studies on patients undergoing coronary angiography and in approximately 1% of routine autopsies. The most common CAA is the separate origin of the left anterior descending (LAD) artery and the left circumflex (LCX) artery, with an incidence of 0.41%, followed by LCX arising from the right coronary artery (RCA), with an incidence of 0.37% [2-6].

## Case Presentation

A 64-year-old African American female with a past medical history of insulin-dependent diabetes mellitus, hypertension, hyperlipidemia, prior history of stroke, hypothyroidism, and family history of coronary artery disease presented to the emergency department with complaints of typical chest pain. The patient's chest pain was associated with nausea and vomiting. The physical examination and initial electrocardiogram were unremarkable. Cardiac enzymes were negative. The patient was started on aspirin, statin, and nitroglycerin. Cardiology was consulted and they decided to do left heart catheterization through right radial access and an echocardiogram, as the patient was having unstable angina. The echocardiogram showed a normal ejection fraction with no wall motion abnormalities.

Left heart catheterization showed anomalous coronaries, with all three coronaries arising from

Received 04/18/2018

Review began 04/19/2018

Review ended 04/22/2018

Published 04/25/2018

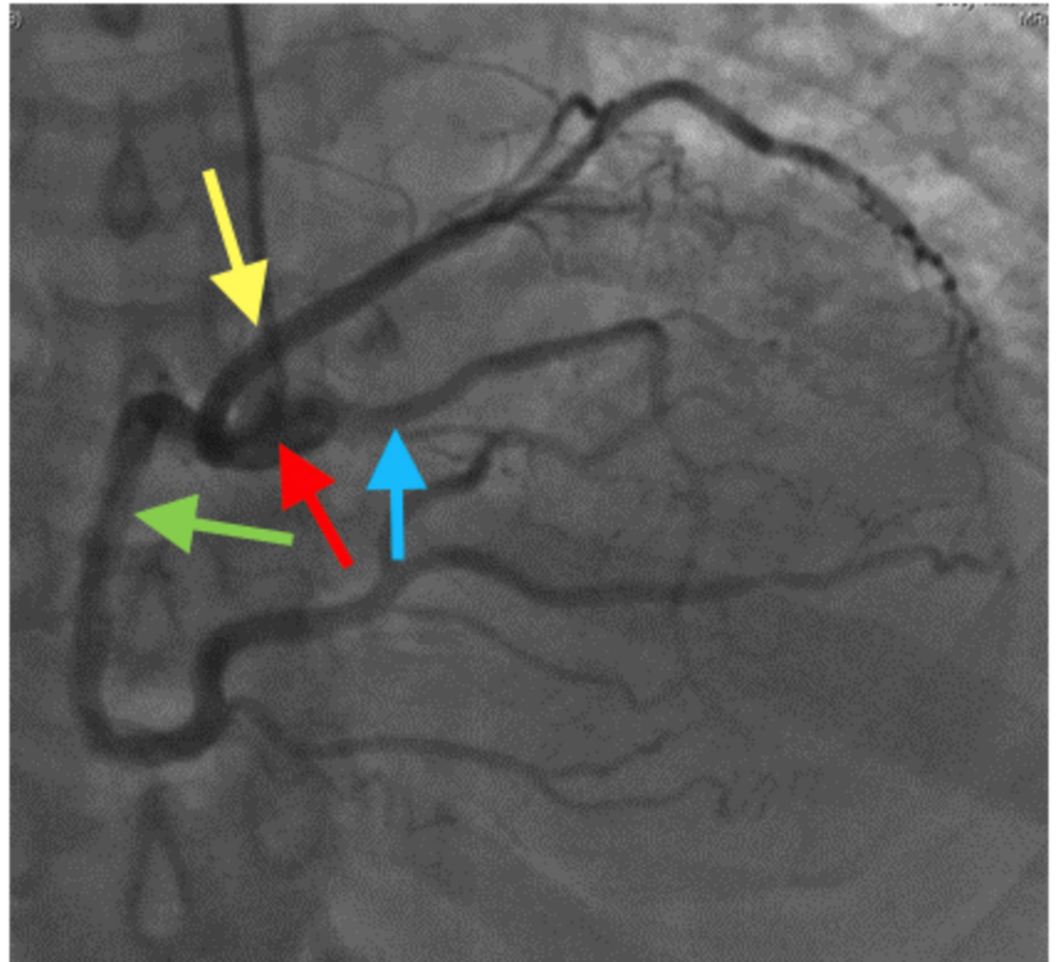
© Copyright 2018

Ali et al. This is an open access article distributed under the terms of the Creative Commons Attribution License CC-BY 3.0., which permits unrestricted use, distribution, and reproduction in any medium, provided the original author and source are credited.

### How to cite this article

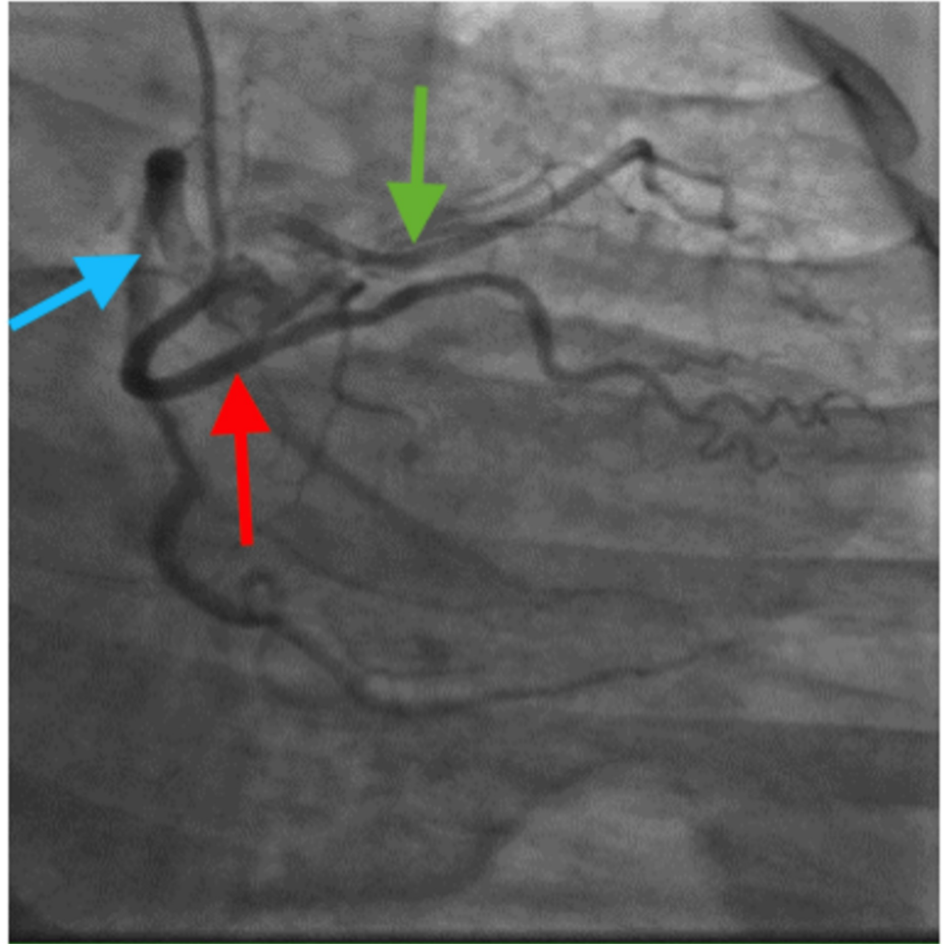
Ali R, Tahir A, Shakhathreh M I, et al. (April 25, 2018) Anomalous Origin of Coronary Arteries Arising from the Right Coronary Cusp: A Rare Presentation. Cureus 10(4): e2535. DOI 10.7759/cureus.2535

the right coronary cusp with a separate ostium, as shown in Figures 1-2.



**FIGURE 1: Left heart catheterization showing anomalous coronaries, with all three coronaries arising from the right coronary cusp with separate ostia.**

Yellow arrow: left circumflex artery; green arrow: right coronary artery; blue arrow: left anterior descending artery; red arrow: right coronary cusp



**FIGURE 2: Another view of anomalous coronaries. Distal left anterior descending has a significant disease.**

Red arrow: left circumflex artery; blue arrow: right coronary artery; green arrow: left anterior descending artery

The left anterior descending artery (LAD) had an anomalous origin with a separate ostium from the right coronary cusp. There was focal moderate to severe 70%-80% disease in the mid vessel. The LAD was a small vessel. The left circumflex artery had an anomalous origin with a separate ostium from the right coronary cusp. Mild luminal irregularities were present. The right coronary artery was a large dominant vessel with mild luminal irregularities. It was decided to treat the patient with medical management.

## Discussion

This was a very rare presentation of a coronary anatomy. However, our patient did not have any problem with the anomalous origin of her coronaries. We think this type of anomaly is benign. However, the origin of the coronary artery arising from the innominate artery can be the cause of syncope [7] or chest pain in adults [8-9]. The origin of the right coronary artery from the descending thoracic aorta may be associated with atypical and striking elastotic changes and the thickening of the wall of the coronary artery as the underlying pathogenesis of severe

consequences [10]. Circulatory symptoms may also be derived from the ectopic coronary arterial course between the pulmonary trunk and the aorta in spite of the lack of atherosclerotic plaques in the coronary artery [11]. The anomalous origin of the coronary artery can be associated with a common congenital heart defect [12] or with rare congenital heart defect like the cervical aortic arch [13]. The anomalous origin of the coronary artery can sometimes be associated with acquired heart disease, including coronary artery disease or heart valve disorders. Sudden death [14-15] and exercise-related death [16] are most common with the anomalous origin of the left main from the right coronary sinus. The anomalous origin of the right coronary artery from the left coronary sinus is also frequently associated with exercise-related sudden death. The high-risk anatomies responsible for sudden death are a coronary artery segment coursing between the pulmonary artery and the aorta [17], an acute angle take-off of the left coronary artery [18], and ostial abnormalities, including an ostial valve-like ridge [19], a slit-like orifice, and a flute beak-shaped ostium. The management of the anomalous origin of the coronary artery remains controversial. Surgical treatment is a definitive therapy that is recommended even for asymptomatic high-risk patients.

## Conclusions

A non-dominant coronary artery disease can be managed with medical management. However, the origin of the coronary artery arising from the innominate artery can be the cause of different symptoms, even sudden death. The high-risk anatomies responsible for sudden death are a coronary artery segment coursing between the pulmonary artery and the aorta, an acute angle take-off of the left coronary artery, and ostial abnormalities, including an ostial valve-like ridge, a slit-like orifice, and a flute beak-shaped ostium. The management of the anomalous origin of the coronary artery remains controversial. Surgical treatment is a definitive therapy that is recommended even for asymptomatic high-risk patients.

## Additional Information

### Disclosures

**Human subjects:** Consent was obtained by all participants in this study. **Conflicts of interest:** In compliance with the ICMJE uniform disclosure form, all authors declare the following:

**Payment/services info:** All authors have declared that no financial support was received from any organization for the submitted work. **Financial relationships:** All authors have declared that they have no financial relationships at present or within the previous three years with any organizations that might have an interest in the submitted work. **Other relationships:** All authors have declared that there are no other relationships or activities that could appear to have influenced the submitted work.

## References

1. Wesselhoeft H, Fawcett JS, Johnson AL: Anomalous origin of left coronary artery from the pulmonary trunk. Its clinical spectrum, pathology and pathophysiology based on a review of 140 cases with seven further cases. *Circulation*. 1968, 38:403-425. [10.1161/01.CIR.38.2.403](#)
2. Young PM, Gerber TC, Williamson EE, Julsrud PR, Herfkens RJ: Cardiac imaging: part 2, normal, variant, and anomalous configurations of the coronary vasculature. *AJR Am J Roentgenol*. 2011, 197:816-826. [10.2214/AJR.10.7249](#)
3. Angelini P, Velasco JA, Flamm S: Coronary anomalies: incidence, pathophysiology, and clinical relevance. *Circulation*. 2002, 105:2449-2454. [10.1161/01.CIR.0000016175.49835.57](#)
4. Yamanaka O, Hobbs RE: Coronary artery anomalies in 126,595 patients undergoing coronary arteriography. *Cathet Cardiovasc Diagn*. 1990, 21:28-40. [10.1002/ccd.1810210110](#)
5. Yurtdaş M, Gülen O: Anomalous origin of the right coronary artery from the left anterior descending artery: review of the literature. *Cardiol J*. 2012, 19:122-129.
6. Alexander RW, Griffith GC: Anomalies of the coronary arteries and their clinical significance. *Circulation*. 1956, 14:800-805. [10.1161/01.CIR.14.5.800](#)

7. Santucci PA, Bredikis AJ, Kavinsky CJ, Klein LW: Congenital origin of the left main coronary artery from the innominate artery in a 37-year-old man with syncope and right ventricular dysplasia. *Catheter Cardiovasc Interv*. 2001, 52:378-381. [10.1002/ccd.1086](https://doi.org/10.1002/ccd.1086)
8. Duran NE, Duran I, Aykan AC: Congenital anomalous origin of the left main coronary artery from the innominate artery in a 73-year-old woman. *Can J Cardiol*. 2008, 24:e108.
9. Kim YM, Choi RK, Lee CK: Anomalous origin of left coronary artery from innominate artery. *J Am Coll Cardiol*. 2009, 54:176. [10.1016/j.jacc.2009.02.070](https://doi.org/10.1016/j.jacc.2009.02.070)
10. Cheatham JP, Ruyle NA, McManus BM, Gammel GE: Origin of the right coronary artery from the descending thoracic aorta: angiographic diagnosis and unique coronary artery anatomy at autopsy. *Cathet Cardiovasc Diagn*. 1987, 13:321-324. [10.1002/ccd.1810130508](https://doi.org/10.1002/ccd.1810130508)
11. Mahajan D, Agnihotri G, Brar R: Anomalous origin of right coronary artery: an anatomico-clinical perspective of 2 cases. *Acta Inform Med*. 2012, 20:56-57. [10.5455/aim.2012.20.56-57](https://doi.org/10.5455/aim.2012.20.56-57)
12. McMahan CJ, DiBardino DJ, Ündar A, Fraser Jr CD: Anomalous origin of left coronary artery from the right pulmonary artery in association with type III aortopulmonary window and interrupted aortic arch. *Ann Thorac Surg*. 2002, 74:919-921. [10.1016/S0003-4975\(02\)03794-3](https://doi.org/10.1016/S0003-4975(02)03794-3)
13. Charrot F, Tarmiz A, Glock Y, Léobon B: Diagnosis and surgical treatment of an aneurysm on a cervical aortic arch associated with an anomalous origin of the left main coronary artery. *Interact Cardiovasc Thorac Surg*. 2010, 10:346-347. [10.1510/icvts.2009.219352](https://doi.org/10.1510/icvts.2009.219352)
14. Robicsek F: Origin of the left anterior descending coronary artery from the left mammary artery. *Am Heart J*. 1984, 108:1377-1378.
15. Corrado D, Basso C, Pavei A, Michieli P, Schiavon M, Thiene G: Trends in sudden cardiovascular death in young competitive athletes after implementation of a preparticipation screening program. *JAMA*. 2006, 296:1593-1601. [10.1001/jama.296.13.1593](https://doi.org/10.1001/jama.296.13.1593)
16. Click RL, Holmes DR Jr, Vlietstra RE, Kosinski AS, Kronmal RA: Anomalous coronary arteries: location, degree of atherosclerosis and effect on survival: a report from the Coronary Artery Surgery Study. *J Am Coll Cardiol*. 1989, 13:531-537. [10.1016/0735-1097\(89\)90588-3](https://doi.org/10.1016/0735-1097(89)90588-3)
17. Taylor AJ, Rogan KM, Virmani R: Sudden cardiac death associated with isolated congenital coronary artery anomalies. *J Am Coll Cardiol*. 1992, 20:640-647. [10.1016/0735-1097\(92\)90019-J](https://doi.org/10.1016/0735-1097(92)90019-J)
18. Catanzaro JN, Makaryus AN, Catanese C: Sudden cardiac death associated with an extremely rare coronary anomaly of the left and right coronary arteries arising exclusively from the posterior (noncoronary) sinus of Valsalva. *Clin Cardiol*. 2005, 28:542-544. [10.1002/clc.4960281111](https://doi.org/10.1002/clc.4960281111)
19. Virmani R, Chun PK, Goldstein RE, Robinowitz M, Mcallister HA: Acute takeoffs of the coronary arteries along the aortic wall and congenital coronary ostial valve-like ridges: association with sudden death. *J Am Coll Cardiol*. 1984, 3:766-771. [10.1016/S0735-1097\(84\)80253-3](https://doi.org/10.1016/S0735-1097(84)80253-3)