



ELSEVIER

Contents lists available at [ScienceDirect](https://www.sciencedirect.com)

Respiratory Medicine Case Reports

journal homepage: www.elsevier.com/locate/rmcr

Antineutrophil cytoplasmic antibody-negative granulomatosis with polyangiitis localized to the lungs

Yuichi Ohteru^a, Kazuki Hamada^{a,*}, Keiji Oishi^b, Junki Suizu^a, Misa Harada^a, Keita Murakawa^a, Ayumi Chikumoto^a, Kazuki Matsuda^a, Sho Uehara^a, Shuichiro Ohata^a, Yoriyuki Murata^b, Yoshikazu Yamaji^a, Kenji Sakamoto^a, Maki Asami-Noyama^a, Nobutaka Edakuni^a, Tsunahiko Hirano^a, Tomoyuki Kakugawa^c, Tomoyuki Murakami^d, Tamiko Takemura^e, Kazuto Matsunaga^a

^a Department of Respiratory Medicine and Infectious Disease, Graduate School of Medicine, Yamaguchi University, Japan

^b Department of Medicine and Clinical Science, Graduate School of Medicine, Yamaguchi University, Japan

^c Department of Pulmonary and Gerontology, Graduate School of Medicine, Yamaguchi University, Japan

^d Department of Pathology, National Hospital Organization Kannon Medical Center, Japan

^e Department of Pathology, Kanagawa Cardiovascular and Respiratory Center, Japan

ARTICLE INFO

Keywords:

Localized granulomatosis with polyangiitis
Antineutrophil cytoplasmic antibody
Non-life-threatening disease
Granuloma of unknown cause

ABSTRACT

Patients with granulomatosis with polyangiitis (GPA), formerly known as Wegener's granulomatosis, sometimes exhibit no clinical features. Here, we describe a case of antineutrophil cytoplasmic antibody (ANCA)-negative GPA presenting with only lung granuloma. A 55-year-old woman with a right upper lung mass underwent lobectomy for suspected lung cancer; however, only granuloma was detected, and the etiology was not identified. Serum ANCA results were negative. Four years postoperatively, another pulmonary nodule appeared in the left lung's apex. The kidneys and sinuses were not impaired, but re-examination of the resected specimen revealed necrotizing vasculitis and granulomas around the vessels. Thus, the patient was diagnosed with GPA localized to the lungs. Although this was a non-life-threatening disease, the patient was administered oral prednisolone (PSL) and intravenous cyclophosphamide (IVCY) to prevent fatal complications of GPA as she was non-elderly and had no comorbidities, leading to a decrease in the mass size. Detailed re-examination by expert pulmonary pathologists could aid in GPA diagnosis when clinical features are absent, as in our case. In patients with granulomas of unknown etiology, a careful multidisciplinary approach is pivotal in the diagnosis. If patients tolerate adverse effects, a PSL and IVCY combination may prevent fatal outcomes, even in patients with non-life-threatening disease.

Abbreviations

ANCA Antineutrophil cytoplasmic antibody

* Corresponding author. Department of Respiratory Medicine and Infectious Disease, Graduate School of Medicine, Yamaguchi University, 1-1-1 Minami-kogushi, Ube, Yamaguchi, 755-8505, Japan.

E-mail address: khamada@yamaguchi-u.ac.jp (K. Hamada).

<https://doi.org/10.1016/j.rmcr.2022.101600>

Received 30 March 2021; Received in revised form 30 December 2021; Accepted 31 January 2022

Available online 2 February 2022

2213-0071/© 2022 Published by Elsevier Ltd. This is an open access article under the CC BY-NC-ND license

(<http://creativecommons.org/licenses/by-nc-nd/4.0/>).

CYC	Cyclophosphamide
CT	Computed tomography
GPA	Granulomatosis with polyangiitis
IVCY	Intravenous cyclophosphamide
MPO-ANCA	myeloperoxidase-ANCA
PR3-ANCA	proteinase 3-ANCA
PSL:	Prednisolone

1. Introduction

Granulomatosis with polyangiitis (GPA), formerly known as Wegener's granulomatosis, is an antineutrophil cytoplasmic antibody (ANCA)-associated vasculitis, characterized by necrotizing vasculitis of small- and medium-sized vessels and perivascular granulomatosis [1,2]. In GPA, the upper and lower respiratory tracts and kidneys are commonly impaired. ANCA is a hallmark of GPA and provides diagnostic information for GPA [3]. Approximately 90% of GPA patients are ANCA-positive [4]. Moreover, ANCA serology results are more likely to be negative, especially in localized GPA, which is defined as restricted to the respiratory tract with no signs of systemic vasculitis [5]. Manifestations of GPA vary between patients, and some can be non-specific. The absence of the clinical features of GPA makes diagnosis challenging [6–8].

We describe a case of ANCA-negative GPA presenting only with lung granuloma, in which detailed re-examination by pulmonary pathologists led to the diagnosis of GPA. To prevent fatal complications, the patient was treated with a combination of prednisolone (PSL) and intravenous cyclophosphamide (IVCY) despite the disease being non-organ- and non-life-threatening.

2. Case presentation

A 55-year-old woman had undergone chest radiography for a comprehensive medical examination four years prior to reporting to our hospital, and a mass lesion was detected. Chest computed tomography (CT) revealed a mass lesion measuring 50 mm diameter in the apical portion of the right lung (Fig. 1A). Video-assisted thoracoscopic right upper lobectomy was performed for the suspected lung cancer. The surgical specimen revealed granulomatous lesions with inflammatory cell infiltration, but no evidence of malignancy, and a definitive diagnosis was not attained. Four years postoperatively, another nodule of 20 mm diameter appeared in the apical portion of the left lung (Fig. 1B), and she was referred to our hospital for the examination of this unknown mass.

This patient had no history of smoking, and no abnormal findings were observed on physical examination. She did not present symptoms of vasculitis, including fever, loss of appetite, weight loss, and fatigue. Laboratory data are shown in Table 1. Blood tests revealed that leukocyte and C-reactive protein levels were not elevated. Serum creatinine and blood urea nitrogen levels were within the normal range, and urinalysis results were normal. Tumor markers, β -D glucan, and fungal antigens, including those for *Cryptococcus neoformans* (latex agglutination test) and *Aspergillus* spp. (enzyme-linked immunosorbent assay), were negative. Interferon-gamma release assay and soluble interleukin-2 receptor levels were within the respective normal ranges. Both myeloperoxidase-ANCA (MPO-ANCA) and proteinase 3-ANCA (PR3-ANCA) (antigen specific assay) were negative. Human leukocyte elastase ANCA was not measured. Transbronchial lung biopsy was performed from another nodule in the apical portion of the left lung. However, no conclusive findings were observed, which prompted a re-examination of the previously obtained right lung surgical specimen. Detailed pathological examination of the surgical specimen by pulmonary pathologists revealed poorly formed granulomas with geographic and basophilic necrosis (Fig. 2A), the periphery of which contained palisaded epithelioid histiocytes (Fig. 2B). Moreover, small vessel vasculitis (Fig. 2C) and collagen fiber necrosis (Fig. 2D) were observed at the edge of the necrotic tissue. These lesions were accompanied by a mixed inflammatory infiltrate consisting of neutrophils, lymphocytes, plasma cells, macrophages, giant cells, and eosinophils. Tissue culture results for acid-fast bacilli were negative. Based on these pathological findings, the patient was diagnosed

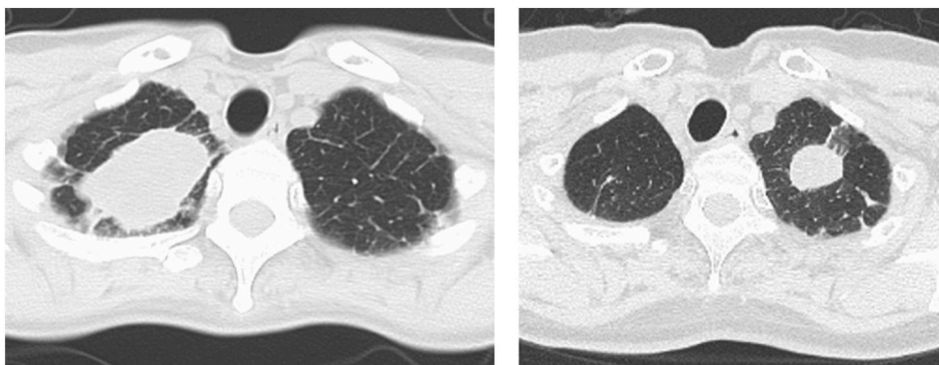


Fig. 1. (A) Chest computed tomography (CT) revealed a mass lesion of 50 mm in the apical portion of the right lung. (B) Four years after the lobectomy, another nodule of 20 mm appeared in the apical portion of the left lung.

with GPA.

Despite the localized GPA being non-life-threatening, she was treated with IVCY pulse therapy (15 mg/kg/time) every four weeks and daily oral PSL (started at 0.6 mg/kg) to prevent fatal outcomes. After the initiation of immunosuppressive therapy, the mass in the apical portion of the left lung substantially decreased (Fig. 3). IVCY was administered four times, and PSL was gradually reduced every four weeks. Subsequently, the mass almost disappeared, and no recurrence has been observed for three years and eight months after the initial treatment.

3. Discussion

Herein, we discuss two important clinical issues with regard to this case. A detailed revision of the lung specimen by expert pulmonary pathologists confirmed the diagnosis of localized GPA. This patient was treated with a combination of PSL and IVCY to prevent fatal outcomes, although the disease was non-organ and non-life-threatening.

First, in this case, the ANCA negative, localized GPA was not diagnosed initially, but a detailed revision of the specimen led to the diagnosis. In previous cases, as in our case, the first pathological examination has not been conclusive, but detailed re-examination of the specimen have revealed pathologic findings specific to GPA [9,10]. The pulmonary pathologic features of GPA vary in each case, and typical pathological findings are sometimes absent, making it difficult to diagnose [11]. If clinical features of GPA are absent, as in the present case, detailed revision of the specimen by an expert pulmonary pathologist may be key to the diagnosis of GPA.

Regarding the absence of clinical features of GPA in this case, negative for both MPO-ANCA and PR3-ANCA is to be debated. In patients with localized GPA (restriction to the respiratory tract), both MPO-ANCA and PR3-ANCA are less positive, whereas PR3-ANCA is often positive in limited GPA (absence of renal lesion but several organs impaired) [12]. In cases of both MPO-ANCA and PR3-ANCA negative, some patients show test positive for elastase-ANCA [13]. However, we did not measure elastase-ANCA as elastase-ANCA is rarely positive (less than 1% of GPA cases) and pathological diagnosis of GPA was eventually confirmed in our case.

Moreover, the present patient presented with only lung granuloma of “unknown” etiology. Granuloma alone is a non-specific finding, and the differential diagnoses of granulomatous lung diseases are remarkably variable (e.g., mycobacteria, fungi, sarcoidosis, hypersensitivity pneumonitis, hot tub lung, berylliosis, rheumatoid nodules, eosinophilic granulomatosis with polyangiitis and GPA) [14]. In cases with granuloma of “unknown” etiology, GPA may be a differential diagnosis, and a careful multidisciplinary approach would be pivotal for a definitive diagnosis.

Second, the patient was administered PSL and IVCY, although the disease was non-life-threatening, which is categorized by the absence of any evidence of active glomerulonephritis and organ-threatening or life-threatening manifestations. In non-life-threatening disease, the European League Against Rheumatism recommends treatment with corticosteroids combined with methotrexate or mycophenolate mofetil rather than IVCY [15]. Nonetheless, this patient was treated with a combination therapy of PSL and IVCY for following two reasons.

The first reason is that even GPA that is “non-life-threatening” at the time of diagnosis can be as fatal as generalized GPA. Fatal diffuse alveolar hemorrhage has reportedly occurred in patients with lung-localized GPA who initially showed only a solitary nodule and no evidence of extra-pulmonary involvement [18]. Another study described a GPA patients who initially presented with only solitary mediastinal mass but progressed to rapidly progressive glomerulonephritis [19]. Thus, fatal outcomes are sometimes unpredictable, and may require more intensive immunosuppressive therapy in some cases to prevent fatal events.

The second reason is that localized GPA may simply be the early stage in the clinical course of the disease. Although it is well known that GPA can show initially indolent course [16,17], localized and non-life-threatening GPA can relapse and extend to generalized GPA despite a combination of immunosuppressants. A prospective, long-term, observational study demonstrated that 10% of patients with localized GPA progressed to the systemic form and 46% had relapse even after immunosuppressant therapy [5]. The Nonrenal Wegener’s Granulomatosis Treated Alternatively with Methotrexate trial demonstrated that the relapse rate at 18 months was significantly higher with methotrexate than with cyclophosphamide (CYC) (70% in the methotrexate group and 47% in the oral CYC group, respectively), indicating that CYC may be superior to methotrexate in terms of preventing generalized GPA and fatal

Table 1
Laboratory data.

Blood test						Urinalysis				
WBC	5540	/μl	ALT	12	U/l	IgG	1635	mg/dl	Protein	(-)
Neut	65.7	%	BUN	15	mg/dl	IgA	330	mg/dl	Glucose	(-)
Lym	24.5	%	Cre	0.62	mg/dl	IgM	124	mg/dl	Ketone	(-)
Eos	4.9	%	Na	143	mEq/l	Total IgE	44	mg/dl	Blood	(-)
Baso	0.4	%	K	4.0	mEq/l	Cryptococcus Ag	(-)		WBC	(-)
Mono	4.5	%	Cl	109	mEq/l	Aspergillus Ag	(-)			
RBC	461 × 10 ⁴	/μl	CRP	0.05	mg/dl	sIL-2R	285	U/ml		
Hb	13.5	g/dl	CEA	0.7	ng/ml	PR3-ANCA	<1.0	U/ml		
Plt	16.9 × 10 ⁴	/μl	SCC	1.1	ng/ml	MPO-ANCA	<1.0	U/ml		
Alb	4.4	g/dl	ProGRP	54.9	pg/ml					
LDH	185	U/l	β-D glucan	2.2	pg/ml					
AST	16	U/l	IGRA	(-)						

Abbreviations: WBC, white blood cell; Neut, neutrophil; Lym, lymphocyte; Eos, eosinophil; Baso, basophil; Mono, monocyte; RBC, red blood cell; Hb, hemoglobin; Plt, platelet; Alb, albumin; Cre, creatinine; CRP, C-reactive protein; Ig, immunoglobulin; Ag, antigen; IGRA, interferon-gamma release assay; sIL-2R, soluble interleukin-2 receptor; PR3-ANCA, proteinase 3-ANCA; MPO-ANCA, myeloperoxidase-ANCA.

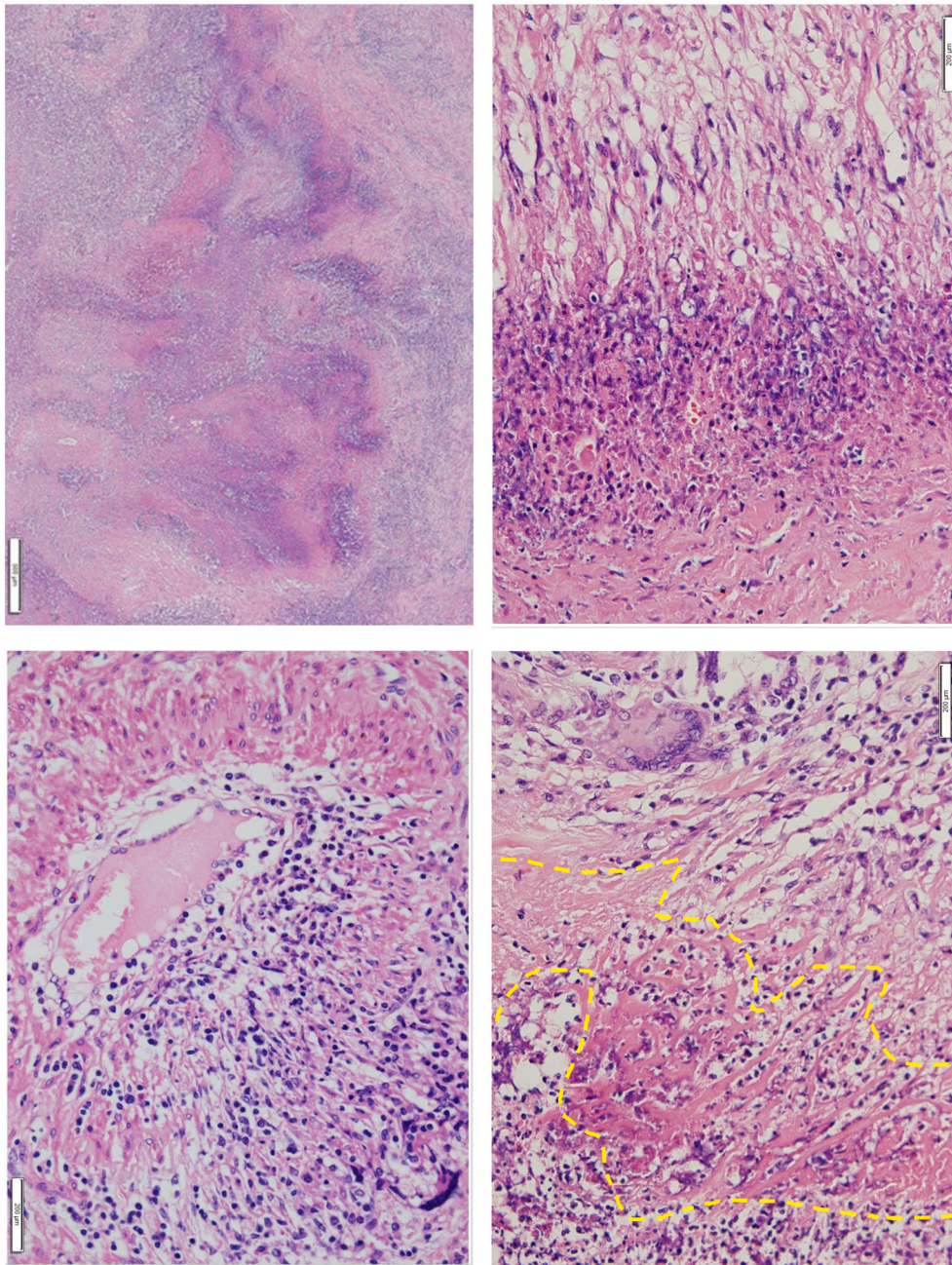
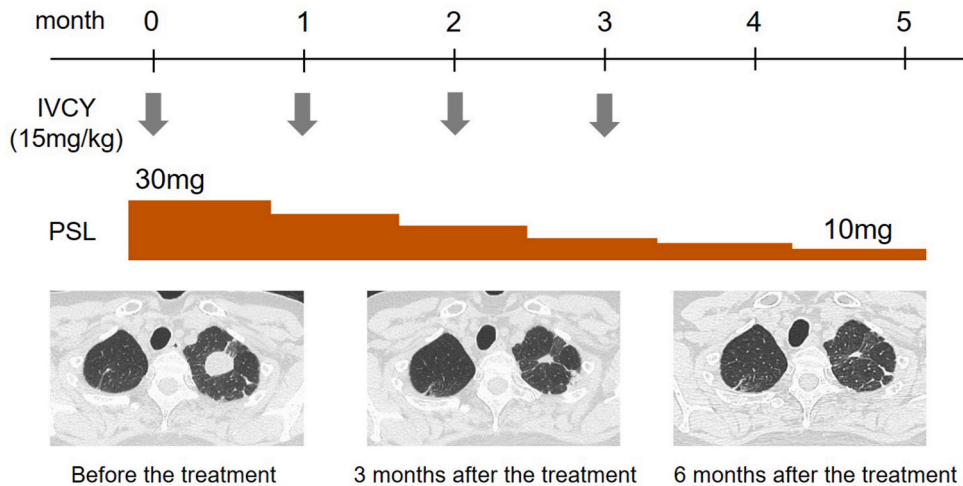


Fig. 2. (A) Poorly formed granuloma with geographic and basophilic necrosis. (B) The periphery of the necrosis had a palisaded arrangement of epithelioid histiocytes. (C) Small vessel vasculitis and degeneration of arterial wall, accompanied by a mixed inflammatory infiltrate composed of neutrophils, lymphocytes, plasma cells, giant cells, and eosinophils. (D) Collagen fiber necrosis with a mixed inflammatory infiltrate.

complications [20]. IVCY may have more side effects than methotrexate or mycophenolate mofetil. Nonetheless, the present patient was non-elderly and had no comorbidities, which is typically associated with less adverse effects of IVCY. At present, this patient has shown no signs of recurrence of GPA for three years and eight months after the initial therapy, indicating that a combination of IVCY and PSL contributes to preventing the relapse and progression of systemic vasculitis for a long term. If patients are tolerant of the adverse effects, a combination of PSL and IVCY may be an option even in patients with non-life-threatening disease; however, the risk–benefit balance should be cautiously evaluated. Meanwhile, trimethoprim-sulfamethoxazole is an alternative treatment for localized GPA. The effectiveness of trimethoprim-sulfamethoxazole for localized GPA is reported [21]. Less toxic therapy such as trimethoprim-sulfamethoxazole could be an option if patients are at risks for side effects of immunosuppressive therapy (i.e., the



IVCY: Intravenous cyclophosphamide
PSL: Prednisolone

Fig. 3. Course of treatment is shown. After the initiation of the immunosuppressive therapy, the mass in the apical portion of the left lung substantially decreased.

elderly, patients with comorbidities).

Therefore, in cases of lung granulomas of unknown etiology, a careful multidisciplinary approach is pivotal for a definitive diagnosis. To prevent fatal outcomes and progression to generalized GPA, PSL combined with IVCY may be considered even in cases of non-life-threatening disease, if the patients can tolerate the adverse effects. Further accumulation of cases is required to elucidate the validity of a combination of PSL and IVCY in patients with non-life-threatening, localized GPA.

Funding sources

This research did not receive any specific grant from funding agencies in the public, commercial, or not-for-profit sectors.

Declaration of competing interest

None.

Acknowledgements

We thank Editage (www.editage.jp) for English language editing.

References

- [1] J.L. Fahey, E. Leonard, J. Churg, G. Godman, Wegener's granulomatosis, *Am. J. Med.* 17 (2) (1954) 168–179.
- [2] E.J. Mark, O. Matsubara, N.S. Tan-Liu, R. Fienberg, The pulmonary biopsy in the early diagnosis of Wegener's (pathergic) granulomatosis: a study based on 35 open lung biopsies, *Hum. Pathol.* 19 (9) (1988) 1065–1071.
- [3] G.S. Hoffman, U. Specks, Antineutrophil cytoplasmic antibodies, *Arthritis Rheum.* 41 (9) (1998) 1521–1537.
- [4] J.D. Finkielman, A.S. Lee, A.M. Hummel, M.A. Viss, G.L. Jacob, H.A. Homburger, T. Peikert, G.S. Hoffman, P.A. Merkel, R. Spiera, E.W. St Clair, J.C. Davis Jr., W.J. McCune, A.K. Tibbs, S.R. Ytterberg, J.H. Stone, U. Specks, WGET Research Group, ANCA are detectable in nearly all patients with active severe Wegener's granulomatosis, *Am. J. Med.* 120 (7) (2007), 643.e9-14.
- [5] J.U. Holle, W.L. Gross, K. Holl-Ulrich, P. Ambrosch, B. Noelle, M. Both, E. Csernok, F. Moosig, S. Schinke, E. Reinhold-Keller, Prospective long-term follow-up of patients with localised Wegener's granulomatosis: does it occur as persistent disease stage? *Ann. Rheum. Dis.* 69 (11) (2010) 1934–1939.
- [6] S. Campainha, M. Gonçalves, V. Tavares, P. Castelões, A. Marinho, S. Neves, Granulomatosis with polyangiitis initially misdiagnosed as lung cancer, *Rev. Port. Pneumol.* 19 (1) (2013) 45–48.
- [7] P. Masuta, I. Amzuta, Solitary pulmonary nodule: a diagnostic Dilemma, *Case Rep. Pulmonol.* 2019 (2019) 5242634.
- [8] E. McCarthy, M. Mustafa, M. Watts, ANCA-negative granulomatosis with polyangiitis: a difficult diagnosis, *Eur. J. Case Rep. Intern. Med.* 4 (8) (2017), 000625.
- [9] J. Fijolek, E. Wiatr, D. Gawryluk, R. Langfort, K. Roszkowski-Sliż, Difficulties in recognizing granulomatosis with polyangiitis (GPA) in elderly patients undergoing diagnostic thoracotomy twice - a report of two cases, *Adv. Respir. Med.* 87 (6) (2019) 258–264.
- [10] L. Pan, J.-H. Yan, F.Q. Gao, H. Li, S.-S. Han, G.H. Cao, C.-J. Lv, X.-Z. Wang, Case report of a 28-year-old man with aortic dissection and pulmonary shadow due to granulomatosis with polyangiitis, *BMC Pulm. Med.* 8 19 (1) (2019) 122.
- [11] W.D. Travis, G.S. Hoffman, R.Y. Leavitt, H.I. Pass, A.S. Fauci, Surgical pathology of the lung in Wegener's granulomatosis. Review of 87 open lung biopsies from 67 patients, *Am. J. Surg. Pathol.* 15 (4) (1991) 315–333. April.
- [12] J.W. Tervaert, R. Goldschmeding, R.J. Hene, C.G.M. Kallenberg, Neutrophil cytoplasmic antibodies and Wegener's Granulomatosis, *Lancet* i (270) (1989).

- [13] J.W. Tervaert, L. Mulder, C. Stegeman, J. Elema, M. Huitema, H. The, C. Kallenberg, Occurrence of autoantibodies to human leucocyte elastase in Wegener's granulomatosis and other inflammatory disorders, *Ann. Rheum. Dis.* 52 (2) (1993) 115–120.
- [14] S. Ohshimo, J. Guzman, U. Costabel, F. Bonella, Differential diagnosis of granulomatous lung disease: clues and pitfalls: number 4 in the series "pathology for the clinician" edited by peter dorfmüller and Alberto Cavazza, *Eur. Respir. Rev.* 26 (145) (2017) 28794143. Aug 9.
- [15] M. Yates, R.A. Watts, I.M. Bajema, M.C. Cid, B. Crestani, T. Hauser, B. Hellmich, J.U. Holle, M. Laudien, M.A. Little, R.A. Luqmani, A. Mahr, P.A. Merkel, J. Mills, J. Mooney, M. Segelmark, V. Tesar, K. Westman, A. Vaglio, N. Yalçındağ, D.R. Jayne, C. Mukhtyar, EULAR/ERA-EDTA recommendations for the management of ANCA-associated vasculitis, *Ann. Rheum. Dis.* 75 (9) (2016) 1583–1594.
- [16] R. Fienberg, The protracted superficial phenomenon in pathergic (Wegener's) granulomatosis, *Hum. Pathol.* 12 (1981) 458–467.
- [17] J.W.C. Tervaert, F.J. van der Woude, A.S. Fauci, J.L. Ambrus, J. Velosa, W.F. Keane, S. Meijer, M. van der Giessen, K. van der Hem, T.H. The, G.K. van der Hem, C.G.M. Kallenberg, Association between active Wegener's granulomatosis and anticytoplasmic antibodies, *Arch. Intern. Med.* 149 (11) (1989) 2461–2465.
- [18] M. Odeh, L.A. Best, H. Kerner, H. Bassan, A. Oliven, Localized Wegener's granulomatosis relapsing as diffuse massive intra-alveolar hemorrhage, *Chest* 104 (3) (1993) 955–956.
- [19] P. Boudes, Mediastinal tumour as the presenting manifestation of Wegener's granulomatosis, *J. Intern. Med.* 227 (3) (1990) 215–217.
- [20] K.D. De Groot, N. Rasmussen, P.A. Bacon, J.W. Tervaert, C. Feighery, G. Gregorini, W.L. Gross, R. Luqmani, D.R. Jayne, Randomized trial of cyclophosphamide versus methotrexate for induction of remission in early systemic antineutrophil cytoplasmic antibody-associated vasculitis, *Arthritis Rheum.* 52 (8) (2005) 2461–2469.
- [21] J.W.C. Tervaert, Trimethoprim-sulfamethoxazole and antineutrophil cytoplasmic antibodies-associated vasculitis, *Curr. Opin. Rheumatol.* 30 (4) (2018) 388–394.