

Crossed Renal Ectopia and Aorto-Occlusive Disease: A Management Strategy

Eugene Ng, MBBS^{1,2}, Ian Campbell, MBBS¹, Andrew MTL Choong, FRACS, FEBVS^{1,2},
Nigel Dungleison, FRACS³, Maged Aziz, FRACS^{1,2}

We present a rare case of a patient with aortoiliac occlusive disease on the background of type A crossed renal ectopia, for whom open surgical intervention was required. Aortic exposure in patients with concomitant crossed renal ectopia can present technical challenges to the vascular surgeon. The knowledge of variations in the ectopic renal blood supply is of paramount importance when performing surgery to treat this condition and affects the choice of surgical exposure. We present and discuss the operative details of our patient and outline an approach to this subset of patients.

Key words: 1. Vascular disease
2. Atherosclerosis
3. Blood vessel prosthesis implantation
4. Peripheral artery disease/diseases

CASE REPORT

A 42-year-old female smoker presented to the Vascular department with a 10-day history of acute-onset right leg pain. Her vascular history was significant for stable intermittent claudication in the left leg that had been ongoing for several years and a right great hallux ulcer secondary to trauma that necessitated multiple courses of antibiotics.

On examination, the first and second digits of her right foot were noted to be discoloured, with associated decreased sensation in the affected areas. Buerger's test was positive. No femoral or lower extremity distal pulses were palpable. A discernible aortic, renal, and iliac bruit were noted.

A computed tomography angiogram of the abdomen showed severe aortoiliac occlusive disease. She was not

deemed suitable for endovascular repair. A crossed-fused ectopic kidney was noted in the right upper pelvis (Figs. 1–3). The ectopic kidney was supplied by two renal arteries, one arising from the right renal artery and supplying the upper pole at the L2 vertebral level and another right renal artery supplying the midpole at the L4 vertebral level. The arterial supply of the left kidney was an artery arising from the midline just above the abdominal aorta. Two renal veins were noted, merging into a common origin with the inferior vena cavae.

The patient consented to an aortobifemoral bypass graft. The operation was performed under a general anaesthetic as well as a T10- to T11 vertebral level epidural. A midline laparotomy was performed with exposure of the suprarenal aorta following left medial visceral rotation. The renal vessels were

¹Department of Vascular and Endovascular Surgery, Royal Brisbane and Women's Hospital, ²Discipline of Surgery, School of Medicine, University of Queensland, ³Griffith University

Received: February 12, 2015, Revised: July 30, 2015, Accepted: July 3, 2015, Published online: October 5, 2015

Corresponding author: Eugene Ng, Department of Vascular Surgery, Royal Brisbane Hospital, Bowen Bridge Road, Herston, Queensland 4000, Australia

(Tel) 61-7-4433-1111 (Fax) 61-7-3646-8111 (E-mail) Eugeneng82@gmail.com

© The Korean Society for Thoracic and Cardiovascular Surgery. 2015. All right reserved.

© This is an open access article distributed under the terms of the Creative Commons Attribution Non-Commercial License (<http://creativecommons.org/licenses/by-nc/4.0>) which permits unrestricted non-commercial use, distribution, and reproduction in any medium, provided the original work is properly cited.

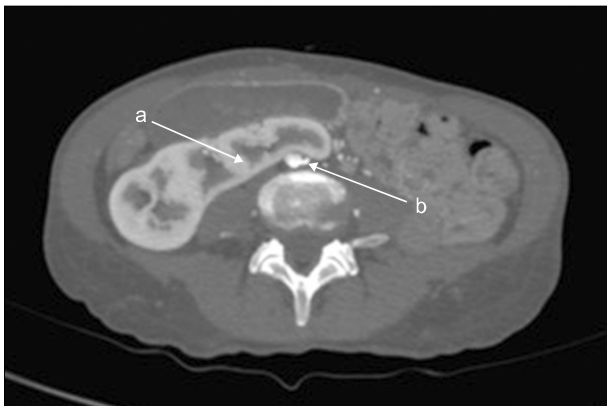


Fig. 1. Axial computed tomography depicting (a) crossing renal ectopic tissue and (b) severe occlusive aortic bifurcation disease.

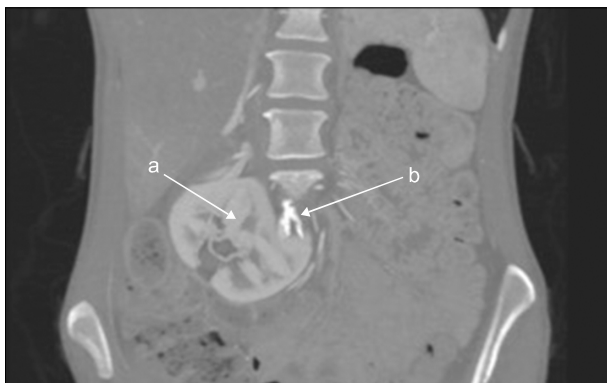


Fig. 2. Coronal computed tomography depicting (a) crossing renal ectopic tissue and (b) severe occlusive aortic bifurcation disease.

identified and preserved. Urology input was requested to identify the left ureter for the purpose of graft tunnelling. A proximal end-to-side anastomosis with a 12×6-mm Dacron graft was performed with 4-0 prolene, and the graft was tunnelled retroperitoneally, posterior to the ureters bilaterally. Distally, bilateral common femoral artery exposure was performed and an end-to-side anastomosis with 6-0 prolene was carried out.

The patient spent two days in the intensive care unit and was discharged on the second postoperative day to the ward. On the third postoperative day, she complained of left leg numbness and pain. She was noted to have a palpable left femoral pulse but no distal pedal pulses present on the left side. An ultrasound showed a left common femoral artery occlusion distal to the left limb of the aortobifemoral bypass

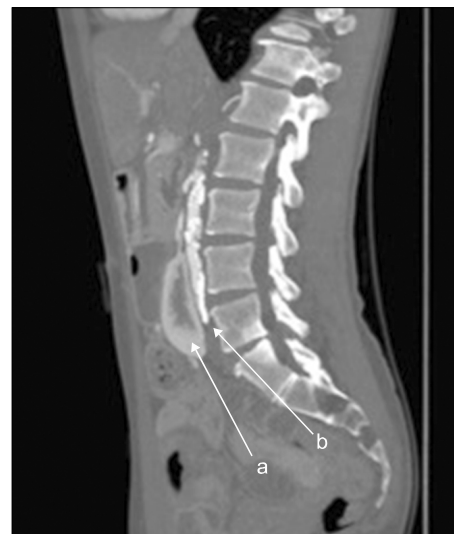

Fig. 3. Coronal computed tomography depicting (a) crossing renal ectopic tissue and (b) severe occlusive aortic bifurcation disease.

graft. Localized endarterectomy was performed and the distal pulse was restored. The patient had an uneventful post-operative course and was discharged from the hospital four days later.

DISCUSSION

The earliest description of renal ectopia in the presence of abdominal aortic aneurysmal disease was by Julian in 1956 [1]. Renal fusion and ectopia, while rare, are the most common congenital abnormalities of the kidneys. The various forms of renal fusion are illustrated in Fig. 2. Renal ectopia arises from the aberrant ascent of the kidneys during embryological development in the fourth to eighth weeks of gestation. This can be a result of anomalies of the ureteric metanephros, vascular supply, or genetic abnormalities. As the kidneys ascend, they derive their vascular supply from the vessels closest to them; initially the median sacral artery, then the common iliac and inferior mesenteric arteries, and finally the aorta. Upon reaching the normal retroperitoneal location in the body, renal arteries and veins develop to provide vascular support. In renal ectopia, aberrant vasculature arises because the ectopic kidneys maintain their associated multiple arterial branches as they ascend, which is a reflection of the embryological origin of the blood supply to the kidneys dur-

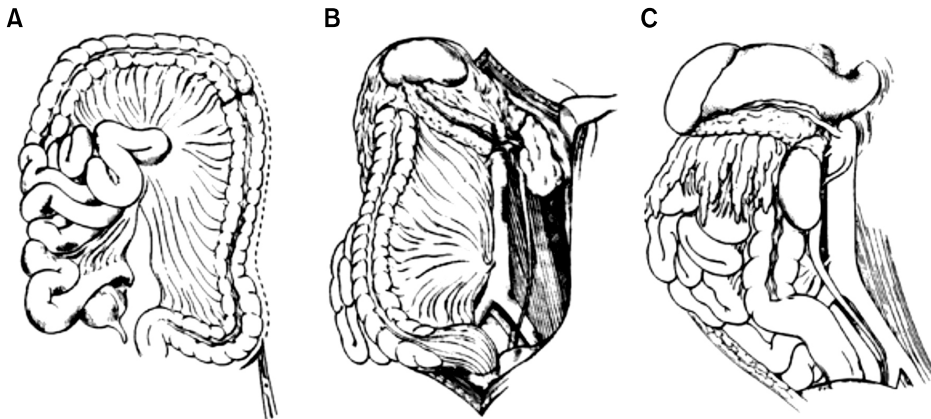


Fig. 4. Figures A, B and C all show the process of left medial visceral rotation in stages and the single leg-ent provided applies to all figures A to C [6].

ing normal development. The sites of ectopia are varied and include the pelvic, iliolumbar, and lower chest regions [2].

Crossed renal ectopia is the second most common renal fusion anomaly after horseshoe kidney, with an incidence of 1 in 1,000. Four types exist: type A, crossed renal ectopia with fusion; type B, crossed ectopia without fusion; type C, solitary crossed ectopia; and type D, bilaterally crossed ectopia.

In patients with crossed renal ectopia, the arterial blood supply to the kidneys may range from one to six arteries that are often abnormally located, with 75% arising from the upper aorta and 25% arising from the lower aorta and iliac arteries. Venous return may also be abnormal, with the majority of return via the main right and left renal veins draining directly into the inferior vena cava. Crossed ectopia is always associated with abnormally located ureters. Regardless of whether one or more kidneys are involved, the associated ureters always cross the midline at the level of the distal aorta or bifurcation and enter the bladder on the side of embryonic origin.

Generally, renal fusion and ectopia are relatively benign conditions, associated with normal renal function in adulthood. The problem arises when the same patient presents for the surgical management of aorto-occlusive disease. This requires preoperative imaging to elucidate the vascular and renal anatomy, planning the optimal surgical exposure of the aortic lesion, identifying the corresponding obstructed arterial branch, and preserving the renal blood supply with avoidance of injury to the abnormally positioned ureters. Of particular importance is the preservation of the renal blood supply, as all renal and accessory arteries are end arteries with no anas-

tomoses for alternative supply if sacrificed, and renal failure is common in the postoperative period in patients with crossed renal ectopia.

No fixed recommendations currently exist regarding the surgical approach in the treatment of aorto-occlusive disease in this subgroup of patients. The majority of the literature discusses aortic aneurysmal disease in conjunction with renal ectopia. In these studies, an anterior midline transperitoneal approach was most frequently used [3-5].

The largest case series on this particular subset of patients was performed by Crawford et al. [3] in 1988, in which 17 patients with ectopic kidneys and concomitant aorto-occlusive or aneurysmal disease were studied. This study also discussed the surgical approach in the management of these patients. Of note were the two cases of crossed ectopic kidneys. The surgical approach was retroperitoneal with exposure of the aneurysm from behind and reflection of the kidney mass and ureter upwards and to the right in one case, while the other case involved a standard anterior midline incision.

Faggioli et al. [4] studied the technical challenges and outcomes of 18 patients with renal anomalies and concurrent aortic pathology. Of these patients, 10 had horseshoe kidneys, while eight had ectopic kidneys. Seventeen patients had aortic aneurysms and 1 patient had aorto-occlusive disease. The choice of surgical approach was determined through the preoperative evaluation of the vascular anatomy. The anterior transperitoneal approach was utilized in 16 patients and a retroperitoneal/thoracoabdominal approach in the remaining two, of which one was an ectopic kidney. The perioperative mortality rate was 0%, with no renal or aortic complications at

long-term follow-up.

In our case, the patient had type A crossed renal ectopia. A midline anterior approach was performed, with the utilisation of left medial visceral rotation.

This technique is also known as the Cattell-Mattox procedure and involves the mobilisation of the left colon, spleen, and kidney to expose the entire length of the abdominal aorta (Fig. 4). Conversely, right medial visceral rotation is known as the Cattell-Braasch procedure, which normally involves an extended Kocher incision to allow for mobilisation of the duodenum as well. We opted for this technique to allow for optimal visualisation of the vascular and renal anatomy and to facilitate operative intervention.

In summary, renal anomalies in the presence of aortic disease do not preclude aortic surgery, although careful preparation must be done before operative intervention. There are two main aims of surgery: revascularisation to ameliorate the effects of aorto-occlusive disease and the preservation of renal function.

The approach to patients with crossed renal ectopia and concomitant aorto-occlusive disease should thus be stepwise and structured, involving the following steps. (1) Careful elucidation of the vascular and renal anatomy, with consideration of computerized tomography, angiography, and intravenous pyelography. (2) Early consultation with urology for planning the surgical management of aberrant renal vasculature in conjunction with revascularisation. (3) The surgical approach should be based on the vascular and renal anatomy, with the majority of studies advocating a midline anterior transperitoneal approach. This approach allows for the optimal visual-

ization of the aberrant ectopic renal vasculature and also facilitates operative intervention. (4) The preservation of the renal vessel and ureter supply is of paramount importance. Surgeons should be aware of the crossing of the ureters at the midline of the distal aorta or bifurcation, regardless of the type of ectopia. (5) Monitoring for renal failure and general graft complications postoperatively.

CONFLICT OF INTEREST

No potential conflict of interest relevant to this article was reported.

REFERENCES

1. Julian OC. *Diagnosis in arterial disease*. Surg Clin North Am 1956;(Chicago No):177-91.
2. Hollis HW Jr, Rutherford RB, Crawford GJ, Cleland BP, Marx WH, Clark JR. *Abdominal aortic aneurysm repair in patients with pelvic kidney: technical considerations and literature review*. J Vasc Surg 1989;9:404-9.
3. Crawford ES, Coselli JS, Safi HJ, Martin TD, Pool JL. *The impact of renal fusion and ectopia on aortic surgery*. J Vasc Surg 1988;8:375-83.
4. Faggioli G, Freyrie A, Pilato A, et al. *Renal anomalies in aortic surgery: contemporary results*. Surgery 2003;133:641-6.
5. Ilic NS, Koncar I, Dragas M, et al. *Technical considerations for transabdominal aortic reconstruction with renal fusion and ectopia: case series*. Vascular 2010;18:269-74.
6. Brohi K. Damage control surgery [Internet]. [London]: trauma.org; 2000 [cited 2015 Feb 10]. Available from: <http://www.trauma.org/index.php/main/article/368/>.