

# Surgical Management for Systolic Anterior Motion (SAM) of the Mitral Valve in Obstructive Hypertrophic Myopathy

Akihiko Usui<sup>1</sup> and Masato Mutsuga<sup>2</sup>

**In patients with obstructive hypertrophic cardiomyopathy, left ventricular outflow tract (LVOT) obstruction can be created by the hypertrophic interventricular septum (IVS) as well as systolic anterior motion (SAM) of the anterior mitral leaflet (AML). Sufficient septal myectomy is a fundamental surgical technique to treat LVOT obstruction, however, direct surgical management for SAM is another key aspect. Besides the hypertrophic IVS, mitral valve, subvalvular apparatus, and papillary muscle may play important role for SAM and several surgical techniques have been proposed to treat SAM in literature. In this review, each surgical technique is classified by the anatomical structure on which the surgical procedure is applied. The AML is the main surgical site and is applied with plication (vertical plication, resection–plication–release strategy), extension (the AML extension, transverse incision of the AML), sutured (edge-to-edge repair, anterior leaflet retention plasty), or traction (floating stitch, papillary muscle-to-anterior annulus stitches, paradoxical stitches, transposition of a directed chorda tendinea to the AML). Height reduction of the posterior mitral valve leaflet and papillary muscle reorientation are other techniques. We should understand theoretical aspects of each technique on correction of anatomical and functional abnormalities of the structure and should apply them under proper indication.**

**Keywords:** systolic anterior motion, obstructive hypertrophic cardiomyopathy, mitral valve repair, surgical technique

## Introduction

In patients with obstructive hypertrophic cardiomyopathy (HCM), left ventricular outflow tract (LVOT)

<sup>1</sup>Department of Cardiovascular Surgery, Fujita Health University Okazaki Medical Center, Okazaki, Aichi, Japan

<sup>2</sup>Department of Cardiac Surgery, Nagoya University Graduate School of Medicine, Nagoya, Aichi, Japan

Received: June 13, 2022; Accepted: June 16, 2022

Corresponding author: Akihiko Usui, Department of Cardiovascular Surgery, Fujita Health University Okazaki Medical Center, Gotanda 1, Harisaki-cho, Okazaki, Aichi 444-0827, Japan  
Email: akihiko.usui@fujita-hu.ac.jp



This work is licensed under a Creative Commons Attribution-NonCommercial-NoDerivatives International License.

©2022 The Editorial Committee of *Annals of Thoracic and Cardiovascular Surgery*

obstruction can be created by the hypertrophic interventricular septum (IVS) as well as systolic anterior motion (SAM) of the anterior mitral leaflet (AML). An early theory of SAM was that hypertrophy IVS causes a narrowing of the LVOT and that high blood velocities in the LVOT cause Venturi forces that suck the AML into the IVS. Recently, it was reported that LVOT blood velocities are not high to make significant Venturi forces at the onset of SAM and blood flow behind the AML is observed early in systole.<sup>1,2</sup> This dragging force of blood flow pushes the AML from behind and sweeps them into the IVS. The principal role of the hypertrophied IVS is that it redirects flow posteriorly and laterally in the left ventricular (LV) cavity, so that its early systolic flow strikes the AML on the wrong side. SAM is understood as an overlap between the inflow and outflow portions of the LV.<sup>3</sup> Once AML–IVS contact

occurs, it produces the pressure gradient that further narrows the LVOT.

Sufficient septal myectomy is a theoretical and fundamental surgical technique to treat LVOT obstruction. Septal myectomy redirects ejection flow anteriorly and medially away from the AML, and this physiological flow reduces the dragging force to the AML. However, direct surgical management for SAM is another key aspect of surgery for obstructive HCM. SAM is caused by many factors besides the hypertrophic IVS. Mitral valve, subvalvular apparatus, and papillary muscle may play important role for SAM in the majority of patients.

Elongated AML is the most common abnormality. It protrudes the coaptation plane into the LV ejection flow<sup>4)</sup> and makes the AML slack that permits increased mobility. Anterior position of the AML in the LV cavity is the necessary condition for SAM. In this condition, LV flow is easy to strike the posterior side of the AML.<sup>1,2)</sup> Another common anomaly is an anteriorly positioned head of the anterolateral papillary muscle that positions the AML into the LV outflow tract by tenting the AML anteriorly. Anatomical and functional abnormalities of these structures should be evaluated precisely by diagnostic imaging such as echocardiography, magnetic resonance imaging, or four-dimensional computed tomography, and additional procedure to treat these abnormalities may be required to manage SAM in several cases. So direct management of SAM is another key aspect of surgery for obstructive HCM. SAM can be caused after mitral valve repair, and anatomical, functional abnormalities of valvular and subvalvular structures also play important role for SAM in such cases and surgical management of these abnormalities should reduce SAM.

Several kinds of surgical technique have been proposed to treat SAM in literature. In this review, each surgical technique is classified by the anatomical structure on which the surgical procedure is applied. They are IVS, AML, posterior mitral valve leaflet (PML), papillary muscle, and subvalvular apparatus, and most of the surgical techniques are applied on the AML with plication, extension, suture, or traction. Each procedure is introduced with technical aspects and theoretical ones as well.

## Surgical Management of SAM

### Intraventricular septum

#### *Extended septal myectomy*

Septal myectomy is based on Morrow's technique. It was originally reported as myotomy from the apex of the

heart to the aortic annulus.<sup>5)</sup> Myectomy consists of creating a rectangular channel in the IVS. Two parallel incisions are made beneath nadir of right coronary cusp and as far leftward as possible. These incisions are joined by a transverse incision.<sup>6)</sup> Extended myectomy and reconstruction of the subvalvular mitral apparatus have been proposed by Messmer,<sup>7)</sup> and the current extended septal myectomy technique was confirmed by the Mayo Clinic group.<sup>8)</sup> Sufficient volume reduction of the IVS is a key of extended myectomy and several techniques were introduced to achieve a safe and satisfactory septal myectomy. We have proposed a needle stick technique for septal myectomy. Three 21-gauge needles are inserted into the IVS just below the aortic valve annulus beyond the far side of the septal bulge. The right and left needles are both side margins, and the center needle is a guide for the thickness. Each needle plays a role as a mark of resection for the width, length, and thickness. The needles also stabilize the ventricular septum and provide good exposure of the entire IVS. This technique is helpful to safely achieve sufficient septal myectomy of a constant thickness.<sup>9)</sup>

### Anterior mitral leaflet (AML)

#### *Plication of the AML*

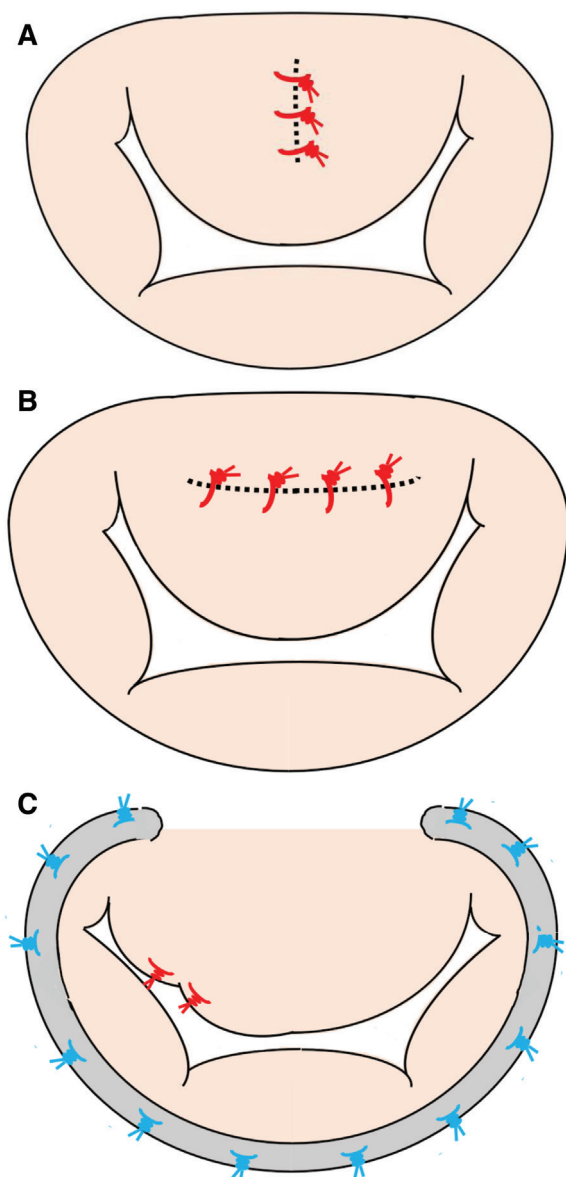
Elongation of AMLs is one of major causes for SAM, and Klues and associates found that 44% of patients with obstructive HCM had enlarged and elongated mitral valves leaflets.<sup>10)</sup> Shortening of an elongated AML is a theoretical technique to reduce SAM in such cases. Two kinds of methods have been proposed in literature. One is vertical plication and another is resection–plication–release (RPR) technique.

#### a. Vertical plication (**Fig. 1A**)

McIntosh et al. proposed the vertical plication of the AML. The AML is plicated along its long axis to reduce the billowing of the AML. The effects of this procedure were assessed in 34 patients and 28 cases were reported to gain substantial functional improvement after surgery. There was no hemodynamic evidence of mitral stenosis and one patient had increase in mitral regurgitation after surgery. This technique reduces the width but not the length of the AML.<sup>11)</sup>

#### b. RPR (resection-plication-release) strategy (**Fig. 1B**)

Swistel and Sherrid proposed the horizontal plication of the AML. If the AML is excessively long, a horizontal plication can be performed, or if a residual leaflet portion



**Fig. 1** Schema of the surgical technique of plication of the AML. (A) Vertical plication. The AML is plicated along its long axis to reduce the billowing of the AML. (B) RPR (resection-plication-release) strategy. If the AML is excessively long, a horizontal plication can be performed, or if a residual leaflet portion is present, it can be resected. (C) Partial anterior leaflet valvuloplasty. A redundant lateral segment of the AML is plicated by folding its elongated portion underneath the body of the AML. AML: anterior mitral leaflet

is present, it can be resected. This technique is called RPR strategy. The main body of the AML, just below the mitro-aortic curtain, was plicated with four or five horizontal mattress sutures of 5–0 polypropylene monofilament sutures along the short axis of the AML. It can shorten an excessive long AML by anywhere from 3 to 6

mm.<sup>12)</sup> The RPR strategy has been applied on milder hypertrophic IVS under 18 mm and longer AML height of 30 mm or 17 mm/m<sup>2</sup>. RPR can be performed through the transaortic approach.<sup>13)</sup> The RPR strategy is safe and effective for symptomatic obstructive HCM and results in good intermediate outcomes with respect to gradient, mitral regurgitation, and clinical status.<sup>14)</sup> RPR performed by experienced surgeons in 252 patients led to excellent clinical outcomes with an operative mortality of 0.4% and 1-year survival of 98%.<sup>15)</sup>

Raney and colleagues also reported a ‘Pomeroy procedure,’ which consisted of removal of excess tissue and reduction of the AML height in addition to reduction in the PML height and oversizing of the annuloplasty ring.<sup>16)</sup>

Khalpey and colleagues presented partial AML valvuloplasty to prevent SAM in patients with a redundant lateral segment of the AML by folding its elongated portion underneath the body of the AML. This technique directly addresses the functional anatomic geometry responsible for SAM (Fig. 1C).<sup>17)</sup>

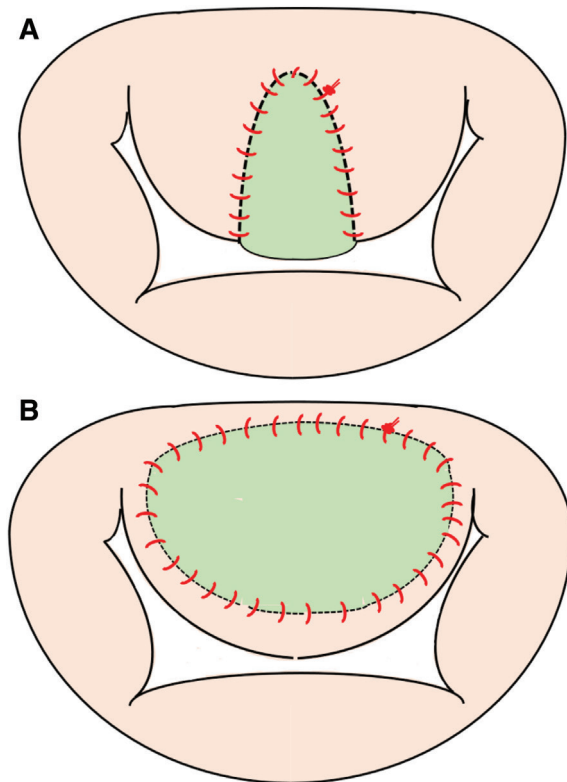
#### *Extension of the AML*

##### a. The anterior mitral leaflet extension (AMLE) (Fig. 2A)

The AMLE was introduced by the Erasmus University group. It involves the vertical incision of the AML, followed by the suture of an oval autologous pericardial patch pretreated with glutaraldehyde.<sup>18)</sup> The AML is incised longitudinally from its subaortic hinge point to the rough zone. The patch, 3 cm wide and 2.5 cm long, is sewn onto the ventricular surface of the AML at the site of the incision by using three running polypropylene monofilament sutures. The patch extends the width of the AML but not its length, determining a lateral shift of the central-attached chordae tendineae that result more under tension. This technique stiffens the central portion of the AML and prevents its abnormal mobility, which may induce SAM. The same working group reported excellent outcomes with  $8.3 \pm 6.1$  years of average follow-up period in 98 patients. SAM grade was reduced from  $2.4 \pm 0.9$  to  $0.1 \pm 0.3$  ( $p < 0.001$ ) and 10-year cumulative survival rate was 92%. AMLE is a low-risk surgical procedure, which results in long-term symptom relief and survival similar to the general population.<sup>19)</sup>

##### b. Transverse incision of the AML

Transverse incision of the AML along the anterior annulus was also reported.<sup>20)</sup> The AML was detached



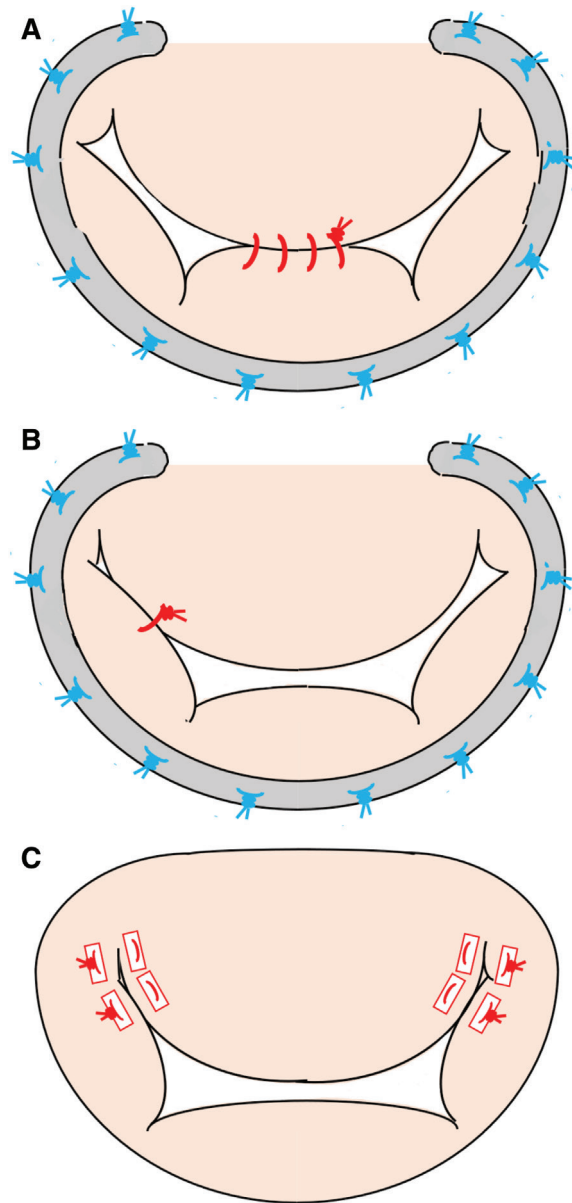
**Fig. 2** Schema of the surgical technique of extension of the AML. (A) AMLE (anterior mitral leaflet extension). It involves the vertical incision of the AML, followed by the suture of an oval autologous pericardial patch pretreated with glutaraldehyde. (B) Transverse incision of the AML. Transverse incision of the AML is made along the anterior annulus and is covered with an oval autologous pericardial patch pretreated with glutaraldehyde. AML: anterior mitral leaflet

from the valve commissures, which provided direct visualization and access of the IVS. A trans-mitral extended Morrow procedure was utilized for septal myectomy. The incision was covered with an oval autologous pericardial patch pretreated with glutaraldehyde. Zhang et al. reported 16 patients who underwent transmitral septal myectomy and enlargement of LV outflow with an autologous pericardial patch in transverse configuration.<sup>21)</sup> It resolved SAM in all with only mild residual mitral regurgitation. This technique can stiffen the central portion of the AML but extends the length of the AML (**Fig. 2B**).

*Sutures of the AML*

a. Edge-to-edge repair (**Fig. 3A**)

The edge-to-edge sutures were proposed as a central double orifice technique in mitral valve repair by Alfieri and colleagues. Orifice mitral valve is created by



**Fig. 3** Schema of the surgical technique of sutures of the AML. (A) Edge-to-edge repair. The free edges of the AML and the posterior mitral leaflet are approximated at the site of regurgitation with a running 4-0 polypropylene monofilament suture or pledgeted polypropylene monofilament mattress sutures. (B) Asymmetric Alfieri's stitch. The edge-to-edge suture is placed between the A1 and P1 segments and not in the midline. (C) ALRP (anterior leaflet retention plasty). The segments of the AML closest to the trigones are sutured to the corresponding posterior annulus with pledgeted polypropylene monofilament mattress sutures. AML: anterior mitral leaflet

approximating the free edges of the leaflets at the site of regurgitation, usually with a running 4-0 polypropylene monofilament suture. In cases of very thin leaflets, 1 or

more U-shaped 5-0 polypropylene monofilament stitches reinforced with pledgets are used. Excellent long-term results of this method have been documented for effectiveness and durability.<sup>22)</sup> The edge-to-edge sutures have been proposed to eliminate SAM conveniently. Myers and colleagues reported 65 cases who underwent the edge-to-edge sutures for treatment of SAM in mitral valve repair. The incidence of SAM was 5.7%. SAM was completely eliminated and no patients developed mitral stenosis (mean transmitral gradient, 2.0  $\pm$  2.6 mmHg). Only one case presented late recurrence of SAM during a mean follow-up of 26 months.<sup>23)</sup>

The edge-to-edge sutures can be applied via the transaortic approach. Shah and coworkers presented 24 patients who underwent septal myectomy and mitral valve repair using the edge-to-edge sutures for obstructive HCM associated with SAM. They concluded that the edge-to-edge sutures is feasible in most cases as an additional repair tool to improve mitral valve regurgitation and minimize SAM and may have a role in addressing mitral disease, such as a long or fibrotic mitral valve.<sup>24)</sup>

However, the edge-to-edge sutures associates with a potentially increased risk of mitral stenosis, especially in patients with a small mitral annulus. It was reported that the edge-to-edge technique can reduce the mitral valve orifice area up to 60%.<sup>25)</sup>

Pereda and colleagues presented a modification of the edge-to-edge technique named asymmetric Alfieri's stitch. They placed the edge-to-edge suture between the A1 and P1 segments and not in the midline. The leaflet segments responsible vary, and the lateral segments of the AML or even the posterior leaflet may be implicated (**Fig. 3B**).<sup>26)</sup>

#### b. Anterior leaflet retention plasty (ALRP) (**Fig. 3C**)

Delmo Walter and Hetzer proposed ALRP and reported the Berlin experience. The segments of the AML closest to the trigones are sutured to the corresponding posterior annulus, wherein the polypropylene monofilament mattress sutures are pledgeted with untreated autologous pericardium. These sutures are passed through the coaptation line of the AML and the corresponding posterior annulus trigones. The valve orifice area is assessed with a valve sizer and the appropriate valve size is determined based on the body surface area. ALRP limits the mobility of the AML in the segment running along the anterior annulus and avoids producing SAM. They applied ALRP on 57 cases in 305 septal myectomies. Mitral valve regurgitation was trivial

in 87% and SAM was nonexistent in all. Two patients underwent mitral valve replacement 1 and 5 years after ALRP for recurrent mitral valve regurgitation. They concluded that ALRP sustained absence of SAM, absence of residual LVOT obstruction, and improvement in hemodynamic and functional statuses.<sup>27)</sup>

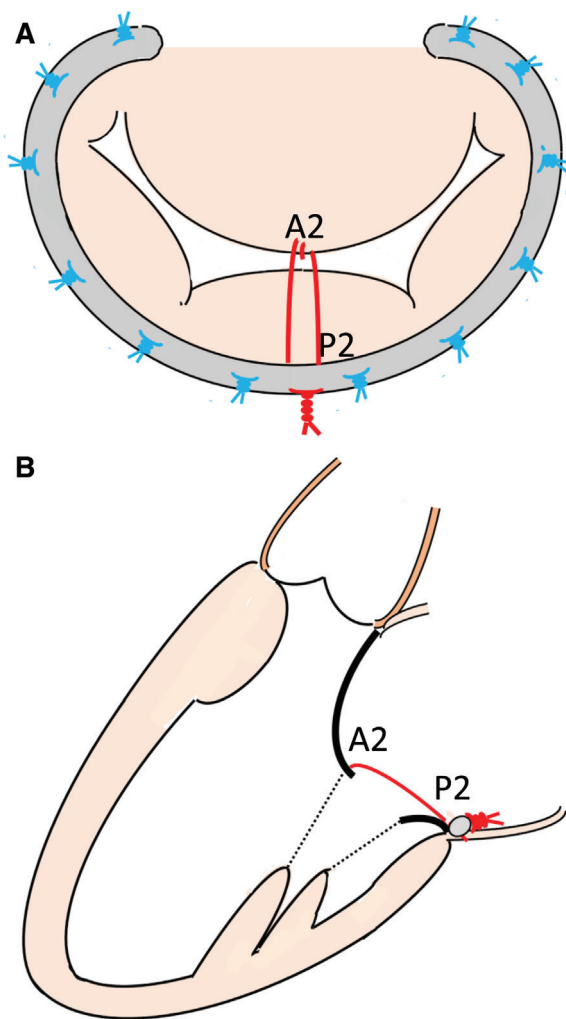
#### *Traction of the AML*

LVOT stenosis is caused by SAM, in which the AML approaches the IVS. By retracting the AML toward the mitral annulus, the AML does not approach to the IVS and SAM can be prevented. We proposed a novel technique by using a floating stitch on the AML to reduce SAM.<sup>28)</sup>

#### a. Floating stitch (**Figs. 4A and 4B**)

A double-arm Gore-Tex suture (CV-4®, W. L. Gore & Associates, Inc., Newark, Delaware, USA) is applied to just the middle of the tip of the AML (A2) in a figure-eight fashion, and both arms of the suture are fixed to the annuloplasty ring at the middle of the posterior annulus (P2). The length of the suture is then usually determined as A2–P2 length plus 2–3 mm of extra length on a water test. The AML is prevented from touching the IVS and SAM can theoretically be solved. Under this length of a floating stitch, the AML can move physiologically except the tip of AML is retracted showing a reverse concave shape during the diastolic phase. We have applied a floating stitch technique on 11 cases with obstructive HCM with moderate or severe mitral valve regurgitation due to SAM. Mitral valve annuloplasty with a partial rigid ring has principally applied concomitant with a floating stitch technique. Postoperative echocardiography was compared with other 11 cases, who underwent septal myectomy with mitral valve repair without a floating stitch. The group with a floating stitch revealed significantly larger IVS–AML distance at the end diastolic phase (13.4 mm vs. 9.7 mm) and similar mitral valve area (2.3 vs. 2.7 cm<sup>2</sup>) compared to the control group. A floating stitch technique is indicated for obstructive HCM patients with severe SAM or requiring mitral valvoplasty due to mitral valve regurgitation, although sufficient septal myectomy can reduce mitral valve regurgitation in these patients. This technique is a reproducible and durable method for preventing SAM.

A floating stitch can also be applied on postrepaired SAM. We reported a case who revealed severe SAM after mitral valve repair of the PML and was successfully treated with two pair of floating stitches.<sup>29)</sup> A floating



**Fig. 4** Schema of the surgical technique of a floating stitch. **(A)** Surgeons' view. A double-arm Gore-Tex suture is applied to just the middle of the tip of the AML (A2) in a figure-eight fashion, and both arms of the suture are fixed to the annuloplasty ring at the middle of the posterior annulus (P2). **(B)** Long axis view. The length of the suture is then usually determined as A2–P2 length plus 2–3 mm of extra length on a water test. The AML is prevented from touching the IVS and SAM can theoretically be solved. AML: anterior mitral leaflet; IVS: interventricular septum; SAM: systolic anterior motion

stitch is a simple method that can be applied without touching the subvalvular apparatus. This technique is easy to be applied via a small right side thoracotomy for minimal invasive cardiac surgery. When the AML is sufficiently long and mobile to touch the IVS, a floating stitch may help to prevent SAM.

#### b. Papillary muscle-to-anterior annulus stitches (**Fig. 5A**)

Kassem and Jamil introduced a surgical technique to prevent SAM after mitral valve repair, the so-called

papillary muscle–anterior annulus stitches technique. Two double-armed 4-0 Gore-Tex sutures are placed on the tip of the head of the posterior papillary muscle, passed through at about the mid-AML and are tightly tied onto the annuloplasty ring on the anterior annulus. The base of this method is to create a barrier at the same level of the posterior wall of the LVOT to support the edge of the AML and to prevent its dropping into the LVOT during the early systolic phase. They applied this technique on four cases of SAM after mitral valve repair.<sup>30)</sup>

#### c. Paradoxical stitches (**Fig. 5B**)

Kassem also proposed another technique, the so-called paradoxical stitches that aim to discipline the movement of the AML to avoid SAM. In this technique, two artificial chords are diagonally implanted at 5 and 7 o'clock locations between the posterior annulus and the AML. During the end diastole, the paradoxical stitches ensure the avoidance of contact between the tip of the elongated AML and the bulging IVS. Kassem first applied the papillary muscle–anterior annulus stitches, but when the anterior annulus was not well exposed, paradoxical stitches were considered.<sup>31)</sup>

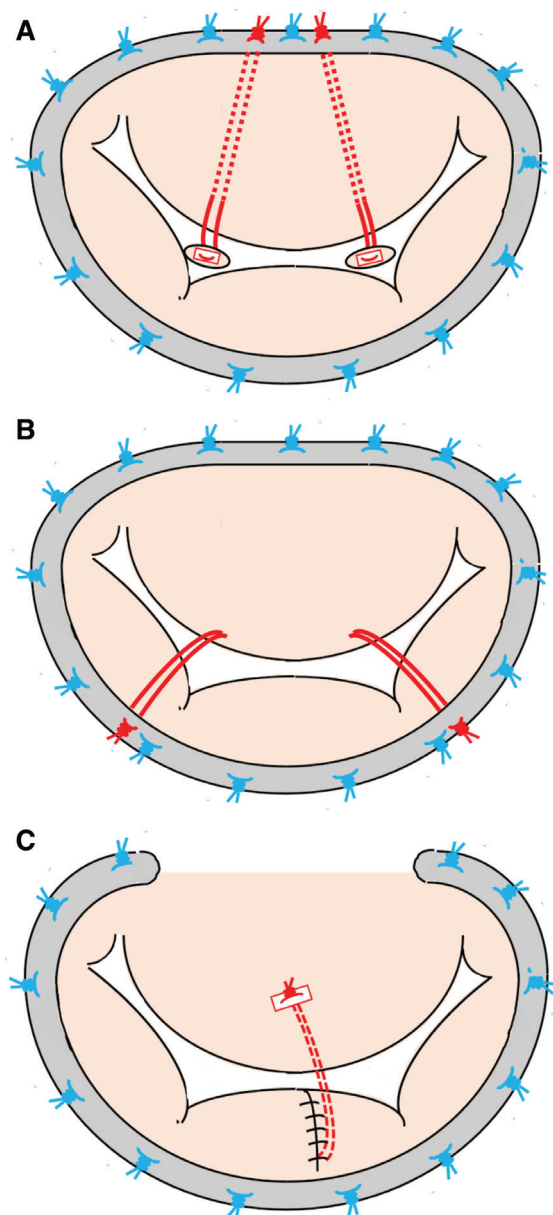
#### d. Transposition of a directed chorda tendinea to the AML (**Fig. 5C**)

Sternik and Zehr proposed the direct insertion of a head of the anterolateral papillary muscle into the mid portion of the AML. When the AML is redundant, it is partially obstructing the LVOT. The redundant AML is tethered posteriorly by transposition of a posteriorly directed chorda tendinea to an intermediate position on the ventricular side of the AML between the primary and secondary chordae tendineae of the A2 segment. It prevents the redundant AML from entering the LVOT. They used this technique on six patients with severely myxomatous regurgitant mitral valves and no postrepair SAM or LVOT obstruction was observed.<sup>32)</sup>

### Posterior mitral leaflet (PML)

#### Reduction height of the PML (**Fig. 6A**)

Another rapid procedure to correct SAM is to reduce the height of the PML by using pledgeted interrupted horizontal mattress sutures.<sup>33,34)</sup> Refractory SAM can also be treated by sliding plasty, if this procedure was not carried out at the initial repair (**Fig. 6B**). Under these circumstances, a prosthetic ring larger than the one previously implanted is often inserted. Other



**Fig 5** Schema of the surgical technique of traction of the AML. (A) Papillary muscle-to-anterior annulus stitches. Two double-armed 4-0 Gore-Tex sutures are placed on the tip of the head of the posterior papillary muscle, passed through at about the mid-AML, and are tightly tied onto the annuloplasty ring on the anterior annulus. (B) Paradoxical stitches. Two artificial chords are diagonally implanted at 5 and 7 o'clock locations between the posterior annulus and the AML. The paradoxical stitches avoid the contact between the tip of the elongated AML and the intraventricular septum. (C) Transposition of a directed chorda tendinea to the AML. The redundant AML is tethered posteriorly by transposition of a posteriorly directed chorda tendinea to an intermediate position on the ventricular side of the AML between the primary and secondary chordae tendineae of the A2 segment. AML: anterior mitral leaflet

effective methods for postrepair SAM correction are the use of short artificial chordae<sup>35)</sup> and the reduction in the height of the AML by ellipsoid excision or septal myectomy.<sup>36)</sup> PML shortening is a simple option that effectively moves the coaptation point of the mitral leaflets posteriorly and eliminates LVOT obstruction caused by SAM.<sup>37)</sup>

### Papillary muscle

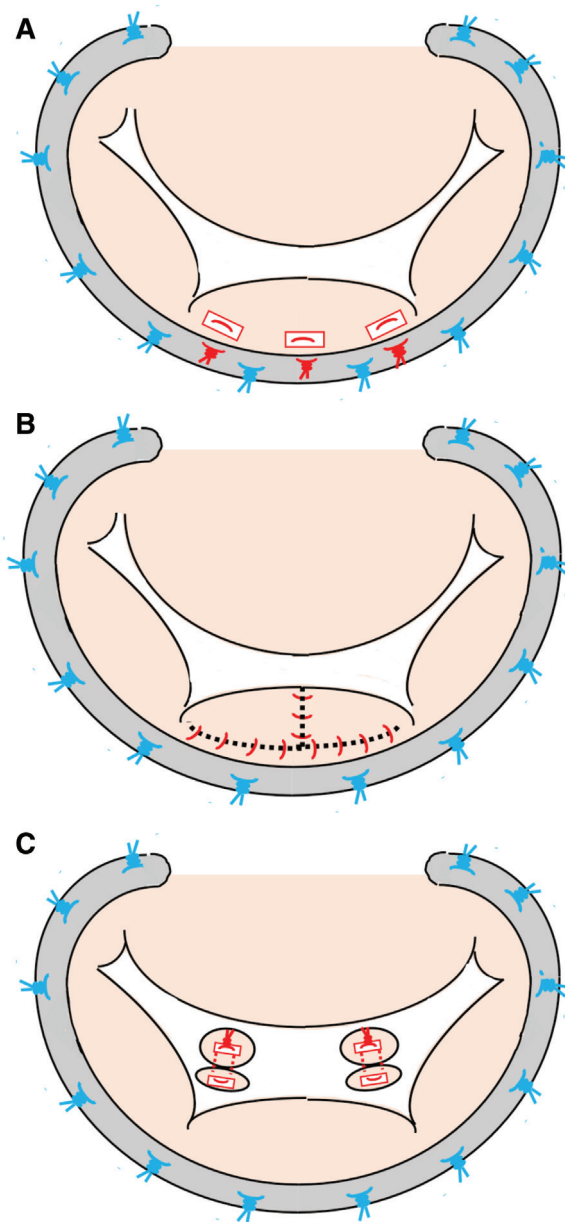
#### *Papillary muscle reorientation (Fig. 6C)*

Kwon et al. proposed papillary muscle reorientation for patients with HCM with bifid hypermobile papillary muscles. Papillary muscle reorientation was performed through the aortic valve. A pledgeted mattress suture was placed to the most posterior papillary muscle head and was passed through the anterior head. One or more mattress sutures were used to realign the papillary muscles, and both anterolateral and posteromedial papillary muscles were realigned as deemed necessary. Papillary muscle reorientation can correct the anteriorly positioned head of the anterolateral papillary muscle, which positions the AML into the LV outflow tract. Kwon et al. applied this technique on 22 cases in 204 consecutive patients with HCM. One patient required mitral valve replacement thereafter, but 21 of 22 patients were asymptomatic at a median follow-up of 166 days.<sup>38)</sup>

Sakaguchi et al. reported papillary muscle reorientation for treating SAM after isolated AML repair. This technique is also useful to treat postrepair SAM, without addressing the leaflet, in patients with degenerative mitral disease.<sup>39)</sup>

### Abnormality of mitral valve, chorda, and papillary muscle

A significant portion of patients with obstructive HCM presents a certain degree of mitral valve apparatus abnormalities that predispose to SAM and LVOT obstruction.<sup>40,41)</sup> Mitral valve repair is applied with specific techniques to address mitral structural abnormalities. A mitral valve replacement is reserved for patients with intrinsic leaflet abnormalities that cannot be repaired.<sup>8)</sup> Abnormality of the papillary muscle has also been reported in patients with obstructive HCM. The base of the anterolateral papillary muscle may be anteriorly displaced and the mitral valve leaflets may be shifted apically.<sup>42)</sup> The anterolateral papillary muscle may present abnormal connections with the LV anterolateral wall as well, and these conditions favor SAM and LVOT



**Fig. 6** Schema of the surgical technique for the PML or papillary muscle. **(A)** Reduction height of the PML. The height of the PML is reduced by using pledgeted interrupted horizontal mattress sutures. **(B)** Sliding plasty of the PML. Sliding plasty of the PML reduces the PML height if this procedure was not carried out at the initial repair. **(C)** Papillary muscle reorientation. One or more pledgeted mattress sutures are placed to the posterior papillary muscle head and are passed through the anterior head to realign both anterolateral and posteromedial papillary muscles. PML: posterior mitral valve leaflet

obstruction.<sup>43</sup> Freeing the papillary muscle from all the secondary attachments, as well as cutting it down from the ventricular wall, is necessary.

Anomalous papillary muscles in which the mitral valve leaflets are directly attached to the papillary muscle without chordae are sometimes observed in patients with obstructive HCM and play an important role in the pathophysiology of dynamic LVOT obstruction. We routinely excised and reconstructed all anomalous papillary muscles with Gore-Tex sutures concomitant with septal myectomy.<sup>44)</sup>

In patients with relatively thin IVS, abnormalities of mitral valve apparatus may be the main reason for SAM and LVOT obstruction. The selective cut of secondary chordae allows the repositioning of the coaptation point farther from the outflow tract. It may prevent SAM.<sup>45)</sup> Ferrazzi et al. reported a series of 39 symptomatic patients with severe LVOT obstruction but moderate septal hypertrophy ( $\leq 19$  mm), treated by chordal cutting in association with a shallow septal myectomy. When compared with the control group (similar characteristics but treated with a shallow myectomy only), the postoperative AML-annulus ratio was 17% greater and the tenting area was 24% smaller in patients with chordal cutting. It indicated that the MV apparatus had moved to a more normal posterior position within the LV cavity, preventing MV systolic displacement into the LVOT and outflow obstruction.<sup>46)</sup> Even after mitral valve repair, the length of the AML secondary chordae and the distance from the coaptation point to the IVS were associated with an increased risk of the postrepair SAM.<sup>47)</sup>

Ferrazzi et al. reported muscular mitral-aortic discontinuity in five young patients with obstructive HCM and sarcomere mutations. A long muscular discontinuity displaced the AML toward the apex and could predispose to the development of LVOT obstruction.<sup>48)</sup> The presence of a muscular band between the two valves has been previously documented in patients with abnormal ventriculoarterial connections, such as the double outlet right ventricle.<sup>49)</sup>

## Conclusion

The AML, PML, papillary muscle, and subvalvular apparatus may play an important role for SAM as well as does the hypertrophic IVS in the majority of patients with obstructive HCM. Anatomical and functional abnormalities of these structures should be recognized precisely with diagnostic imaging, and it is necessary to consider whether LVOT obstruction can be released by treating these abnormalities. Many kinds of surgical



techniques for SAM have been proposed in literature. We should understand the theoretical aspects of each technique on the correction of anatomical and functional abnormalities of these structures and should apply these techniques under proper indication. We hope this review article may help readers' improvement in the surgical management of SAM.

## Disclosure Statement

All authors including spouses and other immediate family members have no financial relationships with commercial manufacturers, pharmaceutical companies, or other commercial entities that have an interest in the subject matter or materials discussed in this manuscript.

## References

- 1) Ro R, Halpern D, Sahn DJ, et al. Vector flow mapping in obstructive hypertrophic cardiomyopathy to assess the relationship of early systolic left ventricular flow and the mitral valve. *J Am Coll Cardiol* 2014; **64**: 1984–95.
- 2) Sherrid MV, Gunsburg DZ, Moldenhauer S, et al. Systolic anterior motion begins at low left ventricular outflow tract velocity in obstructive hypertrophic cardiomyopathy. *J Am Coll Cardiol* 2000; **36**: 1344–54.
- 3) Sherrid MV, Männer J, Swistel DG, et al. On the cardiac loop and its failing: left ventricular outflow tract obstruction. *J Am Heart Assoc* 2020; **9**: e014857.
- 4) Shah PM, Taylor RD, Wong M. Abnormal mitral valve coaptation in hypertrophic obstructive cardiomyopathy: proposed role in systolic anterior motion of mitral valve. *Am J Cardiol* 1981; **48**: 258–62.
- 5) Morrow AG, Brockenbrough EC. Surgical treatment of idiopathic hypertrophic subaortic stenosis: technic and hemodynamic results of subaortic ventriculomyotomy. *Ann Surg* 1961; **154**: 181–9.
- 6) Morrow AG. Hypertrophic subaortic stenosis. Operative methods utilized to relieve left ventricular outflow obstruction. *J Thorac Cardiovasc Surg* 1978; **76**: 423–30.
- 7) Messmer BJ. Extended myectomy for hypertrophic obstructive cardiomyopathy. *Ann Thorac Surg* 1994; **58**: 575–7.
- 8) Schaff HV, Said SM. Transaortic extended septal myectomy for hypertrophic cardiomyopathy. *Oper Tech Thorac Cardiovasc Surg* 2012; **17**: 238–50.
- 9) Usui A, Araki Y, Oshima H, et al. A needle stick technique for septal myectomy for hypertrophic obstructive cardiomyopathy. *Ann Thorac Surg* 2013; **95**: 726–8.
- 10) Klues HG, Roberts WC, Maron BJ. Morphological determinants of echocardiographic patterns of mitral valve systolic anterior motion in obstructive hypertrophic cardiomyopathy. *Circulation* 1993; **87**: 1570–9.
- 11) McIntosh CL, Maron BJ, Cannon RO 3rd, et al. Initial results of combined anterior mitral leaflet plication and ventricular septal myotomy-myectomy for relief of left ventricular outflow tract obstruction in patients with hypertrophic cardiomyopathy. *Circulation* 1992; **86**(Suppl): II60–7.
- 12) Swistel DG, Sherrid MV. The surgical management of obstructive hypertrophic cardiomyopathy: the RPR procedure-resection, plication, release. *Ann Cardiothorac Surg* 2017; **6**: 423–5.
- 13) Sherrid MV, Balamaram S, Kim B, et al. The mitral valve in obstructive hypertrophic cardiomyopathy: a test in context. *J Am Coll Cardiol* 2016; **67**: 1846–58.
- 14) Balamaram SK, Tyrie L, Sherrid MV, et al. Resection-plication-release for hypertrophic cardiomyopathy: clinical and echocardiographic follow-up. *Ann Thorac Surg* 2008; **86**: 1539–44; discussion, 1544–5.
- 15) Noack T, Borger MA. Commentary: prevention of systolic anterior motion after mitral repair in hypertrophic obstructive cardiomyopathy: one simple stitch fits all? *Semin Thorac Cardiovasc Surg* 2020; **32**: 269–70.
- 16) Raney AA, Shah PM, Joyo CI. The 'Pomeroy procedure': a new method to correct post-mitral valve repair systolic anterior motion. *J Heart Valve Dis* 2001; **10**: 307–11.
- 17) Khalpey Z, Shernan SK, Nascimben L, et al. Partial anterior leaflet valvuloplasty to avoid systolic anterior motion after mitral valve repair. *Ann Thorac Surg* 2013; **95**: 1462–3.
- 18) van der Lee C, Kofflard MJM, van Herwerden LA, et al. Sustained improvement after combined anterior mitral leaflet extension and myectomy in hypertrophic obstructive cardiomyopathy. *Circulation* 2003; **108**: 2088–92.
- 19) Vriesendorp PA, Schinkel AFL, Soliman O, et al. Long-term benefit of myectomy and anterior mitral leaflet extension in obstructive hypertrophic cardiomyopathy. *Am J Cardiol* 2015; **115**: 670–5.
- 20) Kofflard MJ, van Herwerden LA, Waldstein DJ, et al. Initial results of combined anterior mitral leaflet extension and myectomy in patients with obstructive hypertrophic cardiomyopathy. *J Am Coll Cardiol* 1996; **28**: 197–202.
- 21) Zhang H, Zhu K, Wang F, et al. Enlargement of left ventricular outflow tract using an autologous pericardial patch for anterior mitral valve leaflet and septal myectomy through trans-mitral approach for the treatment of hypertrophic obstructive cardiomyopathy. *J Card Surg* 2021; **36**: 4198–202.
- 22) Alfieri O, Maisano F, De Bonis M, et al. The double-orifice technique in mitral valve repair: a simple solution for complex problems. *J Thorac Cardiovasc Surg* 2001; **122**: 674–81.

- 23) Myers PO, Khalpey Z, Maloney AM, et al. Edge-to-edge repair for prevention and treatment of mitral valve systolic anterior motion. *J Thorac Cardiovasc Surg* 2013; **146**: 836–40.
- 24) Shah AA, Glower DD, Gaca JG. Trans-aortic Alfieri stitch at the time of septal myectomy for hypertrophic obstructive cardiomyopathy. *J Card Surg* 2016; **31**: 503–6.
- 25) Noack T, Kiefer P, Mallon L, et al. Changes in dynamic mitral valve geometry during percutaneous edge-edge mitral valve repair with the MitraClip system. *J Echocardiogr* 2019; **17**: 84–94.
- 26) Pereda D, Topilsky Y, Nishimura RA, et al. Asymmetric Alfieri's stitch to correct systolic anterior motion after mitral valve repair. *Eur J Cardiothorac Surg* 2011; **39**: 779–81.
- 27) Delmo Walter EM, Javier MF, Hetzer R. Long-term outcome of simultaneous septal myectomy and anterior mitral leaflet retention plasty in hypertrophic obstructive cardiomyopathy: the Berlin experience. *Ann Cardiothorac Surg* 2017; **6**: 343–52.
- 28) Mutsuga M, Narita Y, Usui A. A floating stitch on the anterior mitral leaflet can eliminate systolic anterior motion in hypertrophic obstructive cardiomyopathy. *Semin Thorac Cardiovasc Surg* 2020; **32**: 266–8.
- 29) Tokuda Y, Fujimoto K, Narita Y, et al. Sutures on the anterior mitral leaflet to prevent systolic anterior motion. *Ann Thorac Surg* 2021; **111**: e213–5.
- 30) Kassem S, Jamil H. Papillary muscle-to-anterior annulus stitches: another technique to prevent systolic anterior motion after mitral valve repair. *J Thorac Cardiovasc Surg* 2011; **142**: 1278–81.
- 31) Kassem S. Paradoxical stitches aim to discipline the anterior leaflet to avoid postplasty systolic anterior motion. *J Thorac Cardiovasc Surg* 2013; **145**: 893–5.
- 32) Sternik L, Zehr KJ. Systolic anterior motion of the mitral valve after mitral valve repair: a method of prevention. *Tex Heart Inst J* 2005; **32**: 47–9.
- 33) Alfieri O, Lapenna E. Systolic anterior motion after mitral valve repair: where do we stand in 2015? *Eur J Cardiothorac Surg* 2015; **48**: 344–6.
- 34) Kudo M, Yozu R, Kokaji K, et al. A simple method of prevention for systolic anterior motion in mitral valve repair by loop technique method. *Ann Thorac Surg* 2009; **87**: 324–5.
- 35) Varghese R, Itagaki S, Anyanwu AC, et al. Predicting systolic anterior motion after mitral valve reconstruction: using intraoperative transoesophageal echocardiography to identify those at greatest risk. *Eur J Cardiothorac Surg* 2014; **45**: 132–7; discussion, 137–8.
- 36) Said SM, Schaff HV, Suri RM, et al. Bulging subaortic septum: an important risk factor for systolic anterior motion after mitral valve repair. *Ann Thorac Surg* 2011; **91**: 1427–32.
- 37) George KM, Gillinov AM. Posterior leaflet shortening to correct systolic anterior motion after mitral valve repair. *Ann Thorac Surg* 2008; **86**: 1699–700.
- 38) Kwon DH, Smedira NG, Thamilarasan M, et al. Characteristics and surgical outcomes of symptomatic patients with hypertrophic cardiomyopathy with abnormal papillary muscle morphology undergoing papillary muscle reorientation. *J Thorac Cardiovasc Surg* 2010; **140**: 317–24.
- 39) Sakaguchi T, Hiraoka A, Ryomoto M, et al. Papillary muscle reorientation for systolic anterior motion after mitral valve repair. *Ann Thorac Surg* 2021; **111**: e305–7.
- 40) Maron MS, Olivotto I, Harrigan C, et al. Mitral valve abnormalities identified by cardiovascular magnetic resonance represent a primary phenotypic expression of hypertrophic cardiomyopathy. *Circulation* 2011; **124**: 40–7.
- 41) Affronti A, Pruna-Guillen R, Sandoval E, et al. Surgery for hypertrophic obstructive cardiomyopathy: comprehensive LVOT management beyond septal myectomy. *J Clin Med* 2021; **10**: 4397–409.
- 42) Levine RA, Vlahakes GJ, Lefebvre X, et al. Papillary muscle displacement causes systolic anterior motion of the mitral valve. Experimental validation and insights into the mechanism of subaortic obstruction. *Circulation* 1995; **91**: 1189–95.
- 43) Halpern DG, Swistel DG, Po JR, et al. Echocardiography before and after resect-plicate-release surgical myectomy for obstructive hypertrophic cardiomyopathy. *J Am Soc Echocardiogr* 2015; **28**: 1318–28.
- 44) Mutsuga M, Tokuda Y, Fujimoto K, et al. Surgery for anomalous papillary muscle directly into the anterior mitral leaflet. *Ann Thorac Surg* 2021; **111**: 1512–8.
- 45) Messas E, Guerrero JL, Handschumacher MD, et al. Chordal cutting: a new therapeutic approach for ischemic mitral regurgitation. *Circulation* 2001; **104**: 1958–63.
- 46) Ferrazzi P, Spirito P, Iacovoni A, et al. Transaortic chordal cutting: mitral valve repair for obstructive hypertrophic cardiomyopathy with mild septal hypertrophy. *J Am Coll Cardiol* 2015; **66**: 1687–96.
- 47) Roshanali F, Naderan M, Shoar S, et al. Length of second-order chordae as a predictor of systolic anterior motion of the mitral valve. *Interact Cardiovasc Thorac Surg* 2016; **23**: 280–5.
- 48) Ferrazzi P, Spirito P, Binaco I, et al. Congenital muscular mitral-aortic discontinuity identified in patients with obstructive hypertrophic cardiomyopathy. *J Am Coll Cardiol* 2020; **76**: 2238–47.
- 49) French JW, Popp R. Variability of echocardiographic discontinuity in double outlet right ventricle and truncus arteriosus. *Circulation* 1975; **51**: 848–54.