

Single Case

Sarcomatoid Tumor following Radium Treatment

Wahida Chakari^a Anette Pedersen Pilt^b Jørgen Lock-Andersen^a

^aDepartment of Plastic and Breast Surgery, Zealand University Hospital, Roskilde, Denmark; ^bDepartment of Pathology, Zealand University Hospital, Roskilde, Denmark

Keywords

Sarcomatoid carcinoma · Radium treatment · Haemangioma · Sarcoma · Squamous cell carcinoma

Abstract

Haemangiomas are benign skin lesions that usually regress spontaneously, but radiotherapy has previously been used to assist the regression and healing of the lesions. Radium and X-rays were used as a treatment for benign skin lesions such as haemangioma until the carcinogenic effect of ionising radiation in humans was described. We report a patient diagnosed with a sarcomatoid carcinoma. Her past history was of particular interest since she had received radium treatment for a haemangioma at the same location more than 70 years before.

© 2018 The Author(s)
Published by S. Karger AG, Basel

Introduction

Haemangiomas are benign skin lesions that usually occur in early childhood. The skin tumours typically regress spontaneously, but radiotherapy has previously been used to assist the regression and healing of the lesions. From the 1920s to the late 1950s, ionising radiation was used as a treatment for benign skin lesions such as haemangioma [1, 2]. Radium and X-rays were used to treat the lesions. A wide range of techniques for the treatment have been described. Radium treatments were performed by placing flat applicators, tubes, or

needles on the haemangioma. The needles and tubes were placed in glass cases that were then placed onto the skin with a distance of 4–5 mm. The applicators were arranged in one or two rows and would usually cover the lesion with some margin.

Radium treatment for benign skin lesions was stopped in the late 1950s, and today the carcinogenic effect of ionising radiation is well known and extensively studied [2]. We present the case of an 81-year-old woman diagnosed with a sarcomatoid carcinoma. Her past history was of particular interest since she had received radium treatment for a haemangioma at the same location more than 70 years before at Radiumstation, Aarhus, Denmark.

Case Report

In September 2016, an 81-year-old woman presented with a suspect skin lesion on the ventral side of her left forearm. The patient had no prior history of skin cancer, but had received radiation treatment for a birthmark or haemangioma at the same location at the age of 4 years. Unfortunately no medical records of the patient's radium treatment could be found. She had always had a reddish pigmentation left at the spot (Fig. 1), but she had recently developed an ulcer in the area that would not heal. Upon examination, there was a 10 × 15 mm superficial skin lesion with an ulcer on the skin of the ventral side of the left forearm. The element was excised with a 5-mm margin and sent to pathological examination. The pathology report showed a mixed tumour with sarcoma and carcinoma component, resulting in the diagnosis of sarcomatoid carcinoma (Fig. 2). According to the pathologist the tumour fell under the classification of pleomorphic undifferentiated sarcoma. The case was discussed with the sarcoma team, which suggested re-excision with a 3-cm margin and post-operative radiotherapy. Furthermore, the patient underwent a PET-CT scan that showed a malignant suspicious process in the right liver lobe, thickening of the colon ascendens wall, and several enlarged lymph nodes over and under the diaphragm and the left inguinal area. A biopsy of the liver showed metastasis from adenocarcinoma with the colon as the possible origin. Furthermore, an enlarged lymph node from the left inguinal area was extirpated and the pathology report revealed chronic lymphatic leukaemia. Biopsies taken from the colon through colonoscopy showed adenocarcinoma with metastasis to the liver. The patient underwent surgery and chemotherapy, and her latest PET-CT scans from September 2017 showed complete remission of her cancer. Additionally, her chronic lymphatic leukaemia was in a chronic stage and she did not have to receive treatment for it. The patient is alive and is still followed up for her cancer diseases.

Discussion

The carcinogenic effect of ionising radiation in humans has been widely studied. The first reports of radium directly causing a skin lesion date back to 1900 and are authored by the Germans Friedrich Walkhoff and Friedrich Giesel. In the early years following the discovery of radium, most of the studies were carried out in Europe. The Americans began to experiment with radium a bit later since radium sources were rare in the United States. Dr. George H. Stover was amongst the first Americans to investigate the effects of self-exposure to radium. This resulted in a great number of cutaneous neoplasms [3].

Ionising radiation is a well-known risk factor in the development of cutaneous squamous cell carcinoma [4]. Furthermore, radium treatment for benign skin lesions has been

linked to an increased risk of sarcoma of the bone [5]. In our case, the patient presented with a mixed tumour of carcinoma and sarcoma at the same site where she had received radium treatment. The fact that she developed the malignancy at the same location raises the suspicion that the previous radium treatment caused it. A cohort study carried out in Sweden during late 1980s investigated the carcinogenic effects of ionising radiation in infancy. Approximately 12,000 children treated with radium-226 for haemangioma were traced back and followed up in the Swedish Cancer Register for incident cancer cases. The study showed a slight but significant excess of neoplasms in this population [6]. Our patient was simultaneously diagnosed with colon cancer and chronic lymphatic leukaemia, which raises the suspicion back to the patient's previous radiotherapy that could also have caused an overall carcinogenic effect.

Radium treatment for benign lesions is not carried out anymore, but radium is still being used for medical purposes. An example is the use of the radium-223 isotope. It is used as an intravenous treatment for painful osteoblastic metastases from prostate cancer. Recently, a case report describing a patient who had developed a cutaneous squamous cell carcinoma due to extravasation of intravenous radium-223 was published [7]. The patient presented with a hyperkeratotic lesion on the dorsal side of the left hand at the site of the previous injection of radium. It is also important to highlight that this was the isotope radium-223, which has a half-life of 11.4 days, and our patient was likely treated with radium-226, which has a half-life of 1,600 years.

Modern reports involving skin lesions caused by radium are rare. However, Bhatt et al. [8] presented a case report of an elderly patient who had developed bilateral basal cell carcinoma of the lower eyelid following radium treatment for bilateral blepharitis in her childhood. With this case report, we would like to outline the importance of taking a good medical history, with focus on risk factors such as previous expositions to ionising radiation. We still have a population from the era when benign skin lesions were treated with radium.

Statement of Ethics

Patient consent for publication has been obtained.

Disclosure Statement

The authors have no conflicts of interest to disclose.

References

- 1 Lundell M, Furst CJ, Hedlund B, Holm LE: Radium treatment for hemangioma in early childhood. Reconstruction and dosimetry of treatments, 1920–1959. *Acta Oncol* 1990;29:551–556.
- 2 Lyngbye J: Behandling Med Radioaktive Stråler; in Anonymous, Lyssagen – Niels Finsen Og Hans Team på Finseninstituttet (ed 1). Copenhagen, Nordisk Forlag, 2003, pp 155–156.
- 3 Mould RF: Invited review: the early years of radiotherapy with emphasis on X-ray and radium apparatus. *Br J Radiol* 1995;68:567–582.
- 4 Lichter MD, Karagas MR, Mott LA, Spencer SK, Stukel TA, Greenberg ER: Therapeutic ionizing radiation and the incidence of basal cell carcinoma and squamous cell carcinoma. The New Hampshire Skin Cancer Study Group. *Arch Dermatol* 2000;136:1007–1011.
- 5 Hutchison GB: Late neoplastic changes following medical irradiation. *Cancer* 1976;37(2 suppl):1102–1110.

- 6 Lindberg S, Karlsson P, Arvidsson B, Holmberg E, Lunberg LM, Wallgren A: Cancer incidence after radiotherapy for skin haemangioma during infancy. *Acta Oncol* 1995;34:735–740.
- 7 Benjegerdes KE, Brown SC, Housewright CD: Focal cutaneous squamous cell carcinoma following radium-223 extravasation. *Proc (Bayl Univ Med Cent)* 2017;30:78–79.
- 8 Bhatt PR, Al-Nuaimi D, Raines MF: Bilateral basal cell carcinoma of the lower eyelids following radium treatment for blepharitis. *Eye (Lond)* 2008;22:980–981.

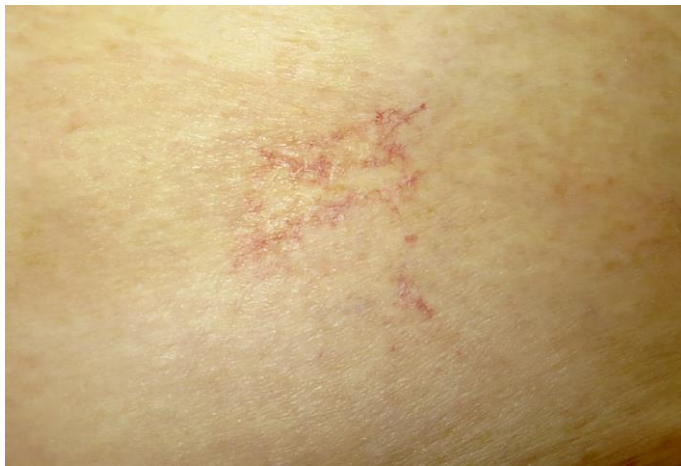

Fig. 1. The patient had a reddish pigmentation left at the spot similar to this one. She had also received radium treatment for haemangioma at this site on the lower part of her abdomen.

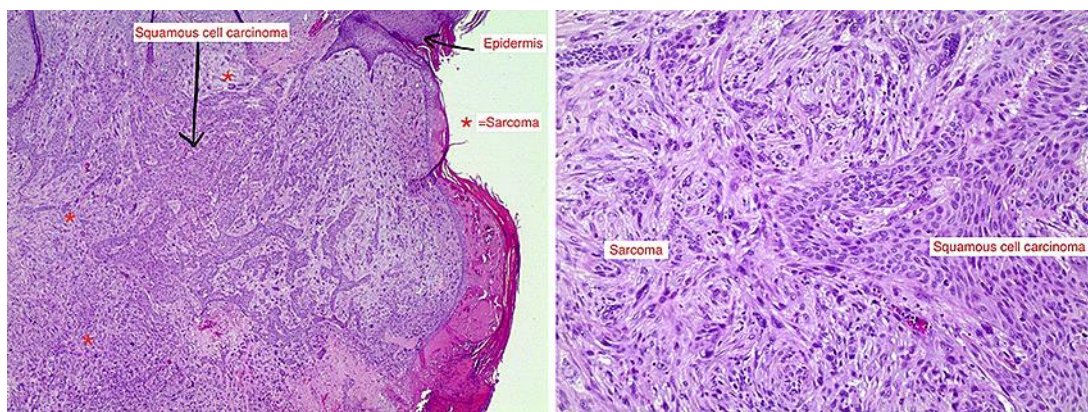


Fig. 2. Skin excision with ulcerated biphasic tumour, with components of squamous cell carcinoma and undifferentiated sarcoma.