

Endoscopic Posterior Ankle Decompression and Release After Total Ankle Arthroplasty



Tun Hing Lui, M.B.B.S. (HK), F.R.C.S. (Edin), F.H.K.A.M., F.H.K.C.O.S.,
Wing Sum Li, M.B.Ch.B., and

Hoi Yan Lam, M.B.B.S. (HK), M.R.C.S.Ed., F.R.C.S.Ed. (Orth), F.H.K.C.O.S., F.H.K.A.M.

Abstract: Accurate positioning of the total ankle arthroplasty implant components with the absence of any hindfoot deformity does not preclude the development of bony impingement. In cases of ankle stiffness after total ankle arthroplasty, the usual limitation is in dorsiflexion. If triceps surae contracture is excluded or persistent restriction remains in ankle dorsiflexion after gastrocnemius recession or tendo-Achilles lengthening, posterior ankle capsulectomy, debridement of posterior ankle gutter, and release of the deep posterior deltoid ligament and the posterior talofibular ligament are indicated. In this Technical Note, the technical details of endoscopic posterior ankle decompression and release after total ankle arthroplasty are described.

The aim of total ankle arthroplasty (TAA) is to restore a pain-free mobile and stable ankle. Despite high satisfaction rates reported in the literature, the incidence of postoperative residual pain after TAA ranges between 23% and 60% and has been attributed to a series of etiologies: (1) pre-existing or under-corrected hindfoot deformities; (2) inaccurate positioning of the implant components; (3) instability of the hindfoot; and (4) impingement.¹ Accurate positioning of the implant components with the absence of any hindfoot deformity does not preclude the development of bony impingement.¹ In cases of ankle stiffness after TAA, the usual limitation is in dorsiflexion.² If triceps surae contracture is excluded or persistent restriction remains in ankle dorsiflexion after gastrocnemius recession or tendo-Achilles lengthening, posterior ankle

capsulectomy, debridement of posterior ankle gutter, and release of the deep posterior deltoid ligament and the posterior talofibular ligament are indicated.^{2,3}

The purpose of this Technical Note is to describe the details of endoscopic posterior ankle decompression and release after total ankle arthroplasty. It is indicated for soft-tissue and/or osseous impingement of the posterior ankle gutter and limited ankle dorsiflexion motion. Heterotopic ossification occurs most commonly in the posterior gutter and can present as posterior ankle pain and limited ankle plantar flexion and dorsiflexion.² However, the occurrence of heterotopic ossification may not correlate with clinical symptoms even if there is evidence of radiologic posterior impingement. Arthroscopic resection is only indicated when there are corresponding symptoms.² The procedure is contraindicated in cases of limited ankle motion as a result of tight triceps surae, improper positioning of the prosthesis in the sagittal plane, or subsidence of its component.² It is also contraindicated in cases of implant loosening, dislocation, osteolysis, or infection needing revision (Table 1).

Technique

Preoperative Planning and Patient Positioning

A detailed history and physical examination are essential to a successful diagnosis. Weight-bearing radiographs of the involved ankle are important to assess the overall alignment of the ankle and any malpositioning, loosening or subsidence, oversizing or

From the Department of Orthopaedics and Traumatology (T.H.L.), North District Hospital (W.S.L., T.H.L.); and Department of Orthopaedics and Traumatology, Alice Ho Miu Ling Nethersole Hospital (H.Y.L.), Hong Kong SAR, China.

The authors report that they have no conflicts of interest in the authorship and publication of this article. Full ICMJE author disclosure forms are available for this article online, as [supplementary material](#).

Address correspondence to Dr. T. H. Lui, Department of Orthopaedics and Traumatology, North District Hospital, 9 Po Kin Rd., Sheung Shui, NT, Hong Kong SAR, China. E-mail: luithderek@yahoo.co.

© 2022 THE AUTHORS. Published by Elsevier Inc. on behalf of the Arthroscopy Association of North America. This is an open access article under the CC BY-NC-ND license (<http://creativecommons.org/licenses/by-nc-nd/4.0/>).

2212-6287/211851

<https://doi.org/10.1016/j.eats.2022.01.001>

Table 1. Indications and Contraindications of Endoscopic Posterior Ankle Decompression and Release After Total Ankle Arthroplasty

Indications	Contraindications
1. Soft-tissue and/or osseous impingement of the posterior ankle gutter and limited ankle dorsiflexion motion.	1. The presence of heterotopic ossification in the posterior gutter without corresponding posterior ankle impingement symptoms.
	2. Limited ankle motion as a result of tight triceps surae, improper positioning of the prosthesis in the sagittal plane or subsidence of its component.
	3. Implant loosening, dislocation, osteolysis, or infection needing revision

undersizing of the TAA components, and the presence of heterotopic ossifications. Lateral radiographs with the ankle maximally plantarflexed and dorsiflexed can be used to assess the motion arc of the arthroplasty and detect any abnormal anteroposterior translational motion of the talar component related to the tibial component. Any posterior ankle bony impingement should be noted.

The patient is placed in the prone position and an ipsilateral thigh tourniquet is used to provide a bloodless surgical field. Fluid inflow is driven by gravity, an arthro-pump is not used, and a 4.0-mm, 30° arthroscope (DYONICS; Smith & Nephew, Andover, MA) is used. In this illustrated case, the patient had left Scandinavian Total Ankle Replacement (STAR Ankle; Stryker, Kalamazoo, MI) done and suffered from limited ankle dorsiflexion with posterior ankle pain.

Portal Placement

The procedure is performed via the posteromedial and posterolateral portals. The posterolateral portal is at the lateral side of the Achilles tendon, just above the posterosuperior calcaneal tubercle. The posteromedial portal is at the intersection point between the medial border of the Achilles tendon and the line joining the undersurface of the first metatarsal and sustentaculum tali (Fig 1).^{4,5} The posteromedial portal is established more proximal than the posterolateral portal in order to reduce the risk of injury to the tibial neurovascular bundle by instrumentation via the posteromedial portal.⁵

Identification of the Flexor Hallucis Longus Tendon

The posteromedial portal is the viewing portal and the posterolateral portal is the working portal. The soft tissue of the posterolateral ankle is carefully dissected with an arthroscopic shaver (DYONICS; Smith &

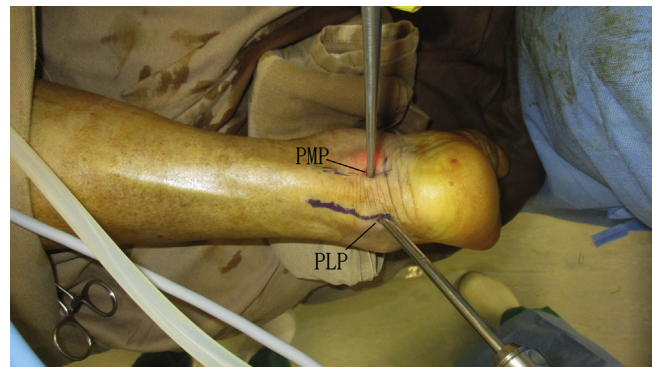


Fig 1. Endoscopic posterior ankle decompression and release after total ankle arthroplasty of the left ankle. The patient is in the prone position. The procedure is performed via the posteromedial and posterolateral portals. The posterolateral portal is at the lateral side of the Achilles tendon, just above the posterosuperior calcaneal tubercle. The posteromedial portal is at the intersection point between the medial border of the Achilles tendon and the line joining the undersurface of the first metatarsal and sustentaculum tali. (PLP, posterolateral portal; PMP, posteromedial portal.)

Nephew) until the flexor hallucis longus tendon is identified (Fig 2).

Decompression and Release of Lateral Half of the Posterior Ankle Gutter

The posterolateral portal is the viewing portal and the posteromedial portal is the working portal. The

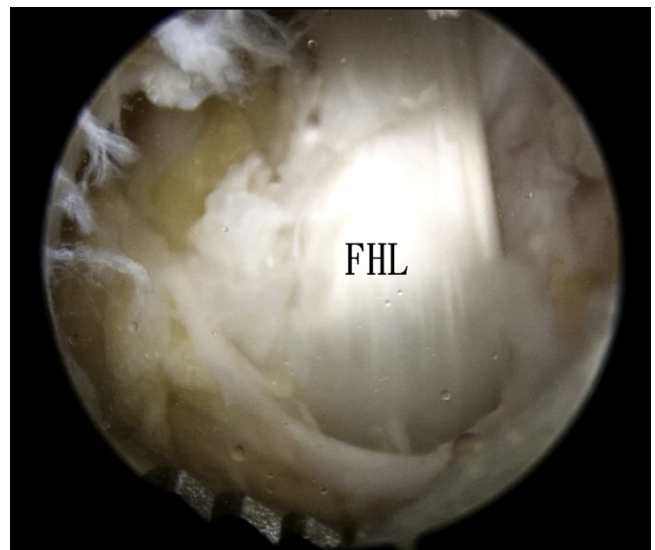


Fig 2. Endoscopic posterior ankle decompression and release after total ankle arthroplasty of the left ankle. The patient is in the prone position. The posteromedial portal is the viewing portal and the posterolateral portal is the working portal. The soft tissue of the posterolateral ankle is carefully dissected with an arthroscopic shaver (DYONICS; Smith & Nephew) until the flexor hallucis longus tendon is identified. (FHL, flexor hallucis longus tendon.)

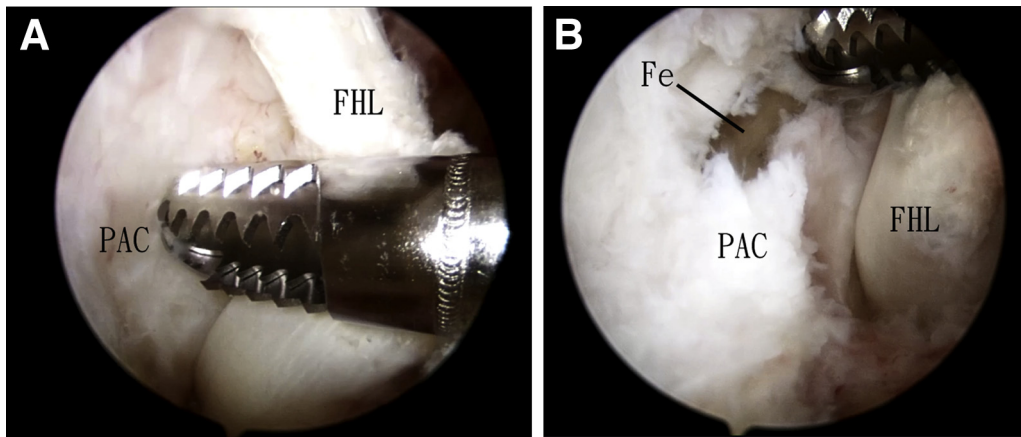


Fig 3. Endoscopic posterior ankle decompression and release after total ankle arthroplasty of the left ankle. The patient is in the prone position. The posterolateral portal is the viewing portal and the posteromedial portal is the working portal. (A) The working area is at the lateral side of the flexor hallucis longus tendon. (B) The posterior ankle capsule lateral to the flexor hallucis longus tendon is fenestrated by the arthroscopic shaver. (Fe, fenestration of the posterior ankle capsule; FHL, flexor hallucis longus tendon; PAC, posterior ankle capsule.)

posterior ankle capsule lateral to the flexor hallucis longus tendon is fenestrated by the arthroscopic shaver (Fig 3). The thick fibrotic posterior ankle capsule is released with an arthroscopic probe (ACUFEX; Smith & Nephew) and arthroscopic scissors (ACUFEX; Smith & Nephew) and is resected with the arthroscopic shaver and Kerrison rongeur (Integra, Plainsboro, NJ). The working area is at the lateral side of the flexor hallucis longus tendon. The tendon can be pushed medially by the arthroscopic instrument to facilitate resection of the more medial posterior ankle capsule. The flexor hallucis longus tendon protects the tibial neurovascular bundle from injury by the arthroscopic instruments. The scarred capsule should be resected down to the TAA prosthesis, but caution should be paid not to injure the prosthesis. Heterotopic ossifications, if present, also should be resected.

After that, the arthroscope is switched to the posteromedial portal. The most lateral part of the posterior ankle capsule is resected with the arthroscopic shaver and arthroscopic radiofrequency wand (Smith & Nephew) (Fig 4).

Looping the Flexor Hallucis Longus Tendon With a Vascular Sling

The posteromedial portal is the viewing portal and the posterolateral portal is the working portal. The flexor hallucis longus tendon is looped with a vascular sling via the posterolateral portal (Fig 5).

Decompression and Release of Medial Half of the Posterior Ankle Gutter

The flexor hallucis longus tendon is retracted laterally by the sling to expose the medial part of the posterior ankle capsule. The posterolateral portal is the viewing

portal and the posteromedial portal is the working portal. The medial part of the posterior ankle capsule is dissected with a hemostat and serrated banana knife (ACUFEX; Smith & Nephew) and is resected with the arthroscopic shaver and Kerrison rongeur (Fig 6). Heterotopic ossifications, if present, should also be resected.

Decompression of the Posteromedial Ankle Gutter

The posterolateral portal is the viewing portal and the posteromedial portal is the working portal. The

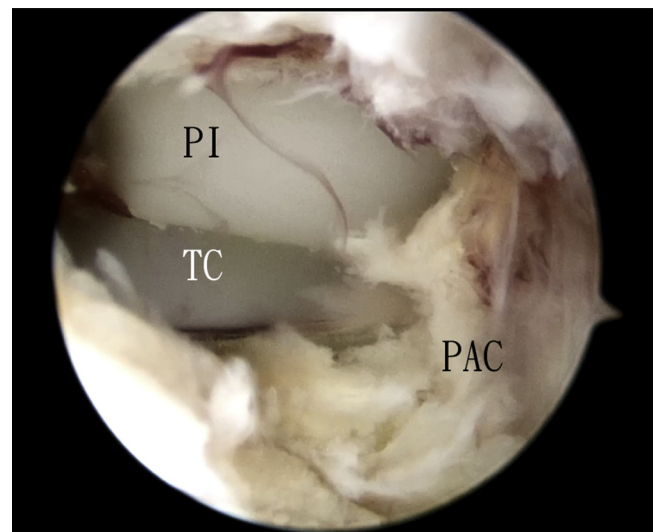


Fig 4. Endoscopic posterior ankle decompression and release after total ankle arthroplasty of the left ankle. The patient is in the prone position. The posteromedial portal is the viewing portal. The lateral part of the total ankle arthroplasty is exposed. (PAC, posterior ankle capsule; PI, polyethylene insert; TC, talar component.)

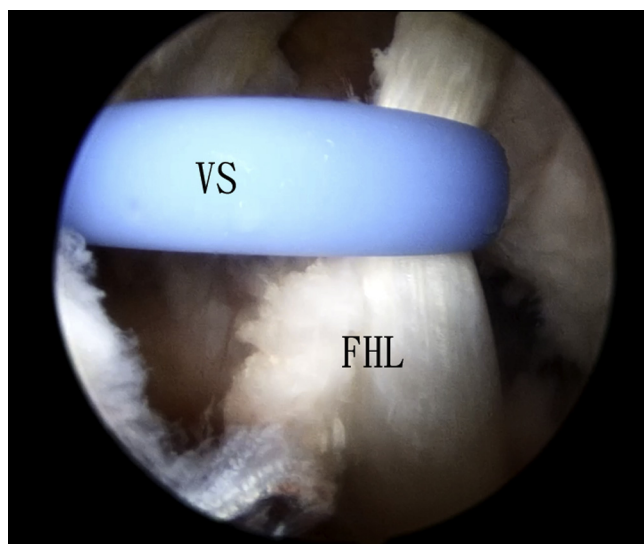


Fig 5. Endoscopic posterior ankle decompression and release after total ankle arthroplasty of the left ankle. The patient is in the prone position. The posteromedial portal is the viewing portal and the posterolateral portal is the working portal. The flexor hallucis longus tendon is looped with a vascular sling via the posterolateral portal. (FHL, flexor hallucis longus tendon; VS, vascular sling.)

fibrous tissue at the posteromedial ankle gutter is released with an arthroscopic probe and is resected with the arthroscopic shaver with the shaver blade facing away from the prosthesis (Fig 7). The ankle is slightly plantarflexed to relax the tibial neurovascular bundle and reduce the risk of impingement injury of the bundle by the shaft of arthroscopic instruments via the posteromedial portal.⁶ Medial malleolus can be burred if bony impingement is present.

Decompression of the Posterolateral Ankle Gutter

The posteromedial portal is the viewing portal and the posterolateral portal is the working portal. The fibrous tissue at the posterolateral ankle gutter is released with an arthroscopic probe and resected with the arthroscopic shaver with the shaver blade facing away from the prosthesis (Fig 8). Lateral malleolus can be burred if bony impingement is present.

The ankle dorsiflexion range of motion is checked after complete posterior ankle capsulectomy. If 5° to 10° ankle dorsiflexion cannot be achieved, release of the posterolateral and posteromedial ankle ligamentous structures is performed.

Release of Posterolateral Ankle Ligamentous Structure

The posteromedial portal is the viewing portal and the posterolateral portal is the working portal. The scarred posterolateral ankle ligamentous structure and fibrous

band is released from its calcaneal insertion by the serrated banana knife (Fig 9).

Release of Posteromedial Ankle Ligamentous Structure

The posterolateral portal is the viewing portal and the posteromedial portal is the working portal. The scarred posteromedial ankle ligamentous structure and fibrous band is carefully dissected with a hemostat and cut by a No. 15 scalpel with the cutting blade facing laterally. The release is completed when the flexor digitorum longus tendon and the tibial neurovascular bundle is exposed (Fig 10, Video 1, Table 2). Postoperatively,

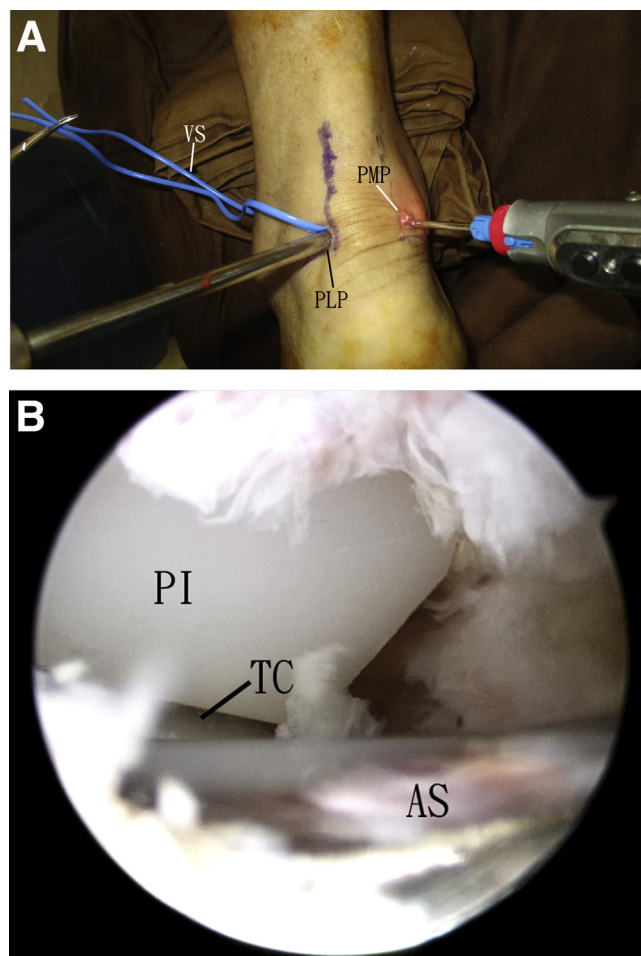


Fig 6. Endoscopic posterior ankle decompression and release after total ankle arthroplasty of the left ankle. The patient is in the prone position. (A) The vascular sling is in the posterolateral portal. (B) The posterolateral portal is the viewing portal and the posteromedial portal is the working portal. The medial part of the posterior ankle capsule is resected. (AS, arthroscopic shaver; PI, polyethylene insert; PLP, posterolateral portal; PMP, posteromedial portal; TC, talar component; VS, vascular sling.)

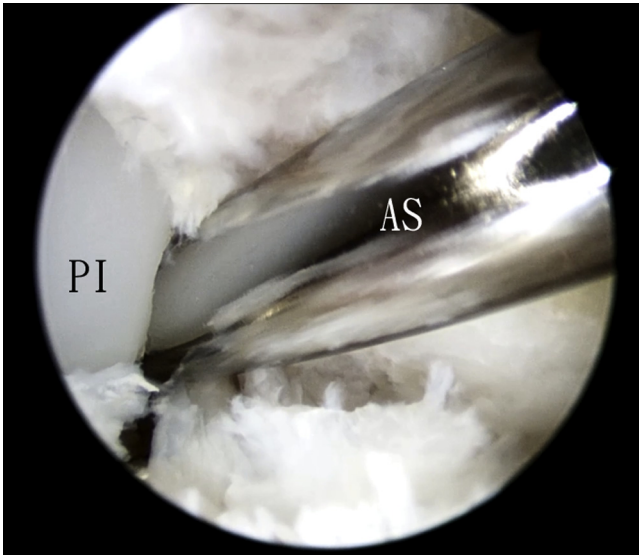


Fig 7. Endoscopic posterior ankle decompression and release after total ankle arthroplasty of the left ankle. The patient is in the prone position. The posterolateral portal is the viewing portal and the posteromedial portal is the working portal. The fibrous tissue at the posteromedial ankle gutter is released with an arthroscopic probe and is resected with the arthroscopic shaver with the shaver blade facing away from the prosthesis. (AS, arthroscopic shaver; PI, polyethylene insert.)

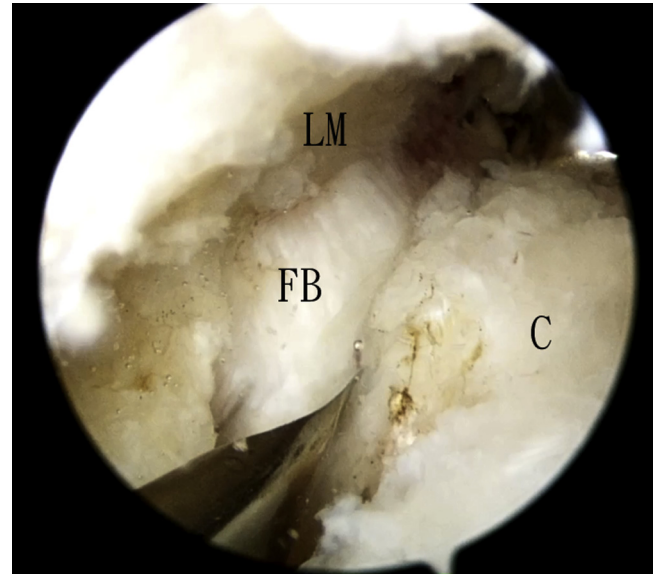


Fig 9. Endoscopic posterior ankle decompression and release after total ankle arthroplasty of the left ankle. The patient is in the prone position. The posteromedial portal is the viewing portal and the posterolateral portal is the working portal. The scarred posterolateral ankle ligamentous structure and fibrous band is released from its calcaneal insertion by the serrated banana knife. (C, calcaneus; FB, fibrous band; LM, lateral malleolus.)

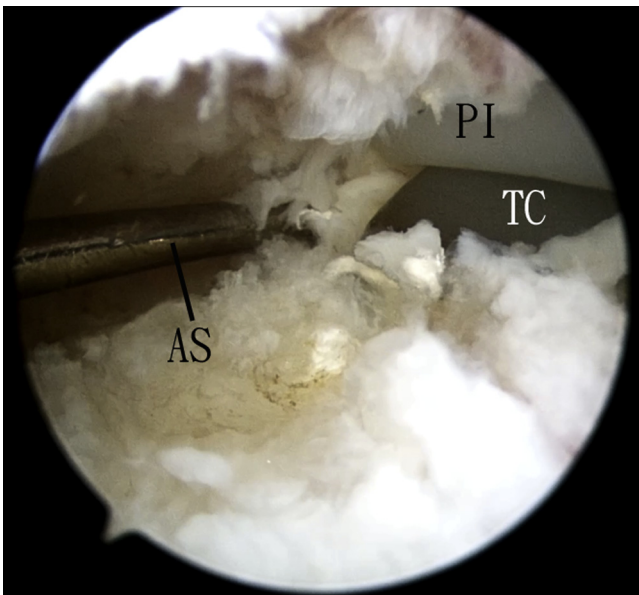


Fig 8. Endoscopic posterior ankle decompression and release after total ankle arthroplasty of the left ankle. The patient is in the prone position. The posteromedial portal is the viewing portal and the posterolateral portal is the working portal. The fibrous tissue at the posterolateral ankle gutter is released with an arthroscopic probe and resected with the arthroscopic shaver with the shaver blade facing away from the prosthesis. (AS, arthroscopic shaver; PI, polyethylene insert; TC, talar component.)

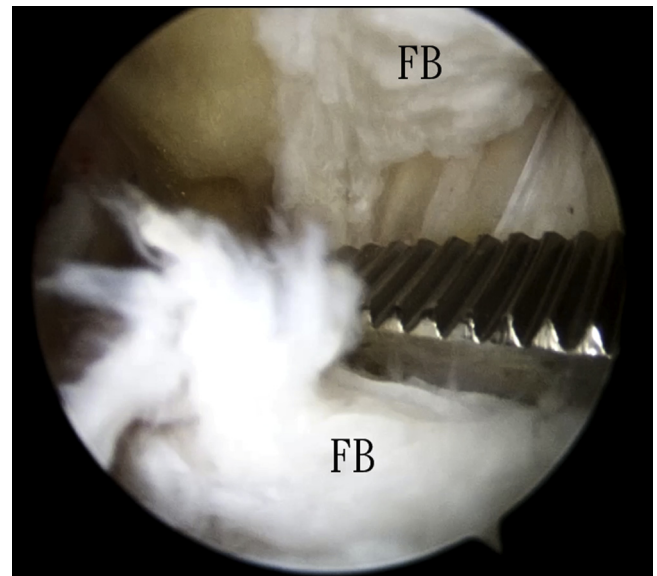


Fig 10. Endoscopic posterior ankle decompression and release after total ankle arthroplasty of the left ankle. The patient is in the prone position. The posterolateral portal is the viewing portal and the posteromedial portal is the working portal. The scarred posteromedial ankle ligamentous structure and fibrous band is carefully cut by a No. 15 scalpel with the cutting blade facing laterally. The release is completed when the flexor digitorum longus tendon and the tibial neurovascular bundle is exposed. (FB, cut fibrous band.)

Table 2. Pearls and Pitfalls of Endoscopic Posterior Ankle Decompression and Release After Total Ankle Arthroplasty

Pearls	Pitfalls
1) The posteromedial portal is established more proximal than the posterolateral portal.	1) Ankle dorsiflexion to open up the posterior ankle during debridement of the posteromedial ankle will lead to impingement injury to the tibial neurovascular bundle by the arthroscopic instrument during debridement of the posteromedial ankle.
2) Arthroscopic probe is useful to dissect the deep part of the posterior capsule from the TAA prosthesis before capsulectomy.	
3) The ankle should be slightly plantarflexed to relax the tibial neurovascular bundle during procedures of the posteromedial ankle.	

TAA, total ankle arthroplasty.

immediate free ankle mobilization and weight bearing as pain tolerated is allowed.

Discussion

Besides posterior ankle endoscopy, posterior ankle arthroscopy with coaxial portals can be used in cases of soft-tissue impingement. It is especially useful if concomitant anterior ankle arthroscopy is indicated, such as debridement of the medial and/or lateral gutter. This procedure can avoid change of position during the operation and minimize the risk of infection.² In cases of dense scar tissue in the posterior gutter, forceful introduction of arthroscope and arthroscopic instruments into the posterior ankle gutter will cause damage to the TAA components.² In case of posterior ankle pain associated with limited ankle dorsiflexion, posterior ankle endoscopy is preferred as dense scar tissue of posterior ankle gutter is expected. Moreover, posterior ankle arthroscopy cannot deal with the fibrotic extra-articular posteromedial and posterolateral ligamentous structures.²

A study showed that for most of the patients with a painful ankylosis with or without an impingement

syndrome, the pain was only partially relieved by arthroscopic debridement.¹ This may be attributed to incomplete debridement of the posterior ankle by arthroscopic technique. Endoscopic approach provides a more comprehensive access to the intra-articular and extra-articular structures of the posterior ankle and allows more complete debridement and release.

This minimally invasive technique has the advantage of less soft-tissue trauma, better cosmetic results, fewer wound complications, more comprehensive access to both intra-articular and extra-articular structures of the posterior ankle and immediate post-operative weight-bearing and ankle mobilization is allowed. The potential risks of this technique include incomplete debridement and injury to the TAA components, flexor hallucis longus tendon and tibial neurovascular bundle (Table 3). This is technically demanding and should be reserved for the experienced foot and ankle arthroscopists.

References

1. Bevernage BD, Deleu PA, Birch I, Gombault V, Maldague P, Leemrijse T. Arthroscopic debridement after total ankle arthroplasty. *Foot Ankle Int* 2016;37:142-149.
2. Lui TH, Roukis TS. Arthroscopic management of complications following total ankle replacement. *Clin Podiatr Med Surg* 2015;32:495-508.
3. Gérard R, Unno-Veith F, Fasel J, Stern R, Assal M. The effect of collateral ligament release on ankle dorsiflexion: An anatomical study. *Foot Ankle Surg* 2011;17:193-196.
4. Lui TH. Flexor hallucis longus tendoscopy: A technical note. *Knee Surg Sports Traumatol Arthrosc* 2009;17:107-110.
5. Lui TH, Chan LK. Posterior ankle and hindfoot endoscopy: A cadaveric study. *Foot Ankle Surg* 2016;22:186-190.
6. Lui TH. Lateral plantar nerve neuropraxia after FHL tendoscopy: Case report and anatomic evaluation. *Foot Ankle Int* 2010;31:828-831.

Table 3. Advantages and Risks of Endoscopic Posterior Ankle Decompression and Release After TAA

Advantages	Risks
1) Less soft-tissue trauma	1) Incomplete debridement
2) Better cosmetic results	2) Injury to the TAA components
3) Fewer wound complications	3) Injury to the flexor hallucis longus tendon
4) More comprehensive access to both intra-articular and extra-articular structures of the posterior ankle	4) Injury to the tibial neurovascular bundle
5) Immediate postoperative weight-bearing and ankle mobilization	

TAA, total ankle arthroplasty.