



REVIEW

Multifocal Pyoderma Gangrenosum with an Underlying Hemophagocytic Lymphohistiocytosis: Case Report and the Review of the Literature

Aleksandra Opalińska · Dominika Kwiatkowska · Adrian Burdacki ·
Mirosław Markiewicz · Dominik Samotij · Marek Dudziński ·
Jadwiga Niemiec-Dudek · Elżbieta Ostańska · Adam Reich

Received: December 5, 2020 / Published online: June 27, 2021
© The Author(s) 2021

ABSTRACT

Pyoderma gangrenosum (PG) is an uncommon, serious, ulcerating skin disease of uncertain etiology. It manifests as a noninfectious, progressive necrosis of the skin characterized by sterile neutrophilic infiltrates. It seems to be a disorder of the immune system. PG is associated with certain underlying conditions in at least 50% of cases. Therefore, it is important to look carefully for comorbidities in every patient with PG and treat them adequately to improve the prognosis. Here, we demonstrate a 35-year-old man diagnosed with multifocal PG and hemophagocytic lymphohistiocytosis (HLH) with fatal outcome, despite combined, long-term, intensive dermatological and hematological treatment with high doses of steroids,

cyclosporin, intravenous immunoglobulins (IVIg), HLH-2004 protocol with intravenously administered etoposide, and anakinra. This case is presented owing to the extremely rare coexistence of PG and HLH and the related diagnostic and therapeutic difficulties. It is also worth underlying that the diagnosis of HLH should perhaps be considered in the presence of a high percentage of double-negative T lymphocytes (DNTs) in flow cytometry, after excluding the diagnosis of lymphoma and leukemia. In this article we have also performed and present the critical literature review of local and systemic options in the management of PG lesions based on a detailed search of the PubMed database.

Keywords: Pyoderma gangrenosum; Hemophagocytic lymphohistiocytosis; HLH; Anakinra; Double-negative T lymphocytes; DNTs; Etoposide

A. Opalińska · D. Kwiatkowska · D. Samotij ·
A. Reich (✉)
Department of Dermatology, Institute of Medical
Sciences, Medical College of Rzeszow University,
Szopena 2 Street, 35-055 Rzeszow, Poland
e-mail: adi_medicalis@go2.pl

A. Burdacki · M. Markiewicz · M. Dudziński ·
J. Niemiec-Dudek
Department of Hematology, Institute of Medical
Sciences, Medical College of Rzeszow University,
Rzeszow, Poland

E. Ostańska
Department of Pathomorphology, Institute of
Medical Sciences, Medical College of Rzeszow
University, Rzeszow, Poland

Key Summary Points

Pyoderma gangrenosum (PG) is an uncommon, serious, noninfectious, progressive necrosis of the skin of uncertain etiology.

Hemophagocytic lymphohistiocytosis (HLH) is an aggressive, life-threatening disease characterized by an abnormal immune activation, which leads to excessive inflammation and tissue destruction.

Both PG and HLH may have a potential etiology, including infection, neoplasm (especially hematological malignancy), autoimmune disease, inflammatory bowel disease, chronic hepatitis, etc.

Once the diagnosis of HLH or PG is established, it is necessary to identify the potential etiology in order to adopt the appropriate treatment strategy.

There are no standard therapy options for patients suffering from both PG and HLH.

INTRODUCTION

Pyoderma gangrenosum (PG) is an uncommon, serious, ulcerating skin disease of uncertain etiology. It is a noninfectious, progressive necrosis of the skin, characterized by sterile neutrophilic infiltrates, and appears to be a disorder of the innate immune system. PG is associated with certain underlying conditions in at least 50% of cases [1, 2]. The most common comorbidities are inflammatory bowel diseases, arthritis, and hematological disorders (e.g., myelodysplastic syndrome, monoclonal gammopathy, leukemia, and others). Thus, it is important to look carefully for comorbidities in every patient with PG and treat them adequately. Otherwise, the prognosis for PG may be unfavorable [3, 4]. To date, there are no standardized treatment guidelines for PG. The

therapy of PG usually combines local wound care and systemic immunosuppression based on personal experience, availability of therapy, and comorbidities [5–7].

Hemophagocytic lymphohistiocytosis (HLH) is an aggressive, life-threatening disease characterized by an abnormal immune activation, which leads to excessive inflammation and tissue destruction. Activated macrophages are not properly downregulated and eliminated by cytotoxic lymphocytes and/or NK cells, which are missing or insufficient [8, 9]. They secrete excessive amounts of cytokines (cytokine storm): interferon gamma, tumor necrosis factor alpha, interleukins (IL), and CD25—the soluble IL-2 receptor, leading to tissue damage, multiorgan failure, and eventually death [10]. The unique feature of HLH is hemophagocytosis of host blood cells by activated macrophages. It is diagnosed during microscopic evaluation of bone marrow, immune tissue (lymph node, spleen, liver), or cerebrospinal fluid, when erythrocytes, leukocytes, platelets, or fragments of these cells are present in the cytoplasm of macrophages. The presence of hemophagocytes in the bone marrow may indicate an infectious background [especially viral: Epstein–Barr virus (EBV) or human immunodeficiency virus (HIV), but also bacteria and parasites may play role], as well as a malignancy (lymphoma, leukemia, or solid tumor) or autoimmune disease. There is also primary HLH, which is usually observed in children and is triggered, among others, by the genetic defect in genes encoding effector proteins of cytotoxic lymphocytes and NK cells [11–13]. When HLH is triggered by other disease, treatment of the underlying triggering disease leads to the elimination of stimulus for immune activation. Thus, therapy of patients with secondary HLH should include the treatment of the trigger with simultaneous chemotherapy specific for HLH [14–17]. Here, we have described a patient who concomitantly developed both PG and HLH, underlining how challenging and difficult the proper treatment choice can be. We have also performed and present the critical literature review of local and systemic options in the management of PG lesions based on a detailed search of the PubMed database.

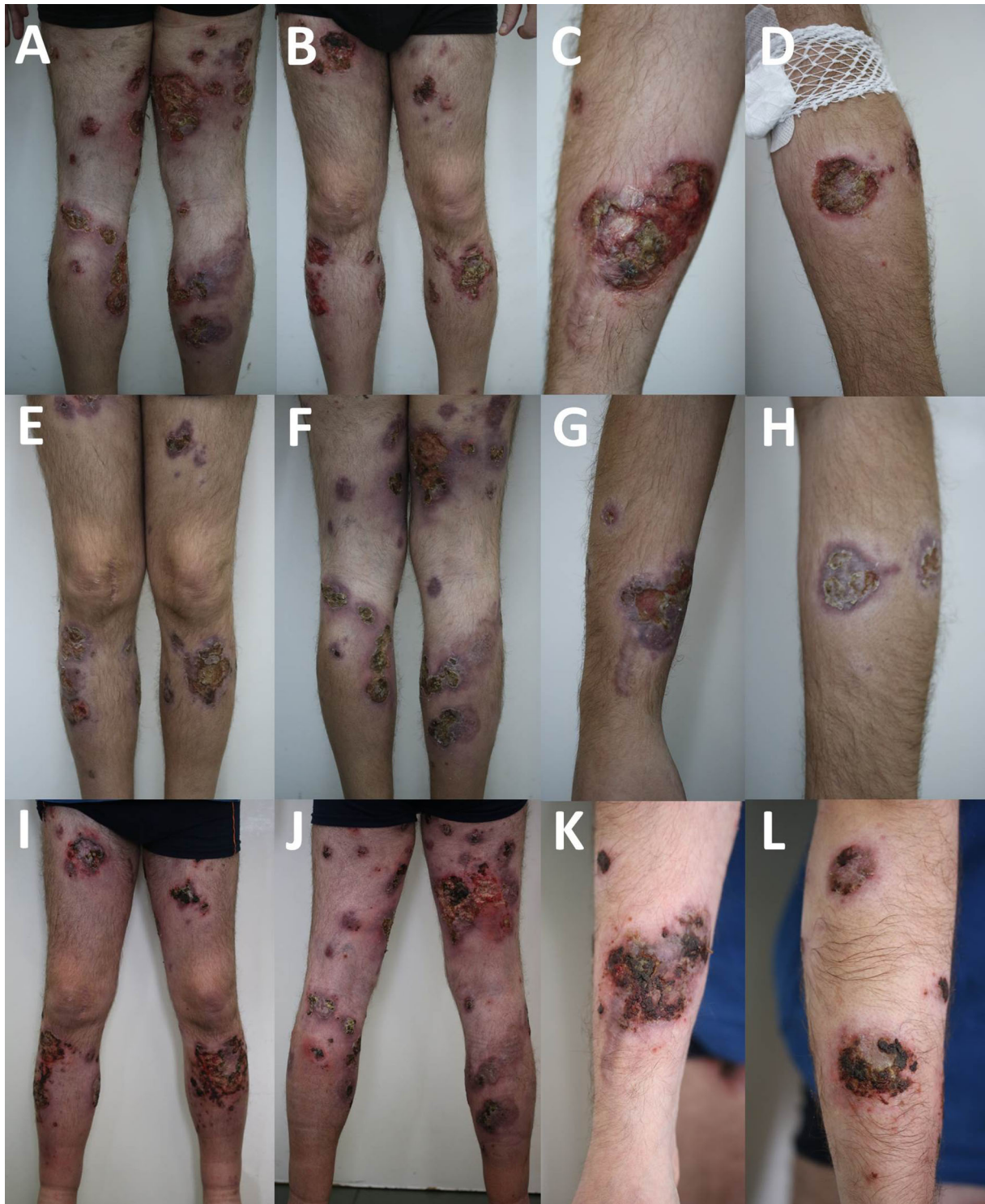

Fig. 1 Multifocal ulcerations in the course of pyoderma gangrenosum on the lower limbs (a, b) and upper limbs (c, d) on the day of admission. e–h The same lesions 2 weeks after intravenous administration of methylprednisolone

followed by prednisone 30 mg and cyclosporin 150 mg twice a day. i–l The same lesions after the second administration of etoposide

CASE REPORT

A 35-year-old man was admitted to the department of dermatology presenting plenty of ulcers with purple and undermined edges, located on the upper and lower limbs (Fig. 1a–d; Informed consent for publication, including publication of the images within the article was obtained from the patient). Five months earlier, the patient was hospitalized in another hospital because of significant neutropenia, lymphopenia, thrombocytopenia, hepatosplenomegaly, and skin lesions. At that time, PG was diagnosed clinically. Further diagnostic procedures were performed then and they included bone marrow trephine biopsy, myelogram, colonoscopy, computed tomography (CT) of head, thorax,

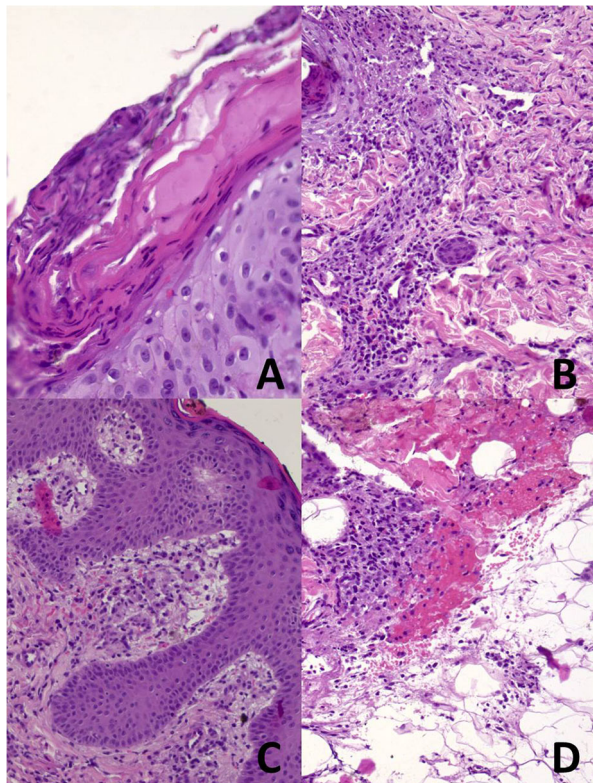


Fig. 2 Histopathology of the ulcer edge: subcorneal abscess formation (a); fibrinoid necrosis of the dermal vessel wall (b); pseudoepitheliomatous hyperplasia (c); infiltrate of chronic inflammatory cells and extravasation of red blood cells (d) [hematoxylin and eosin stain, original magnification: a $\times 40$, b–d $\times 20$]

abdomen, and pelvis, as well as many laboratory and autoimmune tests, but they remain inconclusive. The general condition of the patient was also good and no other symptoms were present. Oral glucocorticosteroid (prednisone 0.8–0.5 mg/kg/day) was administered as the first-line therapy, however, without significant clinical improvement.

At the time of admission to our department, the clinical manifestation of skin lesions was also typical for PG. Additionally, the skin biopsy was performed to exclude other conditions, e.g., cutaneous lymphoma (Fig. 2a–d). Furthermore, the patient still presented peripheral pancytopenia and hepatosplenomegaly. In addition, there were new symptoms such as daily high-spiking fevers of 39–40 °C, transaminitis, significantly elevated level of lactate dehydrogenase (LDH = 969 U/L) and β -2-microglobulin (17.5 mg/L). No lymphadenopathy nor loss of body weight was observed. The detailed screening for malignancies, autoimmune diseases, bowel inflammatory diseases, and infections was performed. CT of the head, thorax, abdomen, and pelvis was taken again, as well as ultrasonography of peripheral lymph nodes, panoramic teeth radiograph, protein electrophoresis, serum immunoglobulin levels, antinuclear antibodies, complement component (C3c and C4) serum levels, liver autoantibodies, serology for viral hepatitis, EBV (anti-VCA/EA IgG, anti-VCA IgM) and HIV, pharyngeal swab, blood culture, urine culture, and gastroenterological consultation. The background of PG and other symptoms remained unidentified.

As a result of serious lymphopenia (247 cells/ μ L), T cell receptor (TCR) gene rearrangement test was performed, but did not reveal any pathology. However, the immunophenotyping of peripheral blood lymphocytes showed important abnormalities: the presence of a significantly increased percentage of “double-negative” $CD3^+/CD4^-/CD8^-$ T lymphocytes (“double-negative” T cells; DNTs), constituting approximately 50% of the total population of T lymphocytes, and an increased percentage of the $CD16^+/CD3^-$ NK cell population, constituting approximately 45% of all lymphocytes (Figs. 3 and 4). The presence of residual

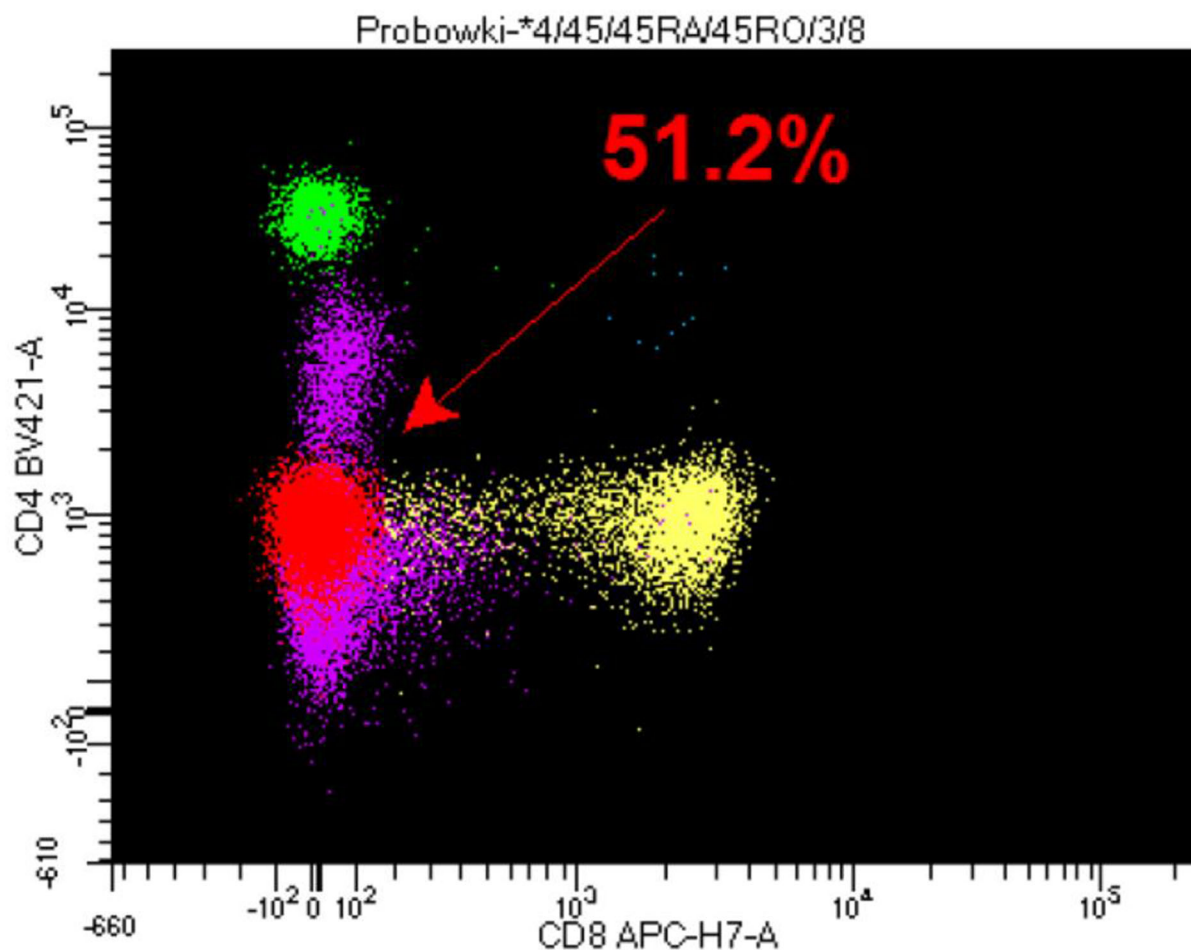


Fig. 3 “Double-negative” $CD4^-/CD8^-$ T lymphocytes* (red), $CD4^+$ helper T lymphocytes (green), $CD8^+$ cytotoxic T lymphocytes (yellow), $CD3^-/CD16^+$ NK cells (purple). *Full immunophenotypic profile of “double-

negative” T lymphocytes: $CD3^+$ strong/ $CD4^-/CD8^-/CD2^+/CD5^+$ dim/ $CD7^+/CD56^\pm/CD57^-/CD45RA^-/CD45RO^-/TCR\alpha\beta^-/TCR\gamma\delta^+$

populations of DNTs and NK cells constituting, respectively, 0.6% and 0.8% of all nucleated cells, was confirmed about 2 months later in the bone marrow. Additionally, it has been observed that cells of granulocytic lineage in the bone marrow showed about 95% expression of CD64 and HLA-DR, which could indicate their increased activation status.

In a meantime, the treatment with intravenous methylprednisolone pulses every 4 weeks was started, followed by prednisone 0.5 mg/kg daily and cyclosporin dosed depending on serum drug level. With each pulse, clinical improvement was achieved and lasted no

longer than 2 weeks from administration of methylprednisolone (Fig. 1e–h), and then PG progressed slowly again. Topical treatment of PG lesions included hydrofiber silver-impregnated antimicrobial dressing (Aquacel[®] Ag), hydrogel wound dressing (Purilon[®] Gel), lipid fat-impregnated sterile dressing (Grassolind[®] Neutral), and 0.05% betamethasone with 0.1% gentamicin ointment applied on the ulcer edges. Because of the lack of full response, in December 2019 IVIG (2 g/kg) were added to the therapy, again, without therapeutic effect. In addition, the hematological disorder continued to progress. Thus, bone marrow was evaluated

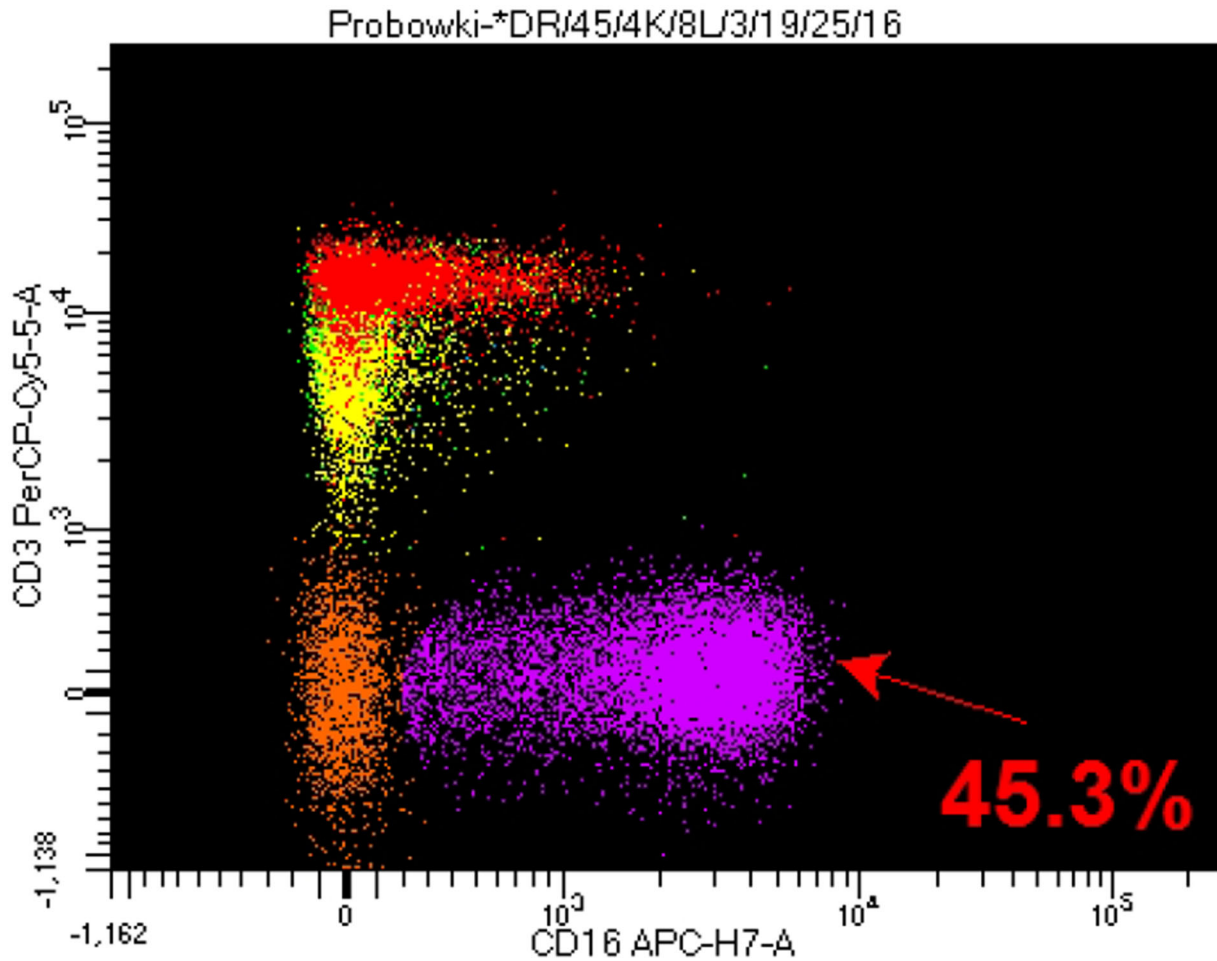


Fig. 4 CD3⁻/CD16⁺ NK cells* (purple), *double-negative* CD4⁻/CD8⁻ T lymphocytes (red), CD8⁺ cytotoxic T lymphocytes (yellow), CD4⁺ helper T lymphocytes

(green), B lymphocytes (orange). *Full immunophenotypic profile of NK cells: CD3⁻/CD16⁺/CD56⁺/CD57⁻/CD45RA⁺/CD45RO⁻/CD2⁺/CD5⁻/CD7⁺

both cytomorphologically in aspirate and histopathologically in biopsy. The aspirate showed coarse toxic granules in granulocytes and numerous hemophagocytes (Fig. 5), present also in the histopathological sample. HLH was suggested and diagnosed quickly in January 2020, according to HLH-2004 diagnostic guidelines [17]. Five out of eight HLH-2004 criteria were confirmed (Fig. 6). HLH-2004 protocol therapy was initiated with etoposide 150 mg/m² i.v. twice weekly, dexamethasone 10 mg/m² p.o. daily, cyclosporin depending on its blood levels, and supportive therapy indicated in the aforementioned protocol [12]. The treatment resulted in grade 4 neutropenia (according to CTCAE v.3.0) and serious bacteremia

quickly after the second administration of etoposide, and subsequently the patient withdrew his consent to continue etoposide, despite some improvement of skin lesions (Fig. 1i–l).

Two weeks after discontinuation of etoposide therapy, the progression of both HLH and PG was noted. In March 2020, the rescue treatment with anakinra (100 mg subcutaneously once a day) was started, in addition to previous treatment with steroids and cyclosporin, as its effectiveness was reported in both PG and HLH [18–25]. However, no clinical improvement was observed and the patient's condition gradually deteriorated. Recurrent thrombocytopenia, neutropenia, and lymphopenia progressed to grade 4 (according to CTCAE v.3.0), resulting in

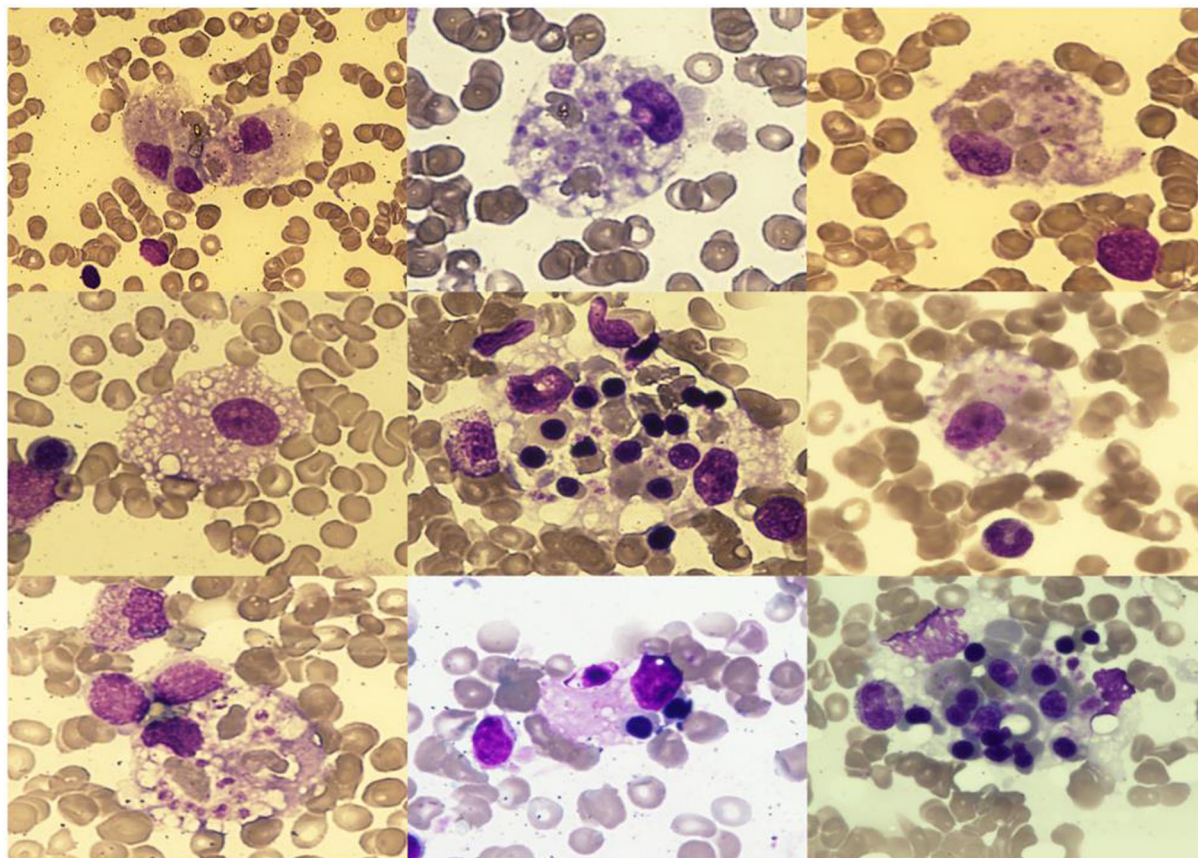


Fig. 5 Hemophagocytes in the patient’s bone marrow. Fragments of phagocytosed cells of the erythroid lineage are present within the macrophage cytoplasm

the patient’s death from sepsis with multiorgan failure. The timeline of therapeutic management and outcomes is presented in Table 1.

DISCUSSION AND LITERATURE REVIEW

The management of PG remains a challenge as therapeutic decisions need to be personalized, focused on the presence of concomitant diseases, and the specific quantity, location, diameter, and depth of lesions. The topical therapy of PG often does not allow proper control of disease activity. Therefore, the additional use of systemic therapeutic agents is necessary in more severe PG cases.

For the purposes of this article, a detailed search of the PubMed database was carried out, using the following search terms: “pyoderma gangrenosum”, “hemophagocytic lymphohistiocytosis”, “HLH”, “double negative T lymphocytes”, “treatment of pyoderma gangrenosum”, “topical treatment of pyoderma gangrenosum”, and “systemic treatment of pyoderma gangrenosum”. Articles published till January 2021 were selected on the basis of their relevance. The list of suitable articles was amended by manual search of references of identified papers. All studies published in languages other than English were excluded. The most relevant papers on PG treatment involving more than 15 patients are listed in Table 2.

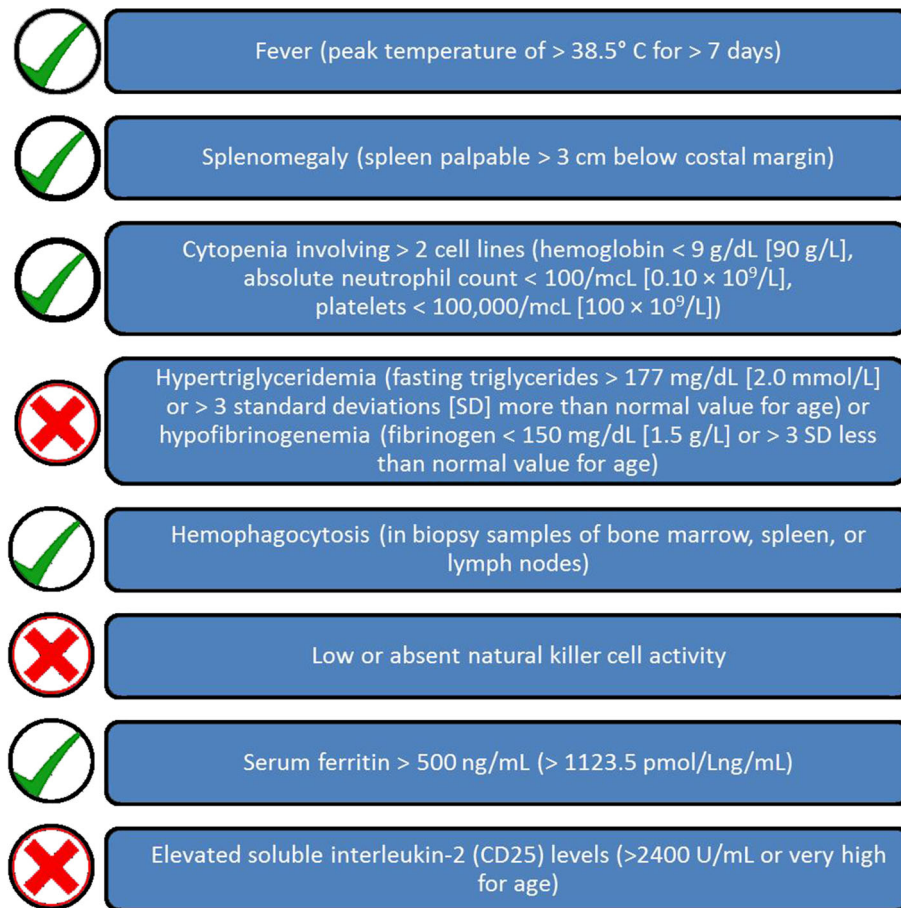


Fig. 6 HLH-2004 diagnostic criteria for hemophagocytic lymphohistiocytosis fulfilled by the patient [17]

Topical Therapy

The most common topical treatments for PG include calcineurin inhibitors and potent or ultra-potent corticosteroids. According to Marzano et al., monotherapy with tacrolimus could be the first-line treatment of idiopathic, early, localized PG [29]. In a case series of five patients treated with 0.1% tacrolimus ointment, complete clinical remission was achieved within a mean time of 6 weeks [37]. Moreover, in another clinical trial conducted by Lyon et al., 11 patients with peristomal PG were treated with topical tacrolimus 0.3%, whereas 17 patients received topical clobetasol propionate 0.05% [30]. This study suggested that 0.3% tacrolimus might be more effective than clobetasol in managing PG lesions larger than 2 cm

in diameter. Importantly, in most case reports, topical tacrolimus was used together with other systemic therapies.

Systemic Therapy

Systemic corticosteroids and cyclosporin, either in monotherapy or combined, are considered first-line agents for PG. The results from a randomized controlled trial comparing oral cyclosporin (4 mg/kg per day) with prednisolone (0.75 mg/kg per day) showed no significant difference between these two regimens [26]. Despite similar adverse reactions, infections were more common in the prednisolone group, while renal impairment and hypertension were frequent in the cohort receiving cyclosporin. Hence, the specific side effect

Table 1 Review of treatments for pyoderma gangrenosum based on the current literature (only studies involving more than 15 patients were included)

5 months earlier	Prednisone 0.8 mg/kg/d	←	Diagnosis of PG Neutropenia, lymphopenia, thrombocytopenia, hepatosplenomegaly
			Improvement of PG lesions and normalization of neutropenia
Day 0	Prednisone 0.5 mg/kg/d	←	Exacerbation of PG and hematological parameters Hepatosplenomegaly Chronic fever around 40 °C
	The day of admission	←	
	Intravenous methylprednisolone 3x500 mg Q4W Prednisone 0.5 mg/kg/d Ciclosporin 4.2 mg/kg/d	←	Short term improvement of PG lesions lasting up to 2 weeks after i.v. steroid pulse, followed by worsening of PG lesions. High levels of double-negative lymphocytes detected.
2nd month of treatment	Intravenous immunoglobulin 2 mg/kg added to the previous therapy	←	Ineffective
		←	Trepanobiopsy repeated HLH diagnosis
3rd month of treatment	HLH – 2004 Protocol: -Etoposide 150 mg/m ² i.v. twice weekly (tapering doses) -Cyclosporin aiming at levels around 200 µg/l -Dexamethasone daily of 10 mg/m ² (tapering doses)	←	Slight improvement of PG lesions Neutropenia 4 th grade (CTCAE) Bacteremia
		←	Bacteremia resolved Slight improvement of neutropenia
	Antibiotherapy	←	
4th month of treatment	Continuation of HLH – 2004 Protocol Treatment without etoposide	←	Progression of PG and HLH: Neutropenia 4 th grade (CTCAE) Thrombocytopenia 4 th grade (CTCAE) Sepsis -> death
	Anakinra 100 mg/d Prednisone 1 mg/kg/d Ciclosporin 3 mg/kg/d	←	
5th month of treatment			

profiles of both drugs should be crucial in making treatment decisions.

In cases of refractory PG, intravenous immunoglobulin therapy (IVIg) can be used simultaneously with systemic steroids [36, 38–40]. In a systematic review of 49 patients, 43 (87.8%) achieved a complete or

partial response, whereas complete response was observed in 26 (53.1%) of cases. Most patients received a dose of 2 g/kg and the average time to initial response was 3–5 weeks. These findings suggest that clinicians may consider IVIg as adjuvant therapy or a good alternative to cyclosporin and corticosteroids.

Table 2 Review of treatments for pyoderma gangrenosum based on the current literature (only studies involving more than 15 patients were included)

Description of treatment modality	Patient population	End points	Response rate	Conclusions	References
<i>Randomized controlled trials</i>					
Prednisolone 0.75 mg/kg/day compared with cyclosporin 4 mg/kg/day	<i>n</i> = 112	The primary end point: healing of the ulcers over 6 weeks	108 patients had complete primary outcome data (51 prednisolone group, 57 cyclosporin group)	Prednisolone and cyclosporin provided similar treatment success and remain the first-line treatment option	Ormerod et al. [26]
53 patients received prednisolone	Mean age In prednisolone group: 51.3	Secondary end points: time to healing, PG-specific global	Secondary outcomes did not differ between groups	Adverse reactions were similar for the two groups	
59 patients received cyclosporin	In cyclosporin group: 57.2	treatment response, resolution of inflammation,	By 6 months, ulcers had healed in 25/53 (47%) in the prednisolone group and 28/59 (47%) in the cyclosporin group	Serious adverse reactions, mainly infections, were more common in the prednisolone group	
	Sex In prednisolone group: M/F 22:31	self-reported pain, health-related quality of life, time to recurrence, number of treatment failures, adverse reactions			
	In cyclosporin group: M/F 17:42	up to 6 months			
	Comorbidities				
	In prednisolone group				
	Crohn's disease 3				
	Ulcerative colitis 8				
	Rheumatoid arthritis 4				
	Other inflammatory arthritis 3				
	Diabetes 9				
	Epilepsy 1				
	In cyclosporin group				
	Crohn's disease 5				
	Ulcerative colitis 7				
	Rheumatoid arthritis 4				
	Other inflammatory arthritis 3				
	Other malignancy 4				
	Diabetes 4				
	Mild renal impairment 2				

Table 2 continued

Description of treatment modality	Patient population	End points	Response rate	Conclusions	References
At week 0 patients received infliximab at a dose of 5 mg/kg or placebo	n = 30	Primary end point: clinical improvement at week 2	46% (6/13) patients had improved in 2 weeks compared to 6% (1/17) in placebo group	Infliximab at a dose of 5 mg/kg was superior to placebo and it is a promising treatment strategy	Brooklyn et al. [27]
13 patients received infliximab	Mean age In infliximab group: 50	Improvement was based on a reduction in ulcer size and depth	29 patients received infliximab with 69% (20/29) beneficial clinical response		
17 patients received placebo	In placebo group: 55	Secondary end points: clinical remission and clinical improvement at week 6, improvement in quality of life scores at week 6	at week 6 was 21% (6/29)		
Unresponsive patients (n = 23) received infliximab 5 mg/kg from week 2.	Sex In infliximab group: M/F 6:7		There was no response in 31% (9/29) of patients		
Further clinical assessments occurred at weeks 4 and 6	In placebo group: M/F 7:10				
	Comorbidities				
	Patients were divided into three subgroups: patients with additional inflammatory bowel disease (IBD) n = 18, patients without IBD n = 11, and patients with peristomal PG n = 9				
<i>Prospective observational studies</i>					
All patients were treated with oral corticosteroids	n = 18 Mean age 34.4 Sex M/F 10:8	N/A	16 patients improved and remained in remission. One of the patients was lost to follow-up after partial healing. The patient with polycythemia vera died	Patients with positive pathology sign required a higher dose of corticosteroids	Bhat et al. [28]
Prednisolone dose 20–80 mg	Comorbidities			Systemic corticosteroids seem to be good choice for the treatment of PG	
Additionally	Ulcerative colitis 3				
11 patients received dapsone	Seronegative arthritis 4				
2 patients received dexamethasone–cyclophosphamide pulse therapy	SLE 1				
1 patient received clofazimine	CML 1				
	Polycythemia vera 1				
			The patient with CML partially responded to therapy, but then died as a result of intracranial hemorrhage. The recurrence rate was 33.33%		

Table 2 continued

Description of treatment modality	Patient population	End points	Response rate	Conclusions	References
First line 7 patients with localized PG received topical tacrolimus 10 patients with multiflesional PG received prednisone 4 patients with disseminated PG received prednisone and cyclosporin	n = 21 All patients were subdivided into three subsets: localized, multiflesional, and disseminated PG Mean age 45 Sex M/F 10:11 Comorbidities Ulcerative colitis 4.9% IGA lambda monoclonal gammopathy 1.5% IGA lambda myeloma 1.5% Cystic fibrosis 1.5% Klinefelter's syndrome 1.5% Kidney neoplasm 1.5%	The primary end point Classification for PG Correlating disease Therapeutic approach, which should induce complete clinical remission in more than 80% of patients; relapse should not occur less than 1 month after therapy withdrawal	Topical tacrolimus proved to be useful in localized PG. Multiflesional PG was successfully treated with prednisone alone or in combination with cyclosporin Disseminated PG responded well to prednisone plus cyclosporin, except for refractory cases in which infliximab was employed	Complete remission observed in more than 80% cases. Relapses were controlled by the same or more aggressive treatment in more than 80% of cases	Marzano et al. [29]
11 patients received topical tacrolimus 0.3% 13 patients received topical clobetasol propionate 0.05%	n = 24 Mean age N/A Sex N/A Comorbidities N/A	To compare the efficacy of topical tacrolimus 0.3% formulated in carmellose sodium paste with topical clobetasol propionate 0.05%	Complete remission 7 patients in the tacrolimus group (mean time to healing 5.1 weeks) vs 5 patients in the clobetasol propionate group (mean time to healing 6.5 weeks) Topical tacrolimus was more effective than clobetasol propionate in managing larger PPG lesions (ulcer diameter > 2 cm)	Topical tacrolimus may be an interesting treatment option In more severe cases of PG topical tacrolimus should be used together with other systemic therapies	Lyon et al. [30]

Retrospective studies and case series

Table 2 continued

Description of treatment modality	Patient population	End points	Response rate	Conclusions	References
Overall/first/definitive treatment	<i>n</i> = 67	N/A	Definitive healing was observed in 4 months on average	Oral corticosteroid therapy remains the most common treatment for PG associated with inflammatory bowel disease	Argüelles-Arias et al. [31]
Oral corticosteroids 51/50/19	Mean age 44				
Infliximab 24/3/22	Sex M/F 26/41		Response rate of corticosteroids was estimated at 38% compared to infliximab 92%		
Cyclosporin 10/4/6	Comorbidities				
Adalimumab 7/3/7	Crohn's disease 41				
Azathioprine 6/0/5	Ulcerative colitis 25				
Tacrolimus 3/1/2					
Surgery 2/2/2					
Sulfasalazine 1/1/1					
Systemic therapy used in 21 (91.3%) patients	<i>n</i> = 27	N/A	70% of patients improved; however, after 1 year one-third of 27 patients still had PG requiring readmission	None of the current therapies provide satisfactory results in all of the patients	Adşen et al. [32]
17 patients were treated with systemic corticosteroids including	Mean age 48.6				
Monotherapy (7)	Sex M/F 10:17				
In combination with other agents	Comorbidities				
Cyclosporin (10)	Behçet's disease 2				
Antibiotics (8)	IBD 2				
Mycophenolate mofetil (4)	Myelodysplastic syndrome 1				
Biologics (infliximab, adalimumab) (3)	Solid neoplasia 3				
Cyclophosphamide (2)	Hypertension 9				
Dapsone (2)	Diabetes 5				
Intravenous immunoglobulin (1)	Thyroiditis 4				
Azathioprine (1)	Hyperlipidemia 4				
Chlorambucel (1)	Congestive heart failure 3				
Clofazimine (1)	Cervical radiculopathy 1				
	Venous insufficiency 8				
	Tuberculosis 1				
	Chronic renal insufficiency 1				
	Meniere disease 1				
	Deep vein thrombosis 1				
	Anemia 14				
	Depression 1				
	Hepatitis 1				

Table 2 continued

Description of treatment modality	Patient population	End points	Response rate	Conclusions	References
All patients with peristomal PG treated with prednisone at a dose of 20–40 mg	n = 17 Historically compared two groups of patients: group A treated before 1998 (<i>n</i> = 7); group B treated after 1998 (<i>n</i> = 10)	N/A	Complete healing (epithelialization) observed in all patients In group B, earlier healing of peristomal PG (<i>p</i> = 0.0023) was observed	Corticosteroid administration improves healing of peristomal PG	Funayama et al. [33]
	Mean age A: 42 B: 25 Sex M/F A: 2:5 B: 4:6 Comorbidities A: Ulcerative colitis 7 B: Ulcerative colitis 7, Crohn's disease 2, indeterminate colitis 1				
All patients received prednisolone. The mean prednisolone dose was 40 mg daily followed by 18 mg daily	n = 26 Mean age 66.3 Sex M/F 12:14 Comorbidities Rheumatoid arthritis 4 Crohn's disease 2 Chronic lymphocytic leukemia 1 Myelodysplasia 1 Chronic small vessel vasculitis 1 Prostate cancer 1 Breast cancer 1 Malignant melanoma 1	Ulcer size was established by measuring height and width Improvement without complications was marked as "excellent", improvement complicated by flares or side effects was marked as "good", and treatment without improvement was marked as "ineffective"	The average duration of treatment was 12.1 months Overall 22 patients demonstrated clinical improvement during mycophenolate mofetil treatment (84.6%). 13 patients achieved complete ulcer healing (50%)	Mycophenolate mofetil in combination with prednisolone could be an interesting treatment approach. This study has limitations as it did not provide differences in response between patients on monotherapy versus combination therapy	Li and Kelly [34]
Mycophenolate mofetil was used as a first-line steroid-sparing agent in 11 patients (42.3%), second-line in 14 (53.8%), and third-line in 1 (3.85%) The initial dose of MMF was 1 g (24/26) or 2 g (2/26) total daily. The maintenance dose was 2 g (10/26) or 3 g total daily (13/26)					

Table 2 continued

Description of treatment modality	Patient population	End points	Response rate	Conclusions	References
10 patients received systemic corticosteroids	<i>n</i> = 24 Mean age 58.3 Sex M/F 5:19 Comorbidities Ulcerative colitis 4 Diverticulitis 2 Crohn's disease 1 Myelodysplastic syndrome 2 Monoclonal gammopathy 2 Chronic myelomonocytic leukemia 1 Myeloproliferative disorder 1 Seronegative polyarthritis 1 Wegener's granulomatosis 1 Churg–Strauss syndrome 1 Colon adenocarcinoma 1 Prostate adenocarcinoma 1	N/A	Response to therapy was generally favorable, with complete healing in 20 patients (83%), on average 4.9 ± 5.8 months after starting treatment. 3 patients on corticosteroids, corticosteroids with cyclosporin, and on topical treatment have died. One patient on topical treatment was lost to follow-up	Systemic combination therapy with corticosteroids and other immunosuppressive agents can be useful	Pereira et al. [35]
8 patients were treated with systemic corticosteroids and cyclosporin					
1 patient was treated with systemic corticosteroids and dapsona					
2 patients received dapsona					
3 patients received superpotent topical corticosteroids					
36 patients (73.5%) received IVIG at a dose of 2 g/kg or higher	<i>n</i> = 49 Mean age 53.9 Sex M/F 15:26; 8 N/A Comorbidities Malignancy 22 (45%) Inflammatory bowel disease 12 (24.5%) Post-trauma/surgical 11 (22%) Autoimmune 8 (16%) Hidradenitis suppurativa 2 (4%)	To assess the efficacy of IVIG as adjunct therapy for refractory PG	26 (53%) patients achieved complete response 43 (88%) patients achieved complete or partial response 6 (12%) patients had not responded to treatment	IVIG may be considered as adjuvant therapy for refractory PG	Song et al. [36]
13 (26.5%) patients received IVIG at a dose lower than 2 g/kg					
IVIG was administered with systemic steroids in 43 (88%) cases, in monotherapy in 3 cases (8%), and with a steroid-sparing immunosuppressive agent in 1 (2%) case; there was missing data in 2 (4%) cases					

The use of other immunosuppressive agents, such as azathioprine, methotrexate, cyclophosphamide, mycophenolate mofetil, or thalidomide have been described in the literature; however, more data are required to evaluate their effectiveness in the management of PG, as currently only individual case series are available [41–44].

In recent years, many new treatment approaches have been introduced for a subset of patients who only partially respond to conventional immunosuppressive therapy [45]. Although the role of cytokines in pathogenesis of PG is not fully understood, overexpression of tumor necrosis factor alpha (TNF α) is associated with the neutrophil infiltration characteristic of PG; therefore, this group of drugs may be useful. A multicenter study evaluated the efficacy and safety of adalimumab in active ulcers of PG [46]. In this clinical trial, 22 enrolled patients received adalimumab 160 mg at week 0, followed by 80 mg at week 2, and then 40 mg every week starting at week 4. Of this group, seven patients (32%) who achieved Physician Global Assessment (PGA) 0 (all ulcers completely healed) completed the study at week 26, while nine patients (41%) who reached improvement of ulcers with a PGA score of 1–3 at week 26 entered the extension period to receive adalimumab 40 mg every week until week 52. Eighteen patients experienced adverse events, most commonly infections ($n = 11$), whereas serious adverse events, such as anemia, cataract, bacterial arthritis, and pain due to PG, were reported by four patients. Nevertheless, the results of this study suggest that adalimumab is an effective and generally well-tolerated treatment for patients with PG.

The efficacy of infliximab for the treatment of PG was evaluated in a randomized, double-blind, placebo-controlled trial conducted by Brooklyn et al. [27]. In this study, 30 patients were randomized to receive an infusion of infliximab at 5 mg/kg or placebo at week 0. Thereafter, 13 patients received infliximab, and 17 patients received a placebo. At week 2, the infliximab group achieved better improvement (46%; 6/13) compared to placebo group (6%; 1/17). Subsequently, patients were reassessed, and those who did not respond were offered

open-label infliximab at the same dose. At the end of the study, of the 29 patients who received infliximab, 69% (20/29) demonstrated a favorable clinical response.

Although data for the effectiveness of etanercept are limited to case reports and small case series, it appears to be useful in the treatment of recalcitrant and widespread PG [47–53]. The majority of studies showed clinical improvement or complete resolution with no serious adverse reactions. However, compared to infliximab, etanercept was less effective in the treatment of PG coexisting with active Crohn's disease. Another novel TNF α inhibitor golimumab could be an interesting treatment option, especially for patients who did not respond to infliximab and adalimumab therapies [54]. In one case report, 24 weeks after the start of the treatment with golimumab, the patient showed complete remission of PG. It is worth noting, that TNF α inhibitors, especially adalimumab and etanercept, may elicit potential paradoxical effects and induce PG lesions. In such cases, the IL-12/23 inhibitor ustekinumab has proved to be beneficial [55], as several reports have demonstrated the complete resolution of resistant PG lesions with this drug. However, further research is required to confirm these results.

In some genetic syndromes such as PAPA (pyogenic arthritis, PG, and acne) mutation in the *PSTPIP1* gene is common. In these cases, increased IL-1 production was noted. Therefore, IL-1 inhibitors could be the treatment of choice for this group of patients. Several studies have described the rapid and lasting response to anakinra in patients with PAPA syndrome [20]. Nevertheless, data suggesting its superiority over other biological drugs are still limited. Another monoclonal antibody targeting IL-1 β canakinumab was found to be effective in the case of steroid-refractory PG [56]. In this prospective open-label study, five patients received canakinumab subcutaneously in a single dose of 150 mg at weeks 0 and 2, and a dose of 150–300 mg at week 4. Four out of five patients achieved reduction in wound size, as well as improvement of PGA score and the Dermatology Life Quality Index (DLQI). In

addition, three out of five patients showed complete remission at week 16.

Peculiarities of Current Case

Among possible therapeutic options for PG, some molecules, such as corticosteroids, cyclosporin, and IVIG, may also be used in treatment of HLH. Simultaneously, the pathogenesis of these diseases is still not fully understood, which makes choosing the optimal treatment modality difficult. Moreover, both PG and HLH can coexist with various systemic disorders, and the requirement for successful therapy is to treat these comorbidities effectively, as well. Here, we demonstrate a case of the concomitance of these two rare diseases, where, despite intensive cooperative treatment, no successful outcome was obtained. A long thorough analysis of the interview and medical documentation also did not lead us to determine which of these conditions developed primarily and which was secondary.

The detection and further research of abnormalities within cell populations will possibly help us to understand mechanisms responsible for occurrence of these two conditions and their symptoms. In our patient we observed an increased NK cell population, constituting approximately 45% of all lymphocytes, while normally in adults they only represent about 10–15% of the total peripheral blood lymphocytes. In HLH, cytotoxic T lymphocytes and NK cells are dysfunctional, which leads to pathological immune stimulation resulting in a significant increase in proinflammatory cytokine concentrations and in reduced or absent NK cell activity. The functioning of T lymphocytes and NK cells may be affected also by genetic disorders, which results in abnormal synthesis of their intracellular cytotoxic granules [57, 58].

Additionally, an increased $CD4^+/CD8^-$ (TCR γ/δ) DNT population was also revealed, constituting approximately 50% of all peripheral blood T lymphocytes, instead of the normally observed less than 5% [59]. The exact role and function of DNTs within the immune system remains still unclear. A high percentage of

these cells is described in infections (both bacterial and viral), inflammatory diseases, post-splenectomy, cellular immunity deficiencies, autoimmune disorders, or lymphoproliferative malignancy [60–62]. Reports on immunophenotypic changes accompanying HLH focus mainly on the population of cytotoxic T lymphocytes, while reports on the presence of DNTs in the course of HLH are rare [9]. An increased, similarly to our observation, number of DNTs was reported by Dalal et al. [63], who studied various immunophenotypic abnormalities in adults with HLH. Splenic infiltration of atypical $CD4^+/CD8^- \alpha/\beta$ T cells in a 14-year-old boy diagnosed with HLH was reported by Hossny et al. [64].

PG and HLH appear to be disorders of the immune system and share common mechanisms consisting of increased production of cytokines, among others the IL-1 family. It is already well recognized that blocking of IL-1-mediated inflammation by anakinra (human IL-1 receptor antagonist) reduces consequences of tissue damage and organ failure. Anakinra is registered for treatment of rheumatoid arthritis, Still disease, and cryopyrin-associated periodic syndromes; however, it is also frequently used off-label. There are reports about successful anakinra therapy of PG in the context of PAPA syndrome [20], PG in association with hidradenitis suppurativa and acne (PASH syndrome) [21], and PG in association with rheumatoid and psoriatic arthritis [22, 23]. Anakinra was also reported as a useful therapeutic for patients suffering from severe HLH [24, 25]. Therefore, in the absence of standard therapy options, we decided to use anakinra in our patient. However, the ineffectiveness of this treatment may suggest the need to look for another common immunological checkpoint in patients with co-morbid HLH and PG. So far, there are no descriptions of such clinical cases; thus the aim of this case report is to draw attention to the need to search for new therapeutic options for these patients. Recently, monoclonal antibodies (such as emapalumab, a human IgG1 monoclonal antibody against interferon-gamma) and JAK pathway inhibitors (such as ruxolitinib) have been approved and reported to be effective in the treatment of HLH

[65–69]. Further clinical trials are ongoing to confirm the effectiveness and safety of these and other biological and small molecule therapies in different groups of patients suffering from HLH. Currently, it seems that the use of biological drugs may be considered in the treatment of HLH patients, especially in patients refractory or intolerant to conventional HLH therapy. However, further controlled trials are warranted.

ACKNOWLEDGEMENTS

Compliance with Ethics Guidelines. Informed consent for publication, including publication of the images within the article, was obtained from the patient.

Funding. No funding or sponsorship was received for this study or publication of this article. No Rapid Service Fee was received by the journal for the publication of this article.

Authorship. All named authors meet the International Committee of Medical Journal Editors (ICMJE) criteria for authorship for this article, take responsibility for the integrity of the work as a whole, and have given their approval for this version to be published.

Authors' Contributions. Aleksandra Opalińska drafted the dermatological side of the whole manuscript regarding pyoderma gangrenosum and the case report. Dominika Kwiatkowska prepared the literature review. Adrian Burdacki performed the flow cytometry analysis, wrote the part about the double negative T lymphocytes, and prepared Figs. 3–5. Mirosław Markiewicz drafted the part of the hematological side of the manuscript regarding hemophagocytic lymphohistiocytosis (HLH), consulted and controlled the therapy of HLH. Dominik Samotij was responsible for the photographs of the skin lesions and supervision of the patient treatment. Marek Dudziński and Jadwiga Niemiec-Dudek played roles in making the diagnosis of HLH and choosing the HLH therapy. Elżbieta Ostańska made a

histopathological evaluation and figures. Adam Reich made a concept and design, validated, supervised and edited the whole manuscript, tables and figures. All authors read the entire manuscript and made the appropriate corrections when necessary.

Disclosures. Aleksandra Opalińska, Dominika Kwiatkowska, Adrian Burdacki, Mirosław Markiewicz, Dominik Samotij, Marek Dudziński, Jadwiga Niemiec-Dudek, Elżbieta Ostańska have nothing to disclose. Adam Reich is a member of the journal's Editorial Board.

Data Availability. All data are reported in the manuscript. No additional data were generated while preparing this manuscript.

Open Access. This article is licensed under a Creative Commons Attribution-NonCommercial 4.0 International License, which permits any non-commercial use, sharing, adaptation, distribution and reproduction in any medium or format, as long as you give appropriate credit to the original author(s) and the source, provide a link to the Creative Commons licence, and indicate if changes were made. The images or other third party material in this article are included in the article's Creative Commons licence, unless indicated otherwise in a credit line to the material. If material is not included in the article's Creative Commons licence and your intended use is not permitted by statutory regulation or exceeds the permitted use, you will need to obtain permission directly from the copyright holder. To view a copy of this licence, visit <http://creativecommons.org/licenses/by-nc/4.0/>.

REFERENCES

1. Brooklyn T, Dunnill G, Probert C. Diagnosis and treatment of pyoderma gangrenosum. *Br Med J.* 2006;333:181–4.
2. Braswell SF, Kostopoulos TC, Ortega-Loayza AG. Pathophysiology of pyoderma gangrenosum (PG): an updated review. *J Am Acad Dermatol.* 2015;73:691–8.

3. DeFilippis EM, Feldman SR, Huang WW. The genetics of pyoderma gangrenosum and implications for treatment: a systematic review. *Br J Dermatol*. 2015;172:1487–97.
4. Montagnon CM, Fracica EA, Patel AA, et al. Pyoderma gangrenosum in hematologic malignancies: a systematic review. *J Am Acad Dermatol*. 2020;82:1346–59.
5. Goldust M, Hagstrom EL, Rathod D, et al. Diagnosis and novel clinical treatment strategies for pyoderma gangrenosum. *Expert Rev Clin Pharmacol*. 2020;13:157–61.
6. Reichrath J, Bens G, Bonowitz A, Tilgen W. Treatment recommendations for pyoderma gangrenosum: an evidence-based review of the literature based on more than 350 patients. *J Am Acad Dermatol*. 2005;53:273–83.
7. Teagle A, Hargest R. Management of pyoderma gangrenosum. *J R Soc Med*. 2014;107:228–36.
8. Jordan MB, Allen CE, Weitzman S, et al. How I treat hemophagocytic lymphohistiocytosis. *Blood*. 2011;118:4041.
9. Dalal BI, Vakil AP, Khare NS, et al. Abnormalities of the lymphocyte subsets and their immunophenotype, and their prognostic significance in adult patients with hemophagocytic lymphohistiocytosis. *Ann Hematol*. 2015;94:1111–7.
10. Filipovich A, McClain K, Grom A. Histiocytic disorders: recent insights into pathophysiology and practical guidelines. *Biol Blood Marrow Transplant*. 2010;16:S82.
11. Saxena R, Pati HP, Mahapatra M. Atlas of hematology. New Delhi: Jaypee Brothers Medical Publishers; 2012. 110 p. ISBN 978-93-5025-508-7.
12. Naeim F, Rao NP, Song SX, Grody WW. Atlas of hematopathology: morphology, immunophenotype, cytogenetics, and molecular approaches, 1st ed. London: Academic; 2013. ISBN 13: 9780123851833, ISBN 10: 0123851831.
13. Filipovich AH. Hemophagocytic lymphohistiocytosis (HLH) and related disorders. *Hematology Am Soc Hematol Educ Program*. 2009;2009:127–31.
14. Lehmborg K, Nichols KE, Henter JI, et al. Consensus recommendations for the diagnosis and management of hemophagocytic lymphohistiocytosis associated with malignancies. *Haematologica*. 2015;100:997–1004.
15. Arca M, Fardet L, Galicier L, et al. Prognostic factors of early death in a cohort of 162 adult haemophagocytic syndrome: impact of triggering disease and early treatment with etoposide. *Br J Haematol*. 2015;168:63–8.
16. Kleynberg RL, Schiller GJ. Secondary hemophagocytic lymphohistiocytosis in adults: an update on diagnosis and therapy. *Clin Adv Hematol Oncol*. 2012;10:726–32.
17. Henter JI, Horne A, Aricó M, et al. HLH-2004: diagnostic and therapeutic guidelines for hemophagocytic lymphohistiocytosis. *Pediatr Blood Cancer*. 2007;48:124–31.
18. Pazyar N, Feily A, Yaghoobi R. An overview of interleukin-1 receptor antagonist, anakinra, in the treatment of cutaneous diseases. *Curr Clin Pharmacol*. 2012;7:271–5.
19. Wollina U, Tchernev G. Pyoderma gangrenosum: pathogenetic oriented treatment approaches. *Wien Med Wochenschr*. 2014;164:263–73.
20. Brenner M, Ruzicka T, Plewig G, et al. Targeted treatment of pyoderma gangrenosum in PAPA (pyogenic arthritis, pyoderma gangrenosum and acne) syndrome with the recombinant human interleukin-1 receptor antagonist anakinra. *Br J Dermatol*. 2009;161:1199–201.
21. Braun-Falco M, Kovnerystyy O, Lohse P, et al. Pyoderma gangrenosum, acne, and suppurative hidradenitis (PASH)—a new autoinflammatory syndrome distinct from PAPA syndrome. *J Am Acad Dermatol*. 2012;66:409–15.
22. Beynon C, Chin MF, Hunasehally P, et al. Successful treatment of autoimmune disease-associated pyoderma gangrenosum with the IL-1 receptor antagonist anakinra: a case series of 3 patients. *J Clin Rheumatol*. 2017;23:181–3.
23. Acquitter M, Plantin P, Kupfer I, et al. Anakinra improves pyoderma gangrenosum in psoriatic arthritis: a case report. *Ann Intern Med*. 2015;163:70–1.
24. Wohlfarth P, Agis H, Gualdoni GA, et al. Interleukin 1 receptor antagonist anakinra, intravenous immunoglobulin, and corticosteroids in the management of critically ill adult patients with hemophagocytic lymphohistiocytosis. *J Intensive Care Med*. 2019;34:723–31.
25. Eloiseily EM, Weiser P, Crayne CB, et al. Benefit of anakinra in treating pediatric secondary hemophagocytic lymphohistiocytosis. *Arthritis Rheumatol*. 2020;72:326–34.
26. Ormerod AD, Thomas KS, Craig FE, et al. Comparison of the two most commonly used treatments for pyoderma gangrenosum: results of the STOP GAP randomised controlled trial. *BMJ*. 2015;350:h2958.

27. Brooklyn TN, Dunnill MGS, Shetty A, et al. Infliximab for the treatment of pyoderma gangrenosum: a randomised, double blind, placebo-controlled trial. *Gut*. 2006;55:505–9.
28. Bhat RM, Nandakishore B, Sequeira FF, et al. Pyoderma gangrenosum: An Indian perspective. *Clin Exp Dermatol*. 2011;36:242–7.
29. Marzano AV, Trevisan V, Lazzari R, et al. Pyoderma gangrenosum: a study of 21 patients and proposal of a 'clinicotherapeutic' classification. *J Dermatolog Treat*. 2011;22:254–60.
30. Lyon CC, Stapleton M, Smith AJ, et al. Topical tacrolimus in the management of peristomal pyoderma gangrenosum. *J Dermatolog Treat*. 2001;12:13–7.
31. Argüelles-Arias F, Castro-Laria L, Lobatón T, et al. Characteristics and treatment of pyoderma gangrenosum in inflammatory bowel disease. *Dig Dis Sci*. 2013;58:2949–54.
32. Adışen E, Erduran F, Gürer MA. Pyoderma gangrenosum: a report of 27 patients. *Int J Low Extrem Wounds*. 2016;15:148–54.
33. Funayama Y, Kumagai E, Takahashi KI, Fukushima K, Sasaki I. Early diagnosis and early corticosteroid administration improves healing of peristomal pyoderma gangrenosum in inflammatory bowel disease. *Dis Colon Rectum*. 2009;52:311–4.
34. Li J, Kelly R. Treatment of pyoderma gangrenosum with mycophenolate mofetil as a steroid-sparing agent. *J Am Acad Dermatol*. 2013;69:565–9.
35. Pereira N, Brites MM, Gonçalo M, Tellechea Ó, Figueiredo A. Pyoderma gangrenosum—a review of 24 cases observed over 10years. *Int J Dermatol*. 2013;52:938–45.
36. Song H, Lahood N, Mostaghimi A. Intravenous immunoglobulin as adjunct therapy for refractory pyoderma gangrenosum: systematic review of cases and case series. *Br J Dermatol*. 2018;178:363–8.
37. Marzano AV, Trevisan V, Lazzari R, et al. Topical tacrolimus for the treatment of localized, idiopathic, newly diagnosed pyoderma gangrenosum. *J Dermatolog Treat*. 2010;21:140–3.
38. Kreuter A, Reich-Schupke S, Stucker M, et al. Intravenous immunoglobulin for pyoderma gangrenosum. *Br J Dermatol*. 2008;158:856–7.
39. Cummins DL, Anhalt GJ, Monahan T, Meyerle JH. Treatment of pyoderma gangrenosum with intravenous immunoglobulin. *Br J Dermatol*. 2007;157:1235–9.
40. Gupta AK, Shear NH, Sauder DN. Efficacy of human intravenous immune globulin in pyoderma gangrenosum. *J Am Acad Dermatol*. 1995;32:140–2.
41. Herberger K, Dissemond J, Hohaus K, et al. Treatment of pyoderma gangrenosum: retrospective multicentre analysis of 121 patients. *Br J Dermatol*. 2016;175:1070–2.
42. Alavi A, French LE, Davis MD, et al. Pyoderma gangrenosum: an update on pathophysiology, diagnosis and treatment. *Am J Clin Dermatol*. 2017;18:355–72.
43. Fletcher J, Raed A, Afsaneh A. Recent advances in managing and understanding pyoderma gangrenosum. *F1000Res*. 2019;8:2092.
44. Quist SR, Kraas L. Treatment options for pyoderma gangrenosum. *J Dtsch Dermatol Ges*. 2017;5:34–40.
45. McKenzie F, Cash D, Gupta A. Biologic and small-molecule medications in the management of pyoderma gangrenosum. *J Dermatolog Treat*. 2019;30:264–76.
46. Yamasaki K, Yamanaka K, Zhao Y, et al. Adalimumab in Japanese patients with active ulcers of pyoderma gangrenosum: twenty-six-week phase 3 open-label study. *J Dermatol*. 2000;47:1383–90.
47. Charles CA, Leon A, Banta MR, Kirsner RS. Etanercept for the treatment of refractory pyoderma gangrenosum: a brief series. *Int J Dermatol*. 2007;46:1095–9.
48. McGowan JW, Johnson CA, Lynn A. Treatment of pyoderma gangrenosum with etanercept. *J Drugs Dermatol*. 2004;3:441–4.
49. Pastor N, Betloch I, Pascual JC, Blanes M, Banuls J, Silvestre JF. Pyoderma gangrenosum treated with anti-TNF alpha therapy (etanercept). *Clin Exp Dermatol*. 2006;31:152–3.
50. Roy DB, Conte ET, Cohen DJ. The treatment of pyoderma gangrenosum using etanercept. *J Am Acad Dermatol*. 2006;54(Suppl 2):S128–34.
51. Goldenberg G, Jorizzo JL. Use of etanercept in treatment of pyoderma gangrenosum in a patient with autoimmune hepatitis. *J Dermatolog Treat*. 2005;16:347–9.
52. Rogge FJ, Pacifico M, Kang N. Treatment of pyoderma gangrenosum with the anti-TNF alpha drug—etanercept. *J Plast Reconstr Aesthet Surg*. 2008;61:431–3.
53. Disla E, Quayum B, Cuppari GG, Pancorbo R. Successful use of etanercept in a patient with pyoderma

- gangrenosum complicating rheumatoid arthritis. *J Clin Rheumatol*. 2004;10:50–2.
54. Benzaquen M, Monnier J, Beaussault Y, et al. Pyoderma gangrenosum arising during treatment of psoriasis with adalimumab: effectiveness of ustekinumab. *Australas J Dermatol*. 2017;58:e270–1.
55. Diotallevi F, Campanati A, Radi G, et al. Pyoderma gangrenosum successfully treated with golimumab: case report and review of the literature. *Dermatol Ther*. 2019;32:e12928.
56. Kolios AG, Maul JT, Meier B, et al. Canakinumab in adults with steroid-refractory pyoderma gangrenosum. *Br J Dermatol*. 2015;173:1216–23.
57. McCall CM, Mudali S, Arceci RJ, et al. Flow cytometric findings in hemophagocytic lymphohistiocytosis. *Am J Clin Pathol*. 2012;137:786–94.
58. Park MS, Yoo IY, Kim HJ, et al. Flow cytometric analysis of T cells in hemophagocytic lymphohistiocytosis. *Ann Lab Med*. 2019;39:430–7.
59. De Rosa SC, Andrus JP, Perfetto SP, et al. Ontogeny of $\gamma\delta$ T cells in humans. *J Immunol*. 2004;172:1637–45.
60. Pituch-Noworolska A. Immunophenotype of mature hematopoietic cells—primary and secondary immunodeficiencies. *Post Biol Kom*. 2008;35(suppl.24):45–54.
61. Roden AC, Morice WG, Hanson CA, et al. Immunophenotypic attributes of benign peripheral blood $\gamma\delta$ T Cells and conditions associated with their increase. *Arch Pathol Lab Med*. 2008;132:1774–80.
62. Prochorec-Sobieszek M. Characteristics of T-cell large granular lymphocyte proliferations. *J Transf Med*. 2009;2:81–135.
63. Dalal BI, Khare NS, Wang SY, et al. Diverse immunophenotypic abnormalities in adult patients with hemophagocytic lymphohistiocytosis. *Blood*. 2012;120:3267.
64. Hossny EM, El-Owaidy RH, Afifi HM, Ahmed HR. Double negative alpha beta T cells in pediatric hemophagocytic syndromes. *Egypt J Pediatr Allergy Immunol*. 2019;17:13–9.
65. Vallurupalli M, Berliner N. Emapalumab for the treatment of relapsed/refractory hemophagocytic lymphohistiocytosis. *Blood*. 2019;134:1783–6.
66. Cheloff AZ, Al-Samkari H. Emapalumab for the treatment of hemophagocytic lymphohistiocytosis. *Drugs Today (Barc)*. 2020;56:439–46.
67. Yildiz H, Van Den Neste E, Defour JP, et al. Adult haemophagocytic lymphohistiocytosis: a review. *QJM*. 2020. <https://doi.org/10.1093/qjmed/hcaa011>.
68. Ahmed A, Merrill SA, Alsawah F, et al. Ruxolitinib in adult patients with secondary haemophagocytic lymphohistiocytosis: an open-label, single-centre, pilot trial. *Lancet Haematol*. 2019;6:e630–7.
69. Goldsmith SR, Rehman SSU, Shirai CL, et al. Resolution of secondary hemophagocytic lymphohistiocytosis after treatment with the JAK1/2 inhibitor ruxolitinib. *Blood Adv*. 2019;3:4131–5.