

INNOVATIVE CLINICAL IMAGE

MR Imaging of Parasitic Leiomyoma with Red Degeneration

Hisayoshi Araki¹, Takeshi Yoshizako^{1*}, Rika Yoshida¹, Mitsunari Maruyama¹,
Noriyoshi Ishikawa², and Hajime Kitagaki¹

Keywords: *magnetic resonance imaging, parasitic leiomyoma, red degeneration*

There is a little information about the MRI features of parasitic leiomyoma, and those of parasitic leiomyoma with red degeneration findings have not been described.

A 52-year-old woman, who had undergone hysterectomy with morcellation for multiple leiomyomas 3 years previously, presented to her gynecologist with persistent fever (temperature of 38°C) and right lower abdominal pain. Examination revealed a tender mass in the right lower abdomen associated with rebound tenderness.

Contrast-enhanced computed tomography showed a well-defined heterogeneous hypo-dense mass approximately 2 cm in diameter in the right lower abdomen. To further characterize the lesion, 1.5T MRI (Signa Excite HD; GE Medical System, used phased-array coils) of the pelvis was performed.

On MRI, the round mass showed a heterogeneous high signal intensity on T₂-weighted images (T₂WI), a low signal intensity with peripheral high intensity on fat-suppressed T₁-weighted images (T₁WI), and a high signal intensity on diffusion weighted images ($b = 800$ s/mm²), with a low apparent diffusion coefficient map (Fig. 1a–1d). No enhancement of the lesion was detected on enhanced T₁WI (Fig. 1e). Gastrointestinal stromal tumor, dissemination of malignancy and lymph node swelling were considered as a differential diagnosis. From the history of hysterectomy

and image findings, a parasitic leiomyoma with red degeneration was suspected.

Laparoscopic resection of the mass was performed. Microscopic examination of the resected specimen revealed hyaline degeneration, fibrosis, necrosis, hemosiderosis, and venous infarction (Fig. 2). The final pathologic diagnosis was leiomyoma with red degeneration.

Parasitic leiomyoma is considered to arise when a uterine leiomyoma becomes attached to another structure in the abdomen and eventually receives its blood supply from that structure.¹ A parasitic leiomyoma may develop from a piece of tissue retained in the abdomen following morcellation of a leiomyoma or by detachment of a pedunculated subserosal leiomyoma from the uterus. Our patient had a history of hysterectomy for multiple leiomyomas of the uterus, suggesting the former mechanism.

On imaging, parasitic leiomyoma shows tissue characteristics similar to uterine leiomyoma.¹ Red degeneration, or hemorrhagic infarction, of a leiomyoma occur secondary to venous thrombosis in the peripheral part of the lesion. On MRI, a leiomyoma with red degeneration may show peripheral or diffuse high signal intensity on T₁WI and variable signal intensity with or without a low signal intensity rim on T₂WI, as well as no enhancement. The signal intensity characteristics of the rim are thought to be due to the effect of abundant intracellular methemoglobin in the obstructed vessels.²

Parasitic leiomyoma with red degeneration is very rare. However, parasitic leiomyoma with red degeneration should be suspected if the characteristic imaging findings are detected in a woman with acute abdomen and a history of uterine leiomyoma.

Conflicts of Interest

The authors declare that they have no conflicts of interest.

¹Department of Radiology, Shimane University Faculty of Medicine, 89-1 Enya, Izumo, Shimane 693-8501, Japan

²Department of Organ Pathology, Shimane University Faculty of Medicine, Shimane, Japan

*Corresponding Author, Phone: +81-853-20-2289, Fax: +81-853-20-2285, E-mail: yosizako@med.shimane-u.ac.jp

©2019 Japanese Society for Magnetic Resonance in Medicine

This work is licensed under a Creative Commons Attribution-NonCommercial-NoDerivatives International License.

Received: November 27, 2018 | Accepted: April 2, 2019

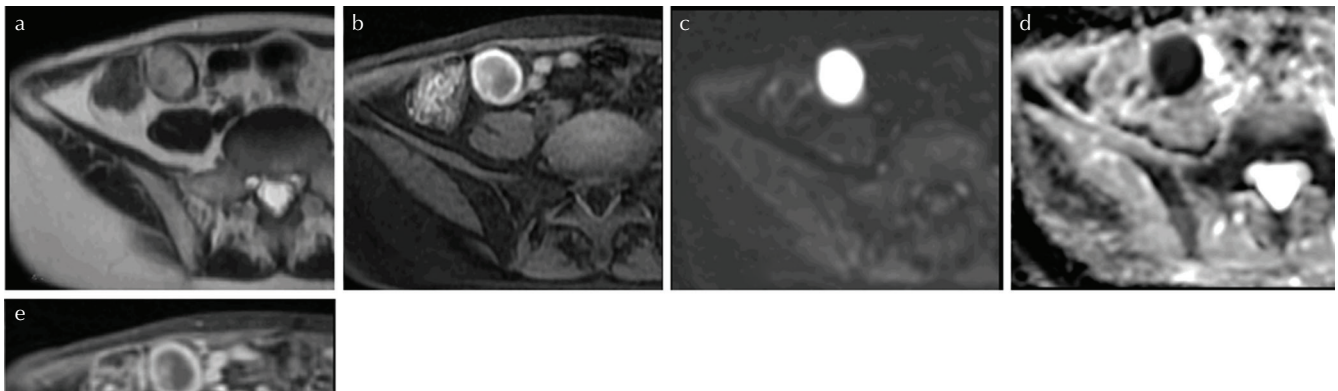


Fig. 1 (a) Axial T₂-weighted images (T₂WI) reveals a mass approximately 2 cm in diameter in the right lower abdomen showing heterogeneous high signal intensity. (b) The mass shows low signal intensity with peripheral high intensity on axial fat-suppressed T₁-weighted images (T₁WI). (c and d) On diffusion weighted image (DWI), the mass has high signal intensity with a low apparent diffusion coefficient (ADC) map ($0.486 \times 10^{-3} \text{ mm}^2/\text{s}$). (e) The mass shows no enhancement on fat-suppressed T₁WI after injection of gadolinium.

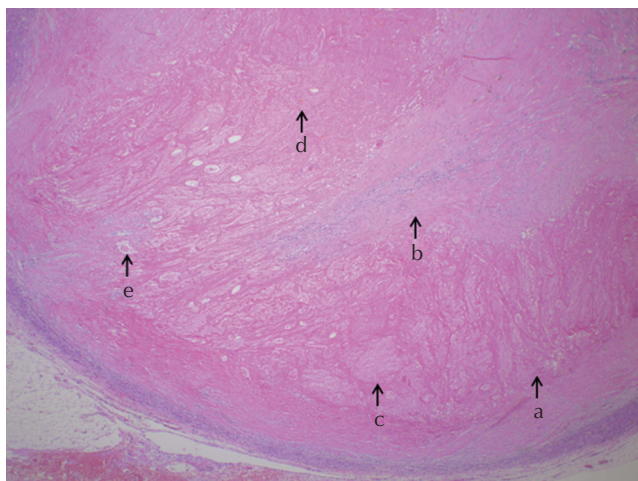


Fig. 2 Photomicrograph of the resected specimen of parasitic leiomyoma shows hyaline degeneration (a), fibrosis (b), necrosis (c), hemosiderosis (d), and venous infarction (e) (H&E, 40×).

References

1. Cohen DT, Oliva E, Hahn PF, Fuller AF, Lee SI. Uterine smooth-muscle tumors with unusual growth patterns: imaging with pathologic correlation. *AJR Am J Roentgenol* 2007; 188:246–255.
2. Iraha Y, Okada M, Iraha R, et al. CT and MR imaging of gynecologic emergencies. *Radiographics* 2017; 37: 1569–1586.