



## Case report

## Rhinoorbital mucormycosis in the immunocompetent: Experience with Isavuconazole



Marta Ilharco<sup>a,\*</sup>, Carla Maravilha Pereira<sup>a,\*</sup>, Laura Moreira<sup>a</sup>, Ana Luísa Proença<sup>b</sup>, Maria do Carmo Fevereiro<sup>a</sup>, Fátima Lampreia<sup>a</sup>, Miguel Lopes Oliveira<sup>c</sup>, José Rola<sup>a</sup>

<sup>a</sup> Department of Internal Medicine 1.4, Hospital de S. José – Centro Hospitalar Universitário de Lisboa Central, Lisbon, Portugal

<sup>b</sup> Department of Radiology, Hospital de Curry Cabral – Centro Hospitalar Universitário de Lisboa Central, Lisbon, Portugal

<sup>c</sup> Department of Maxillofacial Surgery, Hospital de S. José - Centro Hospitalar Universitário de Lisboa Central, Lisbon, Portugal

## ARTICLE INFO

## Article history:

Received 31 May 2019

Received in revised form 7 July 2019

Accepted 7 July 2019

## Keywords:

Mucormycosis  
Immunocompetent  
Isavuconazole  
Hyperbaric oxygen

## ABSTRACT

Mucormycosis is a severe opportunistic fungal infection caused by *Mucorales*. The majority of the affected patients have a history of immunosuppression, with a reported incidence of 4–19% in the immunocompetent. Early recognition and diagnosis, combined with surgical debridement and appropriate antifungal therapy are essential to achieve a cure. In this article we report the case of a 61-year-old immunocompetent male who complained with pain in his right eye. After being first diagnosed with conjunctivitis and treated accordingly, he eventually needed surgical debridement and the biopsy showed the presence of fungi of the class *Zygomycetes*. He was submitted to intravenous therapy with Liposomal Amphotericin B (LAmB) and Posaconazole for several days, which was then changed to Isavuconazole due to bicytopenia. He also received treatment with hyperbaric oxygen, achieving altogether good results. He was discharged after eight months, still on oral Isavuconazole 200mg/day and re-evaluated after three and six months, showing no evidence of progression of the infection.

© 2019 The Authors. Published by Elsevier Ltd. This is an open access article under the CC BY-NC-ND license (<http://creativecommons.org/licenses/by-nc-nd/4.0/>).

## Introduction

Mucormycosis is an uncommon, opportunistic infection caused by fungi of the order *Mucorales*. This microorganism can be found everywhere in the environment, contaminating the soil, vegetables, animal and manufactured products [1]. It behaves in an extremely aggressive way, invading vessels, soft tissue, nerves, bone and cartilage, which eventually leads to tissue infarction and ultimately vessel thrombosis and necrosis [2]. The majority of patients developing mucormycosis have history of immunosuppression, such as diabetes and diabetic ketoacidosis, patients who have received organ or hematopoietic stem cell transplant, patients with severe neutropenia or malignancy [3]. However, some patients with mucormycosis have no identifiable risk factors – therefore, they are considered immunocompetent, with an incidence in literature of 4–19% [4].

The successful treatment of mucormycosis requires a combination of early diagnosis, reversal of possible underlying predisposing factors, aggressive surgical debridement when applicable and intravenous antifungal therapy [3].

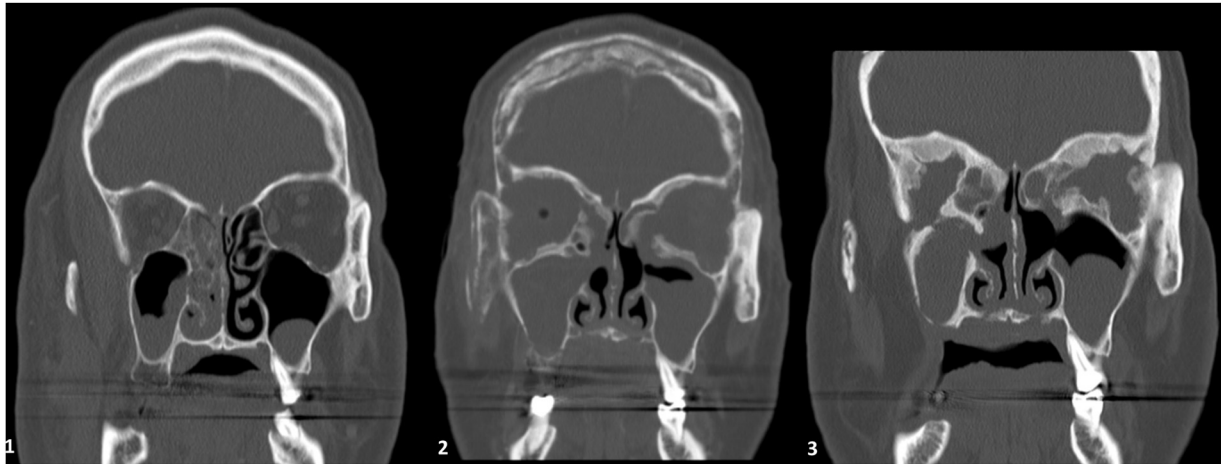
In this article, we present a successfully treated case of rhino-orbito-maxillary mucormycosis in a 61-year-old immunocompetent male.

## Case report

A 61-year-old male with a history of dyslipidemia and chronic sinusitis presented with a 48-h history of pain in the right eye. He was diagnosed with conjunctivitis and prescribed topical antibiotics. Since the symptoms persisted, he returned a week later, complaining with palpebral edema and proptosis of the right eye. Orbital cellulitis was then diagnosed and the patient was started on Ceftriaxone and Vancomycin. At this point, the CT and MRI revealed extensive right orbital cellulitis, with no intracranial changes. Five days later, a decompressive lateral cantotomy and tissue biopsy of the right eye were performed, with no evidence of exudate. Meanwhile, there was rapid progression of the disease with left eye involvement and vision loss, which motivated the patient's transfer to a central hospital. Therefore, nineteen days after initial

\* Corresponding authors.

E-mail addresses: [martailharco@gmail.com](mailto:martailharco@gmail.com) (M. Ilharco), [carla.maravilha.p@gmail.com](mailto:carla.maravilha.p@gmail.com) (C.M. Pereira), [miguel.lopes.oliveira@hgo.min-saude.pt](mailto:miguel.lopes.oliveira@hgo.min-saude.pt) (M.L. Oliveira).



**Image 1.** Evolution of bone destruction shown on CT scan coronal planes. 1. Normal bone density and morphology at admission 2. Extensive osteolytic changes with permeative pattern, involving the orbital wall, perinasal sinus, frontal and right zygomatic bones 3. Diffuse bone thickening due to chronic osteitis.

presentation, the patient was assessed by Ophthalmology, Maxillofacial Surgery and Otorhinolaryngology, who carried out a surgical procedure consisting of sphenoethmoidectomy, antrostomy and re-permeabilization of the frontal sinus. However, a new CT scan revealed right cavernous sinus thrombosis. The patient was then transferred to the Intensive Care Unit for increased vigilance and started on empiric intravenous therapy with Vancomycin (3.5 g/day), Clindamycin and Liposomal Amphotericin B (LAmB), which he maintained for 10 days. Upon the progression of bilateral ocular edema, papilledema, complete vision loss and left eyelid necrosis, the patient was submitted to bilateral orbital exenteration with upper and lower blefarotomy on the left side, by the Maxillofacial Surgery team. The microbiology assay of the orbital tissues showed the presence of microorganisms compatible with fungi of the class *Zygomycetes*. The patient was then transferred to an Internal Medicine ward. The initial image control failed to show regression of the infection, and he therefore suspended Clindamycin and Vancomycin and started Posaconazole in association with ongoing LAmB, which he maintained for, respectively, 63 and 78 days. As a side effect of this antifungal therapy he developed mild anemia and severe neutropenia, occasionally needing infusion of granulocyte colony-stimulation factor (G-CSF), whenever neutrophil count dropped below 500/mL. In addition to this, a more aggressive debridement was performed, with removal of all middle third facial necrotic tissues. Since the patient was failing to improve, a request was emitted to order Isavuconazole as a salvage therapy and the patient was also started on hyperbaric oxygen, approximately one month after being admitted to the hospital, performing a total of 20 sessions. These were complicated with barotrauma of the right tympanic membrane, with the need for a transtympanic catheter. The patient was started on Isavuconazole 80 days after hospitalization, interrupting antifungal therapy with Posaconazole and LAmB. Isavuconazole was started intravenously, with a 2-day loading dose of 200 mg three times per day, followed by a daily dose of 200 mg. Anemia and neutropenia were reverted and the lesions observed in the CT began to improve, showing signs of osteoneogenesis (Image 1). Intravenous therapy was maintained for 24 days, switching to oral Isavuconazole and maintaining it after discharge. We report as clinically relevant a single episode of supra-ventricular tachycardia while on intravenous Isavuconazole, revertible after 6 + 12 mg of adenosine. An echocardiogram and Holter were performed with normal results and the episode did not repeat itself. An extensive study of immunosuppression was performed, including diabetes mellitus, viral infections, autoimmunity, bone marrow study, search for neoplasms and primary

immunosuppression, and nothing was found. All blood tests were normal apart from the changes mentioned earlier, namely liver function and hematological study, including iron overload. The patient was therefore considered immunocompetent. After six months in Internal Medicine, he was transferred for Maxillofacial Surgery department for further facial wounds management, including surgical debridements and vacuum dressings. He was discharged after eight months, while on treatment with oral Isavuconazole in the dosage of 200 mg/day. He was evaluated after three, six and twelve months with no evidence of progression of the infection.

## Discussion

Mucormycosis is the common name given to several different diseases caused by fungi of the order *Mucorales* [5]. It is an opportunistic fungal infection, far more common in immunocompromised patients, despite the fact that it can also occur in healthy individuals. Our patient was fairly young and presented with no comorbidities other than chronic sinusitis. It has been hypothesized that a chronic local insult might act as a predisposing factor in otherwise healthy individuals. Although the spore size of the fungi allows them to enter the host via respiration, the mucosal/cutaneous epithelium and endothelium represent a fundamental and effective barrier against tissue invasion and angioinvasion. A condition such as chronic sinusitis might be caused by an impairment of mucociliary clearance, which in turn causes changes of first-line barrier defense of upper airway. Individuals would then be more vulnerable to fungal colonization and infection [6]. Consequently, we can speculate that chronic sinusitis could have been, in this case, a predisposing factor for the infection.

Moreover, in several descriptions of cases [2], an initial diagnosis of orbital cellulitis is performed and broad spectrum antibiotic therapy is often started, disregarding antifungal therapy. Chamilos et al. showed that early diagnosis of mucormycosis contributes to the improvement of patients' survival, establishing a 5-day cutoff according to which patients who start therapy within 5 days of the first symptoms have a survival rate of 83% compared to the 49% of those who initiate therapy after 6 days [7]. In our case, the patient started LAmB approximately twenty days after initial presentation. The delay on the start of antifungal therapy could have been avoided, had there been a higher level of suspicion.

Other patients who survived have been treated with a combination of LAmB, orbital exenteration and adjacent tissue debridement [2]. Blood vessel thrombosis and resulting tissue

necrosis can result in poor penetration of antifungal agents to the site of the infection, which is why surgical debridement may be critical for complete eradication of the infection [3]. Regarding treatment of this fungal infection, it is difficult to gather robust data, because it is a rare disease, characterized by heterogeneity of hosts and sites of infection. Information regarding the current approach of treatment is therefore based on single-institution, retrospective studies including a limited number of patients with significant variability in their presentation and risk factors, registries with methodological flaws, and “expert opinions” [8]. However, it is consensual that primary antifungal therapy should be based on a polyene, and, if possible, a lipid formulation of Amphotericin B should be used, due to its low level of nephrotoxicity and the fact that it can be administered at higher doses for a longer period of time than Amphotericin B deoxycolate (AmB) [9]. In the case we presented, LAmB together with surgery was not an effective treatment, given that the patient continued to show signs of disease progression. Therefore, the case was discussed together with the department of Infectious Diseases, and other options were considered. Triazoles act by depleting ergosterol from the fungal cell membrane [8]. Among triazole antifungals, posaconazole is the first azole possessing a broad spectrum of activity against Mucormycosis. Although some studies showed that combined posaconazole and LAmB offered no survival benefit over LAmB alone [10], posaconazole has variable in vitro activity against Mucorales, which is species-dependent, and the success rate of studies using the combination has been around 56% [8]. Moreover, 60–70% response rates have been reported in patients with mucormycosis who were refractory or intolerant to polyenes, and it is therefore an option to use posaconazole as salvage therapy for these infections [9]. Additionally, patients receiving posaconazole-based salvage therapy that leads to neutrophil recovery are said to have a favourable outlook [10]. Another option would be the combination of an echinocandin with LAmB, in which in vitro studies have shown evidence of synergism. Although inherently inactive against Mucorales, in vitro echinocandins are considered to have some in vivo effect [8]. Although it is an attractive combination, its use in human patients is not thoroughly studied, requiring assessment in well-designed clinical studies.

It was therefore an option of the multidisciplinary team accompanying the patient to combine LAmB and Posaconazole. Other reports had already described this approach [11].

Due to the hematological side-effects, presumably attributed to LAmB, together with slow progress in treatment, an alternative was found, and the Hospital asked for permission to request Isavuconazole, a therapy not available in our country at the time. We had to maintain the patient on LAmB and Posaconazole, however, as we waited for the arrival of Isavuconazole, prolonging the duration of the previous therapy and totalizing 78 days of LAmB.

Isavuconazole is a new extended-spectrum triazole with activity against yeasts, molds, and dimorphic fungi [12]. Since its metabolism takes place in the liver, no dose adjustment is necessary for patients with renal impairment, but interactions with other inhibitors of CYP3A4 enzyme lead to increased levels of Isavuconazole and must not be overlooked [13]. It has few reported significant adverse effects; however, it can cause QTc segment shortening, which we believe might have happened as an isolated episode in the case we present, resulting in supra-ventricular tachycardia. The VITAL study showed that Isavuconazole was active as primary or salvage treatment for mucormycosis, with response rates that are similar to those reported for LAmB [14]. It was after Isavuconazole was started that the greatest improvements were seen, and we were able to discharge the patient under oral therapy.

In this case, we have also used hyperbaric oxygen (HBO) as an adjunct therapy. This practice is usually well tolerated and associated with low risk of adverse events. HBO is a theoretically attractive therapy, due to the fact that it can relieve tissue hypoxia, promote angiogenesis and the action of LAmB [15]. We believe that, in this case, HBO contributed to achieving clinical stability and tissue healing.

## Conclusion

The successful treatment of Mucormycosis requires an early diagnosis, the reversal of identifiable predisposing risk factors, aggressive surgical debridement and prompt antifungal therapy [3]. Its diagnosis in immunocompetent patients is often misleading and can cause delay in treatment. In cases of persistent nasal congestion, ocular pain and proptosis and vessel thrombosis where there is no clear cause or there is resistance to antibiotic therapy, mucormycosis should be considered as a causative agent and an antifungal therapy should be started. LAmB remains the treatment of choice, whereas salvage therapies, such as Isavuconazole, must not be disregarded, since they are effective, have few side effects and can be administered by mouth.

Finally, it is essential to adopt a multimodal treatment strategy, through the collaboration of a multidisciplinary team aiming to achieve early diagnosis, surgical debridement, optimal antifungal therapy and other adjuncts if necessary, together with patient stabilization and follow-up.

## Declaration of patient consent

The authors certify that they have obtained all appropriate patient consent forms, where the patient has given his consent for his clinical information to be reported.

## Financial support

This research did not receive any grant from funding agencies in the public, commercial, or not-for-profit sectors.

## CRediT authorship contribution statement

**Marta Ilharco:** Writing - original draft, Investigation. **Carla Maravilha Pereira:** Conceptualization, Writing - review & editing. **Laura Moreira:** Investigation, Writing - review & editing. **Ana Luísa Proença:** Investigation, Visualization, Writing - original draft. **Maria do Carmo Fevereiro:** Writing - review & editing. **Fátima Lampreia:** Writing - review & editing, Supervision, Validation. **Miguel Lopes Oliveira:** Validation, Writing - review & editing. **José Rola:** Writing - review & editing.

## Acknowledgements

Our thanks are due to all the doctors who worked together on this case to achieve a favourable outcome, namely Dr. Sara Lino from the Department of Infectious Diseases, Dr. Ezequiel Barros and Dr. Jorge Mexia from the Department of Otorhinolaryngology, Dr. Miguel Oliveira and Dr. Alexandre Bouça from the Department of Maxillofacial Surgery.

## References

- [1] Herbrecht R, Sabou M, Ledoux M-P. Aspects cliniques et radiologiques des mucormycoses. *Médecine/Sciences* 2013;29(March (13)):19–24.
- [2] Shatriah I, Mohd-Amin N, Tuan-Jaafar TN, Khanna RK, Yunus R, Madhavan M. Rhino-orbito-cerebral mucormycosis in an immunocompetent patient: case report and review of literature. *Middle East Afr J Ophthalmol* 2012;19(2):258–61.

- [3] Spellberg B, Walsh TJ, Kontoyiannis DP, Edwards [59\_TD\$DIFF] Jr. J, Ibrahim AS. Recent advances in the management of mucormycosis: from bench to bedside. *Clin Infect Dis* 2009;48(June (12)):1743–51.
- [4] Gutiérrez-Delgado EM, Treviño-González JL, Montemayor-Alatorre A, Ceceñas-Falcón LA, Ruiz-Holguín E, Andrade-Vázquez CJ, et al. Chronic rhino-orbito-cerebral mucormycosis: a case report and review of the literature. *Ann Med Surg* 2016;6(March):87–91.
- [5] Venkatesh D, Dandagi S, Chandrappa P, Hema K. Mucormycosis in immunocompetent patient resulting in extensive maxillary sequestration. *J Oral Maxillofac Pathol* 2018;22(January (4)):112.
- [6] Mignogna MD, Fortuna G, Leuci S, Adamo D, Ruoppo E, Siano M, et al. Mucormycosis in immunocompetent patients: a case-series of patients with maxillary sinus involvement and a critical review of the literature. *Int J Infect Dis* 2011;15(August (8)):e533–40.
- [7] Chamilos G, Lewis RE, Kontoyiannis DP. Delaying amphotericin B-based frontline therapy significantly increases mortality among patients with hematologic malignancy who have zygomycosis. *Clin Infect Dis* 2008;47(August (4)):503–9.
- [8] Sipsas NV, Gamaletsou MN, Anastasopoulou A, Kontoyiannis DP. Therapy of Mucormycosis. *J fungi* 2018;4(July (3)).
- [9] Spellberg B, Ibrahim AS. Recent advances in the treatment of mucormycosis. *Curr Infect Dis Rep* 2010;12(November (6)):423–9.
- [10] Sun H-Y, Singh N. Mucormycosis: its contemporary face and management strategies. *Lancet Infect Dis* 2011;11(April (4)):301–11.
- [11] Graves B, Morrissey CO, Wei A, Coutsouvelis J, Ellis S, Pham A, et al. Isavuconazole as salvage therapy for mucormycosis. *Med Mycol Case Rep* 2016;11(March):36–9.
- [12] Peixoto D, Gagne LS, Hammond SP, Gilmore ET, Joyce AC, Soiffer RJ, et al. Isavuconazole treatment of a patient with disseminated mucormycosis. *J Clin Microbiol* 2014;52(March (3)):1016–9.
- [13] Miceli MH, Kauffman CA. Isavuconazole: a new broad-spectrum triazole antifungal agent Saravolatz L.D., editor. *Clin Infect Dis* 2015;61(November (10)):1558–65.
- [14] Marty FM, Ostrosky-Zeichner L, Cornely OA, Mullane KM, Perfect JR, Thompson GR, et al. Isavuconazole treatment for mucormycosis: a single-arm open-label trial and case-control analysis. *Lancet Infect Dis* 2016;16(July (7)):828–37.
- [15] John BV, Chamilos G, Kontoyiannis DP. Hyperbaric oxygen as an adjunctive treatment for zygomycosis. *Clin Microbiol Infect* 2005;11(July (7)):515–7.